Normal values for native T1 and gadolinium-based contrast agent excretion into pericardial fluid in healthy volunteers – comparison with patients with pericardial effusion

Simon Thalén MD[1], Joao G Ramos MD PhD[1], Henrik Engblom MD PhD[1], Andreas Sigfridsson PhD[1], Peder Sörensson MD PhD[2], Martin Ugander MD PhD [1,3,*]

[1]Department of Clinical Physiology, Karolinska University Hospital, and Karolinska Institutet, Stockholm, Sweden.

[2]Department of Cardiology, Karolinska University Hospital, Stockholm, Sweden.

[3]Kolling Institute, Royal North Shore Hospital, and Charles Perkins Centre, University of Sydney, Sydney, Australia.

[*]Corresponding author.

Abstract

T1 mapping cardiovascular magnetic resonance (CMR) imaging has been used to characterize pericardial effusions, and shown that routinely administered gadolinium-based contrast agents (GBCA) are excreted into effusion fluid. **Aims**: To measure pericardial fluid T1 before and after contrast administration in healthy volunteers to establish normal values and compare them to patients with pericardial effusion. Volunteers (n=30) were compared to retrospectively included patients with at least 5 mm of pericardial effusion (n=69). T1 maps were acquired at 1.5T CMR. A volume of pericardial fluid was imaged in a short-axis slice and in a slice perpendicular to the short-axis orientation. A reliable measurement had a region of interest size >10mm^2, coefficient of variation <10%, and a relative difference <5% between the two slice orientations. In 26/30 (87%) of volunteers, there was a sufficient amount of pericardial fluid to enable reliable measurement. Native T1 did not differ between slice orientations (3262±163 vs 3267±173 ms, p=0.75). In patients, native T1 was normal in 41%, above normal in 3%, below normal in 56%, and GBCA concentration, estimated using the specific relaxivity of the GBCA used, was normal in 65% and above normal in 35%. More than half of effusions in patients had a native T1 below normal, consistent with higher protein content, and a third had an above normal GBCA excretion despite dilution effects, suggesting an inflammatory and exudative etiology. The use of T1 mapping and contrast dynamics to characterize pericardial fluid merits prospective evaluation.

Introduction

Pericardial fluid is a serous ultrafiltrate of plasma normally present between the layers of the pericardium enveloping the heart. An increase in the amount of fluid above approximately 30-35 ml is considered a pericardial effusion [1]. Pericardial effusions can have a wide variety of etiologies, and are a common clinical occurrence. The diagnostic approach includes categorizing the effusion as transudative, due to an imbalance in osmotic and hydrostatic pressures, or exudative, due to an increase in permeability of the pericardium secondary to local inflammation. Biochemical analysis may be performed and interpreted using the Light criteria, originally validated for assessing pleural effusions [2].

With the rapid development of new techniques in cardiovascular magnetic resonance imaging (CMR) there have been several attempts to non-invasively characterize effusion fluids. Early attempts using magnetic field strengths below one tesla were largely unremarkable [3–7]. Later results using diffusion-weighted imaging have shown some promise, but also conflicting results [8–11].

T1-mapping, a technique whereby the T1 value is directly measured has now largely superseded the previous T1-weighted methods where the T1 value was encoded into arbitrary signal intensities and only indirectly estimated. GBCA shortens T1 time in healthy tissue and T1-mapping CMR following the administration of a gadolinium-based contrast agent (GBCA) has enabled the characterization of focal and global cardiovascular pathologies, and made it possible to reliably and quantitatively perform longitudinal and group comparisons [12].

Non-contrast (native) T1 mapping has successfully been used to classify pericardial and pleural effusions as transudate or exudate [13], and has further been used to successfully differentiate between malignant and non-malignant pleural and ascitic effusions *ex vivo* [14]. The rationale for these approaches is that proteins and cells leaking through a permeable

inflamed pericardium and into the pericardial fluid have paramagnetic properties that lower the T1 value of the effusion fluid. Consequently, a low native T1 value would be consistent with an exudate and a high value with a transudate.

One study showed 100% positive predictive value in diagnosing exudative pleural effusions using T1-weighted imaging and GBCA excretion [15]. More recently, T1 mapping of pericardial and pleural effusion fluid has also shown that GBCA routinely administered during CMR exams is always excreted into the effusion fluid, albeit with considerable variability in the amount excreted [16].

The current study aimed to measure T1 in pericardial fluid before, early, and late after intravenous GBCA administration in healthy volunteers to determine the feasibility of these measurements and establish normal values. We also sought to compare the normal values to that of a clinical cohort examined in a previously published study [16].

Methods

The study was approved by the Swedish Ethical Review Authority (application number 2011/1077-31/3) and conducted according to the principles of the Declaration of Helsinki. All participants were enrolled following written informed consent.

Volunteers

Healthy volunteers (n=30) were recruited. Exclusion criteria included any known cardiovascular pathology, MRI-unsafe metallic implants, and an estimated glomerular filtration rate below 30 mL/min/1.73 m^2 as measured by a point-of-care blood sampling of creatinine.

Image acquisition

T1 maps were acquired at end diastole using a modified look-locker inversion recovery (MOLLI) sequence [17] at 1.5T (MAGNETOM Aera, Siemens Healthcare, Erlangen, Germany) using motion-correction [18]. Pre and postcontrast used a 5s(3s)3s acquisition scheme where two inversions were made and images acquired once per heartbeat during five seconds after the first inversion, followed by a three-second pause, and images acquired once per heartbeat during three seconds after the second inversion [19].

Typical image acquisition parameters were: flip angle 35°, matrix size 256 × 136–158, slice thickness 8 mm, initial inversion time 129 ms, field of view 300-410 × 241–384 mm^2, parallel imaging factor 2.

A short-axis (SA) stack of T1-maps encompassing the heart and the ascending aorta was acquired and screened for the presence of pericardial fluid visible as areas with native T1 values above 2500 ms. A slice perpendicular (P) to the short-axis (SA) slice was then prescribed to enable two perpendicular measurements. T1 maps were then again acquired in the same SA slice positions, early (6 min) and late (25 min) after administration of an extracellular GBCA (0.05 mmol/kg, gadobutrol, Gadovist®, Bayer AB, Solna, Sweden).

Image analysis

Image analysis was performed on clinical workstations using clinical imaging software (syngo.via VB30A; Siemens Healthcare GmbH, Erlangen, Germany). Regions of interest (ROI) were manually prescribed in the same volume of pericardial fluid of both the SA and P slices. A three-dimensional cursor feature was used to ensure measurement in the same volume of pericardial fluid in both slice orientations.

To evaluate measurement reliability, the following criteria were used to define a reliable measurement: 1) the ROI size needed to be greater than 10 mm^2, 2) the coefficient of variation of measured values within the ROI needed to be less than 10%, and 3) the relative

difference in measured values between the SA and P slice orientations needed to be below 5%. The coefficient of variation was defined as the ratio of the standard deviation to the mean. The relative difference in native T1 between SA and P measurements was defined as |SA-P| / [(SA+P)/2]. The same volume of pericardial fluid was then identified in the SA stacks acquired early and late after GBCA administration and ROIs prescribed. The timing of contrast injection was recorded as well as the timing of early and late imaging from timestamps in the specific images used for measurement.

The following variables were analysed in the pericardial fluid: T1 acquired natively, early, and late after contrast injection. The following variables were then calculated: the difference between native T1 and T1 acquired early (ΔT1early) and late (ΔT1late), the change in relaxation rate early (ΔR1early) and late (ΔR1late) where ΔR1=1/T1postcontrast-1/T1native and the volume-independent pericardial fluid early-to-late contrast concentration ratio (ΔR1early/ΔR1late). An estimation of GBCA concentration was made using the formula [Gd] = ΔR1/r1, where r1 is the specific relaxivity of gadobutrol which has previously been determined to be 5.2 $L/mmol^{-1}/S^{-1}$ in plasma at 1.5 T and 37° C [20].

The estimated glomerular filtration (eGFR) rate was calculated for all volunteers using the revised Lund-Malmö GFR estimating equation [21].

Reanalysis of previously published data

The same variables analysed in a previously characterized clinical cohort [16] were used for comparison. T1 maps were acquired at end diastole using a modified look-locker inversion recovery (MOLLI) sequence [17] at 1.5T (MAGNETOM Aera, Siemens Healthcare, Erlangen, Germany) using motion-correction [18]. Pre contrast imaging used a 5(3)3 acquisition scheme where the first inversion as followed by acquisition over five heartbeats and three heartbeats pause and the second inversion was followed by acquisition over three

heartbeats. Post contrast imaging used either a 5(3)3 acquisition scheme or a 4(1)3(1)2 scheme where first inversion was followed by acquisition over four heartbeats and one heartbeat pause and the second inversion followed by acquisition over three heartbeats and one heartbeat pause and the third inversion followed by acquisition over two heartbeats [22]. Typical image acquisition parameters were otherwise identical to that of the healthy volunteers.

The GBCA used for the clinical cohort was gadoteric acid (0.2 mmol/kg, Dotarem®, Gothia Medical AB, Billdal, Sweden).

An estimation of GBCA concentration was made using the formula [Gd] = ΔR1/r1, where r1 is the specific relaxivity of gadoteric acid which has previously been determined to be 3.6 $L/mmol^{-1}/S^{-1}$ in plasma at 1.5 T and 37° C [20].

Statistical analysis

The normality of distributions was assessed both visually using Q-Q plots and the Shapiro-Wilks test and data reported as median [interquartile range] or mean±SD as appropriate. Mean value comparisons were made using parametric paired or unpaired t-tests as appropriate. A p-value of less than 0.05 was considered statistically significant. Normal reference ranges were calculated as mean ± 1.96*standard deviation. Statistical calculations were performed using the software package R (R Core Team 2020, Vienna, Austria).

Results

The healthy volunteers averaged 35 (range 20–61) years of age, 14 (46 %) were female and 26/30 (87 %) had a sufficient amount of pericardial fluid to enable reliable measurement. The characteristics of the volunteers are shown in table 1 and an example set of

T1 maps from one volunteer is shown in figure 1. Early imaging was performed (6±1 min) after, and late imaging (25±2 min) after contrast administration.

Native T1 in short-axis and perpendicular slice orientations did not differ (3262±163 vs 3267±173 ms, p=0.75). T1early was 2458±294 and T1late 1552+325 yielding a ΔT1early of 804±285 ms and a ΔT1late of 1710±344 ms. ΔR1early was 0.11±0.05 s^{-1}, ΔR1early 0.37±0.15 s^{-1} and the effusion-volume-independent early-to-late contrast concentration ratio ΔR1early/ΔR1late of 0.30±0.10.

There were no sex differences in native T1 (female 3311±177 vs. male 3220±142 ms, p=0.17), ΔT1early (female 769±276 vs. male 834±300), T1late (female 1669±381 vs. male 1745±319, p=0.59), ΔR1early (female 0.09±0.04 vs. male 0.12±0.06, p =0.24), ΔR1late (female 0.33±0.15 vs. male 0.40±0.15, p=0.24) or ΔR1early/ΔR1late (female 0.30±0.10 vs. male 0.30±0.11, p=0.97). The time course of T1 values is shown in figure 2.

Estimated GBCA concentration in pericardial fluid at the early timepoint, [Gd]early was (20±9 mmol/mL) and at the late timepoint [Gd]late was (70±28 mmol/mL). ROI size in the volume of pericardial fluid in short-axis and perpendicular slice orientations did not differ (18 [14-27] vs 16 [12-23] mm^2, p=0.49). Resulting normal reference ranges are shown in Table 2.

Early imaging of the clinical cohort was performed (3 [2-3] min), and late imaging (24 [19-25] min) after contrast administration. As the early imaging timepoint and the specific GBCA used differed between the healthy volunteers and the clinical patient cohort, the comparison was limited to native T1 and the late estimated GBCA concentration [Gd]late.

Results when applying the reference ranges to the previously published clinical cohort are shown in figure 3 and were as follows: In the clinical cohort native T1 of the pericardial fluid, was normal in 41 % of patients, above normal in 3% and below normal 56 %. The late

estimated concentration of GBCA, [Gd]late was normal in 65 %, above normal in 35 % and below normal in 0 % of patients.

Discussion

The main finding of the study is that native T1 and contrast excretion into pericardial fluid can be reliably measured in healthy volunteers, and normal reference ranges are presented.

Agreement between perpendicularly planned imaging slices showed that T1 can be reliably measured in a normal volume of pericardial fluid in healthy volunteers. All healthy volunteers with reliably measurable T1 showed contrast excretion into the pericardial fluid after GBCA administration. The native T1 values of pericardial fluid in the healthy volunteers in the current study are higher and less variable than the corresponding values in a previously reported cohort study of clinically referred patients [16].

It is not surprising that healthy volunteers show higher native T1 values and less variance. A clinical cohort is likely to contain some patients with inflammatory effusion etiologies, which would have a lower T1 value due to proteins present in the effusion fluid. Indeed, the native T1 was below normal in roughly half of patients in the clinical cohort. Yet only 20 % had a presumably exudative etiology such as malignancy, myocarditis, sarcoidosis or amyloidosis and the majority had presumably transudative ischemic heart disease, dilated left ventricle or left ventricular hypertrophy. This discrepancy could be due to the fact that diuretics, mainstay in the treatment of heart failure, have been found to increase the concentration of protein, or rather, lower the water content of effusion fluid leading to false positive classification as exudate using Light criteria [23]. As a negative correlation between protein levels and native T1 has been found in phantoms as well as *in vitro* [13] and *ex vivo*

[14] effusion fluids, it is reasonable to assume that effusions in patients treated with diuretics are at risk of false positive classification as exudates by T1 mapping.

Light´s criteria misclassifies 25% of pleural transudates as exudates [2], and doubts have been raised on whether it is at all feasible to use Light´s criteria for pericardial effusions, as the cut off values were validated for pleural effusions. In a recent study involving native T1 measurements of pleural and pericardial effusions, biochemical data enabling the use of Light´s criteria were available mostly for exudates and the cohort was therefore supplemented with presumed transudates by including patients with pericardial and/or pleural effusions and chronic severe left ventricular systolic dysfunction [13]. The validity of this approach is questionable as several studies have shown that most pericardial effusions are misclassified as exudate by Light's criteria, and most if not all normal pericardial fluid is classified as exudate [24–26]. We argue that any attempt to classify pericardial effusions as exudate or transudate should be restricted to predefined diagnostic categories reflecting the etiology of the effusion in lack of biochemical testing data validated specifically for pericardial effusions.

Native T1 values of pericardial fluid should at best be seen as a surrogate for biochemical testing measuring total protein content. Contrast dynamics may offer additional insights into the state and permeability of the pericardium.

The variability in post-contrast T1 values increases at the early and further increases at the late time point after contrast administration. The increasing variability over time after contrast administration is expected. As the permeability of the pericardium is variable between subjects, this will likely be evident as an increasing variability in the amount of contrast excreted over time after administration. Furthermore, given identical rate of excretion into pericardial fluid, varying amounts of fluid volume will lead to differences in contrast agent concentration in the pericardial fluid over time. The effusion-volume-

independent early-to-late contrast concentration ratio, ΔR1early/ΔR1late was conceived of to address this.

Limitations

Perhaps the most striking difference between a tissue such as the myocardium and pericardial fluid is that the latter is not perfused by capillaries. This precludes any analysis based on conventional tracer kinetics and 2- or 3-compartment models.

A limitation of this study is the size of ROI required to measure the small volumes of normal pericardial fluid present in healthy volunteers. The matrix size, field of view and slice thickness used in this study are equal to those in routine clinical use and translates to voxel dimensions of approximately 1.5 by 1.5 by 6 mm or 13.5 mm^3. The median ROI size of 18 mm^2 translates to 8 in-plane voxels, or image pixels, per ROI whereas international CMR guidelines recommend avoiding ROI sizes below 20 image pixels for T1 mapping of the myocardium [27]. Even though some partial volume is inevitable, we attempted to overcome this limitation by employing a minimum ROI size criteria, a within-ROI variance criteria, and a between-ROI variance criteria with perpendicular measurements. There are currently no studies or guidelines available to inform the choice, or specific values, of the above criteria for measurements of T1 in pericardial fluid. They were chosen for purposes of consistency based on clinical judgement.

Pre- and post-contrast T1 maps in the healthy volunteers were acquired using the 5s(3s)3s acquisition scheme whereas the pre-contrast T1 maps of the clinical cohort was acquired using the 5(3)3 acquisition scheme. The 5s(3s)3s acquisition scheme was designed to mitigate heart rate dependence by allowing for a more complete recovery at high heart rates [19]. All of the healthy volunteers had normal heart rates, therefore the use of different pre-contrast acquisition schemes should not have influenced the results of this study. Post-

contrast T1 maps in the clinical cohort was acquired the using 5(3)3 acquisition scheme or the 4(1)3(1)2 acquisition scheme, due to a change in the clinical protocol during the inclusion period. The 4(1)3(1)2 acquisition scheme was designed to improve the precision of measurements of the low T1 values in post-contrast myocardium (200 – 600 ms) [19]. While this could mean a lower precision at the longer T1 values of post-contrast pericardial fluid (900-2000 ms), it is not expected to introduce systematic bias.

A further limitation of this study is that the timing of early imaging after contrast injection differs between the healthy volunteers and clinical patients. To compare measurements of contrast dynamics, a homogeneous timing of early imaging between subjects is crucial. As early post-contrast CMR imaging usually involves single minutes, even a small discrepancy in timing can have drastic consequences. Unfortunately, a volume-independent comparison between the healthy volunteers and clinical patients was therefore not possible.

The use of different GBCAs in the healthy volunteers and clinical patients is also not ideal. We attempted to overcome this by estimating the GBCA concentration using the predetermined relaxivity of each specific GBCA in plasma at 1.5 T and 37° C.

Clinical applications

In one study, 0.6% of CMR exams were found to have incidental findings of clinically significant pericardial effusion [28]. A non-invasive alternative to diagnostic pericardiocentesis would have clinical significance as all invasive procedures involve some degree of risk. International guidelines recommend pericardiocentesis with biochemical testing upon suspicion of bacterial or neoplastic pericardial effusion [29]. A non-invasive method of characterizing pericardial fluid as transudate, and hence not of bacterial or neoplastic etiology, could then be used to avoid unnecessary diagnostic pericardiocentesis. If

on the other hand a pericardial effusion is characterized as an exudate, CMR imaging provides detailed anatomical information highly relevant to the pericardiocentesis procedure itself.

Conclusions

T1 can be reliably measured in a normal volume of pericardial fluid in healthy volunteers, and normal reference values are presented. Furthermore, T1 mapping shows a promising ability to differentiate normal pericardial fluid from pericardial effusion fluid in patients. The use of native T1 mapping and contrast excretion to characterize pericardial fluid is currently in its infancy and further research is required to determine the value of this approach.

Acknowledgements

We acknowledge the support provided by the CMR technologists at the Department of Clinical Physiology, Karolinska University Hospital.

Data availability

All data produced in the present study are available upon reasonable request to the authors.

References

1. Spodick DH. Macrophysiology, microphysiology, and anatomy of the pericardium: a synopsis. Am Heart J. 1992;124(4):1046–51.
2. Light RW. The Light Criteria. Clin Chest Med. 2013 Mar;34(1):21–6.
3. Cohen JM, Weinreb JC, Maravilla KR. Fluid collections in the intraperitoneal and extraperitoneal spaces: comparison of MR and CT. Radiology. 1985 Jun;155(3):705–8.

4. D T, U S, G de G, H S, Cb H. Evaluation of pleural and pericardial effusions by magnetic resonance imaging. Eur J Radiol. 1987 Aug;7(3):169–74.

5. Wall SD, Fisher MR, Amparo EG, Hricak H, Higgins CB. Magnetic resonance imaging in the evaluation of abscesses. AJR Am J Roentgenol. 1985 Jun;144(6):1217–21.

6. Terrier F, Revel D, Pajannen H, Richardson M, Hricak H, Higgins CB. MR imaging of body fluid collections. J Comput Assist Tomogr. 1986 Dec;10(6):953–62.

7. Brown JJ, vanSonnenberg E, Gerber KH, Strich G, Wittich GR, Slutsky RA. Magnetic resonance relaxation times of percutaneously obtained normal and abnormal body fluids. Radiology. 1985 Mar;154(3):727–31.

8. Baysal T, Bulut T, Gökirmak M, Kalkan S, Dusak A, Dogan M. Diffusion-weighted MR imaging of pleural fluid: differentiation of transudative vs exudative pleural effusions. Eur Radiol. 2004;14(5):890–6.

9. İnan N, Arslan A, Akansel G, Arslan Z, Eleman L, Demirci A. Diffusion-weighted MRI in the characterization of pleural effusions. Diagn Interv Radiol. 2009;15(1):13.

10. Karatag O, Alar T, Kosar S, Ocakoglu G, Yildiz Y, Gedik E, et al. Can diffusion weighted MRI differentiate between inflammatory-infectious and malignant pleural effusions? J Belg Soc Radiol [Internet]. 2015 [cited 2016 Jun 22];98(2). Available from: http://www.jbsr.be/articles/10.5334/jbr-btr.767/

11. Keskin Z, Yeşildağ M, Alkan E, Kayhan A, Tolu İ, Keskin S. Differentiation Between Transudative and Exudative Pleural Effusions by Diffusion Weighted Magnetic Resonance Imaging [Internet]. Vol. 16, Iranian Journal of Radiology. Kowsar; 2019 [cited 2020 Jul 15]. Available from: https://sites.kowsarpub.com/iranjradiol/articles/78775.html

12. Taylor AJ, Salerno M, Dharmakumar R, Jerosch-Herold M. T1 Mapping. JACC Cardiovasc Imaging. 2016 Jan;9(1):67–81.

13. Rosmini S, Seraphim A, Knott K, Brown JT, Knight DS, Zaman S, et al. Non-invasive characterization of pleural and pericardial effusions using T1 mapping by magnetic resonance imaging. Eur Heart J Cardiovasc Imaging. 2021 Jul 30;jeab128.

14. Kuetting D, Luetkens J, Faron A, Isaak A, Attenberger U, Pieper CC, et al. Evaluation of malignant effusions using MR-based T1 mapping. Sci Rep. 2021 Mar 29;11(1):7116.

15. Frola C, Cantoni S, Turtulici I, Leoni C, Loria F, Gaeta M, et al. Transudative vs exudative pleural effusions: differentiation using Gd-DTPA-enhanced MRI. Eur Radiol. 1997;7(6):860–4.

16. Thalén S, Maanja M, Sigfridsson A, Maret E, Sörensson P, Ugander M. The dynamics of extracellular gadolinium-based contrast agent excretion into pleural and pericardial effusions quantified by T1 mapping cardiovascular magnetic resonance. J Cardiovasc Magn Reson Off J Soc Cardiovasc Magn Reson. 2019 14;21(1):71.

17. Messroghli DR, Greiser A, Fröhlich M, Dietz R, Schulz-Menger J. Optimization and validation of a fully-integrated pulse sequence for modified look-locker inversion-

recovery (MOLLI) T1 mapping of the heart. J Magn Reson Imaging. 2007;26(4):1081–6.

18. Xue H, Greiser A, Zuehlsdorff S, Jolly MP, Guehring J, Arai AE, et al. Phase-sensitive inversion recovery for myocardial T1 mapping with motion correction and parametric fitting. Magn Reson Med. 2013 May;69(5):1408–20.

19. Kellman P, Hansen MS. T1-mapping in the heart: accuracy and precision. J Cardiovasc Magn Reson. 2014;16(1):2.

20. Rohrer M, Bauer H, Mintorovitch J, Requardt M, Weinmann HJ. Comparison of magnetic properties of MRI contrast media solutions at different magnetic field strengths. Invest Radiol. 2005;40(11):715–24.

21. Nyman U, Grubb A, Larsson A, Hansson LO, Flodin M, Nordin G, et al. The revised Lund-Malmö GFR estimating equation outperforms MDRD and CKD-EPI across GFR, age and BMI intervals in a large Swedish population. Clin Chem Lab Med CCLM [Internet]. 2014 Jan 1 [cited 2021 Jul 19];52(6). Available from: https://www.degruyter.com/document/doi/10.1515/cclm-2013-0741/html

22. Schelbert EB, Testa SM, Meier CG, Ceyrolles WJ, Levenson JE, Blair AJ, et al. Myocardial extravascular extracellular volume fraction measurement by gadolinium cardiovascular magnetic resonance in humans: slow infusion versus bolus. J Cardiovasc Magn Reson Off J Soc Cardiovasc Magn Reson. 2011 Mar 4;13:16.

23. Romero-Candeira S, Fernández C, Martín C, Sánchez-Paya J, Hernández L. Influence of diuretics on the concentration of proteins and other components of pleural transudates in patients with heart failure. Am J Med. 2001 Jun 15;110(9):681–6.

24. Ben-Horin S, Shinfeld A, Kachel E, Chetrit A, Livneh A. The composition of normal pericardial fluid and its implications for diagnosing pericardial effusions. Am J Med. 2005 Jun;118(6):636–40.

25. Ben-Horin S, Bank I, Shinfeld A, Kachel E, Guetta V, Livneh A. Diagnostic value of the biochemical composition of pericardial effusions in patients undergoing pericardiocentesis. Am J Cardiol. 2007 May 1;99(9):1294–7.

26. Imazio M, Biondo A, Ricci D, Boffini M, Pivetta E, Brucato A, et al. Contemporary biochemical analysis of normal pericardial fluid. Heart. 2020 Apr;106(7):541–4.

27. Messroghli DR, Moon JC, Ferreira VM, Grosse-Wortmann L, He T, Kellman P, et al. Clinical recommendations for cardiovascular magnetic resonance mapping of T1, T2, T2* and extracellular volume: A consensus statement by the Society for Cardiovascular Magnetic Resonance (SCMR) endorsed by the European Association for Cardiovascular Imaging (EACVI). J Cardiovasc Magn Reson [Internet]. 2017 Dec [cited 2018 Aug 22];19(1). Available from: https://jcmr-online.biomedcentral.com/articles/10.1186/s12968-017-0389-8

28. McKenna DA, Laxpati M, Colletti PM. The Prevalence of Incidental Findings at Cardiac MRI. Open Cardiovasc Med J. 2008 Apr 2;2:20–5.

29. Adler Y, Charron P, Imazio M, Badano L, Barón-Esquivias G, Bogaert J, et al. 2015 ESC Guidelines for the diagnosis and management of pericardial diseases. Eur Heart J. 2015 Nov 7;36(42):2921–64.

Author contributions

Simon Thalén designed the study, performed data acquisition, data analysis and wrote the manuscript. Andreas Sigfridsson supervised the technical aspects of data acquisition, Joao G Ramos, Henrik Engblom and Peder Sörensson participated in data acquisition and all authors substantially contributed to the interpretation of the results. Martin Ugander supervised the project.

Competing interests

The authors declare no competing interests.

Table 1. Baseline variables for healthy volunteers

Characteristic	
Reliably measurable T1, n/n (%)	26/30 (87)
Female sex, n/n (%)	12/26 (46)
Age, years	35 [46-65]
Height, cm	174±10
Weight, kg	71±12
Body mass index, kg/m^2	22±2
Body surface area, m^2	1.8±0.2
eGFR, ml/min/1.73m^2	95±15

Data are presented as numbers (n) and percent, mean±SD, or median [interquartile range].

Table 2. Means and normal reference ranges for characteristics of pericardial fluid

	mean	95% limits
Native T1, ms	3262	2943-3581
T1early, ms	2458	1882-3034
T1late, ms	1552	916-2188
ΔT1early, ms	804	245-1363
ΔT1late, ms	1710	1036-2384
ΔR1early, s^{-1}	0.11	0.01-0.20
ΔR1late, s^{-1}	0.37	0.08-0.66
ΔR1early/ΔR1late, unitless	0.30	0.10-0.50
[Gd]early, mmol/mL	20	2-39
[Gd]late, mmol/mL	70	15-126

Early values were imaged 6 minutes after contrast injection with and late values were imaged 26 minutes after contrast injection. The GBCA used was gadobutrol and the dose used 0.05 mmol/kg.

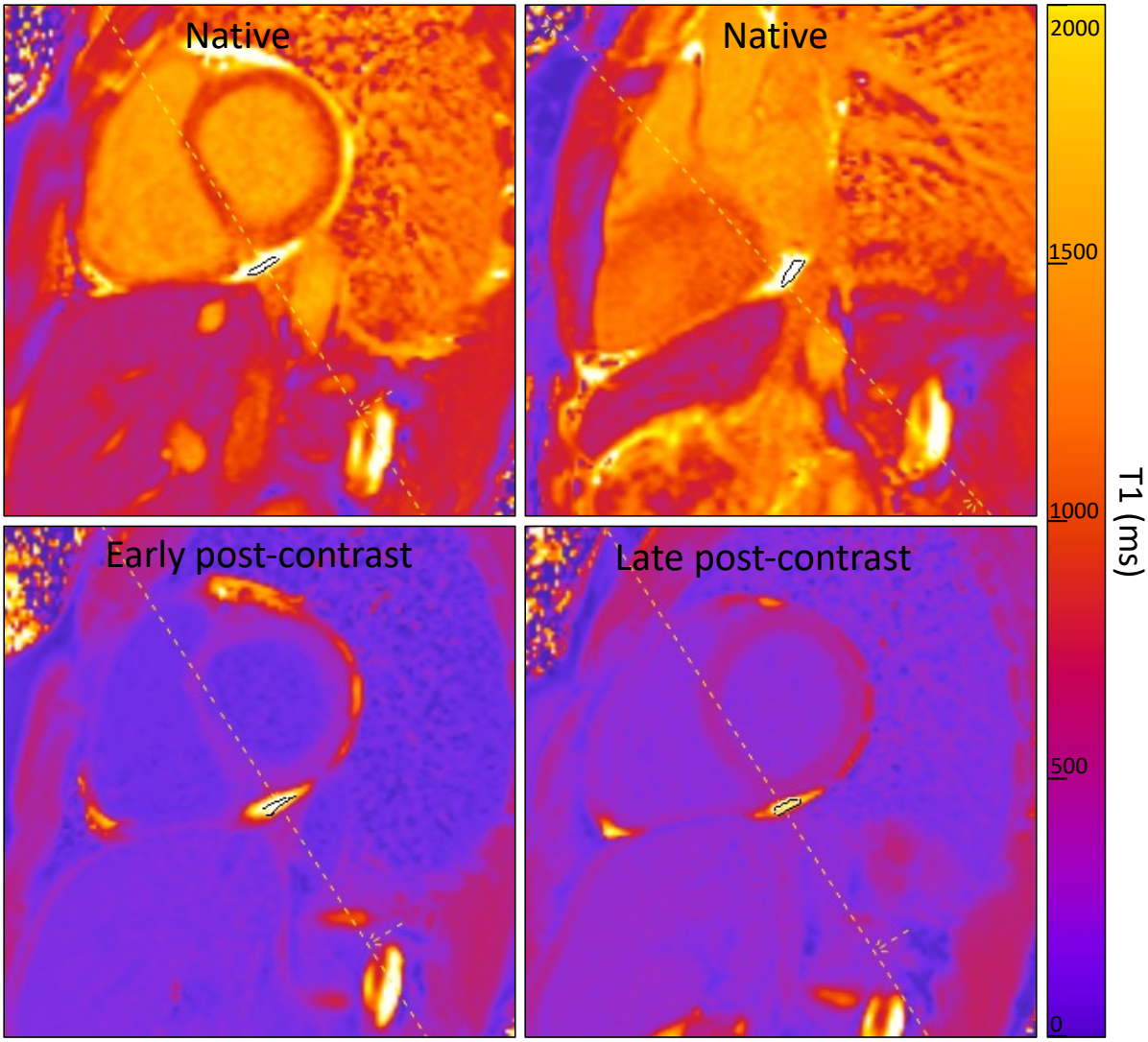

Figure 1. Example T1 maps taken before contrast administration in short axis (top left) and perpendicular (top right) slice orientation, and in short axis early post contrast (bottom left) and late post contrast (bottom right).

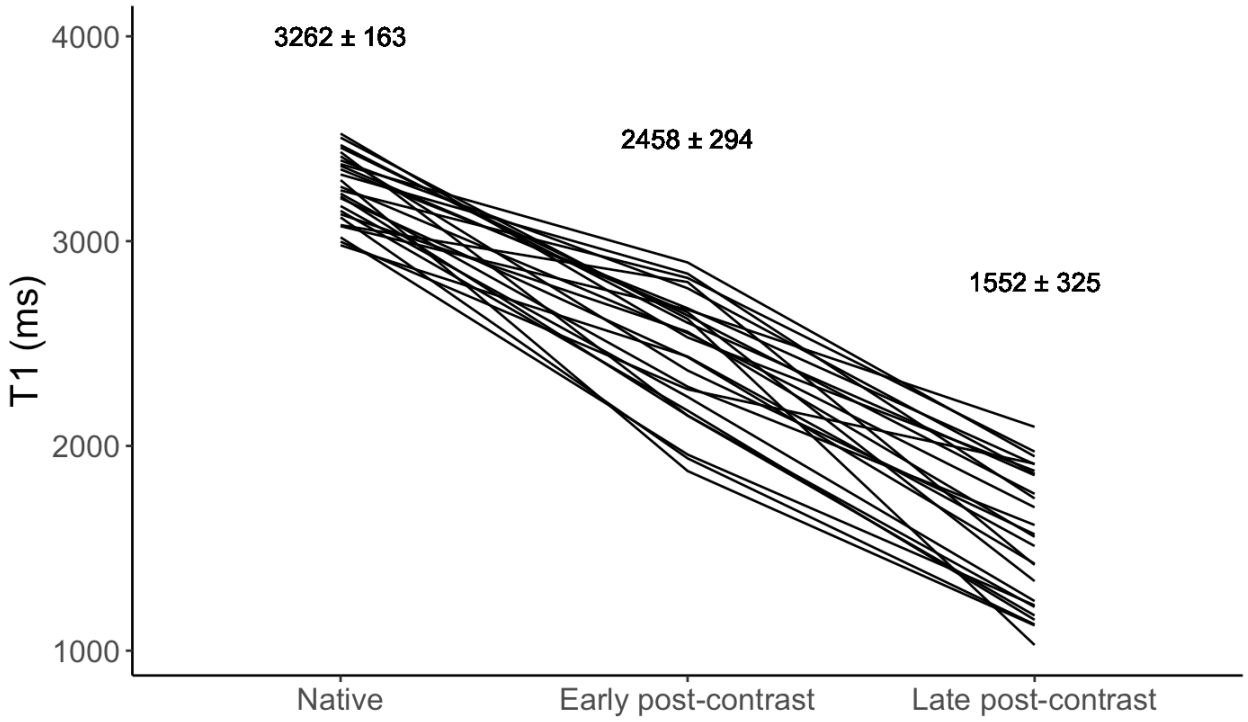

Figure 2. T1 measurements in a volume of pericardial fluid before, early and late after GBCA injection for each individual healthy volunteer. Mean and standard deviation is displayed at each timepoint. Note that all effusions had a reduction in T1 indicating contrast excretion.

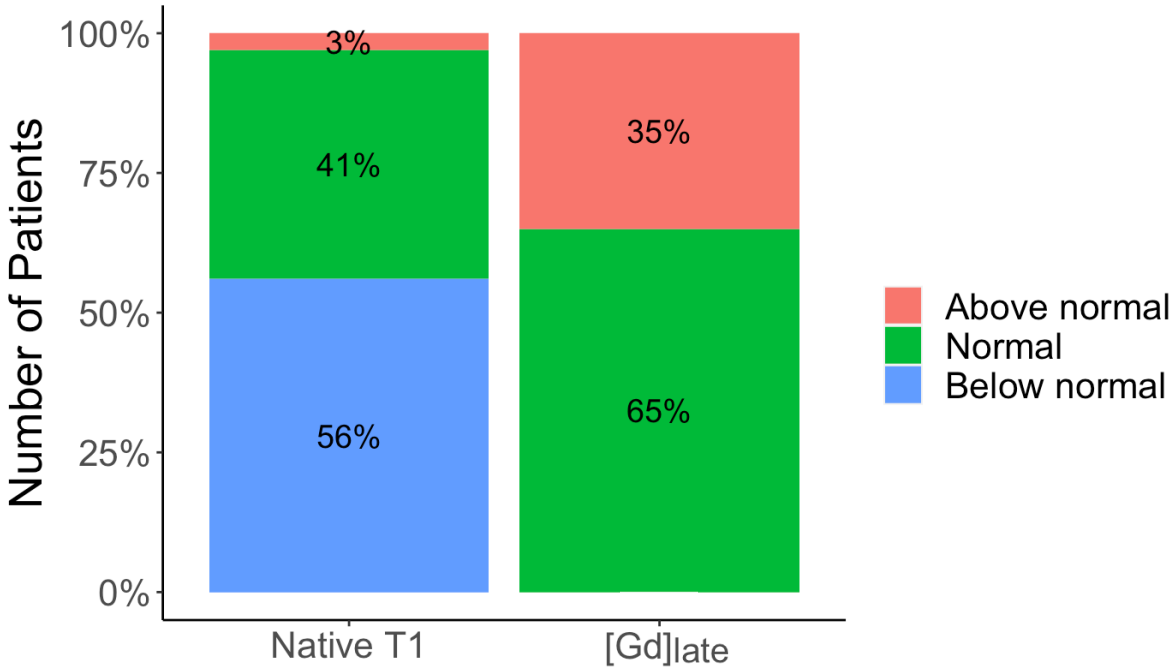

Figure 3. Stacked bar plots showing the percentage of clinical patients above, within and below the normal reference ranges determined from the healthy volunteers. No patients had a Gd[late] below the normal range.