Choroid plexus volume is enlarged in clinically isolated syndrome patients with optic neuritis.

Samuel Klistorner[1], **Anneke Van der Walt**[2], **Michael H Barnett**[3,4], **Helmut Butzkueven**[2], **Scott Kolbe**[2], **John Parratt**[5], **Con Yiannikas**[5], **Alexander Klistorner**[1,]

1. Save Sight Institute, Sydney Medical School, University of Sydney, Sydney, New South Wales, Australia,
2. Monash University, Melbourne, Victoria, Australia
3. Brain and Mind Centre, University of Sydney, Sydney, New South Wales, Australia,
4. Sydney Neuroimaging Analysis Centre, Camperdown, New South Wales, Australia,
5. Royal North Shore Hospital, Sydney, New South Wales, Australia,

Corresponding author: Alexander Klistorner. sasha@eye.usyd.edu.au

Keywords: choroid plexus, Clinically Isolated Syndrome (CIS), multiple sclerosis, optic neuritis

Abstract.

Objectives: People with Multiple Sclerosis (MS) have a larger choroid plexus (CP) volume than healthy controls. We investigated CP volume in early MS by quantitatively assessing brain MRI scans in patients presenting with optic neuritis (ON) as a clinically isolated syndrome (CIS), compared to a cohort with established Relapsing Remitting Multiple Sclerosis (RRMS) and healthy controls.
Methods: Pre- and post-gadolinium 3D-T1, 3D FLAIR and diffusion tensor images were acquired from 44 CIS ON patients at baseline, 1, 3, 6 and 12 months after the onset of ON. Fifty RRMS patients and 50 healthy controls were also included for comparison.
Results: ANOVA revealed significantly larger CP volumes in both ON CIS and RRMS groups compared to healthy controls ($p<0.001$ for both), but no difference between ON CIS and RRMS patients ($p=0.9$)

Twenty-three ON CIS patients who converted to CDMS during 10 years of follow-up

demonstrated CP volume similar to RRMS patients, but significantly larger compared to healthy controls ($p<0.001$). Increased CP volume was identified even in a sub-group of patients without MS-like lesions at baseline ($p<0.001$).

A significant (~6%) transient increase of CP volume was observed following a new bout of inflammation, which, however, returned to pre-inflammatory state few months later.

CP volume was not associated with the severity of acute inflammation of the optic nerve or long-term optic nerve axonal loss, not with brain lesion load or severity of tissue damage within lesions.

Interpretation: Our data demonstrate that enlarged CP can be observe very early in a disease, transiently reacts to acute inflammation, but not associated with the degree of tissue destruction.

Introduction.

The choroid plexus (CP), located within the brain's ventricular system, plays an important role in the implementation of the immune response within the central nervous system (CNS) (Mihaljevic et al. 2021). The CP is essential for the production of cerebrospinal fluid (CSF) (Hofman and Chen 2016); and critically determines brain homeostasis by regulating the entry of immune cells and specific molecules into the brain parenchyma. Specifically, the CP provides a gateway for antigen trafficking between the CSF and the vascular circulation (Vercellino et al. 2008) (Monaco et al. 2020) (Silva-Vargas et al. 2016). Therefore, in contrast to the blood-brain barrier (BBB) and the blood-leptomeningeal barrier (BLMB), the blood-CSF barrier (BCSFB) functions as a controlled gate for neuroimmune communication as well as immunosurveillance (Ayub, Jin, and Bae 2021)(Engelhardt, Wolburg-Buchholz, and Wolburg 2001).

Several recent reports have demonstrated that people with Multiple Sclerosis (MS) have a larger CP volume than healthy controls. Furthermore, the volume of the CP was linked to traditional measures of disease activity, including relapse rate and the number of enhancing lesions and expansion of chronic lesions (Fleischer et al. 2021) (V. A. Ricigliano et al. 2021) (Manouchehri and Stüve 2021) (S. Klistorner et al. 2022).

However, the temporal evolution of CP enlargement in MS is unknown. Therefore, to evaluate the CP volume in early MS, we quantitatively assessed brain MRI scans in patients presenting with optic neuritis (ON) as a clinically isolated syndrome (CIS), compared to a cohort with established Relapsing Remitting Multiple Sclerosis (RRMS) and age and gender matched healthy controls.

Methods.

The study was approved by University of Sydney and Macquarie University Human Research Ethics Committees and followed the tenets of the Declaration of Helsinki. Written informed consent was obtained from all participants.

Subjects

Data from forty-four patients who were enrolled in an ON study conducted at the Royal Victorian Ear and Eye Hospital, Melbourne 2008-2010 were retrospectively analysed. All patents presented with acute ON diagnosed by identical clinical criteria used in the Optic Neuritis Treatment Trial (ONSG 1991). Participants were tested at baseline (i.e. within 48 hours of presentation), 1, 3, 6 and 12 months after onset of ON.

For comparison, we included fifty consecutive patients with established RRMS, defined according to the revised McDonald 2010 criteria(Polman et al. 2011) (who are currently enrolled in the MADMS study) and 50 healthy controls. All groups had similar age and sex composition (see Table 1).

MRI protocol and analysis.

Participants were imaged using a Siemens 3T Trio MRI system with a 32-channel receiver head coil. Each scanning session included a spin-echo echo-planar imaging

diffusion-weighted imaging sequence (TR = 8200□ms; TE = 89□ms; voxel dimensions = 2.0 × 2.0 × 2.0□mm^3; GRAPPA parallel speed factor = 2; 10 non-diffusion-weighted volumes and 60 noncollinearly applied diffusion gradient-applied volumes with gradient *b*-value = 1200□s/mm^2; acquisition time = 9□m 59□s), a Pre (for baseline only)- and post-contrast (gadolinium) 3D T1-weighted volumetric sequence (TR = 1900□ms, TE = 2.63□ms, TI = 900□ms, flip angle = 9°, voxel dimensions = 0.8 × 0.8 × 0.8□mm^3, GRAPPA parallel speed factor = 2, and acquisition time = 5□m 25□s), and a 3D T2-weighted fluid-attenuated inversion recovery (FLAIR) sequence (TR = 5000□ms, TE = 436□ms, TI = 2100□ms, flip angle = 120°, voxel dimensions = 0.9 × 0.9 × 0.9□mm^3, GRAPPA parallel speed factor = 2, and acquisition time = 7□m 37□s). JIM 9 software (Xinapse Systems, Essex, UK) was used to segment individual lesions (using co-registered T2 FLAIR images).

To minimise eye movement during optic nerve scanning, subjects were instructed to perform a simple eye fixation task [18]. For lesion identification, each optic nerve was imaged using a 3D T2-weighted sequence (TR = 6000ms; TE = 403ms; TI = 2100ms; flip angle = 120°; ETL = 123; matrix size = 256 x 222; FOV = 256 x 222mm^2; slice thickness = 1mm). Optic nerve lesions were identified by a neurologist on coronal T2-DICOM images using Osirix Open Source Software [19] and verified by a blinded neuroradiologist (see examples in Fig 1A–1E). Lesion length was calculated as the square root of the sum of the square sagittal length and the square coronal length to correct for nerve tortuosity.

CP within the lateral ventricles was semi-automatically segmented on co-registered T1 images (Fig.1) using JIM 9 software (Xinapse Systems, Essex, UK) by a trained analyst (AK). The analyst, who was blinded to both clinical and lesion data, ensured that the correct contour was selected by the software and performed manual adjustments where needed. SienaX scaling was used to correct for inter-subject variability of head size.
The degree of tissue damage in chronic lesions was assessed by Mean Diffusivity (MD), as previously described (Castriota-scanderbeg et al. 2003) (A. Klistorner et al. 2018).

Optical Coherence Tomography (OCT)

OCT was performed using an OCT-3 scanner (Stratus™, software version 3.0, Carl ZeissMeditec Inc.) using the Fast RNFL protocol consisting of three circular 3.4 mm diameter scans centred on the optic disc. A signal strength of seven or more was deemed acceptable. RNFL thickness was measured at 12-months for the affected and unaffected eyes. The difference in RNFL thinning between affected and unaffected eyes was used to minimise inter-subject variability.

Multi-focal Visual Evoked Potentials (mfVEP)

The mfVEP was performed using the Accumap™ (ObjectiVision, software: Opera, Sydney, Australia) with a previously described testing procedure [7] that entailed recordings from 58 sectors of the visual field using four electrodes placed over the inion on the rear of the skull. Eyes were individually stimulated for 10 to 12 minutes until a sufficient signal to noise ratio (SNR) was reached. Mean latency was calculated per eye as a whole. The difference in mfVEP latency between affected and unaffected eyes was used to minimise inter-subject variability (A. Klistorner et al. 2008).

Results.

Demographic data is presented in Table 1. There were no significant differences in age or gender composition among the ON CIS, RRMS and healthy control cohorts.

	ON CIS patients	RRMS patients	Healthy controls
N	44	50	50
Age, years (Mean±SD)	33.9 ± 8.9	38.2 ± 9.3	36.0 ± 7.4
F/M ratio	2.3	2.1	2.3
Disease duration, years (Mean±SD)	-	5.4 ± 4.2	-
EDSS (median (range)	3 (0-4)	1 (0-4)	-
EDSS at 10 years follow-up (median (range))	0 (0-2)	-	
Brain lesion volume, mm^2 (Mean±SD)	1892 ± 4880	5769 ± 5229	-

<u>Comparison between ON CIS, clinically definite MS and healthy controls.</u>

There was a significant difference in CP volume between the three study groups ($p<0.001$, one-way ANOVA). Post-hoc analysis revealed significantly larger CP volumes in both ON CIS (2260 ± 534 mm^3) and RRMS (2240 ± 659mm^3) groups compared to healthy controls (1735 ± 338mm^3, $p<0.001$ for both). There was no difference in CP volume between ON CIS and RRMS patients ($p=0.9$) (Fig.1).

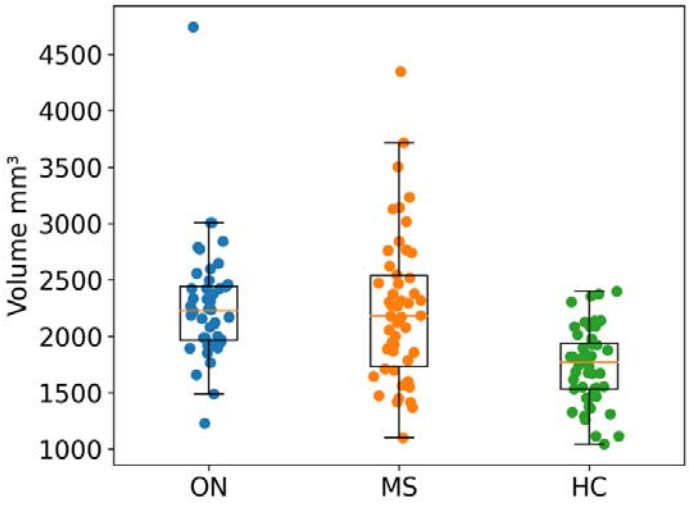

Twenty-three ON CIS patients converted to clinically definite (CDMS) within 10 years from the time of acute ON, while 21 ON CIS patients did not.

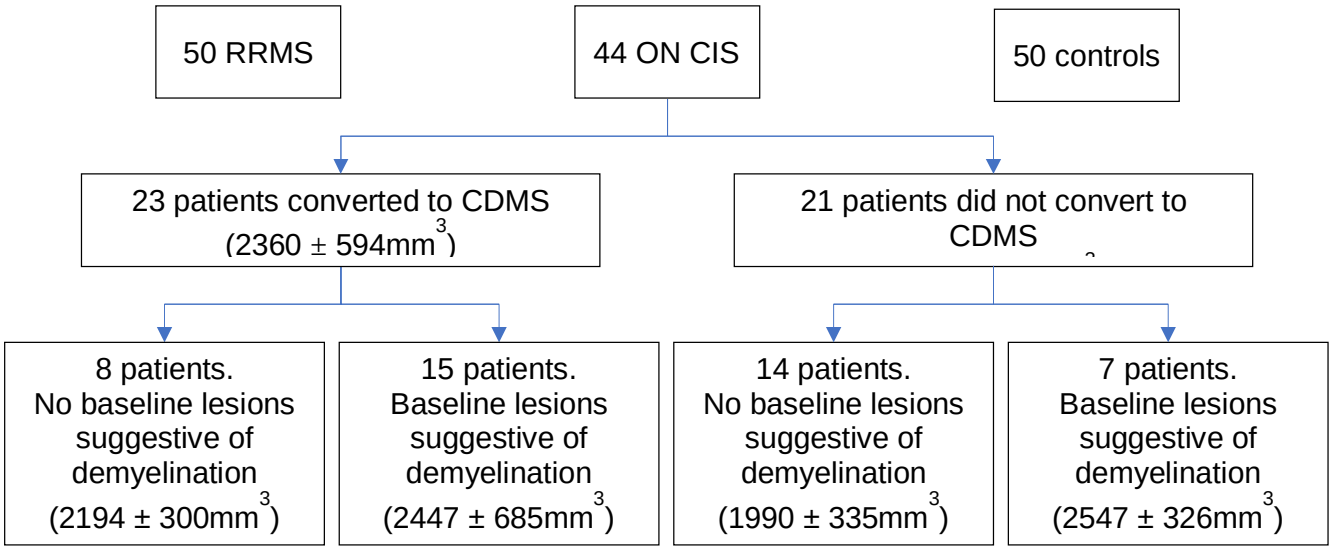

Choroid plexus volume is increased at the earliest stages of multiple sclerosis

Twenty-three ON CIS patients who converted to CDMS during 10 years follow-up demonstrated CP volume similar to RRMS patients, but significantly larger compared to healthy controls (2360 ± 594mm^3 vs 1735 ± 338mm^{3,} $p<0.001$).

Fifteen out of those 23 patients demonstrated brain lesions suggestive of demyelinating disease at the time of ON presentation (average lesion volume: 1892 ± 4880 mm3). In six of those patients at least one lesion was Gd-enhancing. Sub-analysis of CP in this group of 15 patients revealed significantly higher volume compared to healthy controls (2447 ± 685mm^3 vs 1735 ± 338mm^3, $p<0.001$).

Remaining 8/15 patients were lesion-free at the time of ON presentation, suggesting that acute ON was an initial MS event. Sub-analysis of CP in this group also revealed significantly larger volume compared to normal controls (2194 ± 300mm^3 vs 1735 ± 338mm^3, $p<0.001$).

In the 21/44 ON CIS patients who did not convert to CDMS during follow-up period, the CP was also significantly enlarged ($p<0.001$) compared to healthy controls. In this cohort, lesions suggestive of demyelination were observed on the baseline MRI in 7/21 patients. Compared to healthy controls, both patients with and without baseline brain demyelinating lesions demonstrated considerable enlargement of the CP (1990 ± 335mm^{3}vs 1735 ± 338mm^3, $p=0.02$ and 2547 ± 326mm^3 vs 1735 ± 338mm^3, $p<0.001$ respectively). CP enlargement, however, was significantly more pronounced in the latter group ($p=0.003$).

Further analysis was restricted to the 23 patients who converted to CDMS during the 10 years follow-up period.

Temporal evolution of choroid plexus enlargement in multiple sclerosis.

While difference in CP volume between patients with brain lesions suggestive of demyelinating disease and lesion-free patients was not significant, smaller CP volume in the latter group may imply a potential increase during initial stage of the disease.

Therefore, to assess the effect of disease stage on CP enlargement, we estimated CP volume at 1 month and 12 months post ON in patients who ultimately converted to CDMS

with no brain demyelinating lesions at baseline. There was no difference in CP volume between baseline and follow-up timepoints (average CP volumes 2194 ± 300mm^3, 2213 ± 314mm^3 and 2195± 330mm^3 respectively, ANOVA p>0.05).

To investigate the effect of new bouts of inflammation on plexus size we examined the change of plexus volume (as measured from previous timepoint) in a sub-group of ON CIS patients who demonstrated new lesion activity (i.e. new T2 lesions > 3 mm in diameter) during the initial 12 months follow-up period. Further, we selected only those patients who developed new lesions at 3, 6 or 12 months after onset of ON, but had no lesion activity in the preceding interval (i.e. between 1 and 3 months, 3-6 months or 6-12 months respectively). These criteria were satisfied in 14/23 patients (Fig. 3).

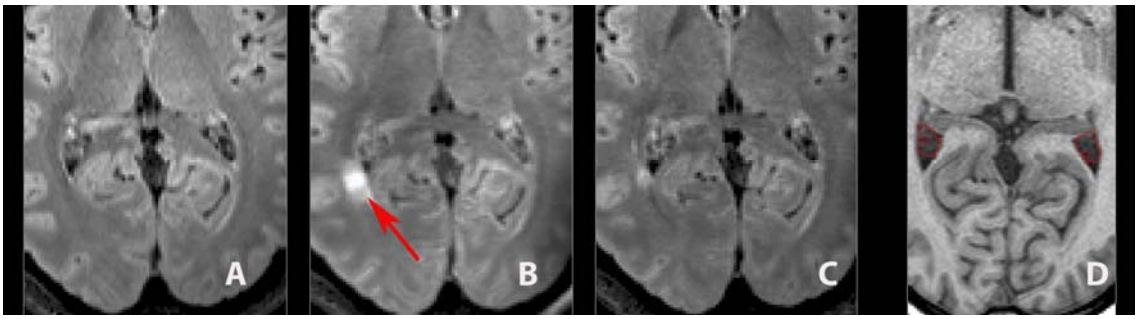

Fig. 3. Example of patient with new lesion at 3 months (arrow).

a. FLAIR image at 1 month (pre-lesion)
b. FLAIR image at 3 month (acute lesion)
c. FLAIR image at 6 month (post-lesion)
d. T1 image with plexus masking

A significant increase in CP volume was observed in patients with new lesion activity (2670+/-730 vs 2833+/- 756 respectively, p<0.001 paired ttest, representing an average increase of 6.3+/-3.9%). In 10/14 cases examined, new lesions occurred at 3 or 6 months, providing an opportunity to also examine changes in CP volume during the post-inflammatory period (i.e. at 6 or 12 months). While a significant increase of CP volume was observed within 2-3 months of new bout of inflammation evident on MRI at 3 or 6 months (2431+/-468 vs 2593+/-496 for pre-and inflammatory stages respectively, p<0.001, representing an increase of 6.7+/-4%), CP volume returned almost to its pre-inflammatory state at 6 or 12 months respectively (2477+/-477 vs 2431+/-468 for pre-and post-inflammatory stages respectively, p=0.1 or difference of 1.4+/-4%).

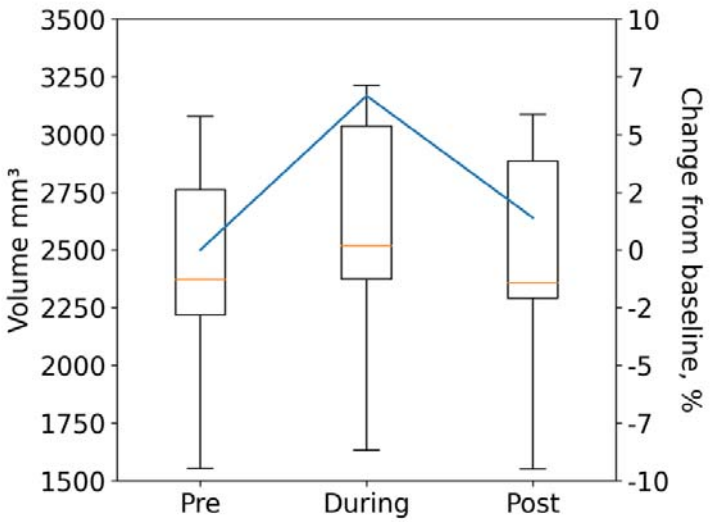

CP volume is not associated with the severity of acute inflammation of the optic nerve.

Measurement of the optic nerve lesion length during acute ON was performed in all 23 ON CIS patients who converted to CDMS. The average ON lesion length was 10.7 ± 5.8mm. Due to a high incidence of conduction block at the time of acute ON, analysable mfVEP waveforms were obtained only in 15/23 patients at the time of baseline MRI testing. Average mfVEP latency delay in the ON eye compared to the fellow eye was 11.4 ± 9.7 msec.

Both measures of acute inflammation (lesion length and mfVEP latency delay) demonstrated a wide spectrum of values (ON lesion length: 0-21.5 mm; inter-eye mfVEP latency asymmetry: 2-22 msec), indicating a variable degree of acute demyelination in the optic nerve. However, while these metrics were highly correlated with each other ($r=0.78$, $p<0.001$), neither were associated with CP volume.

CP volume is not associated with optic nerve axonal loss.

Measurement of RNFL thickness at 12 months post-acute ON was available 21/23 ON CIS patients who converted to CDMS; and revealed a marked loss of the RNFL in affected (ON) eyes compared to fellow eyes (inter-eye asymmetry 15.0 ± 11.2 microns), indicating considerable loss of RGC axons caused by optic nerve inflammation. No correlation was observed between baseline CP volume and relative RNFL loss in ON eyes.

CP volume and brain damage in ON CIS patients.

Analysis of the data from 23 ON CIS patients who converted to CDMS showed no association of CP volume with total brain T2 lesion volume, number of brain T2 lesions or average brain T2 lesion size.

Average (patient-wise) MD in the core of chronic lesions varied from values close to the MD typically observed in NAWM (0.87) to highly abnormal values (1.4), indicating broad spectrum of lesional tissue damage. However, there was no correlation between average MD in the core of chronic lesions and CP volume. Gadolinium enhancing lesions were excluded from diffusivity analysis to minimise the confounding effect of oedema related to acute inflammation.

Discussion.

The choroid plexus, a key gateway between the systemic circulation and the CNS, has recently attracted the attention of MS researchers. Indeed, several recent studies have identified a relationship between CP volume and the degree of acute and chronic inflammation in brain tissue.(Fleischer et al. 2021) (Manouchehri and Stüve 2021) (V. A. Ricigliano et al. 2021) (S. Klistorner et al. 2022). We recently reported that volume of CP predicts subsequent expansion of chronic periventricular MS lesions and is associated tissue damage within and outside of chronic lesions.

In the current study we examined the size of CP in a cohort of CIS patients presenting with acute ON; and investigated the relationship between CP volume and various measures of inflammatory demyelination and axonal loss both in the visual system and brain. Our principal finding was an increased CP volume in ON CIS patients, suggesting that the patho-mechanisms that underpin this phenomenon begin at the earliest stages of MS. Enlargement of the CP was also observed in a sub-group of patients who did not display brain lesions suggestive of demyelinating disease at the time of ON presentation, but later converted to CDMS. Since the absence of lesions compatible with demyelination suggests that ON may be the initial inflammatory event in this sub-group, our findings indicate that CP enlargement is likely to be relevant to the pathogenesis of the MS, or at least precede the diagnosis, even based on modern criteria that incorporates MRI. This is consistent with recently reported finding of enlarged CP in a cohort of RIS patients (V. A. Ricigliano et al. 2021) (V. Ricigliano, Louapre, and Poirion 2021). In another study that demonstrated enlargement of the CP, a significant proportion of participants was also represented by CIS patients (Fleischer et al. 2021).

We also observed a small, but significant, transient enlargement of the CP following new bouts of inflammation (as determined by newly appearing T2 brain lesions). Since new lesions appeared within 2-3 months preceding MRI examination, it is reasonable to assume that inflammation still remained active at the time of the MRI scanning following acute lesions, but is likely to subside by the next scan (3-6 months). This finding is in agreement with recently published experimental data describing transient enlargement of the CP in both cuprizone and experimental allergic encephalomyelitis (EAE) models of inflammatory demyelination (Fleischer et al. 2021). CP volume in our study also returned to its pre-inflammatory state within a few months, recapitulating the experimental data. Several potential explanations for transient CP enlargement, such as increased migration of immune and glial cells into the brain parenchyma, oxidative CP injury, increased permeability of CP epithelial cells or inflammation of the CP itself have been suggested (Fleischer et al. 2021) (Vercellino et al. 2008) (Rodríguez-Lorenzo et al. 2020).

A marked reduction in neuro-inflammation may explain (at least to some extent) the recent observation that pharmacological modulation of the blood-CSF barrier by natalizumab, an efficacious anti-inflammatory therapy(Samjoo et al. 2021), appears to prevent CP enlargement, compared to untreated patients and patients receiving dimethyl fumarate (Fleischer et al. 2021).

However, the mechanisms underlying structural changes that lead to permanently increased CP volume in early MS remain largely unknown. Intriguingly, enlargement of the CP has also been reported in other neurological conditions including stroke(Egorova et al. 2019), psychosis(Lizano et al. 2019), schizophrenia(Y. F. Zhou et al. 2020), depression(Althubaity et al. 2022), Alzheimer disease(Choi et al. 2022) and complex regional pain syndrome(G. Zhou et al. 2015). Therefore, enlargement of the CP is not MS-specific, but instead is likely to be associated with general increase of neuroinflammation

(Althubaity et al. 2022) (Choi et al. 2022). Indeed, functional dysregulation of the CP may reflect a common underlying mechanism in the pathophysiology of the chronic stage of neurodegenerative diseases (Schwartz and Cahalon 2022).

Furthermore, it has been suggested that enlargement of the CP may occur before the development of pathological changes in the CNS and may even reflect an inherited or acquired susceptibility to neuroinflammation(Egorova et al. 2019) (Althubaity et al. 2022) (Y. F. Zhou et al. 2020). For example, enlargement of the CP has been reported in stroke patients in the early, post-acute period. CP enlargement did not respect stroke laterality and remained stable during 12 months of follow-up, prompting the authors to raise the possibility that this phenomenon predated the stroke and may be "associated with increased vascular burden and neuroinflammation, which may also increase the likelihood of stroke" (Egorova et al. 2019). In patients with recently diagnosed schizophrenia, significantly larger CP volumes, compared with healthy controls, were observed, leading the authors to speculate that "it is possible that this (CP enlargement) may occur prior to the first episode of schizophrenia" or even be related to abnormal adult neurogenesis (Y. F. Zhou et al. 2020). Moreover, a similar study of patients with psychosis not only demonstrated increased CP volume across the spectrum of the disease, but also reported significant heritability of this observation by examining first-degree relatives(Lizano et al. 2019).

This finding of early CP enlargement in other neurological conditions is in line with our observation that CP volume is increased even at the time of a very first MS attack. A smaller CP volume, albeit still increased compared with healthy controls, in CDMS patients without baseline lesions compared to patients with demyelinating brain lesions at baseline (i.e. patients likely to have a longer disease duration) implies that CP enlargement occurs at the initial stages of the disease and subsequently plateaus. While the stability of our longitudinal data of CP volume within first 12 months of post-ON does not support this scenario, our sample size is limited and this observation cannot be generalised.

CP volume in ON CIS patients was not associated with severity of acute inflammation of the optic nerve, as measured by MRI-defined lesion length and extent of acute demyelination determined by latency delay of the mfVEP. There was also no relationship between CP size and axonal loss resulting from optic neuritis (as measured by relative thinning of RNFL). Likewise, CP volume was not related to volumetric characteristics of brain lesions or the degree of lesional damage measured by tissue rarefication (MD) (caution, however, must be taken in interpreting this finding since starting point of the diseae may precede first clinical attack by several year). Analogously, similar lack of relationship between lesion size and volumes of CP has recently been reported in stroke patients (Egorova et al. 2019).

Although patients who did not convert to CDMS in our study also demonstrated increased CP volume, this was primarily driven by the subjects with demyelinating brain lesions on baseline imaging, a cohort that remains at high risk of developing MS even 10 years after acute optic neuritis (ONSG 2008). Our observation may therefore reflect the mixed (MS vs non-MS) nature of the non-converter group.

Our study has several limitations. The sample size, particularly for sub-analyses of patients with and without baseline brain lesions, was small and potentially impacts the robustness of our conclusions. Since the source data for our study was collected more than 10 years ago, a first generation OCT device was used to analyse RNFL thickness. However, the effect of ON on axonal loss of reginal ganglion cells is profound and the accuracy of time-domain OCT therefore sufficient for this purpose. To further reduce variability of measurement, relative inter-eye asymmetry, rather than absolute RNFL thickness, was used.

Conclusion.

The CP is enlarged in ON CIS patients, even when ON is the only discernible MS pathology on MRI. In addition, there is transient enlargement of the CP in association with appearance on new brain lesions. Similar to other neurodegenerative diseases, it remains to be seen as to whether enlargement of the CP is a cause or an effect of CNS neuroinflammation(Gião et al. 2022) (Choi et al. 2022) (Y. F. Zhou et al. 2020).

Althubaity, Noha et al. 2022. “Choroid Plexus Enlargement Is Associated with Neuroinflammation and Reduction of Blood Brain Barrier Permeability in Depression.” *NeuroImage: Clinical* 33. http://creativecommons.org/licenses/by/4.0/ (April 10, 2022).

Ayub, Maria, Hee Kyung Jin, and Jae sung Bae. 2021. “The Blood Cerebrospinal Fluid Barrier Orchestrates Immunosurveillance, Immunoprotection, and Immunopathology in the Central Nervous System.” *BMB Reports* 54(4): 196–202.

Castriota-scanderbeg, Alessandro et al. 2003. “Coefficient Dav Is More Sensitive Than Fractional Anisotropy in Monitoring Progression of Irreversible Tissue Damage in Focal Nonactive Multiple Sclerosis Lesions.” *AJNR Am J Neuroradiol* 24(April): 663–70.

Choi, Jong Duck et al. 2022. “Choroid Plexus Volume and Permeability at Brain MRI within the Alzheimer Disease Clinical Spectrum.” *Radiology* (9).

Egorova, Natalia et al. 2019. “Choroid Plexus Volume after Stroke.” *International Journal of Stroke* 14(9): 923–30.

Engelhardt, Britta, Karen Wolburg-Buchholz, and Hartwig Wolburg. 2001. “Involvement of the Choroid Plexus in Central Nervous System Inflammation.” *Microscopy Research and Technique* 52(1): 112–29.

Fleischer, Vinzenz et al. 2021. “Translational Value of Choroid Plexus Imaging for Tracking Neuroinflammation in Mice and Humans.” *Proceedings of the National Academy of Sciences of the United States of America* 118(36): 1–12.

Gião, Tiago, Tiago Teixeira, Maria Rosário Almeida, and Isabel Cardoso. 2022. “Choroid Plexus in Alzheimer’s Disease—The Current State of Knowledge.” *Biomedicines* 10(2).

Hofman, Florence M, and Thomas C Chen. 2016. “Choroid Plexus: Structure and Function.” In *THE CHOROID PLEXUS AND CEREBROSPINAL FLUID*, eds. Josh Neman and Thomas C Chen. Amsterdam: Elsevier Inc., 29–40.

Klistorner, A. et al. 2008. “Axonal Loss and Myelin in Early ON Loss in Postacute Optic Neuritis.” *Ann Neurol* 64(3): 325–31. http://www.ncbi.nlm.nih.gov/pubmed/18825673.

———. 2018. “Evidence of Progressive Tissue Loss in the Core of Chronic MS Lesions: A Longitudinal DTI Study.” *NeuroImage: Clinical* 17: 1028–35.

Klistorner, Samuel et al. 2022. “Choroid Plexus Volume Predicts Expansion of Chronic Lesions and Associated Brain Atrophy in Multiple Sclerosis.” *Annals of Clinical and Translational Neurology* ccepted.

Lizano, Paulo et al. 2019. “Association of Choroid Plexus Enlargement with Cognitive, Inflammatory, and Structural Phenotypes across the Psychosis Spectrum.” *American Journal of Psychiatry* 176(7): 564–72.

Manouchehri, Navid, and Olaf Stüve. 2021. “Choroid Plexus Volumetrics and Brain Inflammation in Multiple Sclerosis.” *Proceedings of the National Academy of Sciences*

of the United States of America 118(40): 10–12.
Mihaljevic, Sandra, Alena Michalicova, Mangesh Bhide, and Andrej Kovac. 2021. "Pathophysiology of the Choroid Plexus in Brain Diseases." *Gen. Physiol. Biophys.* 40: 443–62.
Monaco, Salvatore, Richard Nicholas, Richard Reynolds, and Roberta Magliozzi. 2020. "Intrathecal Inflammation in Progressive Multiple Sclerosis." *International Journal of Molecular Sciences* 21(21): 1–11.
ONSG. 1991. "The Clinical Profile of Optic Neuritis: Experience of the Optic Neuritis Treatment Trial." *Arch Ophthalmol* 109: 1673–78.
———. 2008. "Multiple Sclerosis Risk after Optic Neuritis: Final Optic Neuritis Treatment Trial Follow-Up." *Arch neurol* 65: 727–32.
Polman, Chris H et al. 2011. "Diagnostic Criteria for Multiple Sclerosis: 2010 Revisions to the McDonald Criteria." *Annals of neurology* 69(2): 292–302. http://www.pubmedcentral.nih.gov/articlerender.fcgi?artid=3084507&tool=pmcentrez&rendertype=abstract (July 10, 2014).
Ricigliano, VAG, Céline Louapre, and Émilie Poirion. 2021. "An Imaging Signature in Choroid Plexuses in Pre-Symptomatic Multiple Sclerosis." *Presented at Annual Meeting of the European Charcot Foundation* Poster.
Ricigliano, Vito AG et al. 2021. "Choroid Plexus Enlargement in Inflammatory Multiple Sclerosis." *Radiology* 301: 166–77.
Rodríguez-Lorenzo, Sabela et al. 2020. "Inflammation of the Choroid Plexus in Progressive Multiple Sclerosis: Accumulation of Granulocytes and T Cells." *Acta Neuropathologica Communications* 8(1): 1–13.
Samjoo, Imtiaz A. et al. 2021. "Efficacy Classification of Modern Therapies in Multiple Sclerosis." *Journal of Comparative Effectiveness Research* 10(6): 495–507.
Schwartz, Michal, and Liora Cahalon. 2022. "The Vicious Cycle Governing the Brain–Immune System Relationship in Neurodegenerative Diseases." *Current Opinion in Immunology* 76: 102182. https://doi.org/10.1016/j.coi.2022.102182.
Silva-Vargas, Violeta et al. 2016. "Age-Dependent Niche Signals from the Choroid Plexus Regulate Adult Neural Stem Cells." *Cell Stem Cell* 19(5): 643–52. http://dx.doi.org/10.1016/j.stem.2016.06.013.
Vercellino, Marco et al. 2008. "Involvement of the Choroid Plexus in Multiple Sclerosis Autoimmune Inflammation: A Neuropathological Study." *Journal of Neuroimmunology* 199(1–2): 133–41.
Zhou, Guangyu et al. 2015. "Enlargement of Choroid Plexus in Complex Regional Pain Syndrome." *Scientific Reports* 5: 1–5. http://dx.doi.org/10.1038/srep14329.
Zhou, Yan Fang et al. 2020. "Choroid Plexus Enlargement and Allostatic Load in Schizophrenia." *Schizophrenia Bulletin* 46(3): 722–31.