

1 **Systemic inflammatory syndromes as life-threatening side effects of immune**
2 **checkpoint inhibitors: Systematic review of the literature**

3
4 Lisa L. Liu^{1,2,#}, Marcus Skribek^{1,2}, Ulrika Harmenberg^{1,2}, Marco Gerling^{1,3,#}

5
6 ¹Theme Cancer, Karolinska University Hospital, 17176 Solna, Sweden

7 ²Department of Oncology-Pathology, Karolinska Institutet, 17176 Solna, Sweden

8 ³Department of Bioscience and Nutrition, Karolinska Institutet, 14183 Huddinge, Sweden

9
10 # Corresponding authors:

11 Lisa L. Liu Burström, MD, PhD, email: lisa.liu@ki.se

12 Marco Gerling, Dr. med, email: marco.gerling@ki.se

13
14 **Abstract**

15 Immune checkpoint inhibitors (ICIs) are associated with a wide range of immune-related
16 adverse events (irAEs). As oncological indications for ICIs widen, their rare side effects
17 become increasingly visible in clinical practice and impact therapy decisions.

18 Here, we provide a systematic review of the literature of CRS and related life-
19 threatening side effects of ICI treatment, such as hemophagocytic lymphohistiocytosis
20 (HLH). We searched Medline, Embase, and the Web of Science Core Collection from
21 inception until October 2021 for reports on CRS, cytokine storm, macrophage activation
22 syndrome, HLH, and related hyperinflammatory disorders in patients with solid cancers
23 receiving ICIs. We found $n = 1866$ articles, which were assessed for eligibility independently
24 by two examiners. Of those, $n = 49$ articles reporting on $n = 189$ individuals were eligible for
25 review. We found that the median time from last infusion to the occurrence of CRS/HLH was
26 approximately nine days, while the onset of symptoms varied from immediately after
27 infusion to one month after treatment. Most patients were treated with either corticosteroids
28 or the anti-interleukin 6 (IL-6) antibody tocilizumab, and although the majority of patients
29 recovered, a few cases were fatal. Concomitant IL-6 and ICI treatment was reported as
30 beneficial for both the antitumoral effect and for limiting side effects. Data from international
31 pharmacovigilance databases underscored that ICI-related CRS and HLH are rare events, but
32 we identified significant differences in reported frequencies, which might suggest substantial
33 underreporting.

34 The results from this first systematic review of CRS/HLH due to ICI therapy highlight
35 that life-threatening systemic inflammatory complications of ICIs are rare and non-fatal in the
36 majority of patients. Limited data support the use of IL-6 inhibitors in combination with ICIs
37 to augment the antitumoral effect and reduce hyperinflammation.

43

44 **Introduction**

45 Immune checkpoint inhibitors (ICIs) have become important therapeutic options for various
46 tumor types. ICIs are associated with specific toxicities, commonly referred to as immune-
47 related adverse events (irAEs), which can lead to treatment interruption or discontinuation.
48 International guidelines aid clinicians in the diagnosis and management of relatively common
49 irAEs, such as skin rashes, colitis, thyroiditis, and pneumonitis^{1,2}. However, the increasing
50 volume of patients treated with ICIs is starting to reveal less common side effects, including
51 systemic hyperinflammatory syndromes. Nonspecific systemic inflammatory reactions to
52 ICIs, such as self-limiting fever or skin rashes during or shortly after infusion², need to be
53 distinguished from severe, persistent, and potentially life-threatening conditions such as
54 cytokine release syndrome (CRS) and hemophagocytic lymphohistiocytosis
55 (HLH)/macrophage-activation syndrome (MAS)³. Due to their severity, these irAEs are of
56 particular clinical importance and require a decision on continuation of ICI treatment, for
57 which evidence is lacking. Because of their rarity, hyperinflammatory syndrome are
58 incompletely captured in randomized clinical trials with ICIs^{4,5}, and not yet discussed in
59 irAE guidelines^{1,2}. Hence, real-world data and case reports of rare irAEs are needed to
60 understand their frequency and severity, and to improve clinical management.

61 In cancer therapy, CRS is best understood in the context of chimeric antigen receptor
62 (CAR) T cell therapies, where it occurs in a substantial proportion of patients at different
63 levels of severity⁶. CRS is believed to be mainly driven by T cell-derived interferon gamma
64 (IFN- γ), which stimulates macrophages to produce various pro-inflammatory substances
65 including interleukin 6 (IL-6) and tumor necrosis factor alpha (TNF- α)⁷. Therapeutically, IL-
66 6 inhibition with specific anti-IL-6 receptor antibodies, such as tocilizumab, has proven
67 highly effective against CRS, reflected by the US Federal Drug Agency's approval of
68 tocilizumab for CAR T cell-induced CRS⁸. This is important because IL-6 inhibition could
69 allow for the continuation of any treatment associated with mild CRS⁹.

70 HLH is an umbrella term for life-threatening hyperinflammatory conditions with
71 supramaximal activation of the immune system. For the diagnosis of HLH, the HLH-2004
72 diagnostic criteria are frequently used, although they were developed for the pediatric
73 population³. The criteria include clinical features such as fever and splenomegaly, as well as
74 laboratory findings such as cytopenias, hypertriglyceridemia, hyperferritinemia, evidence of
75 hemophagocytosis, and the absence of natural killer (NK) cell activity³. More recently, the

76 HScore, which includes similar criteria to HLH-2004, was developed to estimate the
77 probability for reactive HLH in adults with inflammatory syndromes¹⁰. Genetic analyses
78 from pediatric patients have revealed a wide variety of predisposing variants that presumably
79 play a role for different immune cell types, suggesting that HLH-related conditions represent
80 a complex disease continuum¹¹.

81 Reports on hyperinflammatory syndromes due to ICI treatment have started to emerge
82 during recent years, and have suggested that these are relatively rare, but potentially life-
83 threatening events¹². Both HLH and CRS can be fatal by causing hypotension, capillary leak
84 syndrome, and consequently organ dysfunction⁷. Because of the potential risk of increasing
85 the severity of CRS/HLH upon repeated exposure to a particular trigger, suspicion of these
86 hyperinflammatory syndromes in clinical practice most often leads to treatment cessation.
87 Hence, a better understanding of this complex disease spectrum in the context of ICI
88 treatment is needed to guide decision-making on treatment continuation and optimal
89 management.

90 To set the stage for a more evidence-based approach to CRS, we conducted a
91 systematic review of the literature, in which we identify $n = 49$ articles on $n = 189$ patients
92 with hyperinflammatory syndromes due to ICIs. The results reveal that most patients with
93 CRS/HLH recover and that a fatal outcome is rare. In addition, the literature reveals that
94 corticosteroids and IL-6 inhibition may provide effective therapies. Extrapolating from
95 preclinical data, which we review in brief, we posit that rechallenging with ICIs after
96 CRS/HLH has been controlled should be considered at least in patients with mild
97 hyperinflammatory ICI side effects who are expected to benefit from ICI treatment. Recent
98 data suggest that ICIs in combination with IL-6 antagonists may boost the antitumoral effect,
99 while simultaneously protecting from severe irAEs, which makes ICIs in combination with
100 IL-6 inhibition an attractive option for rechallenge that warrants further research.

101

102 **Methods**

103

104 **Systematic review**

105 We performed a systematic search for published reports on CRS, HLH and related
106 hyperinflammatory diseases in MEDLINE, Embase, and the Web of Science databases as of
107 October 2021. The search strategies were designed in collaboration with the Karolinska

108 Institute library and are included as **Supplementary Figure 1**. Deduplication was performed
109 as previously described¹³.

110 Additional manual searches were performed based on the lists of references in the
111 eligible studies, and a reduced set of keywords in the MEDLINE database only, as of June
112 13th 2022. Inclusion criteria for abstract review were assessed independently by two
113 reviewers (LLL and MG) and defined as follows: (1) report on any hyperinflammatory
114 syndrome (CRS, HLH, MAS, or any indication of these or related systemic syndromes) on
115 human patients with solid tumors, (2) reported use of any ICI at any time of the treatment, (3)
116 case series or case reports, i.e. no randomized-controlled trial (RCT), unless explicitly stated
117 that CRS/HLH/MAS or any other hyperinflammatory syndrome was reported, (4) articles in
118 English, Swedish, Chinese or German. LLL and MG agreed on article inclusion by discussing
119 the articles for which the initial decision on inclusion differed. For all eligible articles, the
120 full-text was downloaded by LLL or MG. Data were extracted by either LLL, MS, or MG,
121 and all authors convened to agree on final inclusion. As the majority of the included studies
122 were case reports on rare events, no further criteria for study quality assessment were applied
123 and the risk for bias was not assessed. The systematic review was not preregistered.

124

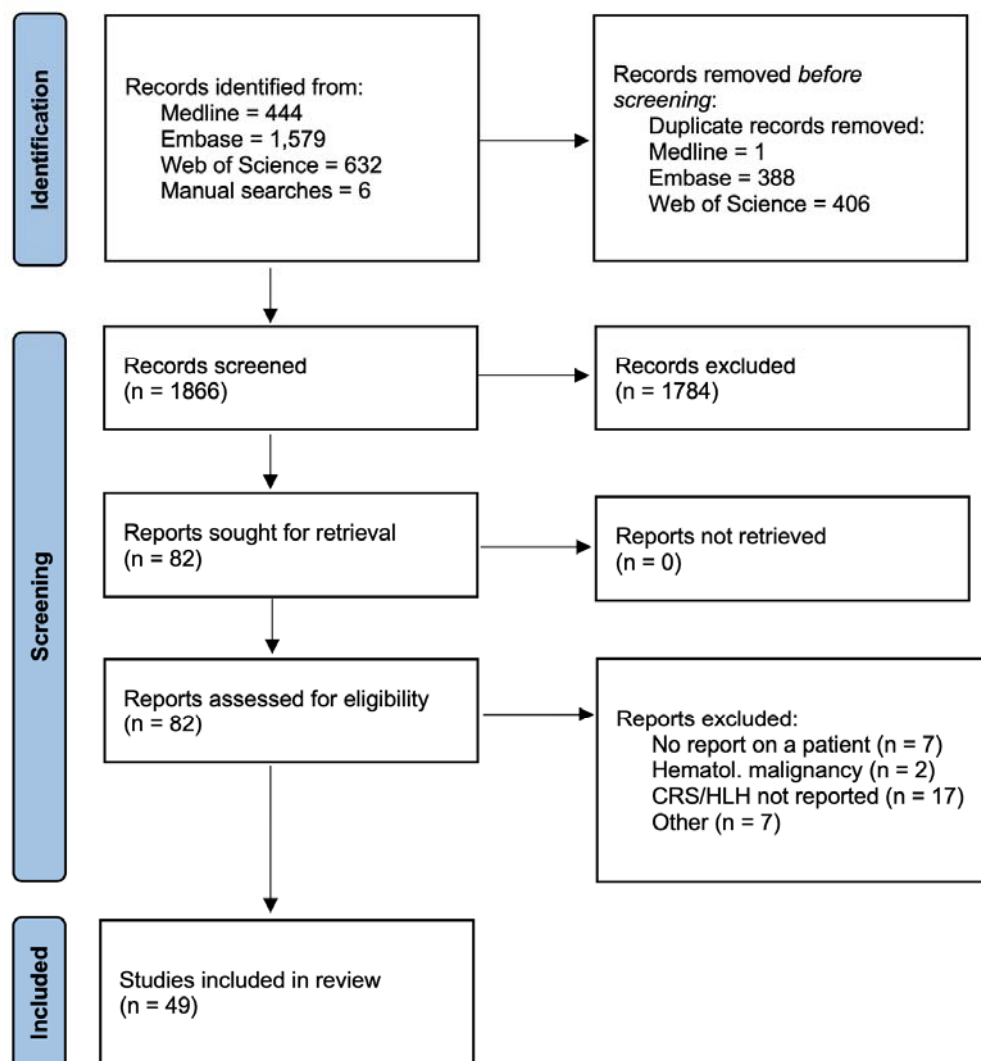
125 **Results**

126

127 **Systematic review**

128 To chart our current knowledge of hyperinflammatory syndromes, such as CRS and HLH, as
129 rare side effects of treatment with ICIs, we conducted a systematic review of the literature
130 housed in the major medical databases as of October 2021. In addition, we manually updated
131 the list of eligible studies as of 13th June 2022. **Supplementary Figure 2** presents the
132 PRISMA reporting chart for the study.

133



134
135

Supplementary Figure 2: PRISMA 2020 flow diagram of the study.

136

137 We identified a total of $n = 49$ articles, reporting on $n = 189$ patients treated in the
138 USA, the UK, Switzerland, Spain, Poland, Lebanon, Japan, Israel, Germany, France, China,
139 Canada, Australia, and Singapore (**Table 1**). Of these studies, $n = 45$ reports were on $n < 5$
140 individual patients (comprising a total of $n = 56$ individuals), while $n = 4$ studies reported
141 case series or data from queries of pharmacovigilance databases (**Table 1**). Definitions of
142 CRS/HLH varied significantly between reports, and retrospective diagnostic assessment was
143 not possible due to partially incomplete and heterogeneous clinical data. Therefore, we used
144 the respective authors' assessment of the hyperinflammatory condition as CRS, HLH, or
145 related hyperinflammatory diseases for further analysis. The earliest published report was
146 from 2016¹².

147 The ICIs used included pembrolizumab ($n = 21$ studies) and nivolumab ($n = 11$
148 studies) as single agents, combined treatment with ipilimumab and nivolumab ($n = 13$), and,
149 less frequently ($n = 2$ studies each), ipilimumab, sintilimab or atezolizumab monotherapy,
150 and cemiplimab ($n = 1$). Often, ICIs were combined either with chemotherapeutic agents or
151 other anticancer drugs, such as TKIs (i.e. cabozantinib or dabrafenib/trametinib), or drugs
152 that were used prior to development of the hyperinflammatory syndrome(s).

153 In the individual reports, $n = 15$ patients were diagnosed with CRS, $n = 34$ with HLH,
154 and $n = 6$ were described as having related hyperinflammatory conditions such as capillary
155 leak syndrome with high fever, or systemic inflammatory response syndrome (SIRS). The
156 most frequently reported underlying malignancies in individual case reports were malignant
157 melanoma ($n = 21$ individual reports) and lung cancer ($n = 14$ individual reports). The
158 average age of the patients in the individual reports was 59 years. In individual reports that
159 reported the patients' sex, $n = 35$ patients were males, and $n = 20$ patients were females. The
160 highest frequencies of male patients were also reported in the largest case series from two
161 centers in Singapore¹⁴ ($n = 18$ males, $n = 7$ females), and in a World Health Organization
162 (WHO) pharmacovigilance database queried for HLH¹⁵ ($n = 29$ males, $n = 9$ females) and
163 CRS, respectively¹⁶ ($n = 34$ males, $n = 21$ females). Most studies ($n = 46$ studies out of 49)
164 comprised data on patients with metastatic disease (**Table 1**). Time from ICI infusion to onset
165 of symptoms varied from hours to one month, with a median of $n = 9$ days. In total, $n = 42$
166 studies on $n = 56$ individual patients (75%) reported recovery from ICI-induced irAEs, while
167 $n = 5$ cases (out of 56, corresponding to 8.9%) were fatal. Of those, $n = 3$ cases were reported
168 to have HLH, and $n = 2$ had CRS, as per the authors' assessment. Overall, $n = 42$ patients
169 from individual reports were reported to have recovered from their hyperinflammatory

170 complications. Reports from pharmacovigilance data were incomplete for outcome data; a
171 study including $n = 25$ patients from Singapore reported $n = 3$ fatal cases (0.12 %).

172 Treatments for CRS/HLH varied significantly, and included different types of
173 corticosteroids in almost all cases, and tocilizumab in $n = 14$ cases. Various other drugs were
174 used in some patients, including etoposide in combination with dexamethasone, an
175 established HLH treatment^{17,18}, as well as intravenous immunoglobulins, plasmapheresis,
176 mycophenolate mofetil, and tacrolimus. Often, these were combined, at least initially, with
177 antibiotic therapy because of suspected sepsis (**Table 1**).

178

179 Table 1: Studies retrieved in systematic review

<u>Authors¹⁴</u> <u>Publication</u> <u>Year</u> <u>Country</u>	<u>Study title</u>	<u>Type of malignancy</u>	<u>No. of patients with CRS</u>	<u>Age & Sex</u>	<u>Tumor burden (stage)</u>	<u>Antibody used</u>	<u>Additional therapy</u>	<u>Main complication (CRS, HLH, other, as assessed by the authors)</u>	<u>Cycle of ICI treatment prior to CRS/HLH</u>	<u>Time from infusion to symptoms (in days)</u>	<u>Main symptoms</u>	<u>Intervention (steroids, IL-6, other)</u>	<u>CRS/HLH-specific outcome after intervention</u>	<u>Rechallenge ICI</u>	<u>Tumor-specific outcome</u>	<u>Comments</u>
Sharma et al. ¹² 2016 USA	Systemic inflammatory response syndrome (SIRS) with immune checkpoint inhibitors.	*Progressive lung cancer*	12		N/A	Nivolumab		SIRS	Unclear		*One or more of the following - fever, tachypnea, tachycardia, hypotension, organ failure occurring 1-2 days to weeks after immunotherapy.*	Steroids, tocilizumab	Unclear	Unclear	Unclear	Presented as poster; no detailed description of individual cases in published abstract.
El Rassy et al. ¹⁹ 2017 Lebanon	Diffuse edema suggestive of cytokine release syndrome in a metastatic lung carcinoma patient treated with pembrolizumab	Lung squamous cell carcinoma	1	62 M	Metastatic (stage IV)	Pembrolizumab		CRS	7	1	*Fatigue, persistent low-grade fever and an acute onset of diffuse swelling involving [...] limbs and abdomen. [...] pain sensation on exertion in both hands and legs.*	Furosemide for edema, then steroids.	Recovery	Yes, up to at least 13 cycles.	Unclear	
Shah et al. ²⁰ 2017 USA	Pembrolizumab associated hemophagocytic lymphohistocytosis	Bladder	1	76 M	Metastatic	Pembrolizumab		HLH	9 months of therapy	Unclear	Fatigue, fever. Sinus tachycardia, pallor, maculopapular rash, and spleno megalaly. Pancytopenia. Acute renal failure. Hyperferritinemia and hyperfibrinogenemia. Increased soluble IL-2R.	Etoposide, steroids	Unclear	Unclear	CR	
Rotz et al. ²¹ 2017 USA	Severe cytokine release syndrome in a patient receiving PD-1 directed therapy	Sarcoma	1	29 F	Metastatic	Nivolumab	Pazopanib	CRS	2	4	Fatigue, myalgias, fever, diffuse maculopapular rash, encephalopathy. Fever, tachycardia, hypotension, desaturation and disorientation. Thrombocytopenia, lactic acidosis, acute kidney and liver injury. Abnormal coagulation studies. Elevated CRP. Elevated levels of IL-6, IL-8, IL-10, IFN- γ .	IV fluids, steroids, broad-spectrum ABS, tocilizumab.	Recovery	No	Unclear	
Urosevic-Maiwald et al. ²² 2017 Switzerland	Systemic inflammatory reaction syndrome during combined kinase inhibitor therapy following anti-PD-1 therapy for melanoma	Malignant melanoma	2 (1)	45 F	Metastatic (stage IV)	Pembrolizumab	Dabrafenib/trametinib after ICI progression side effects, switched instead to vemurafenib/cobimetinib	SIRS		28	Fever, chills, fatigue. Hypotension (38/26 mm Hg), tachycardia, anuria.	Broad-spectrum ABS, steroids	Recovery	No, but rechallenge with vemurafenib/cobimetinib did not result in recurrence		

Cont. Urosevic-Maiwald et al.		Malignant melanoma	2 (2)	48 F	Metastatic (stage IV)	Pembrolizumab	Vemurafenib and cobimetinib after ICI progress	*hypersensitivity syndrome* or DRESS	Unclear	8	Face swelling (including eyes and lips) and a diffuse pruritic eruption, composed of erythematous and violaceous macules and papules. Hypotension, tachycardia and fever >39°C.	Steroids	Recovery	No	Unclear, but PD after around 7 months	
Takeshita et al. ²³ 2017 Japan	Coincidence of immunotherapy-associated hemophagocytic syndrome and rapid tumor regression	Squamous non-small cell lung cancer	1	63 F	Metastatic (stage IV)	Nivolumab		CRS	2	25	Severe general fatigue and high-grade fever	Methylprednisolone (1000 mg/day, 3 days, then prednisolone).	Recovery	No	Regression	
Michot et al. ²⁴ 2018 France	Fever reaction and haemophagocytic syndrome induced by immune checkpoint inhibitors	Melanoma	1	52 F	Metastatic (stage IV)	Ipilimumab	Previously 8 cycles of pembrolizumab, then cerebral stereotactic radiotherapy for a brain metastasis, then ipilimumab.	HLH	1 (8 pembrolizumab)	Initial symptoms unclear, fulminant disease 8 weeks after the last dose of ipilimumab	Initially grade 3 hepatitis, 'fever with pancytopenia and disseminated intravascular coagulation 8 weeks after the last ipilimumab cycle.'	Steroids, etoposide	Death from brain hemorrhage at metastatic site.	No	Unclear	
Sadaat et al. ²⁵ 2018 USA	Hemophagocytic lymphohistocytosis with immunotherapy: brief review and case report	Malignant melanoma	1	58 M	Metastatic	Pembrolizumab		HLH	6	31	Fever, upper normal sized spleen, anemia, thrombocytopenia, hypertriglyceridemia, hyperferritinemia, reduced NK cell activity and elevated sCD163 levels. Nausea, arthralgia. Elevated LDH.	Steroids	Recovery	No	CR for 1 year, then relapse.	
Hantel et al. ²⁶ 2018 USA	Severe hemophagocytic lymphohistocytosis in a melanoma patient treated with ipilimumab + nivolumab	Malignant melanoma	1	35 F	Metastatic	Ipilimumab/nivolumab		HLH	'Received first doses'	21	Fallor, jaundice, tachycardia. Splenomegaly. Hypotension. Anemia, thrombocytopenia, elevated bilirubin. Elevated LDH and CRP. Low haptoglobin. Hyperferritinemia, hypertriglyceridemia. Low TSH. Hemophagocytosis and elevated CD25.	IV fluids, steroids.	Recovery	No	CR	Previously progressed on adjuvant ipilimumab.
Satzger et al. ²⁷ 2018 Germany	Treatment-related hemophagocytic lymphohistocytosis secondary to checkpoint inhibition with nivolumab plus ipilimumab	Malignant melanoma	1	26 F	Metastatic	Ipilimumab/nivolumab		HLH	4	7	Increased liver function tests, fever. Elevated IL-2R, bilirubin, hyperferritinemia, hypofibrinogenemia.	Steroids, mycophenolate mofetil.	Recovery	No	CR	
Shah et al. ²⁸ 2018 USA	A Case of Epstein-Barr Virus-Related Hemophagocytic Lymphohistocytosis in Association With Pembrolizumab Therapy	Metastatic bladder cancer and thymoma	1	75 M	Metastatic	Pembrolizumab		HLH	Unclear	Unclear	Fever, fatigue, and acute onset pancytopenia. Elevated ferritin, low fibrinogen, splenomegaly, elevated soluble CD25, and decreased natural killer cell activity. Hemophagocytosis.	Unclear	Unclear	Unclear	Unclear	Active EBV infection at the same time.

Sasaki et al. ²⁸ 2018 Japan	Hemophagocytic lymphohistiocytosis associated with dabrafenib and trametinib combination therapy following pembrolizumab administration for advanced melanoma	Malignant melanoma	1	60 F	Metastatic (stage IV)	Pembrolizumab	Dabrafenib/trametinib after ICI progress	HLH	'1 month after last ICI'	13	Fever, hepatosplenomegaly, and erythema multiforme-like targetoid lesions all over the body. Pancytopenia, hyperferritinemia, increased liver enzyme levels, and coagulation abnormalities. Hemophagocytosis.	Steroids	Recovery	No, but rechallenged with TKI, no HLH.	PR	Sequential TKI and ICI
Laderian and Koehn ³⁰ 2019 USA	Association of Hemophagocytic Lymphohistiocytosis and Programmed Death 1 Checkpoint Inhibitors	Thymic carcinoma	1	49 M	Metastatic (stage IV)	Pembrolizumab	'Multiagent chemotherapy' prior to ICI treatment.	HLH	Several over the course of one year, unspecified.	Unclear	Gradually worsening pancytopenia, hemophagocytosis on bone marrow exam, no signs of viral infection as a cause for HLH.	Unclear	Deceased	Unclear	'Clinical benefit'	
Kogure et al. ³¹ 2019 Japan	Cytokine Release Syndrome with Pseudo progression in a Patient with Advanced Non-Small Cell Lung Cancer Treated with Pembrolizumab	Lung adenocarcinoma	1	67 M	Locally advanced (IIIB)	Pembrolizumab		CRS	1	2	Fever, tachycardia, hypotension.	Steroids	Recovery	Yes	Pseudoprogression, after 3 cycles of pembrolizumab PR, continuous treatment with pembrolizumab, unclear how many cycles -> near CR.	
Oda et al. ³² 2019 Japan	First Case of Cytokine Release Syndrome after Nivolumab for Gastric Cancer	Gastric adenocarcinoma	1	43 M	Metastatic	Nivolumab		CRS	1	8	'Fever (39.0°C), tachycardia, appetite loss, malaise.'	Prednisolone, then methylprednisolone, then mycophenolate mofetil.	Death 'from gastric cancer.'	No	PD	
Noseda et al. ¹⁵ 2019 France, Japan, Germany, Switzerland, Canada, USA	Hemophagocytic lymphohistiocytosis in patients treated with immune checkpoint inhibitors: analysis of WHO global database of individual case safety reports	Melanoma, lung cancer, bladder cancer, renal cell carcinoma, Hodgkin's disease, transitional cell carcinoma, gastric adenocarcinoma, thymoma, T-ALL.	38	29 M 9 F		Ipilimumab, nivolumab, pembrolizumab, atezolizumab, and combinations of the above.	Antineoplastic drugs in 2 cases, antibacterial drugs in 2 cases.									Reports 34 cases of HLH from an international pharmacovigilance database; of note, the frequency of HLH per treated case varies per country from 0.03% (USA) to 0.4% (France).
Lorenz et al. ²⁹ 2019 Germany	Hemophagocytic lymphohistiocytosis secondary to pembrolizumab treatment with insufficient response to high-dose steroids	Prostate	1	68 M	Castration-resistant, metastatic (not further specified)	Pembrolizumab	ADT and enzalutamide	HLH	Unclear	Unclear	Fever, hepatosplenomegaly, pancytopenia, hyperferritinemia, elevated serum sIL-2R, hyperriglyceridemia, hypofibrinogenemia, elevated liver enzymes. Hemophagocytosis.	Steroids, daily plasmapheresis, cyclosporin A, etoposide, tacrolimus.	Recovery	No	CR	

Okawa et al. ²⁴ 2019 Japan	Pembrolizumab-induced Autoimmune Hemolytic Anemia and Hemophagocytic Lymphohistocytosis in Non-small Cell Lung Cancer	Lung squamous cell carcinoma	1	78 M	Locally advanced (IIIB)	Pembrolizumab		HLH	1	10	Anemia, increased total and indirect bilirubin, reticulocytes and LDH. Autoimmune hemolytic anemia. Fatigue, fever. Jaundice. Leukocytosis. Serum sIL-2R elevation. Increased D-dimer. DIC. Splenomegaly.	Steroids, antibiotics.	Recovery	No	CR	
Chin et al. ²⁵ 2019 Australia	Secondary hemophagocytic lymphohistocytosis due to checkpoint inhibitor therapy	Malignant melanoma	1	69 F	Metastatic	Nivolumab (maintenance)	Ipilimumab/nivolumab	HLH	Unclear	30	Fever, lethargy, abdominal distention, swelling. Hepatosplenomegaly. Anemia, thrombocytopenia, hyponatremia, hyperferritinemia, hypofibrinogenemia and hypertriglyceridemia. CD25 elevation. Reduced NK cell activity.	Steroids	Recovery	No	SD	
Honjo et al. ²⁶ 2019 Japan	Severe cytokine release syndrome resulting in purpura fulminans despite successful response to nivolumab therapy in a patient with pleomorphic carcinoma of the lung: a case report	Pulmonary pleomorphic carcinoma	1	52 F	Locally advanced (III)	Nivolumab	Carboplatin + nab-paclitaxel (consolidation?)	CRS	*After the last nivolumab administration.*	14	Asthenia, fever. Livedo reticularis with systemic purpura. Thrombocytopenia, increased serum soluble IL-2 receptor, ferritin, triglycerides, LDH, CK, Myocarditis (increased CK-MB). Gangrene of lower extremities, amputated.	Steroids, thrombomodulin and methylcophenolate hemodialfiltration.	Recovery	No	PR	Paraneoplastic syndrome prior to ICI initiation.
Adashek and Feldman ²⁷ 2019 USA	Cytokine Release Syndrome Resulting From Anti-Programmed Death-1 Antibody: Raising Awareness Among Community Oncologists	Lung adenocarcinoma	1	72 M	Metastatic	Pembrolizumab	Radiotherapy, carboplatin, pemetrexed	CRS	3 then again after 4	1	Fever, chills, and hypotension, mental status change the first time. Then hypotension, lactic acidosis, and respiratory distress.	Tocilizumab	Recovery	Unclear	Unclear	
Slota et al. ²⁸ 2019 USA	Cytokine Release Syndrome As a Rare Complication of Nivolumab: A Case Report	Malignant melanoma	1	71 M	Metastatic (stage IV)	Nivolumab		CRS	17	Unclear	Altered mental status, hypotension, tachycardia, fever, hypoxia. Grade 3 maculopapular rash.	Broad-spectrum ABS, steroids, tocilizumab	Recovery, then relapse 6 weeks later (deceased)	No	PR	
Takahashi et al. ²⁹ 2020 Japan	A case of pembrolizumab-induced hemophagocytic lymphohistocytosis successfully treated with pulse glucocorticoid therapy	Lung adenocarcinoma	1	78 M	Metastatic (stage IV)	Pembrolizumab	Initially 2 cycles of carboplatin and pemetrexed, then switch because of bacterial pleuritis.	HLH	1	7	High grade fever, liver dysfunction and diarrhea, hypertriglyceridemia / hypofibrinogenemia, elevated ferritin, hemophagocytosis in bone marrow, cytopenia and elevated IL-2R.	Prednisolone, antibiotics; later switch to methylprednisolone.	Recovery	No	SD for 3 months	

Ohira et al. ⁴⁵ 2020 Japan	A case report of fulminant cytokine release syndrome complicated by dermatomyositis after the combination therapy with immune checkpoint inhibitors	Renal cell carcinoma	1	78 M	Metastatic (stage IV)	Nivolumab and ipilimumab		CRS	2	2	'Dermatomyositis [...] high fever, hypotension, respiratory failure, impaired consciousness, renal failure, and coagulation abnormality.'	Steroids, mycophenolate mofetil, plasma exchange; also in need of intubation and dialysis.	Recovery	No	SD for 2 months	
Normand et al. ⁴¹ 2020 Switzerland	Acute cytokine release syndrome after a first dose of pembrolizumab as second-line treatment for metastatic, programmed death-ligand 1-positive, non-small-cell lung cancer	Lung adenocarcinoma	1	79 M	Metastatic (stage IV)	Pembrolizumab	Carboplatin, pemetrexed, denosumab; whole brain radiation.	CRS	1	1	High fever, renal impairment (lab results), elevated high-sensitivity troponin T, confusion, dyspnoea.	Antibiotics, steroids.	Recovery	No	SD for 6 months	Acute onset, which is rarely reported.
Gao et al. ⁴² 2020 China	Anesophageal cancer case of cytokine release syndrome with multiple-organ injury induced by a nan anti-PD-1 drug: a case report	Esophageal squamous cell carcinoma	1	69 M	Locally advanced	Sintilimab	Docetaxel, nedaplatin, radiation.	CRS	3	Unclear; symptoms after 6 fractions of radiotherapy (2 Gy per fraction).	'Fever, diarrhea, hematological inflammation, renal damage and so on.'	Methylprednisolone, tocilizumab, mycophenolate mofetil, levothyroxine, and human immunoglobulin.	Recovery	Unclear	Unclear	
Özdemir et al. ⁴³ 2020 Switzerland	Cytokine-directed therapy with tocilizumab for immune checkpoint inhibitor-related hemophagocytic lymphohistocytosis	Malignant melanoma	3 (1)	42 M	Metastatic (stage IV)	Ipilimumab/nivolumab		HLH	2	Unclear	Fever, nausea, extreme fatigue and drowsiness. Pancytopenia, hepatitis G3, disorder of coagulation-fibrinolysis system, AKIN III.	Systemic steroids, tocilizumab, plasma, low dose heparin prophylaxis.	Recovery	Unclear	CR	Good cytokine overview with suggestions for potential therapies.
Cont. Özdemir et al.		Malignant melanoma	3 (2)	36 M	Metastatic (stage IV)	Nivolumab		HLH	5	Unclear	Splenomegaly. Deterioration of general condition, fever and extreme fatigue. Pancytopenia, hepatitis G3, disorder of coagulation-fibrinolysis system.	Tocilizumab, steroids, low dose heparin prophylaxis.	Recovery	Unclear	PR	
Cont. Özdemir et al.		Malignant melanoma	3 (3)	32 M	Metastatic (stage IV)	Ipilimumab/nivolumab		HLH	3	Unclear	Hepatosplenomegaly. Deterioration of general condition, fever and extreme fatigue. Pancytopenia, hepatitis G3, disorder of coagulation-fibrinolysis system.	Tocilizumab, plasma, low dose heparin prophylaxis.	Recovery	Unclear	PR	
Azari et al. ⁴⁴ 2020 UK	First case of hemophagocytic lymphohistocytosis secondary to cabozantinib with checkpoint inhibitors	Renal cell carcinoma	1	54 M	Metastatic	Nivolumab and ipilimumab	Cabozantinib	HLH	1	6	'Myalgia, fevers, frontal headache, photophobia, blurry vision, and vomiting', bitter rash, oral ulceration, conjunctivitis and fever, accompanied by kidney failure and elevated liver enzymes, coagulopathy,	Initially Seprin and acyclovir for suspected meningitis, upon deterioration. Meropenem, followed by methylprednisolone and anakinra.	Recovery	No	Unclear	

											encephalitis.					
Dupré et al. ⁶ 2020 France	Haemophagocytic lymphohistiocytosis associated with immune checkpoint inhibitors: a descriptive case study and literature review	Pulmonary sarcomatoid carcinoma	5 (1)	54 M	Metastatic	Pembrolizumab		HLH	1	7	Fever, asthenia, dyspnea, bone pain. Bicytopenia (thrombocytopenia, anemia), hyperferritinemia, Hemophagocytosis.	Steroids, broad-spectrum Abs.	Recovery	Yes	PD	Report of 5 cases from a pharmacovigilance study.
Cont. Dupré et al.		Malignant melanoma	5 (2)	35 F	Metastatic	Ipilimumab/nivolumab		HLH	1	21	Asthenia, spleno megaly, thrombocytopenia. Hemophagocytosis. Hyperferritinemia, hypofibrinogenemia, hypertriglyceridemia.	Steroids, etoposide, IV immunoglobulins, tocilizumab.	Recovery	Yes	SD	
Cont. Dupré et al.		Malignant melanoma	5 (3)	52 F	Metastatic	Ipilimumab/pembrolizumab		HLH	'After ipilimumab perfusion.'	30	Asthenia, fever. Hepatic cytolysis. Pancytopenia, hypofibrinogenemia, hyperferritinemia, hypertriglyceridemia. Hemophagocytosis. Cerebral hemorrhage.	Steroids, etoposide	Deceased	No	PD	
Cont. Dupré et al.		Malignant melanoma	5 (4)	69 M	Metastatic	Ipilimumab/nivolumab		HLH	'Five weeks and two cycles after the introduction of the combination.'	Unclear	Fever. Spleno megaly. Cytopenia, hyperferritinemia. Hepatic cytolysis, lymphocytic meningitis.	Steroids	Recovery	Yes	PD	Several different combinations of ICIs and TKIs. Low HScore with other IAEs, diagnosed as HLH. No hemophagocytosis.
Cont. Dupré et al.		Melanoma	5 (5)	27 M	Stage III	Ipilimumab/nivolumab		HLH	Unclear	Unclear	Fever, anemia, hyperferritinemia. Hemophagocytosis. Hypophysitis, lymphocytic meningitis, colitis, hepatic cytolysis.	Steroids	Recovery	No	Unclear	Received adjuvant pembrolizumab, progressed, then ipilimumab/pembrolizumab.
Akagiet al. ⁴⁶ 2020 Japan	Hemophagocytic Lymphohistiocytosis in a Patient with Rheumatoid Arthritis on Pembrolizumab for Lung Adenocarcinoma	Lung adenocarcinoma	1	74 M	Locally advanced (stage IIB)	Pembrolizumab		HLH	1	27	Joint swelling, hypertension, fever 38.9°C, diffuse macular rash. Leukopenia, anemia, thrombocytopenia. High ferritin level. High D-dimer. Hepatosplenomegaly.	Steroids, recombinant thrombomodulin, G-CSF, etoposide.	Recovery	No	CR	Active rheumatoid arthritis.
Thummajalli et al. ⁴⁷ 2020 USA	Hemophagocytic Lymphohistiocytosis Secondary to PD-1 and IDO Inhibition in a Patient with Refractory Glioblastoma	Glioblastoma	1	74 M	Unclear	Nivolumab	Anti-IDO1 inhibitor	HLH	2	17	Elevated ASAT, ALAT, ALP, total bilirubin. Fever, altered mental status, leukopenia, neutropenia. Spleno megaly. Hyperferritinemia, IL-6, Hypertriglyceridemia.	Steroids, vancomycin, ceftazidime, metronidazole, amphotericin B, acyclovir, and atovaquone.	Deceased	No	Unclear	

Mizuta et al. ⁴⁸ 2020 Japan	Hemophagocytic lymphohistocytosis with advanced malignant melanoma accompanied by ipilimumab and nivolumab: A case report and literature review	Malignant melanoma	1	69 F	Metastatic	Ipilimumab/nivolumab		HLH	2	1	Fever, malaise, headache, grade 2 diarrhea, thirst, elevated liver enzymes, elevated CRP and LDH, Thrombocytopenia, D-dimer elevation, Lymphadenopathy.	NSAID, levofloxacin, steroids	Unclear	Unclear	Unclear	
Ceschiet al. ¹⁶ 2020 WHO database, inc. reports from N. America, Europe, Australia, Japan.	Immune Checkpoint Inhibitor-Related Cytokine Release Syndrome: A Analysis of WHO Global Pharmacovigilance Database	Melanoma, lung cancer, other unspecified cancers	58 cases, 42 patients with non-hematological malignancies.	Med. age 55 y (inc. hematological cases). 34 M 21 F 61	Unclear	Ipilimumab, nivolumab, pembrolizumab, atezolizumab, avelumab and combinations.	Co-suspected drugs were antineoplastic agents in 18 cases and 5 other unspecified drugs.	CRS	10 cases after a single administration.	"A median of 4 weeks after ICI initiation."	"CRS, defined accordingly to the correspondent MedDRA PT 'cytokine release syndrome' (MedDRA version 21.1)."	No reported	Two fatal cases, unknown outcome in 20 cases	Unclear	Unclear	
Kalmuk et al. ⁴⁹ 2020 USA	Pembrolizumab-induced Hemophagocytic Lymphohistocytosis: an immunotherapeutic challenge	Oropharyngeal squamous cell carcinoma	1	61 M	Metastatic	Pembrolizumab	Cisplatin, radiotherapy, aspirin/clopidogrel.	HLH	14	4	Fever, malaise, pancytopenia, transaminitis. Hepatosplenomegaly. Hyperferritinemia, hypofibrinogenemia, hypertriglyceridemia. Elevated sIL-2R.	Antibiotics, steroids, etoposide	Recovery	Yes	SD for 8 months	
Hu et al. ⁵⁰ 2020 China	Pulmonary fibrosis and cytokine release syndrome after hyperactivation with sintilimab	Cobn	1	50 M	Metastatic	Sintilimab		Pulmonary fibrosis with cytokine storm.	2	1	Fever, hypotension, dyspnea, desaturation. Type I respiratory failure. Pulmonary edema and cardiogenic shock. Elevated D-dimer and BNP. Elevated IL-6 and IL-10. Elevated CRP.	IV fluids, vasopressors, steroids, broad-spectrum Abs, nintedanib.	Recovery	Unclear	Unclear	Pulmonary fibrosis due to CRS. Previously received Nivolumab without irAE.
Nieves-Borero et al. ⁵¹ 2020 USA	Atezolizumab associated with tumor lysis syndrome, cytokine release syndrome, and autoimmune toxicity	Small cell lung cancer	1	68 M	Metastatic	Atezolizumab	Carboplatin, etoposide	CRS	1	3	Acute kidney injury, elevated lactate, phosphorus, potassium, uric acid and LDH. Hypotension, cardiac arrest. Elevated IL-6, CRP, IFN-γ and ferritin. Elevated ASAT/ALAT and bilirubin.	Hemodialysis, renal replacement therapy.	Deceased	No	Unclear	
Dudda et al. ⁵² 2020 Germany	Hemophagocytic lymphohistocytosis of a melanoma patient under BRAF/MEK-inhibitor therapy following anti-PD1 inhibitor treatment: a case report and review to the literature	Malignant melanoma	1	Unclear Unclear	Metastatic (stage IV)	Nivolumab	Dabrafenib/trametinib after ICI progress.	HLH	Unclear	21	Elevated CRP, procalcitonin, splenomegaly, fever. Pancytopenia. Hyperferritinemia, increased sCD25 receptor, hypertriglyceridemia, hypofibrinogenemia.	Broad-spectrum Abs.	Recovery	No, but rechallenged with vemurafenib and cobimetinib (different BRAF/MEK).	PR	Sequential TKI and ICI.

Amlaniet al. ⁵³ 2020 Canada	Successful Treatment of Cytokine Release Syndrome with IL-6 Blockade in a Patient Transitioning from Immune-Checkpoint to MEK/BRAF Inhibition: A Case Report and Review of Literature	Malignant melanoma	1	58 M	Metastatic (stage IV)	Nivolumab	Dabrafenib/trametinib after ICI progress, side effects, switched instead to vemurafenib/cobimetinib.	CRS	Unclear	Unclear	Fatigue, malaise, and chills. Severe nausea, vomiting, diarrhea, fever of 39°C, and a purpuric eruption on his lower extremities. Distributive shock not responsive to fluids. Transaminitis, atrial fibrillation. Oliguric acute kidney injury, worsened anemia and thrombocytopenia, and confusion. NO hemophagocytosis. Encephalopathy. Acute aspiration. Elevated IL-6, IL-10, IFNγ, TNFα.	Broad-spectrum ABS, steroids, tocilizumab	Recovery	No	Unclear	TKI and ICI
Yomota et al. ⁵⁴ 2021 Japan	Cytokine Release Syndrome Induced by Immune-checkpoint Inhibitor Therapy for Non-small-cell Lung Cancer	Lung adenocarcinoma	1	53 M	Metastatic (stage IV)	Atezolizumab	Cisplatin, pemetrexed, radiation.	CRS	1	7	"High fever, rash, DIC, reduced level of consciousness, heart failure with LVEF reduced to 20% from normal at baseline."	Initially methylprednisolone, tocilizumab from day 11; supportive therapy requiring vasopressors.	Recovery	No	PR	
Percik et al. ⁵⁵ 2021 Israel	Capillary-leak syndrome: an unrecognized early immune adverse effect of checkpoint-inhibitors treatment	Malignant melanoma	2 (1)	58 M	Stage IIIB	Nivolumab and ipilimumab	No	Capillary-leak syndrome.	Nivolumab single	21	Generalized edema	Discontinuation of ICI	Initial recovery, followed by severe proximal muscle weakness and death one month later.	No	PR	
Cont. Percik et al.		Duodenal adenocarcinoma	2 (2)	72 F	Stage II	Pembrolizumab and 'an investigational CTLA-4 blocker.'	Unclear if combined	Capillary-leak syndrome.	FOLFOX initially, then 5FU, irinotecan and bevacizumab and radiation at time of relapse.	1	Fever, fatigue, bilateral leg swelling, weight gain.	Steroids	Recovery	Unclear	Unclear	
Dei Bello et al. ⁵⁶ 2021 France	Cytokine storm induced by PD1 inhibitor in a renal transplant patient	SCC	1	81 M	Unclear	Cemiplimab	Tacrolimus, mycophenolic acid, steroids (reduced doses)	Cytokine storm, rejection of renal graft.		1	Septic shock (unclear specific symptoms), renal failure.	Steroids	Dialysis, kidney necrosis transplantectomy. complications after surgery leading to death.	No	Unclear	Acute rejection of renal transplants after ICI.
Sackstein et al. ⁵⁷ 2021 USA	Pembrolizumab-induced cytokine release syndrome in a patient with metastatic lung adenocarcinoma: a case report	Lung adenocarcinoma	1	55 M	Metastatic	Pembrolizumab	Pemetrexed, carboplatin, SRS of brain.	CRS	3	19	Fever, chills, hypotension, tachypnea, lethargy. Elevated inflammatory markers (ferritin, erythrocyte sedimentation rate and C-reactive protein) as well as elevated LDH, serum amino-transferases, acute kidney injury, a bxolute lymphocytopenia with normal hemoglobin and	Vasopressors, IV fluids, broad-spectrum ABS, steroids, ivermectin, hemodialysis, tocilizumab	Recovery	Unclear	Unclear	

											platelet count, and moderate neutropenia. Elevated IL-6. Encephalopathy with aphasia and somnolence.					
Olivares-Hernández et al. ⁵⁸ 2021 Spain	Response to Treatment with an Anti-Interleukin-6 Receptor Antibody (Tocilizumab) in a Patient with Hemophagocytic Syndrome Secondary to Immune Checkpoint Inhibitors	Chorioidal melanoma	1	75 F	Metastatic	Ipilimumab		HLH	3	Unclear	Thrombocytopenia. Spleno megaly. Hyperferritinemia, hypofibrinogenemia, anemia. Fever, elevation of CRP. Elevated IL2.	Steroids, tocilizumab.	Recovery	Unclear	PR	Previously received nivolumab.
Kurozumi et al. ⁵⁹ 2021 Japan	Two cases of lung cancer with hemophagocytic lymphohistocytosis caused by immune checkpoint inhibitors	Lung adenocarcinoma	2 (1)	75 M	Metastatic	Pembrolizumab		HLH	1	10	Fever, elevated liver enzymes, cytopenia, coagulopathy, hyperferritinemia.	Steroids	Unclear	Unclear	Unclear	
Cont. Kurozumi et al. ⁵⁹		Lung adenocarcinoma	2 (2)	60 F	Locally advanced (IIB)	Pembrolizumab	Pemetrexed, chemotherapy (?)	HLH	*After last dose of pembrolizumab.*	30	Cytopenia, coagulation abnormalities, and elevated liver enzyme levels, hyperferritinemia.	Steroids	Unclear	Unclear	Unclear	
Masood et al. ⁶⁰ 2021 USA	Secondary hemophagocytic lymphohistocytosis due to nivolumab/ipilimumab in a renal cell cancer patient—A case report	Renal carcinoma	1	68 M	Metastatic	Ipilimumab/nivolumab		HLH	*Maintenance nivolumab.*	Unclear	Decreased appetite, dizziness, generalized weakness, and declining performance status. Intermittent fevers with associated tachycardia. Symptomatic hyponatremia and pancytopenia. Hyperferritinemia, hypofibrinogenemia, hypertriglyceridemia, low NK cell activity, sCD25 elevation. Spleno megaly. NO hemophagocytosis.	Steroids	Recovery	Unclear	Unclear	
Pacholzak-Majej et al. ⁶¹ 2021 Poland	Effective Treatment of a Melanoma Patient with Hemophagocytic Lymphohistocytosis after Nivolumab and Ipilimumab Combined Immunotherapy	Malignant melanoma	1	57 F	Metastatic	Ipilimumab/nivolumab		HLH	4	Unclear	Fever, general malaise, dyspnea at rest and elevated markers of inflammation and LDH. Elevated CRP and procalcitonin. DIC. Hyperferritinemia, hypofibrinogenemia, low aPTT, high INR. Hypertriglyceridemia. Spleno megaly.	Steroids, FFP, mycophenolate mofetil, cyclophosphamide, etoposide, cyclosporin.	Recovery	No	PR	Radiotherapy after PR.

Tiu et al. ⁶⁵ 2021 UK	A Wolf in Sheep's Clothing: Systemic Immune Activation Post Immunotherapy	NSCLC	3 (1)	59 F	Metastatic	Unclear		HLH	1	11	Fever, rigors, lymphopenia, thrombocytopenia, elevated LDH, elevated transaminases, hypertriglyceridemia, hyperferritinemia, hemophagocytosis.	Broad-spectrum ABS, steroids, PPIs.	Recovery	Unclear	Unclear	
Cont. Tiu et al. ⁶⁵		Breast cancer	3 (2)	42 F	Metastatic	Unclear		HLH	1	11	Fever, maculopapular rash, thrombocytopenia, elevated LDH, transaminitis, hypertriglyceridemia. Normal ferritin, then hyperferritinemia 3 days after first fever episode. Dyspnea, hypoxia.	Broad-spectrum ABS, steroids, PPIs, tocilizumab.	Recovery	Unclear	Unclear	
Cont. Tiu et al. ⁶⁵		Bladder cancer	3 (3)	67 M	Metastatic	Unclear		HLH	1	10	Fever, rigors, thrombocytopenia, lymphopenia, hyperferritinemia. Respiratory failure (type 2). Hemophagocytosis. Elevated IL-1, IL-6, IL-8, IL-10, IFNγ, TNFα.	Broad-spectrum ABS, steroids, tocilizumab, siltuximab, anakinra, hemofiltration, therapeutic plasma exchange, IV immunoglobulin.	Recovery	Unclear	Unclear	
Tay et al. ¹⁴ 2022 Singapore	Cytokine Release Syndrome in Cancer Patients Receiving Immune Checkpoint Inhibitors: A Case Series of 25 Patients and Review of the Literature	NSCLC, renal cell carcinoma, hepatocellular carcinoma, melanoma.	25	Med. age 64 18 M 7 F	Metastatic (stage IV)	Pembrolizumab, nivolumab, ipilimumab, anti-LAG3-antibody.	Concomitant chemotherapy: 6, concomitant radiation: 4, concomitant TKI: 4.	CRS		Median of 11 days after ICI initiation.	All had fever of 38°C or higher.	Steroids, tocilizumab	3 fatal (of those who received tocilizumab, unclear if more).	In 7 patients, no grade 3/4 events.	PR: 6, SD: 5, PD: 10	Out of n=539 patients receiving ICIs, corresponding to 4.6% of all ICI treated patients.
Zhang et al. ⁶⁹ 2022 China	Cytokine release syndrome and successful response to pembrolizumab therapy in a patient with EGFR-mutated non-small-cell lung cancer: A case report	Lung adenocarcinoma	1	67 F	Metastatic	Pembrolizumab		CRS	Unclear	1	Fever, nausea, vomiting, and chest pain. CRP and procalcitonin elevation. Hypotension, hypoxemia, tachycardia, and rash. Transaminase elevation, acute kidney injury, and disseminated intravascular coagulation. T cell and TNFα elevation.	Broad-spectrum Abs, IV fluids, oxygen, steroids.	Recovery	No	PR	

Discussion

CRS and HLH are potentially life-threatening side effects of treatment with ICIs; however, they are relatively rare and therefore are challenging to study. In this systematic review, we provide a comprehensive picture of the reported cases in the literature to date. Our results underscore the notion that hyperinflammatory syndromes are rare, often treatable, and rarely fatal (**Table 1**).

It is interesting to note the predominance of male patients in both case reports and small case series, as well as in pharmacovigilance databases. This might partly be driven by a higher proportion of men among lung cancer patients⁶⁴, which represent the second largest tumor group in the identified studies, and partly by sex differences in the immune response⁶⁵. Interestingly, pharmacovigilance data suggest that the outcome of CRS is more favorable in females than in males¹⁶, warranting further research into sex differences in response to treatment and in side effect profiles of ICIs.

Wider indications and lower costs have continuously led to higher numbers of patients being treated with ICIs. Hence, the clinical need to understand rare side effects has increased, and higher patient numbers allow more informed clinical decisions. A common clinical dilemma in patients receiving ICIs is whether to continue treatment despite severe, and potentially life-threatening irAEs. Key factors in this decision-making process are the risk of recurrence of a given irAE, the anticipated severity in case of recurrence, as well as its treatability. A recent study has suggested that IL-6 blockade given in parallel with ICIs ameliorates irAEs, while enhancing the antitumoral effect of ICIs⁶⁶. Earlier experimental data had already hinted at the potential benefit of adding IL-6 inhibitors to ICIs in mouse models of pancreatic cancer⁶⁷ (which is largely resistant to ICI therapy), as well as hepatocellular carcinoma⁶⁸. Together, these data suggest that IL-6 blockade does not abrogate, but rather enhances, the activation of a beneficial antitumoral immune response, providing a potential oncological rationale for combining IL-6 inhibition and ICIs. Results from CAR-T cell therapy in hematological malignancies support the lack of antagonistic effects of IL-6 antagonists in combination with ICIs; for example, in refractory large B-cell lymphoma, response rates to CAR T cell therapy were independent of the use of concomitant tocilizumab to treat CRS⁶⁹.

Our review of the literature revealed that IL-6 inhibitors have successfully been used in cases of hyperinflammatory irAEs upon ICI treatment (**Table 1**). Given the evidence that combined anti-IL-6/ICI treatment enhances the antitumoral effect and is highly effective for

CRS, an important open question is whether a rechallenge after mild CRS/HLH that responded well to anti-IL-6 treatment or corticosteroids should be considered. As shown in **Table 1**, only a few case reports exist on ICI rechallenge after CRS or HLH: One patient with metastatic oropharyngeal squamous cell carcinoma developed HLH after cycle 14 of pembrolizumab and was successfully treated with dexamethasone and etoposide⁴⁹. Eight months after this episode, during which no treatment was given, tumor progression was noted, and the patient was restarted on pembrolizumab without signs of recurrent HLH after five additional cycles⁴⁹. Another patient with a locally advanced lung adenocarcinoma developed CRS after the first cycle of pembrolizumab as first-line treatment, and was successfully treated with methylprednisolone³¹. Pembrolizumab was restarted while the patient was on low dose oral corticosteroids; the patient experienced no relapse of CRS and showed a near-complete tumor response to pembrolizumab³¹.

As a higher tumor burden has been shown to correlate with increased inflammation parameters and cytokine levels⁷⁰, it can be hypothesized that pre-treatment tumor burden is associated with the risk of developing irAEs. Indeed, studies of CAR T cell treatment for B cell acute lymphoblastic leukemia (B-ALL) have shown a significant correlation between severe CRS and a high tumor burden^{71,72(p19)}. In the largest case series published containing $n = 25$ cases, $n = 7$ were cases after rechallenge with ICIs; none of these had grade 3 or 4 CRS¹⁴, which lends some support for continuous ICI treatment despite CRS and could be appropriate in selected cases, as the risk of aggravated side effects when re-exposing patients to ICIs could be low.

While we mostly found case reports, two studies reported pharmacovigilance data from the global WHO database, and two reports queried the Registry of Severe Adverse Reactions to Immunomodulatory Antibodies used in Oncology (REISAMIC), a database for ICI-related irAEs in France^{24,45}. The first report on REISAMIC data included $n = 16$ patients with “fever reaction” to ICI treatment, and based on their analysis of these cases, the authors concluded that this irAE can “usually be controlled with a short course of corticosteroids”. The second report also queried two other French databases specifically for HLH cases, and identified $n = 5$ patients with HLH, one of which was fatal. In $n = 3$ of the five cases, rechallenge of ICI was reported, in $n = 2$ cases without recurrence of fever or HLH⁴⁵. One of the HLH cases was identified in REISAMIC among $n = 745$ patients included “at a single center between 2014 and 2019”, suggesting that HLH indeed is a rare event. The rarity of HLH is also supported by the analysis of WHO pharmacovigilance data: 49,883 ICI-related adverse events were retrieved from the WHO database VigiBase on a search conducted in

September 2018, $n = 38$ of whom corresponded to HLH, and $n = 34$ were directly linked to ICI treatment, usually developing more than six weeks after ICI treatment. Interestingly, the rate of other irAEs was below 20%¹⁵. The same group of authors queried VigiBase for CRS as of January 2020. They found $n = 58$ reports likely corresponding to CRS among a total of 80,700 reports on ICI-related adverse events, of which $n = 43$ were definitely related to ICIs, and which occurred a median of approximately four weeks after initiation of ICI treatment¹⁶. Two of those cases were fatal. Finally, a recent study presented a case series collected at two hospitals in Singapore between February 2014 and January 2021. They found that $n = 25$ out of a total of $n = 539$ patients that had received ICI developed CRS, which is a considerably higher frequency than suggested by the pharmacovigilance data, and the reason for this difference is unclear. In this cohort, $n = 7$ patients with low grade CRS were rechallenged with ICIs and did not relapse. A total of $n = 3$ cases had fatal CRS despite tocilizumab treatment¹⁴. The authors also suggested that time-to-fever-onset, low platelet count and high urea levels at CRS presentation might serve as indicators of a severe course¹⁴.

Although several studies have reported an association between irAEs and improved treatment outcome^{73,74}, it is still debatable whether ICI rechallenge after irAEs might be oncologically favorable. In accordance with current guidelines, the majority of patients with grade 3 or 4 irAEs will discontinue treatment with ICI permanently. The rarity of cases, resulting in cohorts of limited size, poses a challenge when addressing the question of ICI rechallenge. While recent studies have shown that rechallenge with ICI after irAE does not significantly improve overall survival⁷⁵, others have concluded that irAEs upon rechallenge display milder toxicities, and suggested that rechallenge might be safe for most patients, depending on the type of irAE^{76,77}. Furthermore, a meta-analysis of patients with non-small cell lung cancer rechallenged with ICIs suggests that certain patients with disease progression during ICI discontinuation might benefit from ICI rechallenge⁷⁸. Whether these data are applicable to ICI-related CRS remains to be seen.

In summary, the published data suggest that CRS and HLH are infrequent, potentially severe, but frequently treatable side effects of ICIs, and that rechallenge could be considered in selected cases, with IL-6 inhibition as an attractive preventive and therapeutic option.

Declarations

Availability of data and material

Data are available from the authors upon request.

Competing interests

The authors declare no competing interests.

Funding

This study received no dedicated funding. MG is supported by The Swedish Research Council (grant number 2018-02023), LLL is supported by The Swedish Society of Medicine and Swedish Society for Medical Research (grant number P17-0134).

Authors' contributions

LLL and MG conceived the study and performed the literature search together with the librarians of Karolinska Institute's library. LLL, MS, and MG decided on study inclusion and collected the data for the systematic review. LLL, MG, and UH collected and interpreted the data from the clinical case. MG wrote the manuscript, LLL, MS, and UH edited the manuscript.

Acknowledgements

The authors are grateful to Narcisa Hannerz and Sabina Gillsund of the Karolinska Institute's Library, for expert help in conducting the systematic literature search. We are grateful to Marie Meeths for advice on the manuscript.

References

1. Haanen JBAG, Carbone F, Robert C, Kerr KM, Peters S, Larkin J, Jordan K. Management of toxicities from immunotherapy: ESMO Clinical Practice Guidelines for diagnosis, treatment and follow-up. *Annals of Oncology*. 2017;28:iv119–iv142. doi:10.1093/annonc/mdx225
2. Management of Immune-Related Adverse Events in Patients Treated With Immune Checkpoint Inhibitor Therapy: ASCO Guideline Update | *Journal of Clinical Oncology*. [accessed June 15, 2022]. <https://ascopubs.org/doi/full/10.1200/JCO.21.01440>
3. La Rosée P, Horne A, Hines M, von Bahr Greenwood T, Machowicz R, Berliner N, Birndt S, Gil-Herrera J, Girschikofsky M, Jordan MB, et al. Recommendations for the management of hemophagocytic lymphohistiocytosis in adults. *Blood*. 2019;133(23):2465–2477. doi:10.1182/blood.2018894618
4. Onakpoya IJ. Rare adverse events in clinical trials: understanding the rule of three. *BMJ Evidence-Based Medicine*. 2018;23(1):6–6. doi:10.1136/ebmed-2017-110885
5. Zhang S, Zhou Z, Wang L, Li M, Zhang F, Zeng X. Rheumatic immune-related adverse events associated with immune checkpoint inhibitors compared with placebo in oncologic patients: a systemic review and meta-analysis. *Ther Adv Chronic Dis*. 2021;12:2040622320976996. doi:10.1177/2040622320976996
6. Frey N, Porter D. Cytokine Release Syndrome with Chimeric Antigen Receptor T Cell Therapy. *Biol Blood Marrow Transplant*. 2019;25(4):e123–e127. doi:10.1016/j.bbmt.2018.12.756
7. Morris EC, Neelapu SS, Giavridis T, Sadelain M. Cytokine release syndrome and associated neurotoxicity in cancer immunotherapy. *Nat Rev Immunol*. 2022;22(2):85–96. doi:10.1038/s41577-021-00547-6
8. Le RQ, Li L, Yuan W, Shord SS, Nie L, Habtemariam BA, Przepiorka D, Farrell AT, Pazdur R. FDA Approval Summary: Tocilizumab for Treatment of Chimeric Antigen Receptor T Cell-Induced Severe or Life-Threatening Cytokine Release Syndrome. *Oncologist*. 2018;23(8):943–947. doi:10.1634/theoncologist.2018-0028
9. Si S, Teachey DT. Spotlight on Tocilizumab in the Treatment of CAR-T-Cell-Induced Cytokine Release Syndrome: Clinical Evidence to Date. *Ther Clin Risk Manag*. 2020;16:705–714. doi:10.2147/TCRM.S223468
10. Fardet L, Galicier L, Lambotte O, Marzac C, Aumont C, Chahwan D, Coppo P, Hejblum G. Development and validation of the HScore, a score for the diagnosis of reactive hemophagocytic syndrome. *Arthritis Rheumatol*. 2014;66(9):2613–2620. doi:10.1002/art.38690
11. Meeths M, Bryceson YT. Genetics and pathophysiology of haemophagocytic lymphohistiocytosis. *Acta Paediatrica*. 2021;110(11):2903–2911. doi:10.1111/apa.16013
12. Sharma N, Stroud CRG, Walker PR, Cherry CR, Cherukuri SD, Addepalli S, Parent T, Hardin J. Systemic inflammatory response syndrome (SIRS) with immune checkpoint inhibitors. *JCO*. 2016;34(15_suppl):3061–3061. doi:10.1200/JCO.2016.34.15_suppl.3061

13. Bramer WM, Giustini D, de Jonge GB, Holland L, Bekhuis T. De-duplication of database search results for systematic reviews in EndNote. *J Med Libr Assoc*. 2016;104(3):240–243. doi:10.3163/1536-5050.104.3.014
14. Tay SH, Toh MMX, Thian YL, Vellayappan BA, Fairhurst A-M, Chan YH, Aminkeng F, Bharwani LD, Huang Y, Mak A, et al. Cytokine Release Syndrome in Cancer Patients Receiving Immune Checkpoint Inhibitors: A Case Series of 25 Patients and Review of the Literature. *Front Immunol*. 2022;13:807050. doi:10.3389/fimmu.2022.807050
15. Nosedà R, Bertoli R, Müller L, Ceschi A. Haemophagocytic lymphohistiocytosis in patients treated with immune checkpoint inhibitors: analysis of WHO global database of individual case safety reports. *J Immunother Cancer*. 2019;7(1):117. doi:10.1186/s40425-019-0598-9
16. Ceschi A, Nosedà R, Palin K, Verhamme K. Immune Checkpoint Inhibitor-Related Cytokine Release Syndrome: Analysis of WHO Global Pharmacovigilance Database. *Front Pharmacol*. 2020;11:557. doi:10.3389/fphar.2020.00557
17. Henter J-I, Horne A, Aricó M, Egeler RM, Filipovich AH, Imashuku S, Ladisch S, McClain K, Webb D, Winiarski J, et al. HLH-2004: Diagnostic and therapeutic guidelines for hemophagocytic lymphohistiocytosis. *Pediatr Blood Cancer*. 2007;48(2):124–131. doi:10.1002/pbc.21039
18. Henter J-I, Samuelsson-Horne A, Aricò M, Egeler RM, Elinder G, Filipovich AH, Gadner H, Imashuku S, Komp D, Ladisch S, et al. Treatment of hemophagocytic lymphohistiocytosis with HLH-94 immunochemotherapy and bone marrow transplantation. *Blood*. 2002;100(7):2367–2373. doi:10.1182/blood-2002-01-0172
19. Rassy EE, Assi T, Rizkallah J, Kattan J. Diffuse edema suggestive of cytokine release syndrome in a metastatic lung carcinoma patient treated with pembrolizumab. *Immunotherapy*. 2017;9(4):309–311. doi:10.2217/imt-2016-0134
20. Shah D, Shrestha R, Ramlal R, Hatton J, Saeed H. Pembrolizumab associated hemophagocytic lymphohistiocytosis. *Ann Oncol*. 2017;28(6):1403. doi:10.1093/annonc/mdx113
21. Rotz SJ, Leino D, Szabo S, Mangino JL, Turpin BK, Pressey JG. Severe cytokine release syndrome in a patient receiving PD-1-directed therapy. *Pediatr Blood Cancer*. 2017;64(12). doi:10.1002/pbc.26642
22. Urosevic-Maiwald M, Mangana J, Dummer R. Systemic inflammatory reaction syndrome during combined kinase inhibitor therapy following anti-PD-1 therapy for melanoma. *Annals of Oncology*. 2017;28(7):1673–1675. doi:10.1093/annonc/mdx187
23. Takeshita M, Anai S, Mishima S, Inoue K. Coincidence of immunotherapy-associated hemophagocytic syndrome and rapid tumor regression. *Annals of Oncology*. 2017;28(1):186–189. doi:10.1093/annonc/mdw537
24. Michot J-M, Pruvost R, Mateus C, Champiat S, Voisin A-L, Marabelle A, Lambotte O. Fever reaction and haemophagocytic syndrome induced by immune checkpoint inhibitors. *Ann Oncol*. 2018;29(2):518–520. doi:10.1093/annonc/mdx701

25. Hemophagocytic lymphohistiocytosis with immunotherapy: brief review and case report - PMC. [accessed June 21, 2022]. <https://www.ncbi.nlm.nih.gov/pmc/articles/PMC5989389/>
26. Hantel A, Gabster B, Cheng JX, Golomb H, Gajewski TF. Severe hemophagocytic lymphohistiocytosis in a melanoma patient treated with ipilimumab + nivolumab. *J Immunother Cancer*. 2018;6(1):73. doi:10.1186/s40425-018-0384-0
27. Satzger et al Treatment-related hemophagocytic lymphohistiocytosis secondary to checkpoint inhibition with nivolumab plus ipilimumab - Google Suche. [accessed June 21, 2022]. https://www.google.com/search?q=Satzger+et+al+Treatment-related+hemophagocytic+lymphohistiocytosis+secondary+to+checkpoint+inhibition+with+nivolumab+plus+ipilimumab&rlz=1C5GCEM_en&oq=Satzger+et+al%09Treatment-related+hemophagocytic+lymphohistiocytosis+secondary+to+checkpoint+inhibition+with+nivolumab+plus+ipilimumab&aqs=chrome..69i57j0j4&sourceid=chrome&ie=UTF-8
28. 168 A Case of Epstein-Barr Virus-Related Hemophagocytic Lymphohistiocytosis in Association With Pembrolizumab Therapy - ProQuest. [accessed June 21, 2022]. <https://www.proquest.com/openview/ccce829a40174af9e581abea320c369b/1?pq-origsite=gscholar&cbl=586299>
29. Sasaki K, Uehara J, Iinuma S, Doi H, Honma M, Toki Y, Ishida-Yamamoto A. Hemophagocytic lymphohistiocytosis associated with dabrafenib and trametinib combination therapy following pembrolizumab administration for advanced melanoma. *Ann Oncol*. 2018;29(7):1602–1603. doi:10.1093/annonc/mdy175
30. Laderian B, Koehn K, Holman C, Lyckholm L, Furqan M. Association of Hemophagocytic Lymphohistiocytosis and Programmed Death 1 Checkpoint Inhibitors. *J Thorac Oncol*. 2019;14(4):e77–e78. doi:10.1016/j.jtho.2018.11.035
31. Kogure Y, Ishii Y, Oki M. Cytokine Release Syndrome with Pseudoprogression in a Patient with Advanced Non-Small Cell Lung Cancer Treated with Pembrolizumab. *Journal of Thoracic Oncology*. 2019;14(3):e55–e57. doi:10.1016/j.jtho.2018.11.025
32. Oda H, Ishihara M, Miyahara Y, Nakamura J, Kozuka Y, Iwasa M, Tsunoda A, Yamashita Y, Saito K, Mizuno T, et al. First Case of Cytokine Release Syndrome after Nivolumab for Gastric Cancer. *Case Rep Oncol*. 2019;12(1):147–156. doi:10.1159/000496933
33. Lorenz G, Schul L, Bachmann Q, Angermann S, Slotta-Huspenina J, Heemann U, Kuchle C, Schmaderer C, Jäger M, Tauber R, et al. Hemophagocytic lymphohistiocytosis secondary to pembrolizumab treatment with insufficient response to high-dose steroids. *Rheumatology (Oxford)*. 2019;58(6):1106–1109. doi:10.1093/rheumatology/key447
34. Okawa S, Kayatani H, Fujiwara K, Ozeki T, Takada K, Iwamoto Y, Minami D, Sato K, Shibayama T. Pembrolizumab-induced Autoimmune Hemolytic Anemia and Hemophagocytic Lymphohistiocytosis in Non-small Cell Lung Cancer. *Intern Med*. 2019;58(5):699–702. doi:10.2169/internalmedicine.1001-18
35. Chin CK, Hall S, Green C, Van Hazel G, Spagnolo D, Cheah CY. Secondary haemophagocytic lymphohistiocytosis due to checkpoint inhibitor therapy. *Eur J Cancer*. 2019;115:84–87. doi:10.1016/j.ejca.2019.04.026

36. Honjo O, Kubo T, Sugaya F, Nishizaka T, Kato K, Hirohashi Y, Takahashi H, Torigoe T. Severe cytokine release syndrome resulting in purpura fulminans despite successful response to nivolumab therapy in a patient with pleomorphic carcinoma of the lung: a case report. *J Immunother Cancer*. 2019;7(1):97. doi:10.1186/s40425-019-0582-4
37. Adashek ML, Feldman M. Cytokine Release Syndrome Resulting From Anti-Programmed Death-1 Antibody: Raising Awareness Among Community Oncologists. *J Oncol Pract*. 2019;15(9):502–504. doi:10.1200/JOP.19.00160
38. Cytokine Release Syndrome As a Rare Complication of Nivolumab: A Case Report | Blood | American Society of Hematology. [accessed June 21, 2022]. https://ashpublications.org/blood/article/134/Supplement_1/5630/425558/Cytokine-Release-Syndrome-As-a-Rare-Complication
39. Takahashi H, Koiwa T, Fujita A, Suzuki T, Tagashira A, Iwasaki Y. A case of pembrolizumab-induced hemophagocytic lymphohistiocytosis successfully treated with pulse glucocorticoid therapy. *Respir Med Case Rep*. 2020;30:101097. doi:10.1016/j.rmcr.2020.101097
40. Ohira J, Kawamoto M, Sugino Y, Kohara N. A case report of fulminant cytokine release syndrome complicated by dermatomyositis after the combination therapy with immune checkpoint inhibitors. *Medicine (Baltimore)*. 2020;99(15):e19741. doi:10.1097/MD.00000000000019741
41. Normand CV, Zender HO, Staehli DM, Chouiter-Djebaili AF, John G. Acute cytokine release syndrome after a first dose of pembrolizumab as second-line treatment for metastatic, programmed death-ligand 1-positive, non-small-cell lung cancer. *J Oncol Pharm Pract*. 2021;27(6):1528–1533. doi:10.1177/1078155220980813
42. An esophageal cancer case of cytokine release syndrome with multiple-organ injury induced by an anti-PD-1 drug: a case report - Gao - *Annals of Palliative Medicine*. [accessed June 21, 2022]. <https://apm.amegroups.com/article/view/47672/html>
43. Özdemir BC, Latifyan S, Perreau M, Fenwick C, Alberio L, Waeber G, Spertini F, de Leval L, Michielin O, Obeid M. Cytokine-directed therapy with tocilizumab for immune checkpoint inhibitor-related hemophagocytic lymphohistiocytosis. *Ann Oncol*. 2020;31(12):1775–1778. doi:10.1016/j.annonc.2020.08.2101
44. Azari AE, Stratton R, Singh A. First case of hemophagocytic lymphohistiocytosis secondary to cabozantinib with checkpoint inhibitors. *Rheumatology*. 2021;60(5):e167–e168. doi:10.1093/rheumatology/keaa750
45. Dupré A, Michot J-M, Schoeffler A, Frumholtz L, Baroudjian B, Delyon J, Lebbe C, Lambotte O. Haemophagocytic lymphohistiocytosis associated with immune checkpoint inhibitors: a descriptive case study and literature review. *British Journal of Haematology*. 2020;189(5):985–992. doi:10.1111/bjh.16630
46. Akagi Y, Awano N, Inomata M, Kuse N, Tone M, Yoshimura H, Jo T, Takada K, Kumasaka T, Izumo T. Hemophagocytic Lymphohistiocytosis in a Patient with Rheumatoid Arthritis on Pembrolizumab for Lung Adenocarcinoma. *Intern Med*. 2020;59(8):1075–1080. doi:10.2169/internalmedicine.3889-19

47. Hemophagocytic Lymphohistiocytosis Secondary to PD-1 and IDO Inhibition in a Patient with Refractory Glioblastoma - FullText - Case Reports in Oncology 2020, Vol. 13, No. 2 - Karger Publishers. [accessed June 21, 2022].
<https://www.karger.com/Article/FullText/507281>
48. Mizuta H, Nakano E, Takahashi A, Koyama T, Namikawa K, Yamazaki N. Hemophagocytic lymphohistiocytosis with advanced malignant melanoma accompanied by ipilimumab and nivolumab: A case report and literature review. *Dermatologic therapy*. 2020. doi:10.1111/dth.13321
49. Kalmuk J, Puchalla J, Feng G, Giri A, Kaczmar J. Pembrolizumab-induced Hemophagocytic Lymphohistiocytosis: an immunotherapeutic challenge. *Cancers Head Neck*. 2020;5:3. doi:10.1186/s41199-020-0050-3
50. Hu J, Li Y, Chen X, Luo C, Zuo X. Pulmonary fibrosis and cytokine release syndrome after hyperactivation with sintilimab. *Journal of Clinical Pharmacy and Therapeutics*. 2020;45(6):1474–1477. doi:10.1111/jcpt.13217
51. Nieves-Borrero K, Adler S, Pow-anpongkul P, Yeh J. ATEZOLIZUMAB ASSOCIATED WITH TUMOR LYSIS SYNDROME, CYTOKINE RELEASE SYNDROME, AND AUTOIMMUNE TOXICITY. In: *AMERICAN JOURNAL OF KIDNEY DISEASES*. Vol. 75. WB SAUNDERS CO-ELSEVIER INC 1600 JOHN F KENNEDY BOULEVARD, STE 1800 ...; 2020. pp. 613–613.
52. Dudda M, Mann C, Heinz J, Schmidgen I, Weid F, Kühn M, Saloga J, Grabbe S, Loquai C. Hemophagocytic lymphohistiocytosis of a melanoma patient under BRAF/MEK-inhibitor therapy following anti-PD1 inhibitor treatment: a case report and review to the literature. *Melanoma Res*. 2021;31(1):81–84. doi:10.1097/CMR.0000000000000703
53. Amlani A, Barber C, Fifi Mah A, Monzon J. Successful Treatment of Cytokine Release Syndrome with IL-6 Blockade in a Patient Transitioning from Immune Checkpoint to MEK/BRAF Inhibition: A Case Report and Review of Literature. *Oncologist*. 2020;25(7):e1120–e1123. doi:10.1634/theoncologist.2020-0194
54. Yomota M, Mirokuji K, Sakaguchi M, Kitahara Y, Chin F, Setoguchi K, Hosomi Y. Cytokine Release Syndrome Induced by Immune-checkpoint Inhibitor Therapy for Non-small-cell Lung Cancer. *Intern Med*. 2021;60(21):3459–3462. doi:10.2169/internalmedicine.5922-20
55. Percik R, Nethanel A, Liel Y. Capillary-leak syndrome: an unrecognized early immune adverse effect of checkpoint-inhibitors treatment. *Immunotherapy*. 2021;13(8):653–659. doi:10.2217/imt-2020-0332
56. Del Bello A, Zakaroff AG, Meyer N, Delas A, Faguer S, Kamar N, Belliere J. Cytokine storm induced by a PD1 inhibitor in a renal transplant patient. *American Journal of Transplantation*. 2021;21(7):2616–2618. doi:10.1111/ajt.16589
57. Sackstein P, Zaemes J, Kim C. Pembrolizumab-induced cytokine release syndrome in a patient with metastatic lung adenocarcinoma: a case report. *J Immunother Cancer*. 2021;9(7):e002855. doi:10.1136/jitc-2021-002855

58. Olivares-Hernández A, Figuero-Pérez L, Amores Martín MA, Bellido Hernández L, Mezquita L, Vidal Tocino MDR, López Cadenas F, Gómez-Caminero López F, Escala-Cornejo RA, Cruz Hernández JJ. Response to Treatment with an Anti-Interleukin-6 Receptor Antibody (Tocilizumab) in a Patient with Hemophagocytic Syndrome Secondary to Immune Checkpoint Inhibitors. *Case Rep Oncol Med*. 2021;2021:6631859. doi:10.1155/2021/6631859
59. Kurozumi A, Takahashi H, Watanabe T, Iwasaki Y. Two cases of lung cancer with hemophagocytic lymphohistiocytosis caused by immune checkpoint inhibitors. *Thorac Cancer*. 2021;12(10):1625–1628. doi:10.1111/1759-7714.13954
60. Masood A, Wahab A, Clifford T, Weaver EJ, Ehsan H, El Ayass W. Secondary hemophagocytic lymphohistiocytosis due to nivolumab/ipilimumab in a renal cell cancer patient—A case report. *Clinical Case Reports*. 2021;9(12):e05184. doi:10.1002/ccr3.5184
61. Pacholczak-Madej R, Grela-Wojewoda A, Lompart J, Żuchowska-Vogelgesang B, Ziobro M. Effective Treatment of a Melanoma Patient with Hemophagocytic Lymphohistiocytosis after Nivolumab and Ipilimumab Combined Immunotherapy. *Prague Med Rep*. 2022;123(1):35–42. doi:10.14712/23362936.2022.4
62. Tiu C, Shinde R, Pal A, Biondo A, Lee A, Tunariu N, Jhanji S, Grover V, Tatham K, Gruber P, et al. A Wolf in Sheep's Clothing: Systemic Immune Activation Post Immunotherapy. *J Immunother Precis Oncol*. 2021;4(4):189–195. doi:10.36401/JIPO-21-9
63. Zhang M, Cheng Y, Hu Y, Nie L. Cytokine release syndrome and successful response to pembrolizumab therapy in a patient with EGFR-mutated non-small-cell lung cancer: A case report. *Thorac Cancer*. 2022;13(9):1419–1422. doi:10.1111/1759-7714.14390
64. Chen X, Mo S, Yi B. The spatiotemporal dynamics of lung cancer: 30-year trends of epidemiology across 204 countries and territories. *BMC Public Health*. 2022;22(1):987. doi:10.1186/s12889-022-13281-y
65. Sex differences in immune responses | *Nature Reviews Immunology*. [accessed June 28, 2022]. <https://www.nature.com/articles/nri.2016.90>
66. Hailemichael Y, Johnson DH, Abdel-Wahab N, Foo WC, Bentebibel S-E, Daher M, Haymaker C, Wani K, Saberian C, Ogata D, et al. Interleukin-6 blockade abrogates immunotherapy toxicity and promotes tumor immunity. *Cancer Cell*. 2022;40(5):509-523.e6. doi:10.1016/j.ccell.2022.04.004
67. Mace TA, Shakya R, Pitarresi JR, Swanson B, McQuinn CW, Loftus S, Nordquist E, Cruz-Monserrate Z, Yu L, Young G, et al. IL-6 and PD-L1 antibody blockade combination therapy reduces tumour progression in murine models of pancreatic cancer. *Gut*. 2018;67(2):320–332. doi:10.1136/gutjnl-2016-311585
68. Liu H, Shen J, Lu K. IL-6 and PD-L1 blockade combination inhibits hepatocellular carcinoma cancer development in mouse model. *Biochem Biophys Res Commun*. 2017;486(2):239–244. doi:10.1016/j.bbrc.2017.02.128
69. Neelapu SS, Locke FL, Bartlett NL, Lekakis LJ, Miklos DB, Jacobson CA, Braunschweig I, Oluwole OO, Siddiqi T, Lin Y, et al. Axicabtagene Ciloleucel CAR T-Cell

Therapy in Refractory Large B-Cell Lymphoma. *N Engl J Med*. 2017;377(26):2531–2544. doi:10.1056/NEJMoa1707447

70. Davila ML, Riviere I, Wang X, Bartido S, Park J, Curran K, Chung SS, Stefanski J, Borquez-Ojeda O, Olszewska M, et al. Efficacy and toxicity management of 19-28z CAR T cell therapy in B cell acute lymphoblastic leukemia. *Sci Transl Med*. 2014;6(224):224ra25. doi:10.1126/scitranslmed.3008226

71. Hay KA. Cytokine release syndrome and neurotoxicity after CD19 chimeric antigen receptor-modified (CAR-) T cell therapy. *Br J Haematol*. 2018;183(3):364–374. doi:10.1111/bjh.15644

72. Li M, Xue S-L, Tang X, Xu J, Chen S, Han Y, Qiu H, Miao M, Xu N, Tan J, et al. The differential effects of tumor burdens on predicting the net benefits of ssCART-19 cell treatment on r/r B-ALL patients. *Sci Rep*. 2022;12(1):378. doi:10.1038/s41598-021-04296-3

73. Das S, Johnson DB. Immune-related adverse events and anti-tumor efficacy of immune checkpoint inhibitors. *J Immunother Cancer*. 2019;7(1):306. doi:10.1186/s40425-019-0805-8

74. Hussaini S, Chehade R, Boldt RG, Raphael J, Blanchette P, Maleki Vareki S, Fernandes R. Association between immune-related side effects and efficacy and benefit of immune checkpoint inhibitors - A systematic review and meta-analysis. *Cancer Treat Rev*. 2021;92:102134. doi:10.1016/j.ctrv.2020.102134

75. Albandar HJ, Fuqua J, Albandar JM, Safi S, Merrill SA, Ma PC. Immune-Related Adverse Events (irAE) in Cancer Immune Checkpoint Inhibitors (ICI) and Survival Outcomes Correlation: To Rechallenge or Not? *Cancers (Basel)*. 2021;13(5):989. doi:10.3390/cancers13050989

76. Allouchery M, Lombard T, Martin M, Rouby F, Sassier M, Bertin C, Atzenhoffer M, Miremont-Salame G, Perault-Pochat M-C, Puyade M, et al. Safety of immune checkpoint inhibitor rechallenge after discontinuation for grade ≥ 2 immune-related adverse events in patients with cancer. *J Immunother Cancer*. 2020;8(2):e001622. doi:10.1136/jitc-2020-001622

77. Dolladille C, Ederhy S, Sassier M, Cautela J, Thuny F, Cohen AA, Fedrizzi S, Chrétien B, Da-Silva A, Plane A-F, et al. Immune Checkpoint Inhibitor Rechallenge After Immune-Related Adverse Events in Patients With Cancer. *JAMA Oncol*. 2020;6(6):865–871. doi:10.1001/jamaoncol.2020.0726

78. Xu S, Shukuya T, Tamura J, Shimamura S, Kurokawa K, Miura K, Miyawaki T, Hayakawa D, Asao T, Yamamoto K, et al. Heterogeneous Outcomes of Immune Checkpoint Inhibitor Rechallenge in Patients With NSCLC: A Systematic Review and Meta-Analysis. *JTO Clin Res Rep*. 2022;3(4):100309. doi:10.1016/j.jtocrr.2022.100309