

Concurrent gliomas in patients with multiple sclerosis

Katharina Sahm^{1,2}, Tobias Kessler^{3,4}, Philipp Eisele¹, Miriam Ratliff⁵, Elena Sperk⁶, Laila König⁷, Michael O. Breckwoldt^{2,8}, Corinna Seliger^{4,9}, Iris Mildenerberger^{1,2}, Daniel Schrimpf^{10, 11}, Christel Herold-Mende¹², Pia S. Zeiner¹³, Ghazaleh Tabatabai¹⁴, Sven G. Meuth¹⁵, David Capper^{16,17}, Martin Bendszus⁸, Andreas von Deimling^{10,11}, Wolfgang Wick^{3,4}, Felix Sahm^{10,11}, and Michael Platten^{1,2}

- 1) Department of Neurology, Medical Faculty Mannheim, Mannheim Center for Translational Neurosciences (MCTN), University of Heidelberg, Mannheim, Germany
- 2) Clinical Cooperation Unit Neuroimmunology and Brain Tumor Immunology, German Cancer Consortium (DKTK), German Cancer Research Center (DKFZ), Heidelberg, Germany
- 3) Clinical Cooperation Unit Neurooncology, German Cancer Consortium (DKTK), German Cancer Research Center (DKFZ), Heidelberg, Germany
- 4) Department of Neurology and Neurooncology Program, National Center for Tumor Diseases (NCT), Heidelberg University Hospital, Heidelberg, Germany
- 5) Department of Neurosurgery, Medical Faculty Mannheim, Mannheim Center for Translational Neurosciences (MCTN), University of Heidelberg, Mannheim, Germany
- 6) Department of Radiation Oncology, Medical Faculty Mannheim, University of Heidelberg, Mannheim, Germany
- 7) Department of Radiation Oncology, Heidelberg University Hospital, Heidelberg, Germany
- 8) Department of Neuroradiology, Heidelberg University Hospital, Heidelberg, Germany
- 9) Wilhelm Sander-NeuroOncology Unit and Department of Neurology, Regensburg University Hospital, Regensburg, Germany
- 10) Department of Neuropathology, Heidelberg University Hospital, Heidelberg, Germany
- 11) Clinical Cooperation Unit Neuropathology, German Cancer Consortium (DKTK), German Cancer Research Center (DKFZ), Heidelberg, Germany
- 12) Division of Experimental Neurosurgery, Department of Neurosurgery, Heidelberg University Hospital, Heidelberg, Germany
- 13) Dr Senckenberg Institute of Neurooncology, University of Frankfurt, Frankfurt, Germany
- 14) Department of Neurology & Interdisciplinary Neurooncology, University Hospital Tübingen, Hertie Institute for Clinical Brain Research, Eberhard Karls University Tübingen, Germany
- 15) Department of Neurology, Institute of Translational Neurology, University Hospital Münster, Münster, Germany
- 16) Department of Neuropathology, Charité - Universitätsmedizin Berlin, corporate member of Freie Universität Berlin, Humboldt-Universität zu Berlin, and Berlin Institute of Health, Berlin, Germany
- 17) German Cancer Consortium (DKTK), Partner Site Berlin, German Cancer Research Center, Heidelberg, Germany

Running title: Concurrent multiple sclerosis and glioma

Correspondence to: Katharina Sahm, Department of Neurology, Medical Faculty Mannheim, University of Heidelberg, Theodor-Kutzer-Ufer 1–3, 68167 Mannheim, Germany. Phone: +49 (0)621/383-2885, Fax: +49 (0)621/383-3807, E-Mail: katharina.sahm@umm.de

Funding: This work was supported by a grant from the Deutsche Forschungsgemeinschaft (DFG) within CRC1366 “Vascular Control of Organ Function”, project number 39404578, to KS and MP (project C1) and the Hertie Foundation (P1200013) to KS. MOB acknowledges funding by the Else Kröner-Fresenius Stiftung (2019_EKMS.23).

Conflict of interest: The authors declare that they have no competing interests.

Authorship: Conception and design: KS, MP. Acquisition of data: all. Analysis of data: KS, TK, DS, FS, MP. Interpretation of data: all. Writing, review, and/or revision of the manuscript: all.

Total word count: 4825

Abbreviations

CI	confidence interval
DMP	differentially methylated position
DMR	differentially methylated region
HLA	human leukocyte antigen
IDH	isocitrate dehydrogenase
IL	interleukin
MGMT	O6-methylguanine-DNA methyltransferase
NAWM	normal appearing white matter
OR	odds ratio
OS	overall survival
PFS	progression-free survival
RANO	response assessment in neuro-oncology
RT	radiotherapy
SVD	singular value decomposition

Abstract

Background: Concurrent malignant brain tumors in patients with multiple sclerosis (MS) constitute a rare but paradigmatic phenomenon for studying neuroimmunological mechanisms from both molecular and clinical perspectives.

Methods: A multicenter cohort of 26 patients diagnosed with both primary brain tumors and multiple sclerosis was studied for disease localization, tumor treatment-related MS activity, and molecular characteristics specific for diffuse glioma in MS patients.

Results: MS neither predisposes nor protects from the development of gliomas. Patients with glioblastoma WHO grade IV without IDH mutations had a longstanding history of MS, whereas patients diagnosed with IDH-mutant astrocytoma WHO grade II received multiple sclerosis diagnosis mostly at the same time or later. Concurrent MS was associated with a lesser extent of tumor resection and a worse prognosis in IDH-mutant glioma patients (PFS 32 vs. 64 months, $p=0.0206$). When assessing tumor-intrinsic differences no distinct subgroup-defining methylation pattern was identified in gliomas of MS patients compared to other glioma samples. However, differential methylation of immune-related genetic loci including human leukocyte antigen locus on 6p21 and interleukin locus on 5q31 was found in MS patients vs. matched non-MS patients. In line, inflammatory disease activity increased in 42% of multiple sclerosis patients after brain tumor radiotherapy suggesting a susceptibility of multiple sclerosis brain tissue to pro-inflammatory stimuli such as ionizing radiation.

Conclusions: Concurrent low-grade gliomas should be considered in multiple sclerosis patients with slowly progressive, expansive T2/FLAIR lesions. Our findings of typically reduced extent of resection in MS patients and increased MS activity after radiation inform future treatment decisions.

Keywords: Multiple Sclerosis, Glioma, Radiation, Immunotherapy

Key points:

- Disease history and sequence of diagnosis differ in MS patients with high- vs low-grade glioma
- Gliomas of MS patients harbor subtle methylation changes in immune-related genetic regions
- Brain tumor radiotherapy is followed by MS disease activity

Importance of the study

Immune escape is a hallmark of diffuse glioma, while inflammation is the underlying mechanism of multiple sclerosis. These opposing mechanisms concur in patients that suffer in parallel from multiple sclerosis and glioma. This study is the first to investigate the tumor characteristics, tumor treatment responses and effect on multiple sclerosis activity of a cohort of patients with both diseases. The data warrant caution in the interpretation of suspicious lesions in imaging and suggests risk loci for the observed detrimental effects of radiation specific to MS patients.

Introduction

Gliomas have been reported in patients with multiple sclerosis (MS)^{1,2}. As immune surveillance is critical in cancer development, a possible causal “immuno-genetic” relationship between neuroinflammatory diseases and malignant brain tumors has been repeatedly discussed³. Proposed cancer-promoting mechanisms include a malignant transformation of multiple sclerosis plaques⁴ and immunosuppression induced by immunomodulatory therapies^{5 6 7}. However, two population-based studies could not verify an altered risk for gliomas in patients with MS^{8 9}.

From a clinical perspective, concurrent brain tumors may interfere with the diagnosis and course of MS and *vice versa*. MS lesions can mimic cerebral malignancies in conventional magnetic resonance imaging (MRI)¹⁰, and misdiagnosing brain tumor symptoms as relapse in patients with known MS can delay appropriate tumor treatment². Moreover, due to the limited number of cases and lack of detailed analyses of clinical and imaging disease patterns, outcome, and molecular profiling, little is known about the effects of radio- and chemotherapy on MS disease activity and progression.

Discovering the role of epigenetic regulations such as histone modification or DNA methylation for susceptibility, progression, and treatment response of brain tumors has resulted in a fundamental shift in molecular classification and subtyping^{11 12}. In contrast to distinct brain tumor methylomes, epigenetic changes in non-neoplastic diseases are subtler. In MS, aberrant DNA methylation patterns affect disease development and pathogenesis by mediating inflammatory response and neurodegeneration¹³. Interestingly, methylation differences are not only seen in pathologically altered tissue but can also be recapitulated in normal-appearing white matter or peripheral blood cells of MS patients and mainly occur in immune-related genes¹⁴.

While the failure of immune surveillance is crucial for pathogenesis in both conditions, the complex interplay between the immune microenvironment, genetic alterations, and epigenetic regulation is only partly understood.

In this study, we analyzed clinical, imaging, and molecular data of a multicenter cohort of 26 patients with MS and concurrent glioma to determine if brain tumors in MS patients are molecularly distinct and if concurrent MS affects tumor prognosis and occurrence of treatment-associated adverse events.

Materials and Methods

Study population

In this multicenter, retrospective analysis, we collected 30 brain tumor tissue samples diagnosed between 01 January 2001 and 31 December 2017 and clinical and radiographical data of patients with reported multiple sclerosis from the Departments of Neuropathology, Neurology and Neurosurgery, University of Heidelberg; the Departments of Neurology and Neurosurgery, University Medical Center Mannheim of Heidelberg University; Dr Senckenberg Institute of Neurooncology, University of Frankfurt, and the Department of Neurology, University of Tübingen (all located in Germany). Four cases were excluded due to tumor histology other than glioma or insufficient proof of multiple sclerosis diagnosis according to the revised McDonald criteria¹⁵ resulting in a study population of 26 patients in the experimental cohort. Control cases with isocitrate dehydrogenase (IDH)-mutant 1p19q-intact astrocytoma WHO grade II or IDH-wildtype glioblastoma WHO grade IV were collected from the Departments of Neuropathology, Neurology, and Neurosurgery, University of Heidelberg, and matched for tumor histology and the known prognostic markers IDH- and O6-methylguanine-DNA methyltransferase (MGMT)-status, age at diagnosis, and Karnofsky-Index. Tissue sample collection and data collection and use were performed following local ethics regulations and approved by the local ethics committee (ethics votes 005/2003, 2013-832R-MA, 2018-614N-MA).

Clinical assessments

Progression-free survival (PFS), defined as the time from brain tumor surgery to the date of tumor progression, was assessed based on follow-up imaging performed under the response assessment in neuro-oncology (RANO) criteria^{16,17}. The overall survival (OS) was defined as the time from surgery to the date of decease. Multiple sclerosis disease activity was assessed based on clinical attacks and MRI follow-up according to the revised McDonald criteria¹⁵.

Methylation analysis

Bioinformatic analysis of Illumina 450k methylation array data was performed with customized scripts adapted from the R (www.r-project.org) based library “ChAMP” (version: 2.10.116) as described previously¹⁸. At the Genomics and Proteomics Core Facility of the

German Cancer Research Center (DKFZ) in Heidelberg, Germany, the Infinium HumanMethylation450 BeadChip and kits (Illumina, San Diego, CA, USA) were used according to manufacturer's instructions to obtain the DNA methylation status at >450,000 sites in paraffin-embedded tissue derived from glioma patients with MS and matched controls. Raw data was loaded using the `load()` function in "ChAMP". For multi-hit sites, SNPs, and XY chromosome related CpGs data was filtered; next, data was normalized with a BMIQ based method and analyzed for batch effects with a singular value decomposition (SVD) algorithm. There was no significant batch to be corrected. Respective functions were used to assess differentially methylated regions (DMR). Principle component analysis was used for dimensionality reduction. Circos plots showing DMR distribution were constructed with the package "OmicCircos" (version: 1.26.0).

Statistical analyses

Logistic regression analyses to calculate odds ratios (ORs) with 95% confidence intervals (CIs) were performed to compare clinical characteristics in the experimental cohort and control cohort. Distribution of survival times was estimated by the Kaplan–Meier method and compared between groups with the log-rank test. A p-value of less than 0.05 was considered significant.

Data availability

Source code can be made available on reasonable request.

Results

Clinical characteristics of patients with multiple sclerosis and concurrent glioma

A multicenter, retrospective cohort of 26 patients with both MS and diffuse glioma, meeting the predefined inclusion criteria was assembled from four centers (Figure 1, Supplementary Table 1). A survey of 2809 brain tumor patients (C71 ICD-10-GM), diagnosed between 01 January 2007 and 31 December 2015, revealed no evidence of increased MS prevalence compared to published cohorts with or without autoimmune diseases (Anssar *et al.*, 2020) (Supplementary Table 2). All gliomas had an astrocytic morphology, with IDH-mutant astrocytomas WHO grade II being the most frequent brain tumors in MS patients (46%), followed by IDH-wildtype glioblastomas WHO grade IV (31%). Median age at tumor diagnosis was 32.5 years for IDH-mutant astrocytomas and 59 years for glioblastomas, both within the

age range expected for these tumor types¹⁹ (Figure 2 A, Supplementary Table 3, 4). The mean age at MS diagnosis was 31 years and 40 years, respectively (Figure 2 B, Supplementary Table 5). The MS symptom course was relapsing-remitting in 19/26 (73%) cases and secondary progressive in 4/26 (15%). All patients had radiologically proven cerebral inflammatory lesions, 6/26 (23%) had spinal lesions, and 7/26 (27%) had optic neuritis. 15/26 (58%) patients received immunomodulatory treatment (Supplementary Table 1, Supplementary Figure 1 B).

While patients diagnosed with glioblastoma had a longstanding history of CNS inflammatory disease, patients diagnosed with IDH-mutant astrocytoma received MS diagnosis mostly at the same time or later. Subsequently, glioblastomas arose near existing inflammatory lesions, while IDH-mutant astrocytomas developed from radiologically normal-appearing white matter (NAWM) (Figure 2 D, E, F).

Concurrent multiple sclerosis diagnosis is associated with worse prognosis of IDH-mutant astrocytomas

Next, clinical data from glioma patients with concurrent MS were compared with data from control patients without MS and matched for tumor histology and the known prognostic markers IDH- and MGMT-status, age at diagnosis, and Karnofsky-Index (Supplementary Table 3, 4). The glioblastoma-related neurological symptoms and distinct radiological morphology led to prompt radiological tumor suspicion and subsequent histological diagnosis independent of MS comorbidity. In contrast, radiological findings in most MS patients with IDH-mutant astrocytoma WHO grade II occurred incidentally, with a median time of 21 months (0 – 68) between initial MRI suspicion and histological diagnosis (Figure 3 A, B). However, glioma size at the time of histological diagnosis was comparable between MS and control groups for both tumor types (Figure 3 C). For non-contrast enhancing lesions, results from non-invasive MRI spectroscopy could support tumor suspicion in one patient (Supplementary Figure 2). Glioma diagnosis was confirmed by biopsy in 14/26 (54%) cases, and 12/26 (46%) received partial or complete tumor resection. Remarkably, the proportion of patients receiving tumor biopsy was higher in MS patients than controls independent of tumor histology (29% vs. 14% for IDH-wildtype; 50% vs. 25% for IDH-mutant) (Figure 3 D). While all glioblastoma patients received standard tumor-specific treatment, except one non- MS patient receiving best supportive care, the majority of patients with

IDH-mutant astrocytomas were primarily treated with a watchful waiting approach according to the current standard of care independent of MS diagnosis (Figure 3 E). As expected²⁰, patients with IDH-wildtype glioblastomas showed a significantly shorter PFS compared to patients with IDH-mutant astrocytomas independent of concurrent MS. Of note, multiple sclerosis was associated with a worse prognosis in IDH-mutant tumors only (PFS 32 vs. 64 months, $p=0.0206$) (Figure 3 F, Supplementary Figure 1 D). The limited sample size did not allow to firmly establish the impact of immunomodulatory treatments on brain tumor progression (Supplementary Figure 1 E).

Glioma radiotherapy as a possible risk factor for multiple sclerosis disease activity

The majority of patients were treated with radiotherapy (RT) alone or in combination with chemotherapy at one time during the course of brain tumor disease (83% in the IDH-mutant and 71% in the IDH-wildtype cohort) (Figure 4 A, Supplementary Figure 1 C). While none of the IDH-mutant astrocytoma patients showed clinical or radiological signs of multiple sclerosis disease activity according to NEDA-3 criteria within the 12 months prior to starting RT, 5/12 patients (42%) with multiple sclerosis and IDH-mutant astrocytoma showed disease activity within 12 months after RT, with an average of 1.4 clinical relapses. Remarkably, 89% of clinical episodes occurred within the first six months after RT and were associated with new contrast-enhancing lesions within or adjacent to the radiation field (Figure 4, Supplementary Figure 1 F). In 3/5 patients, radiation-associated neuroinflammation occurred despite immunomodulatory treatment, and in 2/5 patients, multiple sclerosis was initially diagnosed within six months after RT. Interestingly, one patient with IDH-wildtype glioblastoma experienced long-term survival with no evidence of tumor recurrence for eight years following radiation-induced pseudo-progression. The radiographical increase in disease activity was accompanied by neurological deterioration, leading to the initial diagnosis of a chronic progressive multiple sclerosis course eight months after completion of radiotherapy (Figure 5).

Genome-wide methylation analysis of glioma samples identified DMRs associated with neuroinflammation

Genome-wide methylation patterns of glioma tissue from 12 multiple sclerosis patients and the matched control cohort without multiple sclerosis were compared to address the

question if chronic neuroinflammation may predispose susceptibility to the exacerbation of focal disease activity on a molecular level in multiple sclerosis patients after radiotherapy (Supplementary Table 3, 4). While principal component analysis and unsupervised clustering revealed no distinct subgroup-defining methylation pattern depending on multiple sclerosis diagnosis, analysis of DMRs identified 117 DMRs in IDH-mutant astrocytomas and 103 DMRs in IDH-wildtype glioblastomas, with 11 common DMRs possibly associated with multiple sclerosis (Figure 6 A, Supplementary Figure 3). Interestingly, DMRs build a hotspot on the short arm of chromosome 6 (p21.32) within the human leukocyte antigen (HLA) region (Figure 6 B). The HLA system plays a critical role in immune regulation by presenting epitopes to leukocytes and thereby releasing antigen-specific immune responses ²¹. For multiple sclerosis, the HLA system has been shown to comprise major susceptibility loci (Gourraud *et al.*, 2012), and the aberrant methylation patterns of specific HLA genes in NAWM of multiple sclerosis patients are thought to be relevant for multiple sclerosis etiology (Huynh *et al.*, 2014). Moreover, most known multiple sclerosis risk genes belong to the immune system, and genetic regions related to innate immunity are thought to constitute glioma risk factors (Plantone *et al.*, 2015). In line, additional DMRs are located on chromosome 5q31 within the interleukin (IL) region and include genes associated with myelination and immune function (Supplementary Table 6). These data suggest that epigenetic changes in inflammatory genes in NAWM predispose to exacerbation of neuroinflammation by focal irradiation.

Discussion

Multiple sclerosis with concurrent glioma is a rare phenomenon, with only a few cases reported ^{9,22-24}. From an immunological perspective, both diseases comprise opposed paradigmatic conditions within the central nervous system (CNS), with excessive immune reactions causing multiple sclerosis and profound immunosuppression enabling glioma progression, respectively ^{25 26 27}. The role of underlying onco-immunological mechanisms for disease susceptibility and etiology has been repeatedly discussed without answering the question of an incidental co-existence or causal relationship ^{22 28 3}. In this context, epigenetic mechanisms could play an essential role. While region-specific changes in DNA methylation occur in multiple sclerosis brains ¹⁴, the methylome is known as a diagnostic and predictive factor in primary brain tumors ^{3,12}. By comparative analysis of genome-wide DNA

methylation patterns of gliomas occurring in patients with and without concurrent multiple sclerosis, we could identify DMRs involving immune-relevant genes such as HLA and interleukin regions (Figure 6). Although the pathophysiological relevance remains unproven, these results support previous findings of subtle but widespread and persistent epigenetic changes in the CNS tissue of multiple sclerosis patients¹⁴ and could reflect underlying (subclinical) neuroinflammation.

One major clinical challenge is the accurate detection of brain malignancies in patients with known multiple sclerosis, where especially early non-enhancing gliomas could be misdiagnosed as multiple sclerosis lesions. On the other hand, tumefactive multiple sclerosis lesions can mimic brain tumors when viewed with conventional MRI techniques². In our cohort, the vast majority of IDH-mutant astrocytomas in patients suffering from multiple sclerosis were incidentally detected during routine radiological follow-up. Although an average of almost two years passed until histological validation was realized, MRI tumor size at the time of surgery was comparable to that of the control group in which further diagnostic procedures were triggered by neurological symptoms. Remarkably, a relevant proportion of multiple sclerosis patients received tumor biopsy only without further resection, which might have contributed to an unfavorable prognosis (Figure 3). Although the small sample sizes constitute a major limitation, our data suggest the importance of an additional diagnostic work-up, the early biopsy of atypical or suspicious lesions, and in case of a brain tumor diagnosis a second surgery to allow for (partial) resection as a known prognostic marker.

So far, little is known about the disease course of multiple sclerosis patients with concurrent brain tumors. While at the early stages of relapsing-remitting multiple sclerosis, clinical episodes associated with inflammatory lesions largely recover, incomplete recovery causes secondary disease progression over time²⁹. Although some case series suggest a positive impact of brain tumors on multiple sclerosis disease course³⁰, conclusive data including the role of brain cancer treatments and multiple sclerosis disease-modifying therapies are lacking. Our data support the concept of radiation-induced inflammation in multiple sclerosis, with close to half the patients presenting with clinical or radiological signs of disease activity after glioma radiotherapy, while showing no evident disease activity before radiotherapy (Figure 4). One patient experienced a complete long-term response after radiation-induced pseudo-progression (Figure 5). The role of secondary immune effects

including release of tumor antigens for the response to radiotherapy is well known³¹, and a combination of radiotherapy and immunotherapy has shown synergistic effects also in brain tumors³². Thus, based on this paradigmatic concurrence of immunologically opposed CNS diseases, our data could support the concept of combined radioimmunotherapy to treat brain cancer.

References

1. Sinclair G, Al-Saffar Y, Johnstone P, Hatiboglu MA, Shamikh A. A challenging case of concurrent multiple sclerosis and anaplastic astrocytoma. *Surgical neurology international*. 2019; 10:166-166.
2. Preziosa P, Sangalli F, Esposito F, et al. Clinical deterioration due to co-occurrence of multiple sclerosis and glioblastoma: report of two cases. *Neurol Sci*. 2017; 38(2):361-364.
3. Plantone D, Renna R, Sbardella E, Koudriavtseva T. Concurrence of multiple sclerosis and brain tumors. *Front Neurol*. 2015; 6:40.
4. Acqui M, Caroli E, Di Stefano D, Ferrante L. Cerebral ependymoma in a patient with multiple sclerosis case report and critical review of the literature. *Surg Neurol*. 2008; 70(4):414-420.
5. Sierra Morales F, Wright RB, Novo JE, Arvanitis LD, Stefoski D, Koralnik IJ. Glioblastoma in natalizumab-treated multiple sclerosis patients. *Ann Clin Transl Neurol*. 2017; 4(7):512-516.
6. Sharim J, Tashjian R, Golzy N, Pouratian N. Glioblastoma following treatment with fingolimod for relapsing-remitting multiple sclerosis. *J Clin Neurosci*. 2016; 30:166-168.
7. Mantero V, Balgera R, Bianchi G, et al. Brainstem glioblastoma in a patient with secondary progressive multiple sclerosis. *Neurol Sci*. 2015; 36(9):1733-1735.
8. Anssar TM, Leitzmann MF, Linker RA, et al. Autoimmune diseases and immunosuppressive therapy in relation to the risk of glioma. *Cancer Med*. 2020; 9(3):1263-1275.
9. Hemminki K, Liu X, Försti A, Ji J, Sundquist J, Sundquist K. Subsequent brain tumors in patients with autoimmune disease. *Neuro Oncol*. 2013; 15(9):1142-1150.
10. Kebir S, Gaertner FC, Mueller M, et al. F-fluoroethyl-L-tyrosine positron emission tomography for the differential diagnosis of tumefactive multiple sclerosis versus glioma: A case report. *Oncol Lett*. 2016; 11(3):2195-2198.
11. Sahm F, Schrimpf D, Stichel D, et al. DNA methylation-based classification and grading system for meningioma: a multicentre, retrospective analysis. *Lancet Oncol*. 2017; 18(5):682-694.
12. Capper D, Jones DTW, Sill M, et al. DNA methylation-based classification of central nervous system tumours. *Nature*. 2018; 555(7697):469-474.

13. Celarain N, Tomas-Roig J. Aberrant DNA methylation profile exacerbates inflammation and neurodegeneration in multiple sclerosis patients. *J Neuroinflammation*. 2020; 17(1):21.
14. Huynh JL, Garg P, Thin TH, et al. Epigenome-wide differences in pathology-free regions of multiple sclerosis-affected brains. *Nat Neurosci*. 2014; 17(1):121-130.
15. Thompson AJ, Banwell BL, Barkhof F, et al. Diagnosis of multiple sclerosis: 2017 revisions of the McDonald criteria. *Lancet Neurol*. 2018; 17(2):162-173.
16. Wen PY, Macdonald DR, Reardon DA, et al. Updated response assessment criteria for high-grade gliomas: response assessment in neuro-oncology working group. *J Clin Oncol*. 2010; 28(11):1963-1972.
17. van den Bent MJ, Wefel JS, Schiff D, et al. Response assessment in neuro-oncology (a report of the RANO group): assessment of outcome in trials of diffuse low-grade gliomas. *Lancet Oncol*. 2011; 12(6):583-593.
18. Kessler T, Sahm F, Sadik A, et al. Molecular differences in IDH wildtype glioblastoma according to MGMT promoter methylation. *Neuro Oncol*. 2018; 20(3):367-379.
19. Wick W, Roth P, Hartmann C, et al. Long-term analysis of the NOA-04 randomized phase III trial of sequential radiochemotherapy of anaplastic glioma with PCV or temozolomide. *Neuro Oncol*. 2016; 18(11):1529-1537.
20. Van Den Bent MJ, Erridge S, Vogelbaum MA, et al. Second interim and first molecular analysis of the EORTC randomized phase III intergroup CATNON trial on concurrent and adjuvant temozolomide in anaplastic glioma without 1p/19q codeletion 2019. Located at: Journal of Clinical Oncology.
21. Klein J, Sato A. The HLA system. First of two parts. *N Engl J Med*. 2000; 343(10):702-709.
22. Aarli JA, Mørk SJ, Myrseth E, Larsen JL. Glioblastoma associated with multiple sclerosis: coincidence or induction? *Eur Neurol*. 1989; 29(6):312-316.
23. Currie S, Urich H. Concurrence of multiple sclerosis and glioma. *J Neurol Neurosurg Psychiatry*. 1974; 37(5):598-605.
24. Frisullo G, Patanella AK, Nociti V, et al. Glioblastoma in multiple sclerosis: a case report. *J Neurooncol*. 2009; 94(1):141-144.
25. Bunse L, Pusch S, Bunse T, et al. Suppression of antitumor T cell immunity by the oncometabolite (R)-2-hydroxyglutarate. *Nat Med*. 2018; 24(8):1192-1203.
26. Mildenerger I, Bunse L, Ochs K, Platten M. The promises of immunotherapy in gliomas. *Curr Opin Neurol*. 2017; 30(6):650-658.
27. Platten M, Bunse L, Riehl D, Bunse T, Ochs K, Wick W. Vaccine Strategies in Gliomas. *Curr Treat Options Neurol*. 2018; 20(5):11.

28. Hinnell C, Almekhlafi M, Joseph JT, Bell R, Sharma P, Furtado S. Concurrence of high-grade brainstem glioma and multiple sclerosis. *Can J Neurol Sci.* 2010; 37(4):512-514.
29. Dobson R, Giovannoni G. Multiple sclerosis - a review. *Eur J Neurol.* 2019; 26(1):27-40.
30. Green AJ, Bollen AW, Berger MS, Oksenberg JR, Hauser SL. Multiple sclerosis and oligodendroglioma. *Mult Scler.* 2001; 7(4):269-273.
31. Tabatabaei P, Visse E, Bergström P, Brännström T, Siesjö P, Bergenheim AT. Radiotherapy induces an immediate inflammatory reaction in malignant glioma: a clinical microdialysis study. *J Neurooncol.* 2017; 131(1):83-92.
32. Reznik E, Smith AW, Taube S, et al. Radiation and Immunotherapy in High-grade Gliomas: Where Do We Stand? *Am J Clin Oncol.* 2018; 41(2):197-212.

Figure Legends

Figure 1 Consort flow diagram of the multicenter study

Figure 2 Clinical and radiological characteristics of 19 patients with multiple sclerosis and concurrent glioma.

A+B Scatter dot plot of patients' age at initial histologically proven diagnosis of glioma depending on the mutation status of isocitrate dehydrogenase-1 (IDH) in patients with concurrent multiple sclerosis (MS) or control patients without multiple sclerosis (ctl) (**A**), and patients' age at initial multiple sclerosis diagnosis depending on tumoral IDH mutation status (**B**). Depicted are single and mean values with SEM.

C Chronology of multiple sclerosis and glioma diagnosis depending on tumor histology judged by IDH mutation status.

D Schematic representation of glioma location in patients with concurrent multiple sclerosis depending on tumoral IDH mutation status. Dots represent single patients.

E MRI with axial FLAIR and contrast-enhanced T1 images of a patient with multiple sclerosis and concurrent IDH-mutant astrocytoma WHO grade II (p02, upper row) and of a patient with multiple sclerosis and IDH-wildtype glioblastoma WHO grade IV (p08, lower row).

F Schematic representation of the spatial relation of multiple sclerosis lesions and IDH-mutant astrocytomas (red) or IDH-wildtype glioblastomas (blue) in patients with concurrent diseases.

Figure 3 Clinical course of brain tumor disease in patients with glioma and concurrent multiple sclerosis

A Percentage of patients with or without glioma-caused neurological symptoms leading to initial tumor diagnosis in patients with concurrent multiple sclerosis (MS) or matched controls (ctl) depending on tumoral IDH mutation status.

B Time between radiological tumor suspicion and subsequent histological diagnosis.

C Tumor size as detected by MRI at the time of histological diagnosis in patients with concurrent multiple sclerosis or matched controls depending on tumoral IDH mutation status. Displayed are the products of the two largest perpendicular diameters (cm²) in axial

FLAIR or contrast-enhanced T1 images for IDH-mutant astrocytomas WHO grade II and IDH-wildtype glioblastomas, respectively.

D Percentage of patients receiving tumor biopsy, partial, or complete resection.

E Type of adjuvant tumor therapy depending on concurrent multiple sclerosis diagnosis and IDH mutation status.

F Kaplan–Meier analysis of progression-free survival (PFS) after primary tumor treatment depending on IDH status and concurrent multiple sclerosis diagnosis

Figure 4 Association between radiotherapy and multiple sclerosis disease activity

A Percentage of patients with or without radiotherapy (RT) treatment during the course of brain tumor disease depending on concurrent multiple sclerosis (MS) diagnosis and tumoral IDH mutation status.

B Percentage of patients with or without clinical or radiological multiple sclerosis disease activity in the 12 months preceding (left bar) and after RT (right bar).

C Scatter dot plot of the number of clinical episodes per patient for six multiple sclerosis patients in the 12 months preceding and after RT. Depicted are single and mean values with SEM.

D Time course of cumulative clinical multiple sclerosis episodes for five multiple sclerosis patients experiencing disease activity in the 12 months after RT.

E MRI with axial FLAIR images of two patients showing new demyelinating lesions (arrows) after RT within the 50% isodose line (p02 photon irradiation 60/2Gy; p47 proton irradiation 54/1.8Gy).

Figure 5 Long-term response after radiation-induced pseudoprogression

Representation of isodoses (Gy) and longitudinal MRIs with axial FLAIR images (left column) and contrast-enhanced axial T1 images (right column) of a patient (p08) with IDH-wildtype glioblastoma WHO grade IV. Transient contrast enhancement within the tumor area corresponding to radiation-induced pseudoprogression with a maximum of 8 months after completion of radiotherapy (60/2Gy) is associated with an increase in subcortical multiple sclerosis lesions (arrows) and the initial diagnosis of a chronic progressive multiple sclerosis course. Long term follow-up shows a moderate generalized brain atrophy (stars) without evidence of glioblastoma recurrence up to 8 years after initial tumor therapy.

Figure 6 Genome-wide DNA methylation changes between gliomas of patients with concurrent multiple sclerosis and controls

A Unsupervised hierarchical clustering of methylation profiles from 850k methylation array data of 12 glioma tissue in multiple sclerosis (MS) patients and matched controls.

B Circos plot showing DMR between patients with and without multiple sclerosis separately for IDH^{mut} (inner two circles) and IDH^{wt} tumors (outer two circles) on each of the human chromosomes with a zoom in on chromosome 6. The inner circle of the respective comparisons show the average methylation, the outer circle the area of the DMR.

Figures

Figure 1 Consort flow diagram of the multicenter study

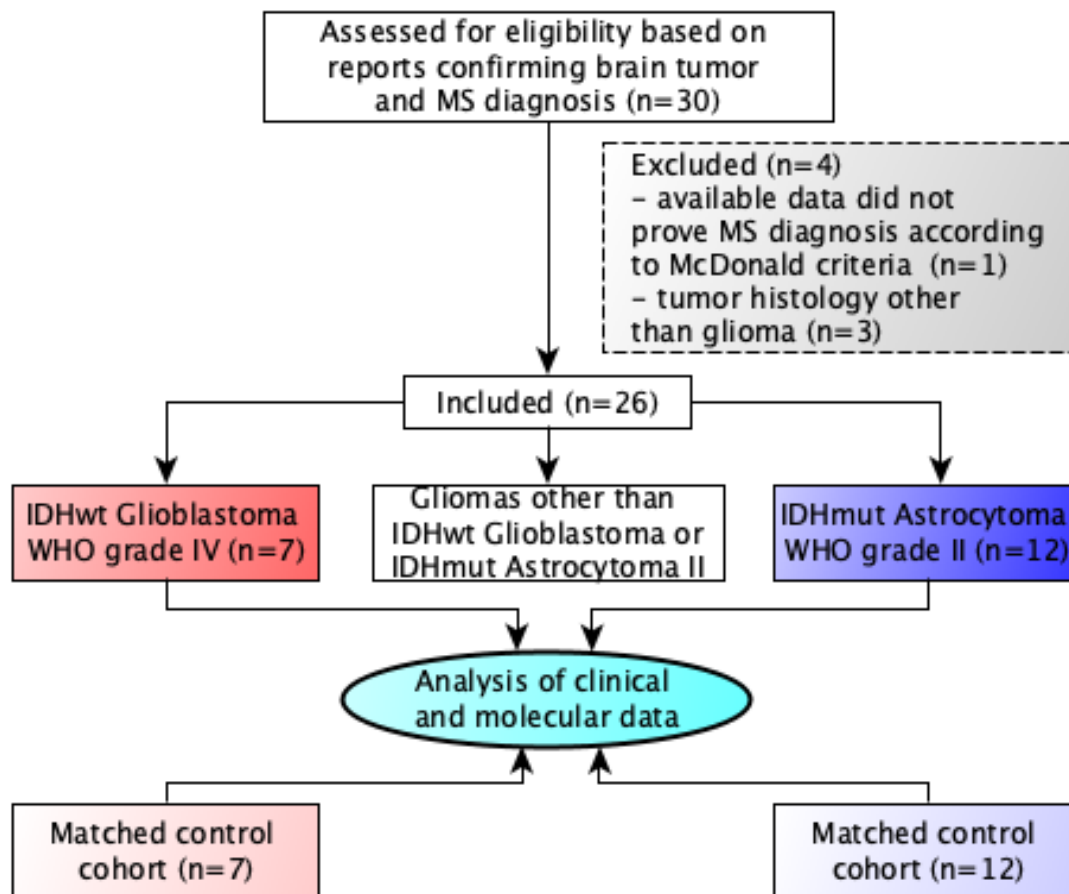


Figure 2 Clinical and radiological characteristics of 19 patients with multiple sclerosis and concurrent glioma

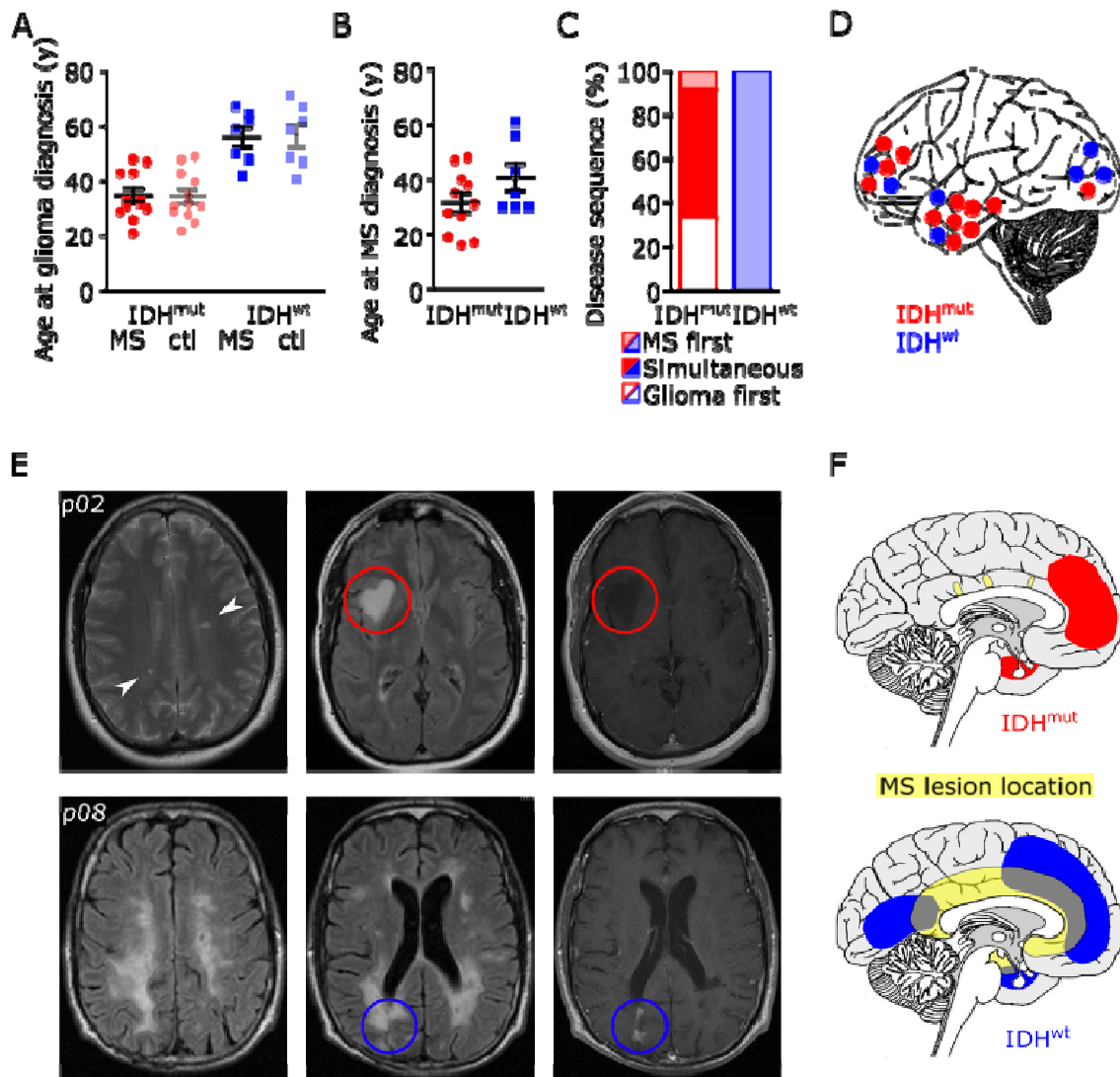


Figure 3 Clinical course of brain tumor disease in patients with glioma and concurrent multiple sclerosis

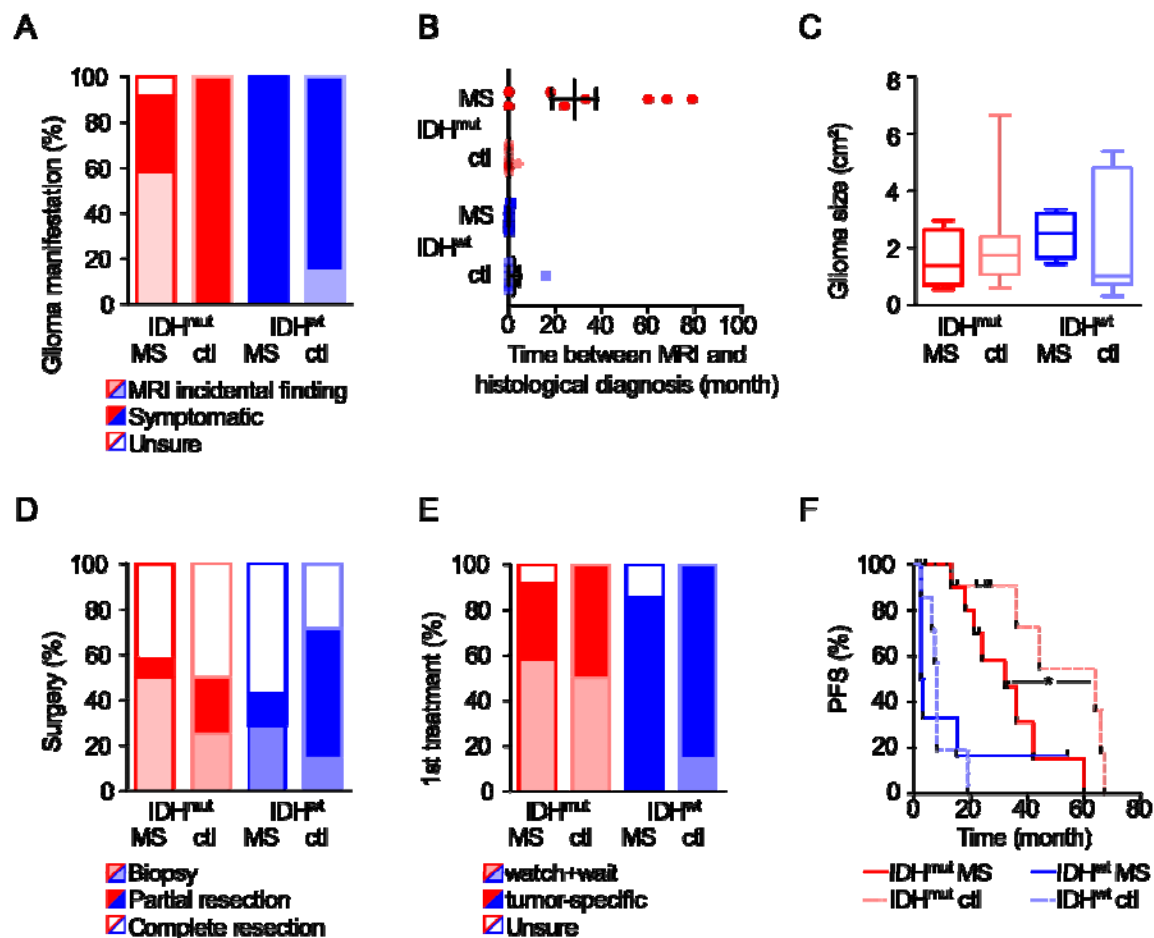


Figure 4 Association between radiotherapy and multiple sclerosis disease activity

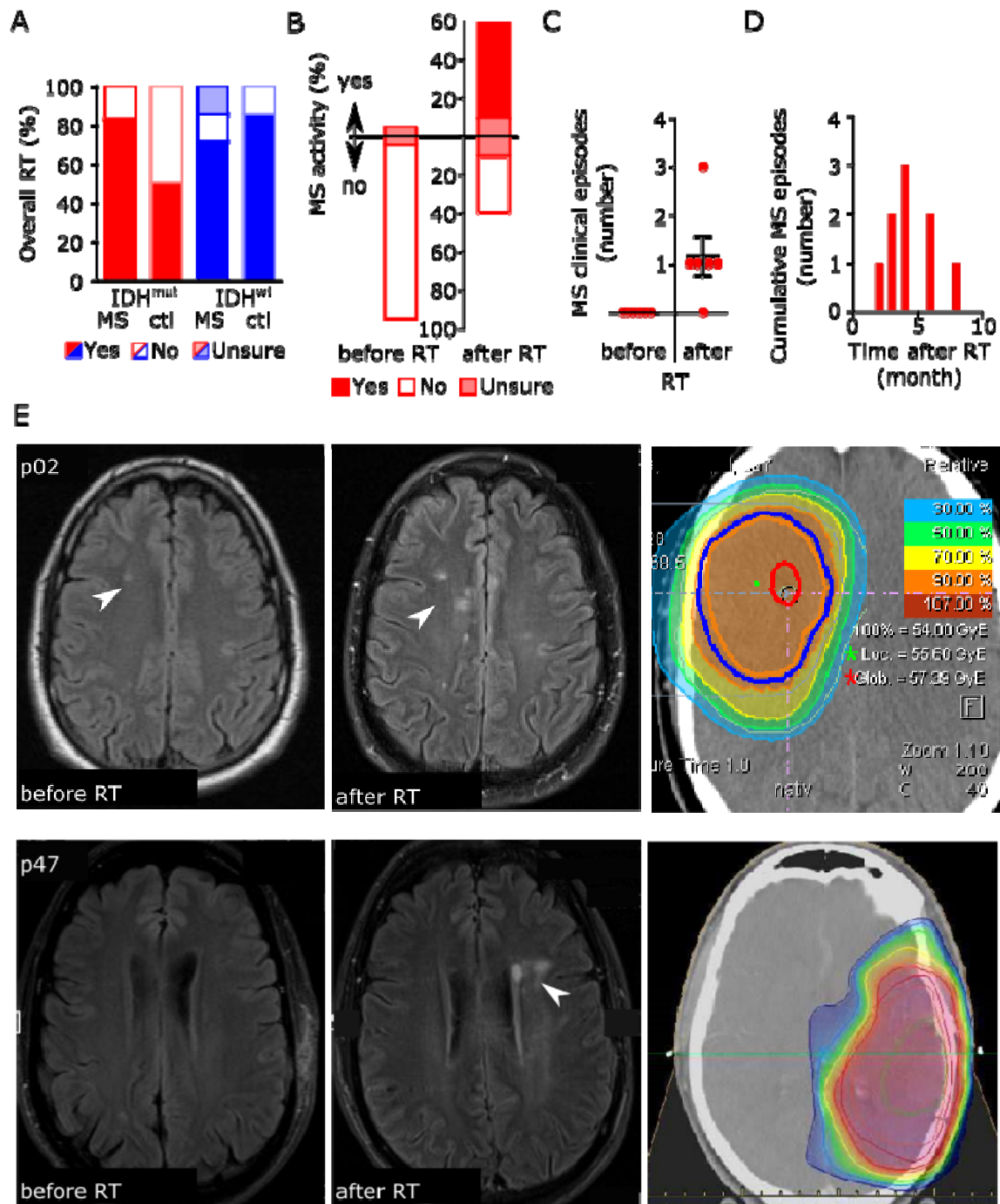


Figure 5 Long-term response after radiation-induced pseudoprogression

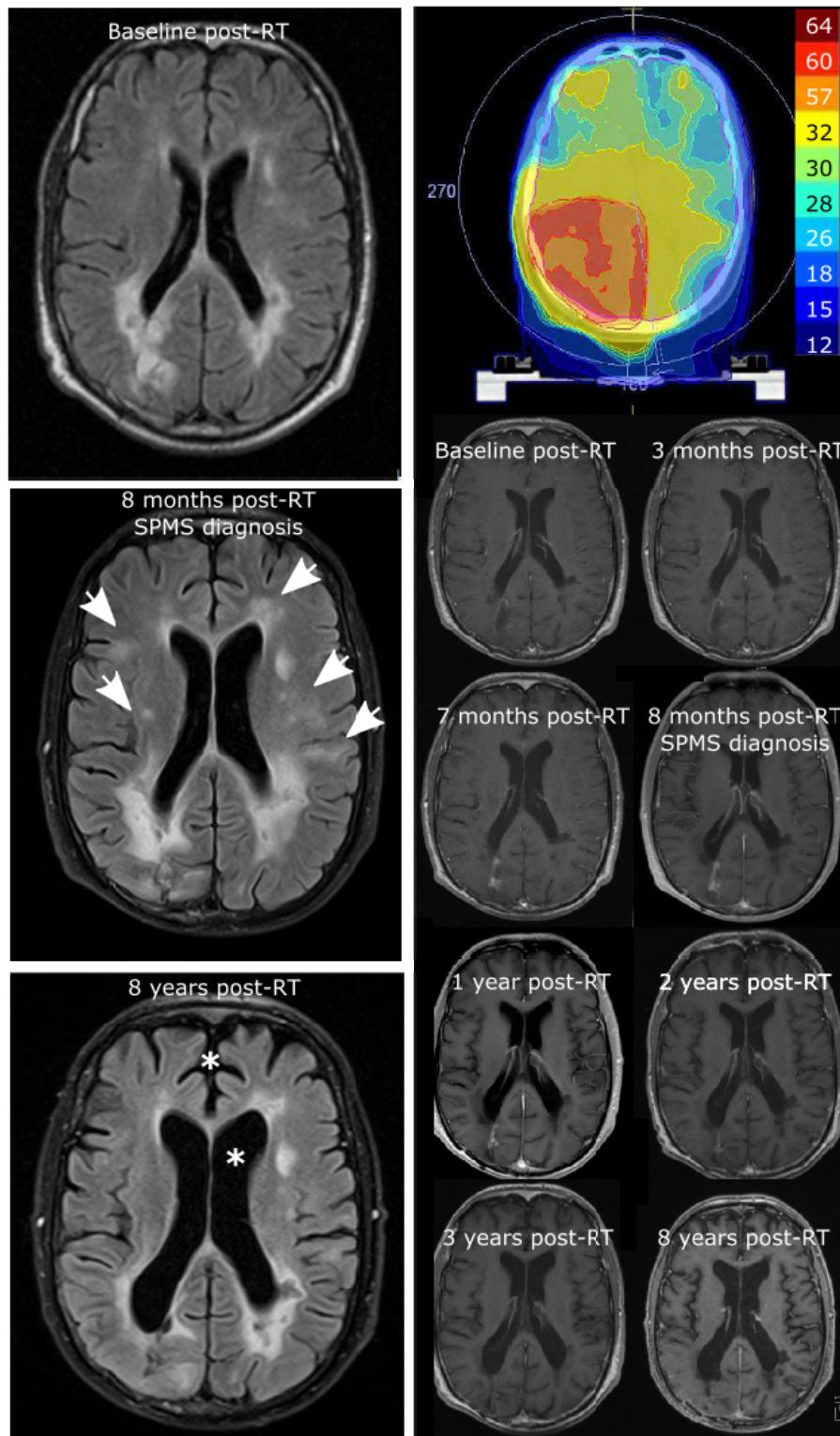
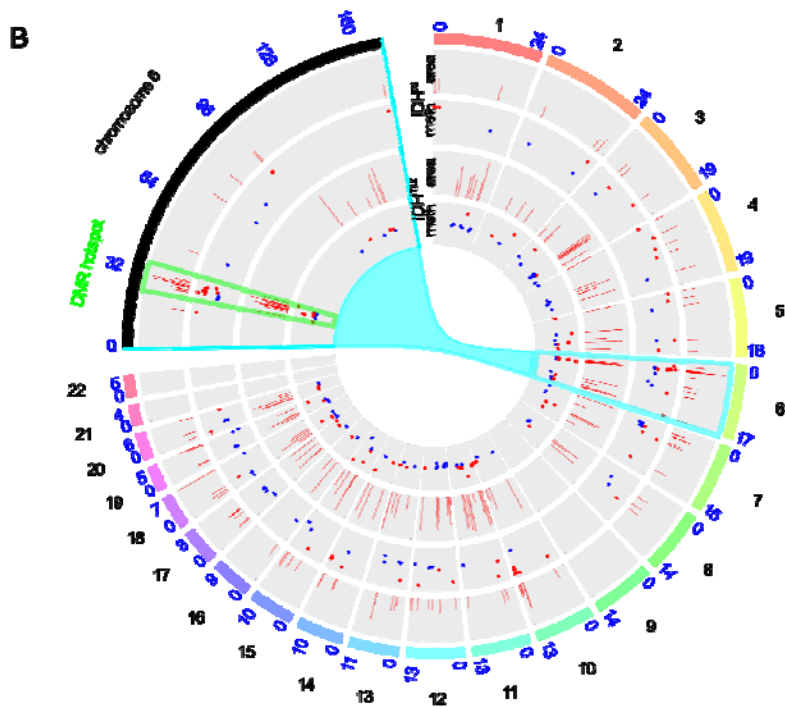
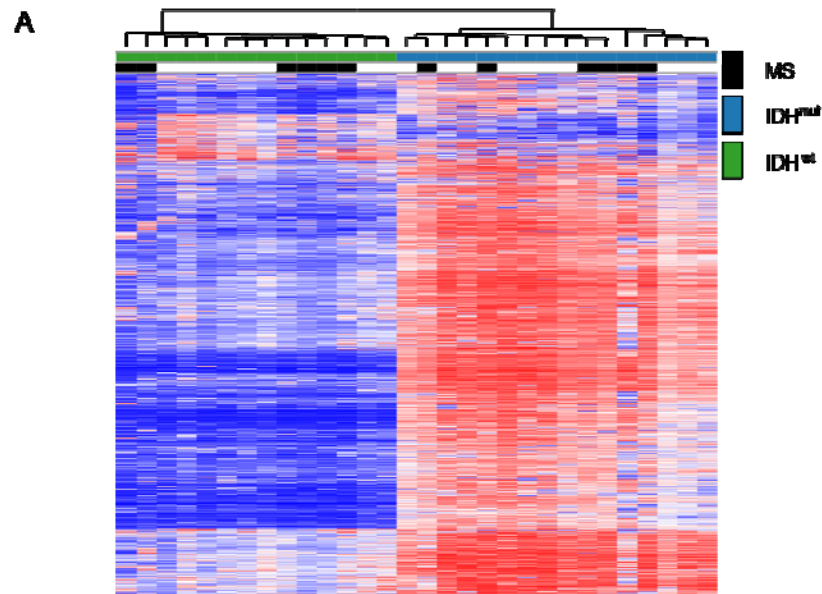
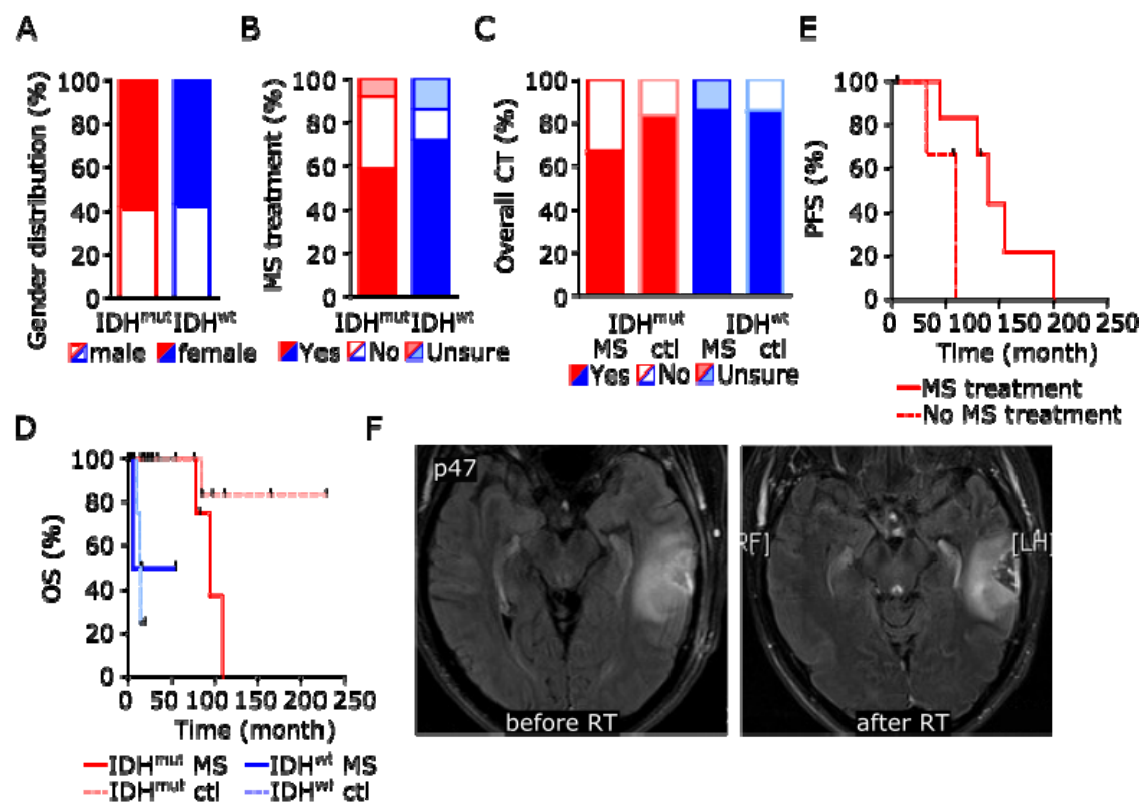


Figure 6 Genome-wide DNA methylation changes between gliomas of patients with concurrent multiple sclerosis and controls



Supplementary Material

Supplementary Figure 1



Clinical and radiological characteristics of 19 patients with multiple sclerosis and concurrent glioma.

A Gender distribution of patient and control cohorts.

B Percentage of patients with and without disease-modifying treatment during the course of MS depending on tumoral IDH mutation status.

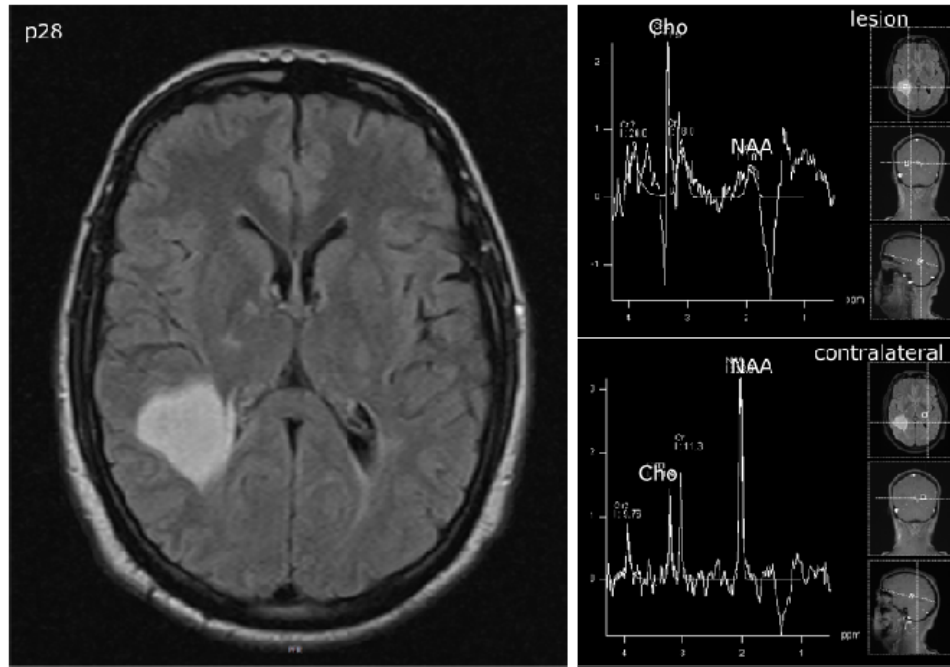
C Percentage of patients with and without chemotherapy (CT) treatment during the course of brain tumor disease depending on concurrent MS diagnosis and tumoral IDH mutation status.

D Kaplan–Meier analysis of progression-free survival (PFS) of patients with IDH mutant astrocytoma and concurrent multiple sclerosis after primary tumor treatment depending on immunomodulatory therapy.

E Kaplan–Meier analysis of overall survival (OS) after primary tumor treatment depending on IDH status and concurrent multiple sclerosis diagnosis.

F MRI with axial FLAIR images of patient p47 showing the tumoral lesion before and after RT with stable disease according to RANO criteria.

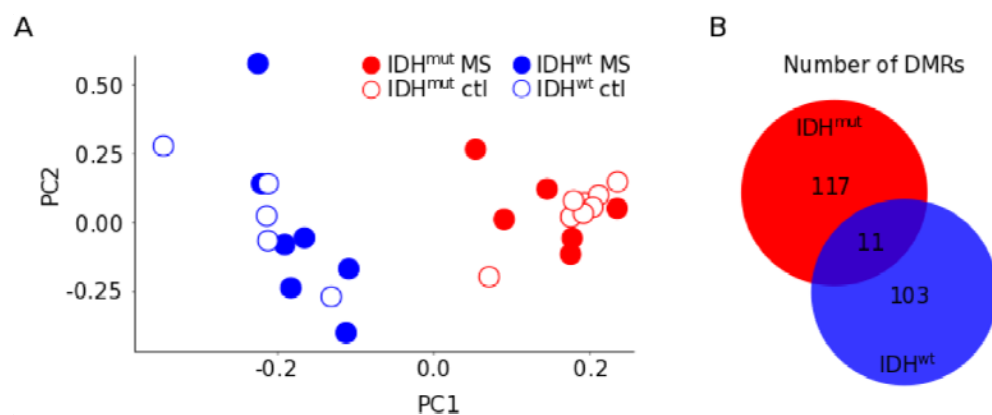
Supplementary Figure 2



MRI spectroscopy

MRI scan of multiple sclerosis patient p28 with axial FLAIR images and spectroscopy demonstrating choline-increase and N-acetyl-aspartate decrease in an IDH-mutant astrocytoma WHO grade II.

Supplementary Figure 3



Genome-wide DNA methylation changes of gliomas in patients with concurrent multiple sclerosis

A Principal component analysis.

B Schematic representation of numbers of differentially methylated regions (DMRs) in gliomas compared between patients with concurrent multiple sclerosis and control patients without multiple sclerosis depending on tumoral IDH mutation status.

Supplementary Table 1 Patient characteristics (n=26)

Characteristic	Number of patients (%)
Male	10 (38%)
Median age at tumor diagnosis (y)	42 (15–67)
Tumor histology	
Astrocytoma	26 (100%)
Oligodendroglioma	0 (0%)
Tumor WHO grade	
I	3 (12%)
II	14 (54%)
III	2 (8%)
IV	7 (27%)
IDH1 mutation status	
Wildtype	8 (31%)
Mutant	12 (46%)
Unsure	6 (23%)
MGMT promotor status	
Hypermethylated	13 (50%)
Hypomethylated	4 (15%)
Unsure	9 (35%)
Tumor location	
Frontal	7 (27%)
Temporal	12 (44%)
Parietal	1 (4%)
Occipital	4 (15%)
Brainstem	1 (4%)
Cerebellar	1 (4%)
Surgery	
Biopsy	14 (54%)
Partial resection	2 (8%)
Complete resection	10 (38%)
Overall tumor-specific therapy	
Radiotherapy	19 (73%)
Chemotherapy	18 (69%)
Median age at MS diagnosis (y)	
	33 (16–61)
MS symptom course	
Relapsing remitting MS	19 (73%)
Primary progressive MS	0 (0%)
Secondary progressive MS	4 (15%)
Inflammatory lesion location	
Optic neuritis	7 (27%)
Cerebral	26 (100%)
Spinal	6 (23%)
Overall immunomodulatory therapy	
Yes	15 (58%)

No	5 (19%)
Unsure	6 (23%)

Supplementary Table 2 Glioma risk in patients with multiple sclerosis

Study cohort	Total number of patients	Number of patients with MS (%)	Odds ratio (95% CI)
Glioma Heidelberg	2809	12 (0.4)	
Glioma CPRD*	3112	9 (0.3)	1.48 (0.62 – 3.52)
Control CPRD*	31120	85 (0.3)	1.57 (0.86 – 2.87)

Glioma risk among MS patients of the Glioma Heidelberg cohort was compared to risks of Glioma CPRD and Control CPRD cohorts previously published (*Anssar *et al.*, 2020); 1:10 matched case-control study within the CPRD (Clinical Practice Research Datalink)).

Supplementary Table 3 Characteristics of patients with IDH1-wildtype glioblastoma WHO grade IV

Characteristic	Number of MS patients (%) n=7 (100%)	Number of ctl patients (%) n=7 (100%)
Male	3 (43%)	4 (57%)
Median age at tumor diagnosis (y)	59 (42–67)	59 (41–71)
Glioblastoma manifestation		
New symptoms	6 (86%)	6 (86%)
MRI incidental finding	0 (0%)	1 (14%)
Unsure	1 (14%)	0 (0%)
Tumor location		
Frontal	2 (29%)	2 (29%)
Temporal	2 (29%)	1 (14%)
Parietal	0 (0%)	2 (29%)
Occipital	3 (43%)	2 (29%)
Brainstem	0 (0%)	0 (0%)
Cerebellar	0 (0%)	0 (0%)
Surgery		
Biopsy	2 (29%)	1 (14%)
Partial resection	1 (14%)	4 (57%)
Complete resection	4 (57%)	2 (29%)
MGMT promotor status		
Hypermethylated	1 (14%)	2 (29%)
Hypomethylated	4 (57%)	4 (57%)
Unsure	2 (29%)	1 (14%)
1 st treatment		
Best supportive care	0 (0%)	1 (14%)
Radiotherapy only	1 (14%)	0 (0%)
Chemotherapy only	1 (14%)	0 (0%)
Radiochemotherapy	5 (71%)	6 (86%)
Median PFS (month)	2.5	8

Supplementary Table 4 Characteristics of patients with IDH1-mutant astrocytoma WHO grade II

Characteristic	Number of MS patients (%) n=12 (100%)	Number of ctl patients (%) n=12 (100%)
Male	5 (42%)	8 (67%)
Median age at tumor diagnosis (y)	32.5 (21–48)	31.5 (22–49)
Tumor manifestation		
Symptomatic	4 (33%)	12 (100%)
MRI incidental finding	7 (58%)	0 (0%)
Unsure	1 (8%)	0 (0%)
Tumor location		
Frontal	4 (33%)	9 (75%)
Temporal	7 (58%)	3 (25%)
Parietal	0 (0%)	0 (0%)
Occipital	1 (8%)	0 (0%)
Brainstem	0 (0%)	0 (0%)
Cerebellar	0 (0%)	0 (0%)
Surgery		
Biopsy	6 (50%)	3 (25%)
Partial resection	1 (8%)	3 (25%)
Complete resection	5 (42%)	6 (50%)
1 st treatment		
Watch + wait	7 (58%)	6 (50%)
Radiotherapy	3 (25%)	3 (25%)
Chemotherapy	2 (17%)	5 (42%)
Unsure	1 (8%)	0 (0%)
Median PFS (month)	32	64

Supplementary Table 5: Multiple sclerosis course

	IDH-mutant, WHO grade II	IDH-wildtype, WHO grade IV
Mean age at MS manifestation (y)	31 (16–47)	unsure
Mean age at MS diagnosis (y)	31 (16–48)	40 (30–61)
Disease sequence		
Glioma first	4 (33%)	0 (0%)
Simultaneous	6 (50%)	0 (0%)
MS first	1 (8%)	7 (100%)
median time between MS and tumor diagnosis (y)	0 (-7–13)	13 (1–34)
Cerebral inflammatory lesions	12 (100%)	7 (100%)
Overall immunomodulatory therapy		
Yes	7 (58%)	3 (43%)
No	4 (33%)	1 (14%)
Unsure	1 (8%)	3 (43%)

Overall RT	10 (83%)	5 (71%)
MS progression in the 12 months preceding RT	0 (0%)	0 (0%)
MS progression in the 12 months after RT	5 (42%)* **	1 (20%)*
Overall CT	8 (67%)	6 (86%)
MS progression in the 12 months preceding CT	0 (0%)	0 (0%)
MS progression in the 12 months after CT	1 (12%)*	1 (17%)*

* combined RCT, ** three (60%) with immunomodulatory treatment

Supplementary Table 6 Common differentially methylated regions (DMR)

Genetic region	Annotated gene	Immune-related function
3q24	ZIC4	
4q23	EIF4E	Regulation of immune function
5q31.3	TMCO6	Interleukin region
5q31.3	PCDHB3	Interleukin region
5q35.1	DUSP1	Autoimmune disease risk
5p15.33	C5orf38	
6p22.1	RNF39	HLA region
6p21.32	PRRT1	HLA region
10p12.1	MKX	
12p13.1	GPR19	
18p11.21	CIDEA	