Improved Multiple Sclerosis Lesion Detection using an Intelligent Automation Software

Christian Federau[1,2,*], Nicolin Hainc[2,3], Myriam Edjlali[4,5], Guangming Zhu[6], Milica Mastilovic[4,7], Nathalie Nierobisch[2,3], Jan-Philipp Uhlemann[2,3], Silvio Paganucci[1], Cristina Granziera[8], Olivier Heinzlef[9,10], Lucas B. Kipp[11], Max Wintermark[5,12]

[1] AI Medical AG, Zollikon, Switzerland
[2] University of Zürich, Zürich, Switzerland
[3] Department of Neuroradiology, Clinical Neuroscience Center, University Hospital Zurich, University of Zurich, Zurich, Switzerland
[4] Department of Radiology, APHP, Hôpitaux Raymond-Poincaré & Ambroise Paré, DMU Smart Imaging, GH Université Paris-Saclay, U 1179 UVSQ/Paris-Saclay, Paris, France
[5] Laboratoire d'imagerie Biomédicale Multimodale (BioMaps), Université Paris-Saclay, CEA, CNRS, Inserm, Service Hopsitalier Frédéric Joliot, Orsay, France.
[6] Stanford University, Stanford, USA
[7] Faculty of Medicine, University of Novi Sad, Novi Sad, Serbia
[8] University Hospital Basel and University of Basel, Basel, Switzerland
[9] Department of Neurology, Poissy-Saint-Germain-en-Laye Hospital, Poissy, France
[10] CRC SEP IDF Ouest, Poissy-Garches, France
[11] Department of Neurology & Neurological Sciences, Stanford University School of Medicine, Stanford, CA, USA
[12] MD Anderson Cancer Center, Houston, USA

*Corresponding Author: Christian Federau, AI Medical AG, Goldhaldenstr 22a, 8702 Zollikon, Switzerland. <surname> at ai-medical.ch

Abstract

Introduction

The assessment of multiple sclerosis (MS) lesions on follow-up magnetic resonance imaging (MRI) is tedious, time-consuming, and error-prone. Automation of low-level tasks could enhance the radiologist in this work. We evaluate the intelligent automation software Jazz in a blinded three centers study, for the assessment of new, slowly expanding, and contrast-enhancing MS lesions

Methods

In three separate centers, 117 MS follow-up MRIs were blindly analyzed on FLuid Attenuated Inversion Recovery (FLAIR), pre- and post-Gadolinium T1-weighted images using Jazz by 2 neuroradiologists in each center. The reading time was recorded. The ground truth was defined in a second reading by side-by-side comparison of both reports from Jazz and the standard clinical report. The number of described new, slowly expanding, and contrast-enhancing lesions described with Jazz was compared to the lesions described in the standard clinical report.

Results

A total of 96 new lesions from 41 patients and 162 slowly expanding lesions (SELs) from 61 patients were described in the ground truth reading. A significantly larger number of new lesions were described using Jazz compared to the standard clinical report (63 versus 24). No SELs were reported in the standard clinical report, while 95 SELs were reported on average using Jazz. A total of 4 new contrast-enhancing lesions were found in all reports. The reading with Jazz was very time efficient, taking on average 2min33sec $\pm$ 1min0sec per case. Overall inter-reader agreement for new lesions between the readers using Jazz was moderate for new lesions (Cohen kappa=0.5) and slight for SELs (0.08).

Discussion

The quality and the productivity of neuroradiological reading of MS follow-up MRI scans can be significantly improved using a dedicated software such as Jazz.

56 **Introduction**

57 Multiple sclerosis (MS) is an autoimmune, potentially disabling demyelinating disease of the
58 central nervous system (CNS), with clinical onset typically in the young adult. [1] Traditionally, MS
59 progression have been categorized in three main type, Primary-Progressive MS (PPMS) affecting
60 between 10 and 15 % of MS patients, Relapsing-Remitting MS (RRMS) and Secondary-Progressive
61 MS (SPMS), [1] although it has been recently suggested that the clinical course of MS is better
62 described as a continuum, with contributions from concurrent pathophysiological processes that
63 vary across individuals and over time. [2] Prior to the availability of the disease-modifying
64 therapies, roughly 50% of patients diagnosed with RRMS would transition to SPMS within 10
65 years, and 90% would transition within 25 years, with a median time of about 19 years. [3] The
66 diagnosis of SPMS is most often established retrospectively, [4] on average 3 years after the actual
67 progression started. [5]

68

69 This is caused by the difficulties by the clinicians and the patients to interpret the initial symptoms
70 indicating early progression, which they can be subtle and fluctuating, [4] and by the difficulties to
71 detect disease progression on imaging. The importance of detecting remaining inflammatory
72 disease earlier and more systematically has further increased with the demonstration that early
73 intervention with high-efficacy disease modifying therapies can delay the onset of SPMS, [6] and
74 with the recent availability of approved new therapies for progressive MS, such as the anti-CD20
75 monoclonal antibody Ocrelizumab [7] or the selective sphingosine-1-phosphate receptor
76 modulator Siponimod. [8]

77

78 MS disease monitoring with imaging is particularly challenging. It involves at least yearly follow-
79 up magnetic resonance imaging (MRI) scans of their central nervous system, and consists of the
80 tedious, time-consuming, and error-prone manual comparison and counting of the multiple
81 demyelinating lesions. Given time constraints and the fact lesion burden can reach hundreds in
82 severe cases, neuroradiologists can be forced to grossly compare the lesion load, and relevant
83 disease evolution might remain unnoticed for some time. Longitudinal subtraction maps have
84 been used to increase sensitivity for detecting new or enlarged lesions multiple sclerosis lesions[9–

[12] and reduce reading time[13], but small lesions might be difficult to detect using this technique. [14]

Fully automated neuroradiological reporting of MS lesion load evolution would be of great interest, but current methods, including deep learning methods, have currently limited practicality given they are far from error free. In the last decade, deep learning methods, in particular two-dimensional and three-dimensional convolutional neural networks, have been applied to develop automatic lesion detection and segmentation. [15] Reported lesion-wise true positive rate ranges between 0.15 and 0.57, and the lesion-wise false positive rate ranges between 0.08 and 0.68. [16–25] Those numbers are relatively low, given that every single new or evolving lesion on a follow-up control can be considered a marker of disease progression requiring a re-evaluation of the patient's current therapy, and therefore, the expert radiologist assessment is still required for every patient. [26]

In this context, a tool based on intelligent automation, which could simplify the work of the radiologist by automating many repetitive tasks, would be of interest. Intelligent automation aims to streamline processes to improve efficiency and reduce errors. [27] It applies the concept of breaking larger complex tasks into several simpler, very-well-understood low-level steps, and automatizes the low-level steps with intelligent software, using artificial intelligence and advanced software engineering. By freeing the radiologist to concentrate on the lesion assessment, it could reduce the number of missed lesions. Intelligent automation promises to improve productivity, reduce costs, as well as more precise processes and a better user experience. Jazz [28] is an intelligent automation software dedicated for neuroradiology, that automates multiple low-level tasks such as contrast recognition, previous exams organization, and images coregistration. It includes a semi-automatic lesion annotation tool, permitting the user to easily save all relevant information in a lesion list, and has a graphical user interface intended to maximize productivity and to minimize operator fatigue and discomfort. (**Figure 1)**

In this retrospective study, we evaluate Jazz for the assessment of new, expanding, and contrast-enhancing MS lesions, blindly in three centers, and compared the reported lesions with the lesions described in the standard clinical report.

Methods

The following analysis was performed in three separate centers in a fully blinded and independent manner.

Dataset

A set of 120 (40 from each of the 3 centers) current and prior magnetic resonance examinations of patients diagnosed with MS were obtained. 3D FLAIR, pre- and post-Gadolinium T1-weighted 3D sequences, as well as the corresponding clinical report, were analyzed. (**Table 1**) All data were anonymized.

Case Reading using Jazz

The cases were loaded in Jazz. In a pre-processing step, Jazz automatically coregistered the images to one another using an affine transformation and labelled their contrast. The reader used then Jazz user interface to switch between the coregistered exams and contrasts using single-click operations or using the corresponding keyboard short-cut to evaluate the lesions. If necessary, the reader used the lesion locking tool to evaluate the lesion in different planes. When the user detected a new, SEL, or contrast-enhancing lesion, the reader used Jazz lesion annotation tool, which permits marking of observed lesions with a single click, wherein the software automatically recognized the anatomical lesion location, and used if necessary the interactive lesion list with picker menus to correct the lesion description if necessary. (**Figure 1**)

In each center, two neuroradiologists evaluated independently all 40 cases using the Jazz software (center 1 __Blinded for Review__, 12 years of experience, and __ Blinded for Review__, 8 years of experience, center 2, __Blinded for Review__, 15 years of experience, and __ Blinded

for Review__, 2 years of experience, center 3 __Blinded for Review__, 5 years of experience, and __ Blinded for Review__, 3 years of experience). The new lesions and the slowly expanding lesions (SELs) were assessed on the 3D FLAIR. New lesions were defined as non-preexisting white matter lesions on the previous exam, visible on the current exam, while SELs were defined as preexisting white matter lesions that demonstrate lesions expansion between previous and current exam. The contrast-enhancing lesions were assessed by comparing the pre- and post-GAD T1-weighted 3D sequences. Reading time was recorded.

Ground Truth

A ground truth was defined by reevaluating, using side-by-side comparison, all lesions described in the standard clinical reports and the reports generated by Jazz. The ground truth reading was done by either the most experienced reader of both readers (in two centers), or by a third experienced reader (third center, __Blinded for Review__, 8 years of experience). Reported new lesions, SELs, and contrast-enhancing lesions in each report were then counted, and classified as true positive, false negative, or false positive.

Statistical Analysis

Statistical significance was assessed using the Mann-Whitney U test between the average reading time with Jazz and generating the standard report. Significance level was set to $\alpha < 0.05$. Inter-reader agreement between the readers using Jazz was assessed using Cohen's Kappa.

Results

Patient Population

39 cases were included from center 1 (mean age 55.5 $\pm$ 10.6 y, median age 57 y, age range 25-72 y, female / male = 30 / 9; one case was excluded because the lesions were very confluent, rendering the comparison of separate lesions difficult). 40 cases were included from center 2 (mean age 48.3 $\pm$ 12.8 y, median age 45 y, age range 26-73 y, female / male = 31 / 9). 38 cases were included from center 3 (mean age 35.4 $\pm$ 9.8 y, median age 34 y, age range 20-64 y, female / male = 20 / 18; one case was excluded because the follow-up MRI was done for hydrocephalus

evaluation without dedicated description of the MS lesions, and one case was excluded because the 3D FLAIR was missing in one of the exams).

Reading time

Reading time using Jazz took on average 2 min 33 sec ± 1 min 0 sec per case for all readers (**Figure 2**). In center 1, reading using Jazz took 2 min 29 sec ± 2 min 15 sec per case for reader 1, and 1 min 45 sec ± 51 sec for reader 2. In center 2, reading using Jazz took 4 min 30 sec ± 2 min 42 sec per case for reader 1, and 2 min 33 sec ± 1 min 12 sec for reader 2. In center 3, reading using Jazz took 2 min 12 sec ± 1 min 7 sec per case for reader 1, and 1 min 51 sec ± 1 min 4 sec for reader 2.

New Lesions on 3D FLAIR

In all three centers, the ground truth reading reported an average of 0.83 ± 0.08 new lesions per case (a total of 96 lesions from 41 patients, out of a total of 117 patients). The standard clinical reports reported 24 true positive new lesions from 13 patients, 72 false negative, and 5 false positive new lesions. The Jazz report reported on average (average of 2 readers) 63 true positive lesions from 30.5 patients, 33 false negative, and 18 false positive new lesions ($p < 0.05$; **Table 1 and Figure 3**).

Slowly Expanding Lesions on 3D FLAIR

In all three centers, the ground truth reading reported an average of 1.39 ± 0.72 SELs per case (a total of 162 lesions from 61 patients, out of a total of 117 patients). The standard clinical reports reported no growing lesions at any center. The Jazz reports reported on average (average of 2 readers) 95 true positive growing lesions from 45 patients, 67 false negative, and 38.5 false positive SELs ($p < 0.05$; **Table 2 and Figure 4**).

Contrast-enhancing Lesions

In center 1, all patients were administered intravenous contrast, and no contrast-enhancing lesions were described in any report. In center 2, 11 patients were not administered intravenous

contrast; in the remaining 29 patients, 4 new contrast-enhancing lesions were described, consistently in all reports, and 1 false positive contrast-enhancing lesion was described on the standard clinical report only. In center 3, all patients except one were administered intravenous contrast; one contrast-enhancing lesion was described, consistently in all reports.

Inter-reader Agreement

Overall inter-reader agreement for new lesions between the readers using Jazz was moderate, with kappa = 0.5 (center 1: 0.45, center 2: 0.51, center 3: 0.54) and for SELs it was slight, with kappa = 0.08 (center 1: -0.3, center 2: 0.3, center 3: 0.22).

Statement

This study was approved by the Ethic committee of the Université Paris, of the Canton of Zürich (2022-00041) and of Stanford University (IRB-26147). All methods were carried out in accordance with relevant guidelines and regulations. Informed consent from the subjects was waived by the above-mentioned ethic committee. The datasets used and analyzed during the current study available from the corresponding author on reasonable request.

Discussion

This study shows that a significantly larger number of new and SELs are reported when using the intelligent automation software Jazz compared to the standard clinical reporting method in a time efficient manner, by allowing the neuroradiologist to concentrate on the detection and evaluation of lesions. By permitting to toggle between coregistered current and previous exams, it uses a particularly potent neurophysiological mechanism to attract the attention of the reader to modifications in the images, in other words in the case of MS, to new and evolving lesions. Indeed, attention is a selective process and is physiologically necessary, because there are severe limits on our capacity to process visual information. [29] A theory suggests that attention is imposed by the fixed amount of overall energy available to the brain, and that because of the high-energy cost of neuronal activity, only a small fraction of the machinery can be engaged concurrently. [29]

229 As a consequence, stimuli have to compete for limited resources, [30] a notion that is supported by
230 electrophysiological, neuroimaging and behavioral studies. [31,32] Of the several visual stimuli that
231 are known to capture attention, the sudden appearance of a new object and the sudden changes
232 of an object are known to be particularly potent and to influence priority in visual search. [33–35]
233 This mechanism is exploited in the dynamic switching tool of Jazz, compared to a standard side-
234 by-side comparison method.
235
236 The identification of progression in MS is typically retrospective and based on clinical symptoms.
237 [36] Most clinical trials rely on an increase in Expanded Disability Status Scale score confirmed over
238 3 or 6 months to define disease progression, and might overestimate the accumulation of
239 permanent disability by up to 30%. [37] Given the profound burden of progressive MS and the
240 recent development of effective treatments for these patients, there is a need to establish
241 reliable and reproducible methods for identifying progression early in the disease course.
242 Neuroradiological MRI reports of MS are often sparse and not standardized, despite the
243 advantages of standardization of clinical data for MS monitoring being well recognized. [38]
244 Structured reports of MRI in patients with MS have been shown to provide more adequate
245 information for clinical decision making than nonstructured reports. [39] Improvement in the
246 digitization of real-world patient data could foster new insights into the epidemiology and
247 pathophysiology of the disease, and are ultimately necessary to achieve truthful personalized
248 patient care. [40]
249
250 This study also shows that at least one SEL was described in more than half of all patients, while
251 none were reported in the standard clinical reports. The inter-reader agreement was low though,
252 showing that this assessment remains particularly difficult and prone to subjectivity. The use of
253 objective criteria defining SELs might help to improve this aspect. SELs can be easily overlooked,
254 and are particularly difficult to detect in a standard DICOM viewer. There is substantial interest
255 in SELs as a potential marker of chronic but active MS lesions [41–43] which may have diagnostic,
256 prognostic and treatment implications. SELs were found to be more prevalent in patients with
257 primary progressive MS (PPMS) compared with patients with relapsing-remitting MS (RRMS). [42]

The proportion of SELs and their microstructural tissue abnormalities were associated with a higher risk of MS progression and secondary progressive MS (SPMS) conversion. [44] In SPMS, SELs were found to represent almost one-third of T2 lesions, associated with neurodegenerative MRI markers and related to clinical worsening. [45] Therefore the number and volume of SELs are a promising biomarker to predict a more active, progressive disease course and could become a new target for therapeutic intervention. This is particularly interesting, because recent advances in our understanding of the mechanisms that drive SELs have fueled optimism for improved treatment of this condition. [46] A robust tool to gather SELs on magnetic resonance images, such as the one described in this work, might help to detect patients with progressive disease earlier and more systematically.

This study suffers from several limitations. Only three centers were included, and our results may not generalize to other centers. The reading using the Jazz software was not under identical conditions to the reading employed to generate the standard report, which was done during the standard clinical routine and might have included more distracting events. The reading of the standard clinical reports included at least a first reading and a second reading through a supervisor, and discussion with, and comments from the referring clinicians might have occurred. The reading with the Jazz software only included a single reading from a single reader. The ground truth was not based on a consensus reading performed by the most experienced reader in each center, which might have biased the agreement. Current and previous exams could have been acquired on different scanners, which might be a cofounder in the SEL evaluation. Further, a previous definition of SELs was based on the inclusion of a least three time points over more than two years, [42] with local expansion assessed by the Jacobian determinant of the deformation between reference and follow-up scans, and a heuristic scored was used to favor individual SEL candidates undergoing concentric and constant change, [42] while here, a more pragmatic approach was considered, using the subjective expansion assessment based on only two MR time points. Finally, no standardized method was used to define the SELs, as the evaluation was left to the subjective appraisal of each reader.

In conclusion, this study shows that significantly more new lesions and SELs can be described in a time-efficient manner using the intelligent automation software Jazz compared to the standard method.

Tables

	Ground Truth	Jazz Reader 1	Jazz Reader 2	Jazz Reader Average	Standard Clinical Report
Center 1	12	5	12	8.5	3
Center 2	11	9	10	9.5	4
Center 3	18	13	12	12.5	6
Total	**41**	**27**	**34**	**30.5**	**13**

Table 1. Number of patients with true positive new lesions.

	Ground Truth	Jazz Reader 1	Jazz Reader 2	Jazz Reader Average	Standard Clinical Report
Center 1	13	12	5	8.5	0
Center 2	29	27	19	23	0
Center 3	19	18	9	13.5	0
Total	**61**	**57**	**33**	**45**	**0**

Table 2. Number of patients with true positive SELs.

Figures

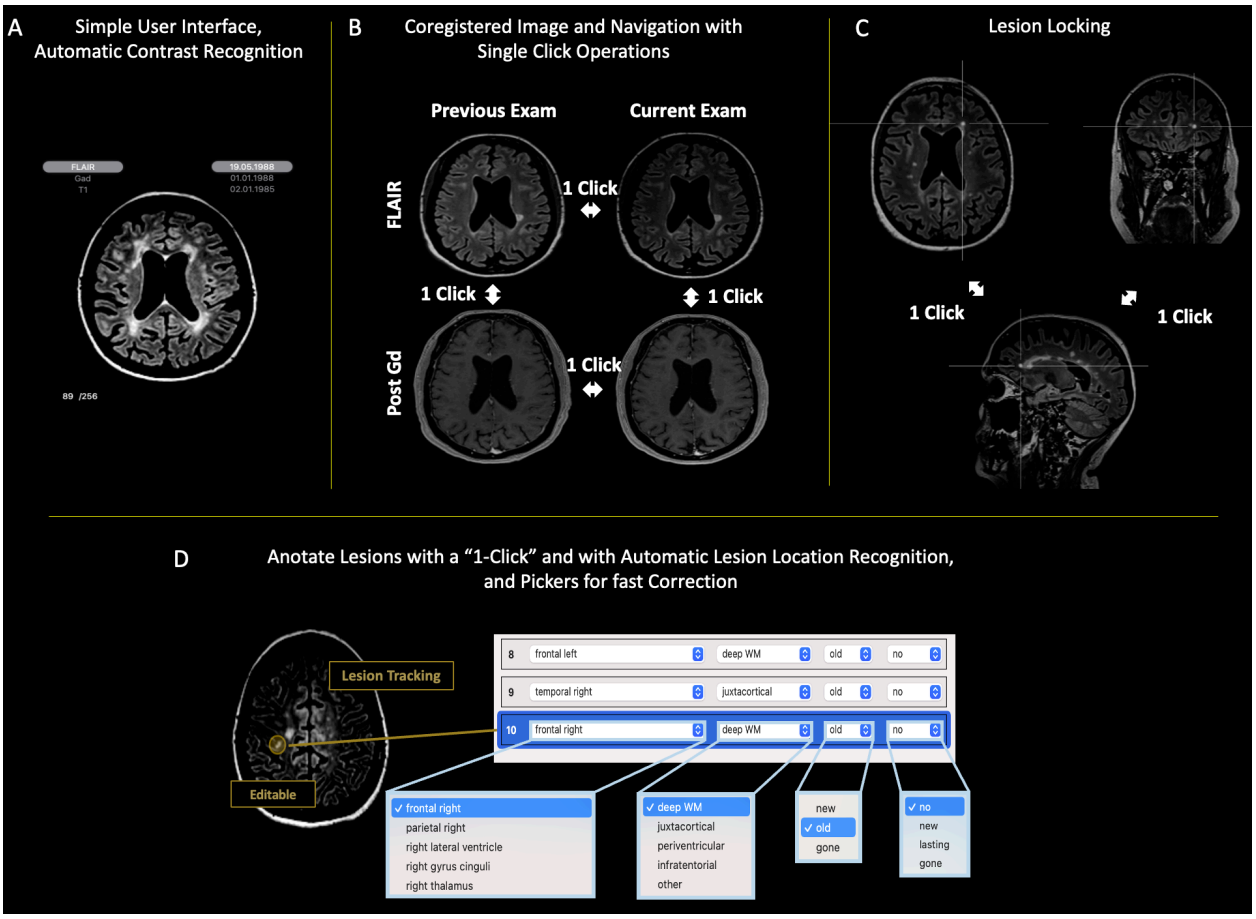

1. The intelligent automation software automizes low-level tasks for the radiologists, including (**A**) automatic contrast recognition, exams ordering, and (**B**) image coregistration for fast "single-click" lesion comparison and evaluation "without eye movements", maximizing efficiency and minimizing errors. (**C**) Lesion locking, which permits the evaluation of the lesion in various plane with a "single-click". (**D**) Automatic anatomic localization and lesion tracking permits ultra-fast lesion navigation. The pre-populated drop-down pickers allow for fast corrections of lesion characteristics. From the lesion list, the software counts the lesions, summarizes the findings, and generates a report automatically, which permits an additional gain in time. Automated lesion counting and generation of a standardized, editable report, including overview figures of the lesions, saves additional time for the radiologist, and eliminates possible human errors in this step.

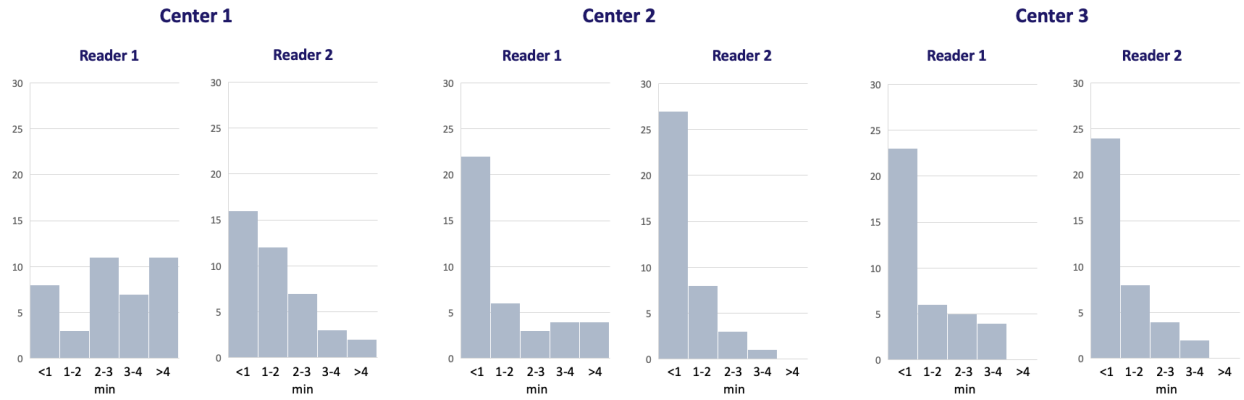

2. Histogram of the reading time by each reader in the three centers using Jazz.

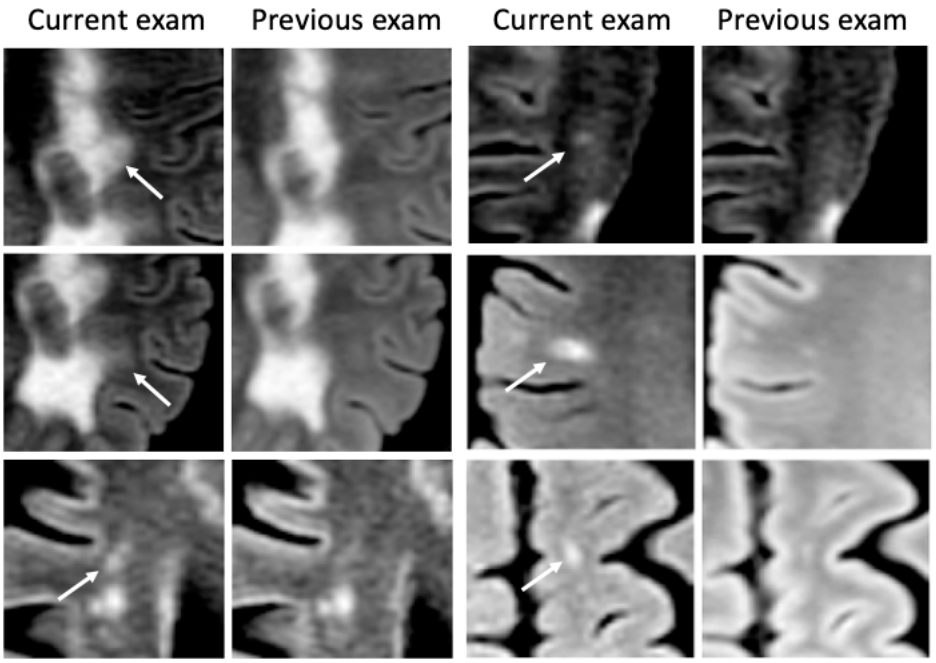

3. Examples of missed lesions on the standard report, detected by both readers with the Jazz software.

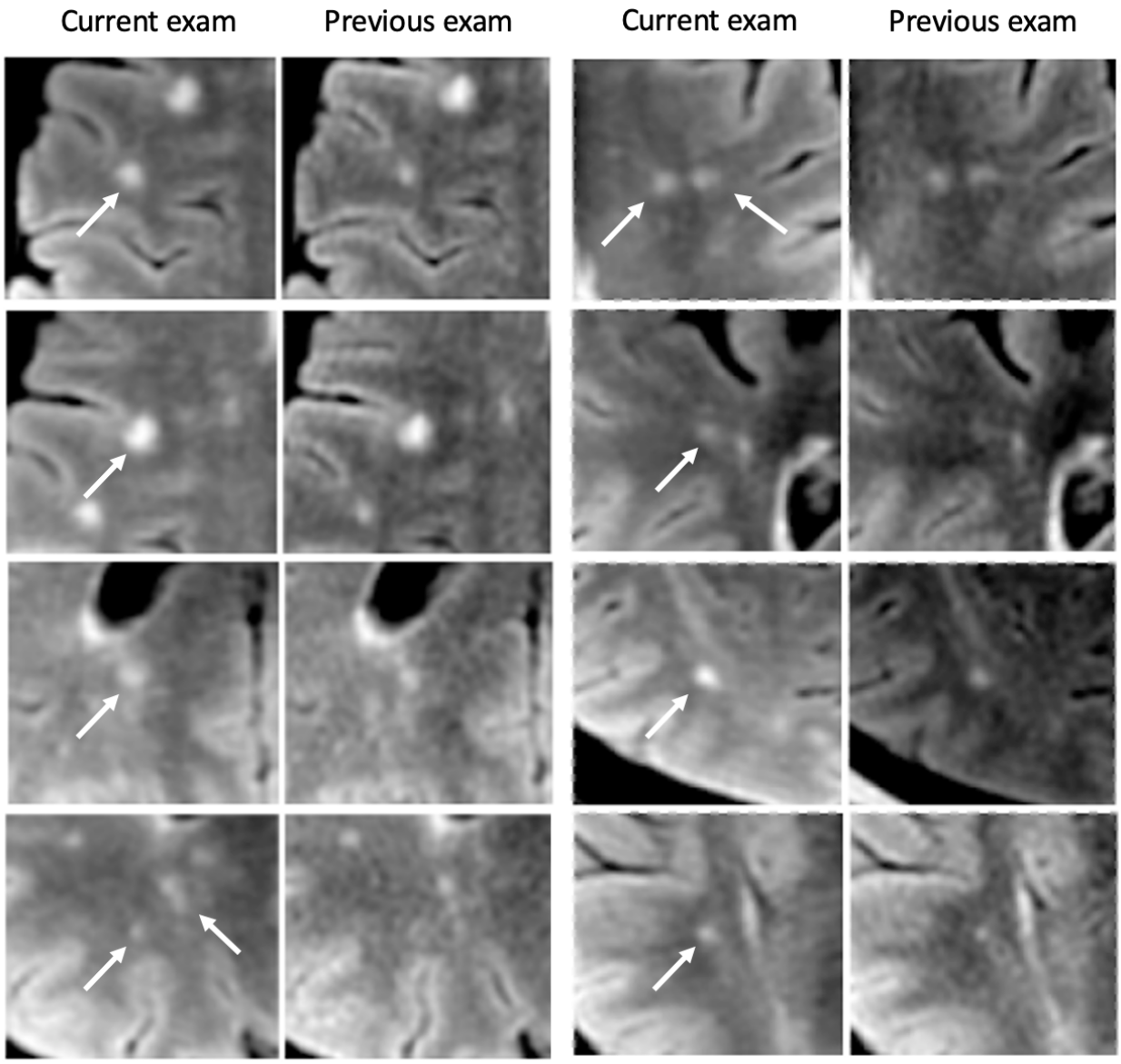

4. Examples of SELs not described on the standard clinical report, but described by both readers with the Jazz software. Note that all those images were acquired from the same patient. While the presence of a single SEL might be often difficult to interpret, as it might occur from partial volume effects or from MRI artifacts, the presence of multiples SELs is highly suggestive of disease progression.

Data Statement

The data that support the findings of this study are available from the corresponding author, C.F., on reasonable request.

References

1. Thompson AJ, Baranzini SE, Geurts J, Hemmer B, Ciccarelli O. Multiple sclerosis. The Lancet. 2018;391:1622–1636.

2. Kuhlmann T, Moccia M, Coetzee T, et al. Multiple sclerosis progression: time for a new mechanism-driven framework. The Lancet Neurology. 2023;22:78–88.

3. Rovaris M, Confavreux C, Furlan R, Kappos L, Comi G, Filippi M. Secondary progressive multiple sclerosis: current knowledge and future challenges. The Lancet Neurology. 2006;5:343–354.

4. Klineova S, Lublin FD. Clinical Course of Multiple Sclerosis. Cold Spring Harb Perspect Med. 2018;8:a028928.

5. Katz Sand I, Krieger S, Farrell C, Miller AE. Diagnostic uncertainty during the transition to secondary progressive multiple sclerosis. Mult Scler. 2014;20:1654–1657.

6. Brown JWL, Coles A, Horakova D, et al. Association of Initial Disease-Modifying Therapy With Later Conversion to Secondary Progressive Multiple Sclerosis. JAMA. 2019;321:175.

7. Lamb YN. Ocrelizumab: A Review in Multiple Sclerosis. Drugs. 2022;82:323–334.

8. Kappos L, Bar-Or A, Cree BAC, et al. Siponimod versus placebo in secondary progressive multiple sclerosis (EXPAND): a double-blind, randomised, phase 3 study. The Lancet. 2018;391:1263–1273.

9. Moraal B, Wattjes MP, Geurts JJG, et al. Improved Detection of Active Multiple Sclerosis Lesions: 3D Subtraction Imaging. Radiology. 2010;255:154–163.

10. Eichinger P, Wiestler H, Zhang H, et al. A novel imaging technique for better detecting new lesions in multiple sclerosis. J Neurol. 2017;264:1909–1918.

11. Eichinger P, Schön S, Pongratz V, et al. Accuracy of Unenhanced MRI in the Detection of New Brain Lesions in Multiple Sclerosis. Radiology. 2019;291:429–435.

12. Tan IL, Van Schijndel RA, Pouwels PJW, Adèr HJ, Barkhof F. Serial Isotropic Three-Dimensional Fast FLAIR Imaging: Using Image Registration and Subtraction to Reveal Active Multiple Sclerosis Lesions. American Journal of Roentgenology. 2002;179:777–782.

355 13. Schmidt MA, Linker RA, Lang S, et al. FLAIRfusion Processing with Contrast Inversion:
356 Improving Detection and Reading Time of New Cerebral MS Lesions. Clin Neuroradiol.
357 2018;28:367–376.

358 14. Ganiler O, Oliver A, Diez Y, et al. A subtraction pipeline for automatic detection of new
359 appearing multiple sclerosis lesions in longitudinal studies. Neuroradiology. 2014;56:363–
360 374.

361 15. Afzal HMR, Luo S, Ramadan S, Lechner-Scott J. The emerging role of artificial intelligence in
362 multiple sclerosis imaging. Mult Scler. 2022;28:849–858.

363 16. Aslani S, Dayan M, Storelli L, et al. Multi-branch convolutional neural network for multiple
364 sclerosis lesion segmentation. NeuroImage. 2019;196:1–15.

365 17. Hashemi SR, Salehi SSM, Erdogmus D, Prabhu SP, Warfield SK, Gholipour A. Asymmetric
366 Loss Functions and Deep Densely Connected Networks for Highly Imbalanced Medical
367 Image Segmentation: Application to Multiple Sclerosis Lesion Detection. IEEE Access.
368 2019;7:1721–1735.

369 18. Andermatt S, Pezold S, Cattin PC. Automated Segmentation of Multiple Sclerosis Lesions
370 Using Multi-dimensional Gated Recurrent Units. In: Crimi A, Bakas S, Kuijf H, Menze B,
371 Reyes M, editors. Brainlesion: Glioma, Multiple Sclerosis, Stroke and Traumatic Brain
372 Injuries. Cham: Springer International Publishing; 2018. p. 31–42.

373 19. Valverde S, Cabezas M, Roura E, et al. Improving automated multiple sclerosis lesion
374 segmentation with a cascaded 3D convolutional neural network approach. NeuroImage.
375 2017;155:159–168.

376 20. Maier O, Handels H. MS lesion segmentation in MRI with random forests. Proc
377 Longitudinal Multiple Sclerosis Lesion Segmentation Challenge, 2015. :1–2.

378 21. Birenbaum A, Greenspan H. Longitudinal Multiple Sclerosis Lesion Segmentation Using
379 Multi-view Convolutional Neural Networks. In: Carneiro G, Mateus D, Peter L, et al.,
380 editors. Deep Learning and Data Labeling for Medical Applications. Cham: Springer
381 International Publishing; 2016. p. 58–67.

382 22. Deshpande H, Maurel P, Barillot C. Adaptive dictionary learning for competitive
383 classification of multiple sclerosis lesions. 2015 IEEE 12th International Symposium on
384 Biomedical Imaging (ISBI) [online]. Brooklyn, NY, USA: IEEE; 2015. p. 136–139. Accessed at:
385 http://ieeexplore.ieee.org/document/7163834/. Accessed October 22, 2021.

386 23. Jain S, Sima DM, Ribbens A, et al. Automatic segmentation and volumetry of multiple
387 sclerosis brain lesions from MR images. NeuroImage: Clinical. 2015;8:367–375.

388 24. Sudre CH, Cardoso MJ, Bouvy WH, Biessels GJ, Barnes J, Ourselin S. Bayesian Model
389 Selection for Pathological Neuroimaging Data Applied to White Matter Lesion
390 Segmentation. IEEE Trans Med Imaging. 2015;34:2079–2102.

391 25. Tomas-Fernandez X, Warfield SK. A Model of Population and Subject (MOPS) Intensities
392 With Application to Multiple Sclerosis Lesion Segmentation. IEEE Trans Med Imaging.
393 2015;34:1349–1361.

394 26. Hainc N, Federau C, Stieltjes B, Blatow M, Bink A, Stippich C. The Bright, Artificial
395 Intelligence-Augmented Future of Neuroimaging Reading. Front Neurol. 2017;8:489.

396 27. Wikipedia - Intelligent automation [online]. Accessed at:
397 https://en.wikipedia.org/wiki/Intelligent_automation. Accessed January 1, 2023.

398 28. Jazz [online]. AI Medical AG; Accessed at: www.ai-medical.ch.

399 29. Carrasco M. Visual attention: The past 25 years. Vision Research. 2011;51:1484–1525.

400 30. Kinchla RA. Attention. Annu Rev Psychol. Annual Reviews; 1992;43:711–742.

401 31. Beck DM, Kastner S. Top-down and bottom-up mechanisms in biasing competition in the
402 human brain. Vision Research. 2009;49:1154–1165.

403 32. Reynolds JH, Chelazzi L. Attentional Modulation of Visual Processing. Annu Rev Neurosci.
404 2004;27:611–647.

405 33. Enns JT, Austen EL, Lollo VD, Rauschenberger R, Yantis S. New Objects Dominate
406 Luminance Transients in Setting Attentional Priority. :16.

407 34. Yantis S, Hillstrom AP. Stimulus-driven attentional capture: Evidence from equiluminant
408 visual objects. Journal of Experimental Psychology: Human Perception and Performance.
409 1994;20:95–107.

410 35. Yantis S, Jonides J. Abrupt visual onsets and selective attention: Evidence from visual
411 search. Journal of Experimental Psychology: Human Perception and Performance.
412 1984;10:601–621.

413 36. Filippi M, Preziosa P, Langdon D, et al. Identifying Progression in Multiple Sclerosis: New
414 Perspectives. Ann Neurol. 2020;88:438–452.

415 37. Kalincik T, Cutter G, Spelman T, et al. Defining reliable disability outcomes in multiple
416 sclerosis. Brain. 2015;138:3287–3298.

417 38. D'Souza M, Papadopoulou A, Girardey C, Kappos L. Standardization and digitization of
418 clinical data in multiple sclerosis. Nat Rev Neurol. 2021;17:119–125.

419 39. Alessandrino F, Pichiecchio A, Mallucci G, et al. Do MRI Structured Reports for Multiple
420 Sclerosis Contain Adequate Information for Clinical Decision Making? American Journal of
421 Roentgenology. 2018;210:24–29.

422 40. Voigt I, Inojosa H, Dillenseger A, Haase R, Akgün K, Ziemssen T. Digital Twins for Multiple
423 Sclerosis. Front Immunol. 2021;12:669811.

424 41. Calvi A, Haider L, Prados F, Tur C, Chard D, Barkhof F. In vivo imaging of chronic active
425 lesions in multiple sclerosis. Mult Scler. Epub 2020 Sep 23.:135245852095858.

426 42. Elliott C, Wolinsky JS, Hauser SL, et al. Slowly expanding/evolving lesions as a magnetic
427 resonance imaging marker of chronic active multiple sclerosis lesions. Mult Scler.
428 2019;25:1915–1925.

429 43. Elliott C, Belachew S, Wolinsky JS, et al. Chronic white matter lesion activity predicts
430 clinical progression in primary progressive multiple sclerosis. Brain. 2019;142:2787–2799.

431 44. Preziosa P, Pagani E, Meani A, et al. Slowly Expanding Lesions Predict 9-Year Multiple
432 Sclerosis Disease Progression. Neurol Neuroimmunol Neuroinflamm. 2022;9:e1139.

433 45. Calvi A, Carrasco FP, Tur C, et al. Association of Slowly Expanding Lesions on MRI With
434 Disability in People With Secondary Progressive Multiple Sclerosis. Neurology.
435 2022;98:e1783–e1793.

436 46. Yong HYF, Yong VW. Mechanism-based criteria to improve therapeutic outcomes in
437 progressive multiple sclerosis. Nat Rev Neurol. 2022;18:40–55.