Duodenal alpha-Synuclein pathology and enteric gliosis in advanced PD patients

Aron Emmi[1,2,7,9,]*, Michele Sandre[2,7,9,]*, Francesco Paolo Russo[3,7], Giulia Tombesi[4], Federica Garrì[2], Marta Campagnolo[2,7], Miryam Carecchio[2,7], Roberta Biundo[2,5,7], Gaya Spolverato[3,7], Veronica Macchi[1,7], Edoardo Savarino[3,7], Fabio Farinati[3,7], Piero Parchi[8], Andrea Porzionato[1,7], Luigi Bubacco[4,7], Raffaele De Caro[1,7], Gabor G Kovacs[6], Angelo Antonini[2,7,9,#]

[1] Institute of Human Anatomy, Department of Neuroscience, University of Padova, Padova, Italy

[2] Parkinson and Movement Disorders Unit, Centre for Rare Neurological Diseases (ERN-RND), Department of Neuroscience, University of Padova, Padova, Italy

[3] Department of Surgery, Oncology and Gastroenterology, Padova University Hospital, Padova, Italy

[4] Department of Biology, University of Padova, Padova, Italy

[5] Department of General Psychology, University of Padova, Padova, Italy

[6] Department of Pathobiology and Laboratory Medicine, University of Toronto, Toronto, Ontario M5S 1A8, Canada

[7] Center for Neurodegenerative Disease Research (CESNE), University of Padova, Padova, Italy

[8] IRCCS, Istituto delle Scienze Neurologiche di Bologna (ISNB), Bologna, Italy

[9] Padua Neuroscience Center (PNC), University of Padova, Padova, Italy

***** Both authors contributed equally to the study

Correspondence: angelo.antonini@unipd.it

ABSTRACT

In Parkinson's Disease (PD), recent evidence points toward the involvement of the gut-brain axis as one of the primary physio pathological mechanisms underlying α-Synuclein aggregation and propagation to CNS. Furthermore, gastrointestinal dysfunctions represent one of the main non-motor symptoms in PD, often preceding the development of proper motor symptoms. We aimed to investigate the enteric nervous system (ENS) in PD by characterizing α-Syn alterations and glial responses in duodenum biopsies of PD patients.

Patients with symptomatic PD which underwent Duodopa Percutaneous Endoscopic Gastrostomy and Jejunal Tube (PEG-J) procedure were included in the study. A mean of 4 wall biopsies were sampled from each patient. Immunohistochemistry was performed with anti-aggregated α-Syn (5G4) and GFAP antibodies. Morphometrical-semi-quantitative analysis was performed to characterize 5G4+ and GFAP+ density and size. Duodenal control biopsies were included from age-and-sex-matched patients undergoing routine diagnostic endoscopy.

Elevated immunoreactivity for aggregated α-Syn was identified in all biopsies of PD patients compared to controls. 5G4+ partially colocalized with neuronal marker β-III-tubulin but was found also outside enteric neurons. Evaluation of enteric glia cells revealed an increased size and density when compared with controls suggesting reactive gliosis.

The ENS could be one of the earliest implicated structures in the pathophysiology of PD. The analysis of enteric glia could represent a precocious biological marker of the disease, as its responses to pathological α-Syn could unveil a link between gastrointestinal neural and immune systems in PD inflammation.

INTRODUCTION

In Parkinson's Disease (PD), the role of the gut-brain axis has been greatly highlighted by recent developments in both clinical and preclinical research[1-5].

There is growing interest in the detection of α-Synuclein (αSyn) deposition, the histological hallmark of PD, in peripheral tissues[6] including the gastrointestinal (GI) tract[7-10]. Considering the involvement of the enteric nervous system (ENS) in the prodromal stages of PD and its relationship with gut motility[11 12], the detection of αSyn aggregation and its deposition in gut tissues appears to be of great relevance[13]. Recent animal models suggested the possibility of a bidirectional transmission of αSyn pathology, that may either originate in the enteric nervous system and spread to the brain, or in the amygdala and then move caudally; this has led to the debate on whether the direction of αSyn spreading may impact on disease phenotype and has greatly driven the discussion on the so-called "gut-brain axis"[2 14 15]. These findings have been supported by human postmortem samples, while in-vivo human studies reported heterogeneous immunohistochemistry staining in GI biopsies (mainly gastric and colonic) [16-18]. Phosphorylated αSyn (p-αSyn) at Serine 129 residue, has been considered as the most reliable marker to distinguish pathological deposits from physiological protein. However, a consensus has not been reached so far on which antibody (anti-αSyn or anti-p-αSyn) should be used in peripheral tissues to distinguish PD patients from controls[9 19 20], while antibodies specific for αSyn aggregates have been employed in a single study on colonic mucosa, with promising results[21]. Specifically, clone 5G4, the antibody used in this work can detect αSyn aggregates and it was raised against the sequence encompassing aminoacids 44-57 of αSyn[22 23]. Recently, in an in-vitro comparative analysis of several αSyn targeting antibodies, 5G4 showed high conformational specificity and strong immunoreactivity for all forms of αSyn aggregates with no reaction toward αSyn monomers[24]. Furthermore, 5G4 immunohistochemistry was more reliable in identifying αSyn aggregates across synucleinopathies compared to other αSyn antibodies and was also able to detect αSyn astrocytic inclusions in Lewy Body dementia[23 25].

Furthermore, considerable attention has been drawn to enteric glial cells (EGCs), which may play a critical role in the crosstalk between inflammation and neurodegeneration. According to available studies, EGCs participate in the regulation of gastrointestinal functions, playing a key role in the pathophysiology of gastrointestinal disorders[26 27]. More recently, EGCs have emerged as critical players in regulating GI function in PD, as higher levels of expression of both GFAP and Sox-10, but not of S100-beta, were reported in the GI tract of PD patients. However, levels of glial markers were negatively related to PD disease duration, suggesting that EGC reaction is more relevant at disease onset and decreases over time[28-30]. However, the precise mechanism by which EGCs contribute to PD pathogenesis remains to be elucidated.

In the present study we aim to investigate the histopathological changes in the enteric nervous system by characterizing both αSyn aggregates and enteric glial responses in duodenum biopsies of advanced PD patients with extensive clinical and demographical documentation.

METHODS

Subjects

Fourteen (14) patients (9 male, 5 female; mean age 65.1 years, 95% CI 60.7 to 69.5; mean disease duration 11.79 years, 95% CI 9.31 to 14.26) with advanced PD who required initiation of Levodopa Carbidopa Intestinal Gel (LCIG) infusion were part of the study[31].

All patients underwent Percutaneous Endoscopic Gastrostomy with Jejunal extension (PEG-J) placement; an average of four 3 mm^3 duodenal-wall biopsies were sampled in a topographically unrelated district to PEG-J placement. Along with the routine clinical assessment (MDS- UPDRS I-II- III, IV, Hoehn and Yahr scales), the Wexner Constipation Score (WCS)[32] was also calculated.

Duodenal biopsies from 10 subjects comparable for age- and sex- (4 male, 6 females; mean age 67.3 years, 95% CI 59.8 to 74.8) undergoing control diagnostic endoscopy were included as

controls. Control subjects were evaluated clinically and interviewed to exclude any manifestation suggestive of PD or any other neurological disorder.

The study protocol received approval by the ethical committee for clinical experimentation of Padua Province (Prot. n. 0034435, 08/06/2020). Informed consent for the use of biological samples was obtained from all patients. All procedures on human tissue samples were carried out in accordance with the Declaration of Helsinki.

Clinical characteristics	Mean ± SD	95% CI
Age at PD onset, years	53.43±8.89	48.8-58.1
PD duration, years	11.79±4.73	9.31-14.26
Age at biopsy	65±8.23	56.77-73.22
Time elapsed from PD diagnosis to biopsy, years	11.57±4.59	9.17-13.98
Age at LCIG initiation, years	63.43±9.06	58.68-68.18
MMSE	28.29±2.96	26.73-29.84
MOCA	23.87±4.42	21.55-26.18
PDQ8	11.54±6.65	7.92-15.16
MDS- UPDRS I	13.45±5.77	10.05-16.86
MDS-UPDRS II	19±10.61	12.73-25.27
MDS-UPDRS III	30.36±11.93	24.11-36.60
MDS-UPDRS IV	8.42±3.15	6.64-10.20
H&Y	2.50±1.02	1.97-3.03
Levodopa baseline	882.14±339.46	704.33-1059.96
LEDD baseline	1309.07±519.76	1036.81-1581.33
WCS	8.83±5.44	5.37-12.29

Table 1. *Demographic and clinical characteristics of Parkinson's Disease patients (n=14) as means ± standard deviations and 95% confidence interval (CI) are shown. SD standard deviation, PD Parkinson's Disease. LCIG levodopa/carbidopa intestinal gel, MMSE Mini-Mental State Examination, MOCA Montreal Cognitive Assessment, PDQ8 Parkinson's Disease Questionnaire, MDS-UPDRS Unified Parkinson's Disease Rating Scale, H&Y Hoehn-Yahr Staging Scale, LEDD Levodopa Equivalent Dose Calculator, MDS-NMS MDS Non-Motor Rating Scale, WCS Wexner Constipation Score.*

Tissue processing and staining

Tissue samples were fixed in phosphate-buffered 4% paraformaldehyde, embedded in paraffin, and sectioned at the microtome (5µm slices). Immunoperoxidase staining for aggregated αSyn (Monoclonal Mouse, Clone 5G4, Millipore) and Glial Fibrillary Acidic Protein (GFAP, Monoclonal Rabbit, Dako Omnis) was performed on a Dako EnVision Autostainer station according to manufacturer's recommendations. Antigen retrieval was performed on a PT-Link Dako Antigen

retrieval station using Citrate-buffer at pH 6 solution at 96° for 15 minutes, followed by 1 minute 95% Formic Acid for the 5G4 antibody.

Immunoperoxidase staining was repeated at least three times to assure reaction consistency and was independently evaluated by three morphologists blind to the clinical findings. Controversies were resolved by consensus.

Morphometrical quantification

Photomicrographs were acquired under a Leica DM4500B microscope (Leica Microsystems) connected to a Leica DFC320 high-resolution digital camera (Leica Microsystems) and a computer equipped with software for image acquisition (QWin, Leica Microsystems) and analysis (ImageJ)[33] [34]. Whole section photomicrographs were acquired at 5x magnification, while an average of four 20x magnification photomicrographs per available sample were acquired as counting fields and loaded into ImageJ software for semi-automatic immunoreactivity quantification.

The area of the sections was quantified by manually drawing the boundaries of the specimens. A Maximum Entropy Threshold was applied and manually adjusted for each section in order to discern immunopositive elements from background and negative tissue. Quality control of the applied threshold was performed by an expert morphologist by overlying the thresholded images to the original photomicrographs. Particle analysis was employed with a 0-infinity px threshold in order to define immunopositive elements quantity and total area occupied within the digital image. For GFAP staining, the quantity of immunopositive elements was divided by the total area of the sample in order to obtain a semi-quantitative measure of immunoreactive density within each section. For 5G4 staining, as immunoreactive structures did not present as distinct elements with defined boundaries, total immunoreactive area (μm^2) and % of immunoreactive area (A%) was

estimated per counting field. Counting fields for each available sample were treated as repeated measures and averaged per single subject.

Immunofluorescence and confocal microscopy

Fluorescent immunohistochemistry was performed manually. Antigen retrieval was performed on de-paraffinized tissue as in immunoperoxidase staining methods. Following autofluorescence was quenched with a 50 mM NH4Cl solution for 10 minutes. Sections were treated with permeabilization and blocking solution (15% vol/vol Goat Serum, 2% wt/vol BSA, 0.25% wt/vol gelatin, 0.2% wt/vol glycine in PBS) containing 0.5% Triton X100 for 90 minutes before primary antibodies incubation. Primary antibodies were diluted in blocking solution and incubated at 4°C overnight. Alexa-Fluor plus 488 Goat antiMouse secondary antibody (Code number: 183 A32723) and Alexa-Fluor plus 568 antiRabbit secondary antibody (Code number: A-11011) were diluted 1:200 in blocking solution as above and incubated for 60 minutes at room temperature. Hoechst 33258 were used for nuclear staining (Invitrogen, dilution: 1:10000 in PBS) for 10 minutes. Slides were mounted and coverslipped with Mowiol solution. Confocal immunofluorescence z-stack images were acquired on a Leica SP5 Laser Scanning Confocal Microscope using a HC PL FLUOTAR 20x/0.50 Dry or HCX PL APO lambda blue 40X/1.40 Oil objectives. Images were acquired at a 16-bit intensity resolution over 2048 × 2048 pixels. Z-stacks images were converted into digital maximum intensity z-projections, processed, and analyzed using ImageJ software.

The antibodies used for IF were the following: mouse anti-aggregated α-Syn clone 5G4 (MABN389, Sigma-Aldrich, 1:1000); rabbit Glial Fibrillary Acidic Protein (GFAP, Dako Omnis, 1:1000); mouse β-III Tubulin (#T8578 Sigma; 1:300).

Statistical Analyses

Statistical analyses and visualizations were performed using GraphPad Prism v.9. Nonparametric data were analyzed with Mann–Whitney U-test. Pearson's correlation analysis has been employed to assess possible correlations between αSyn expression in duodenum and clinical characteristics, including motor and non-motor scales, cognitive assessments and main non-motor symptoms of PD. Values are indicated as the median, with significance as follows: $*p < 0.05$, $**p < 0.01$, $***p < 0.001$, and $****p < 0.0001$.

RESULTS

Alpha-Synuclein Pathology

5G4 immunoreactive elements detected in duodenal specimens were classified according to morphological criteria, as seen in Figure 1. Globular immunoreactivities (Figure 1F-G), as well as Cellular immunoreactivities (Figure 1H-I) were found in both PD and HC, and were likely the result of cross-reactivity with resident mast cells; dot-like immunoreactivities (Figure 1L-M) ere either the result of lipopigment staining in the duodenal mucosa, or could be ascribed to actual aggregated αSyn deposits if colocalizing with neuronal structures via immunofluorescent staining / double label immunoperoxidase staining. Threaded immunoreactivities (Figure 1N-O) were detected in PD patients, but not in controls, and represented the most reliable immunoreactivity type to discern PD from controls. Immunofluorescent staining (Figure 1P-P2) confirmed the colocalization between 5G4 threaded immunoreactivities and β-III Tubulin, a pan-neuronal and neuritic marker, indicating aggregated αSyn deposits in duodenal nerve fibers of the mucosa and submucosa. Furthermore, regardless of morphology, all duodenal samples collected from PD patients were characterized by marked immunoreactivity for aggregated αSyn (14/14; 100%) (Figure 1B,D), while absent (2/10) or barely detectable (8/10) immunoreactivity was found in controls (Figure 1A,C). Semi-automatic morphometrical quantification for 5G4 antibody **revealed statistically** significant higher immunoreactive tissue area in PD patients compared to controls ($****p<0.0001$) (Figure 1E).

GFAP analysis and enteric gliosis

GFAP immunoreactive elements presented as discrete, round immunoreactive cells localized predominantly within the duodenal mucosa and submucosa (Figure 2A, 2E High-Magnification Inserts).

Morphometrical analyses revealed both increased EGC density (PD mean: 102.1±33.1; CTRL mean: 45.6±13.6; Figure 2I) and increased cell size (PD mean: 28.6±1.1 μm^2; CTRL mean: 25.2±1.2 μm^2; Figure 2L) when compared to controls (***$p = 0.0002$), suggesting for local reactive gliosis.

Spearman's rank correlation analysis between αSyn 5G4 immunoreactive area, EGC density and EGC cell size in the duodenum revealed a strong correlation (R_s=0.751, $p<0.0001$ and R_s=0.741, $p<0.0001$, n=24, respectively).

Correlation with clinical data

Pearson's correlation analysis was performed between 5G4 immunoreactive areas and collected clinical data. No correlation was found with sex, disease duration, motor severity, cognitive status, quality of life, and NMS-MDS scale score. Interestingly, we found a trend of increased aggregated αSyn distribution in patients who complained of constipation (p=0.058) (WCS), however validation of this finding requires a larger cohort. Similarly, no significant correlation was observed with the other variables examined, including other gastrointestinal disturbances.

DISCUSSION

In the present study, we documented marked immunoreactivity for aggregated αSyn and morphological changes in EGC suggestive of reactive gliosis in the duodenum of advanced PD patients. These findings expand our knowledge on the involvement of the enteric nervous system in PD and suggest the duodenum as possible target for early disease detection.

Our results also indicate that the 5G4 conformation specific αSyn antibody can be considered as a reliable marker for discerning duodenal biopsies of PD patients and healthy controls. While low or barely detectable immunoreactivity for 5G4 was also found in controls, marked differences with PD patients were revealed by morphometrical quantification. Furthermore, morphological evaluation revealed thread-like immunoreactivities as PD specific-findings; immunofluorescent staining confirmed colocalization between αSyn aggregates and neuronal markers, indicating synuclein aggregates in nerve fibers of the duodenal mucosa and submucosa. 5G4 antibody appears to be specific for αSyn aggregates, as monomeric synuclein is not detectable in vitro[24]. Furthermore, phospho-αSyn antibodies do not appear to be able to discern between PD patients and controls in gastric and colonic mucosa specimens, thus greatly limiting their reliability[35 36]. Unlike previous studies, we have examined an anatomically defined region of the small intestine, the duodenum, greatly limiting the sampling site variability present in colonic mucosa studies. Moreover, the left half of the transverse colon and the descending colon receive parasympathetic innervation from the sacral nerves deriving from the spinal cord, and not from the vagus nerve, and thus are inherently biased towards the brain-to-gut hypothesis of αSyn transmission. The localization and density of αSyn aggregates in the normal aging population has not been documented as to date, with low quantities of aggregated αSyn possibly representing a normal finding in aging subjects, as seen in this small cohort.

GFAP immunoreactive cell density and size was also higher in PD patients compared to controls, suggesting enteric gliosis. However, immunofluorescent staining for 5G4 and GFAP antibodies did not reveal colocalization between markers (Supplementary 1). Conversely, 5G4 colocalization with

neuronal marker βIII-tubulin was found, indicating a preferential site for αSyn aggregates. Challis et al.[37] evidenced increased myenteric EGCs volume and count in a mouse model of αSyn preformed-fibrils (PFF) duodenal inoculation, similar to our in-vivo findings. According to the authors, αSyn-PFF inoculation induces reactive gliosis in response to fibrils seeding, thus linking αSyn pathology to EGCs reaction. Our study suggests a localized reaction of EGCs in in-vivo PD patients in line with the current animal-model studies and supported also by the strong correlation between EGC values and aggregated αSyn; however the mechanisms underlying this require further investigation in humans, with regard to inflammatory and immunity processes involved[38].

There was no correlation between patients' clinical characteristics including cognitive scales and 5G4 distribution in the duodenum suggesting that peripheral pathology may not necessarily reflect phenotypic variability. To investigate this hypothesis further, prospective studies could include REM Behaviour Sleep Disorder (RBD) as well as early PD subjects. Inclusions of patients at various disease stages may provide further insight into the temporal dynamics of aggregated αSyn in the GI tract and its association with brain pathology.

In conclusion, our data suggest that duodenal biopsy may represent a safe, feasible and useful tool for characterizing PD pathology in the GI tract and discerning patients from controls. Future studies will be required to confirm these findings in a prodromal or early PD phase and to evaluate subjects with other synucleinopathies in particular multiple system atrophy.

Acknowledgements

Author Contributions

AA, GGK, LB, AE, MS designed the study. AA, FG, MiC, MaC recruited the patients. AA, MiC, MaC, FG performed the neurological evaluation of the participants. RB performed the neuropsychological assessment of the participants. FPR performed the endoscopic exam and sampling of the biopsies. AE, MS, GT performed the immunohistochemical staining of the samples. AE, MS, RDC, AP performed the morphometrical and morphological evaluation of immunoreactivities. AE, MS performed the statistical analyses. AE, MS, AA drafted the manuscript and figures. All authors read and approved the final version of the manuscript.

Conflicts of Interest

References

1. Klingelhoefer L, Reichmann H. Pathogenesis of Parkinson disease—the gut–brain axis and environmental factors. *Nature Reviews Neurology* 2015;11(11):625-36. doi: 10.1038/nrneurol.2015.197
2. Kim S, Kwon S-H, Kam T-I, et al. Transneuronal Propagation of Pathologic α-Synuclein from the Gut to the Brain Models Parkinson's Disease. *Neuron* 2019;103(4):627-41.e7. doi: 10.1016/j.neuron.2019.05.035
3. Chung HK, Ho H-A, Pérez-Acuña D, et al. Modeling α-Synuclein Propagation with Preformed Fibril Injections. *JMD* 2019;12(3):139-51. doi: 10.14802/jmd.19046
4. Cersosimo MG, Raina GB, Pecci C, et al. Gastrointestinal manifestations in Parkinson's disease: prevalence and occurrence before motor symptoms. *Journal of Neurology* 2013;260(5):1332-38. doi: 10.1007/s00415-012-6801-2
5. Espay AJ, Kalia LV, Gan-Or Z, et al. Disease modification and biomarker development in Parkinson disease. *Neurology* 2020;94(11):481-94. doi: 10.1212/wnl.0000000000009107
6. Chahine LM, Beach TG, Brumm MC, et al. In vivo distribution of α-synuclein in multiple tissues and biofluids in Parkinson disease. *Neurology* 2020;95(9):e1267-e84. doi: 10.1212/wnl.0000000000010404
7. Ma L-Y, Liu G-L, Wang D-X, et al. Alpha-Synuclein in Peripheral Tissues in Parkinson's Disease. *ACS Chemical Neuroscience* 2019;10(2):812-23. doi: 10.1021/acschemneuro.8b00383
8. Sánchez-Ferro Á, Rábano A, Catalán MJ, et al. In vivo gastric detection of α-synuclein inclusions in Parkinson's disease. Movement Disorders: John Wiley & Sons, Ltd, 2015:517-24.
9. Barrenschee M, Zorenkov D, Böttner M, et al. Distinct pattern of enteric phospho-alpha-synuclein aggregates and gene expression profiles in patients with Parkinson's disease. *Acta Neuropathologica Communications* 2017;5(1) doi: 10.1186/s40478-016-0408-2
10. Gelpi E, Navarro-Otano J, Tolosa E, et al. Multiple organ involvement by alpha-synuclein pathology in Lewy body disorders. *Movement Disorders* 2014;29(8):1010-18. doi: 10.1002/mds.25776
11. Singh A, Dawson TM, Kulkarni S. Neurodegenerative disorders and gut-brain interactions. *Journal of Clinical Investigation* 2021;131(13) doi: 10.1172/jci143775
12. Fleming MA, Ehsan L, Moore SR, et al. The Enteric Nervous System and Its Emerging Role as a Therapeutic Target. *Gastroenterology Research and Practice* 2020;2020:1-13. doi: 10.1155/2020/8024171
13. Borghammer P. The α-Synuclein Origin and Connectome Model (SOC Model) of Parkinson's Disease: Explaining Motor Asymmetry, Non-Motor Phenotypes, and Cognitive Decline. *Journal of Parkinson's Disease* 2021;11:455-74. doi: 10.3233/JPD-202481
14. Borghammer P, Van Den Berge N. Brain-First versus Gut-First Parkinson's Disease: A Hypothesis. *Journal of Parkinson's disease* 2019;9(s2):S281-S95. doi: 10.3233/JPD-191721
15. Leclair□Visonneau L, Neunlist M, Derkinderen P, et al. The gut in Parkinson's disease: Bottom□up, top□down, or neither? *Neurogastroenterology & Motility* 2020;32(1) doi: 10.1111/nmo.13777
16. Stokholm MG, Danielsen EH, Hamilton-Dutoit SJ, et al. Pathological α-synuclein in gastrointestinal tissues from prodromal Parkinson disease patients. Annals of Neurology: John Wiley and Sons Inc., 2016:940-49.

17. Beck G, Hori Y, Hayashi Y, et al. Detection of Phosphorylated Alpha-Synuclein in the Muscularis Propria of the Gastrointestinal Tract Is a Sensitive Predictor for Parkinson's Disease. *Parkinson's Disease* 2020;2020:1-8. doi: 10.1155/2020/4687530
18. Ruffmann C, Bengoa-Vergniory N, Poggiolini I, et al. Detection of alpha-synuclein conformational variants from gastro-intestinal biopsy tissue as a potential biomarker for Parkinson's disease. *Neuropathology and Applied Neurobiology* 2018;44(7):722-36. doi: 10.1111/nan.12486
19. Harapan BN, Frydrychowicz C, Classen J, et al. No enhanced (p-) α-synuclein deposition in gastrointestinal tissue of Parkinson's disease patients. *Parkinsonism & Related Disorders* 2020;80:82-88. doi: 10.1016/j.parkreldis.2020.08.020
20. Fricova D, Harsanyiova J, Kralova Trancikova A. Alpha-Synuclein in the Gastrointestinal Tract as a Potential Biomarker for Early Detection of Parkinson's Disease. *International Journal of Molecular Sciences* 2020;21(22):8666. doi: 10.3390/ijms21228666
21. Skorvanek M, Gelpi E, Mechirova E, et al. α-Synuclein antibody 5G4 identifies manifest and prodromal Parkinson's disease in colonic mucosa. *Mov Disord* 2018;33(8):1366-68. doi: 10.1002/mds.27380
22. Kovacs GG, Breydo L, Green R, et al. Intracellular processing of disease-associated α-synuclein in the human brain suggests prion-like cell-to-cell spread. Neurobiology of Disease: Academic Press, 2014:76-92.
23. Kovacs GG, Wagner U, Dumont B, et al. An antibody with high reactivity for disease-associated α-synuclein reveals extensive brain pathology. Acta Neuropathologica: Springer, 2012:37-50.
24. Kumar ST, Jagannath S, Francois C, et al. How specific are the conformation-specific α-synuclein antibodies? Characterization and validation of 16 α-synuclein conformation-specific antibodies using well-characterized preparations of α-synuclein monomers, fibrils and oligomers with distinct struct. *Neurobiology of Disease* 2020;146:105086. doi: 10.1016/j.nbd.2020.105086
25. Sorrentino ZA, Goodwin MS, Riffe CJ, et al. Unique α-synuclein pathology within the amygdala in Lewy body dementia: implications for disease initiation and progression. *Acta neuropathologica communications* 2019;7(1):142-42. doi: 10.1186/s40478-019-0787-2
26. Sharkey KA. Emerging roles for enteric glia in gastrointestinal disorders. *Journal of Clinical Investigation* 2015;125(3):918-25. doi: 10.1172/jci76303
27. Grubišić V, Gulbransen BD. Enteric glia: the most alimentary of all glia. *The Journal of Physiology* 2017;595(2):557-70. doi: 10.1113/jp271021
28. Clairembault T, Kamphuis W, Leclair-Visonneau L, et al. Enteric GFAP expression and phosphorylation in Parkinson's disease. *Journal of Neurochemistry* 2014;130(6):805-15. doi: 10.1111/jnc.12742
29. Clairembault T, Leclair-Visonneau L, Neunlist M, et al. Enteric glial cells: New players in Parkinson's disease? *Movement Disorders* 2015;30(4):494-98. doi: 10.1002/mds.25979
30. Benvenuti L, D'Antongiovanni V, Pellegrini C, et al. Enteric Glia at the Crossroads between Intestinal Immune System and Epithelial Barrier: Implications for Parkinson Disease. *International Journal of Molecular Sciences* 2020;21(23):9199. doi: 10.3390/ijms21239199
31. Antonini A, Odin P, Pahwa R, et al. The Long-Term Impact of Levodopa/Carbidopa Intestinal Gel on 'Off'-time in Patients with Advanced Parkinson's Disease: A Systematic Review. *Advances in Therapy* 2021;38(6):2854-90. doi: 10.1007/s12325-021-01747-1
32. Agachan F, Chen T, Pfeifer J, et al. A constipation scoring system to simplify evaluation and management of constipated patients. *Dis Colon Rectum* 1996;39(6):681-5. doi: 10.1007/bf02056950
33. Porzionato A, Guidolin D, Emmi A, et al. High-quality Digital 3D Reconstruction of Microscopic Findings in Forensic Pathology: The Terminal Pathway of a Heart Stab Wound*. *Journal of Forensic Sciences* 2020;65(6):2155-59. doi: 10.1111/1556-4029.14497

34. Emmi A, Porzionato A, Contran M, et al. 3D Reconstruction of the Morpho-Functional Topography of the Human Vagal Trigone. *Front Neuroanat* 2021;15:663399-99. doi: 10.3389/fnana.2021.663399
35. Visanji NP, Marras C, Kern DS, et al. Colonic mucosal α-synuclein lacks specificity as a biomarker for Parkinson disease. *Neurology* 2015;84(6):609-16. doi: 10.1212/wnl.0000000000001240
36. Chung SJ, Kim J, Lee HJ, et al. Alpha-synuclein in gastric and colonic mucosa in Parkinson's disease: Limited role as a biomarker. *Movement Disorders* 2016;31(2):241-49. doi: 10.1002/mds.26473
37. Challis C, Hori A, Sampson TR, et al. Gut-seeded α-synuclein fibrils promote gut dysfunction and brain pathology specifically in aged mice. *Nature Neuroscience* 2020;23(3):327-36. doi: 10.1038/s41593-020-0589-7
38. Sandre M, Emmi A, Tombesi G, et al. Alpha-synuclein pathology and enteric glia in advanced Parkinson's disease: A study from gastrointestinal biopsies. *Journal of the Neurological Sciences* 2021;429:119460. doi: 10.1016/j.jns.2021.119460

FIGURE LEGENDS

Figure 1. 5G4 immunoperoxidase-stained duodenal biopsies. A,C) Healthy Controls (HC). B,D) Parkinson's Disease (PD) patients. Scale Bar = 50µm. E) Mann-Whitney U-test reveals statistically significant differences between PD and HC (****P<0.0001). F-O) 5G4 Immunoreactivity types encountered in the duodenal mucosa. F-G) Globular immunoreactivities and H-I) cellular reactivities, found in both PD and HC, likely represent antibody cross-reactivity with resident mast cells. L-M) dot-like reactivities can be either ascribed to lipopigment deposits in the GI mucosa, or may represent actual 5G4 aggregated synuclein deposits in nerve fibers fragmented within the sectioning plane. N-O) Threaded (thread-like) reactivities encountered in PD patients indicate alpha-synuclein aggregates in nerve fibers of the GI tract, as demonstrated by double-label immunofluorescent staining for 5G4 aggregated synuclein (yellow) and beta-III-tubulin (magenta), a pan-neuronal and neuritic marker (P1-P2).

Figure 2. GFAP immunoperoxidase-stained duodenal biopsies. A-D) Healthy Controls (HC). E-H) Parkinson's Disease (PD) patients. Scale Bar = 50µm; high magnification inserts Scale Bar = 15µm. I-L) Mann-Whitney U-test reveals statistically significant differences between PD and HC in terms of both enteric glial cell size (I) and density (L) (***P<0.001; ****P<0.0001).

FIGURES

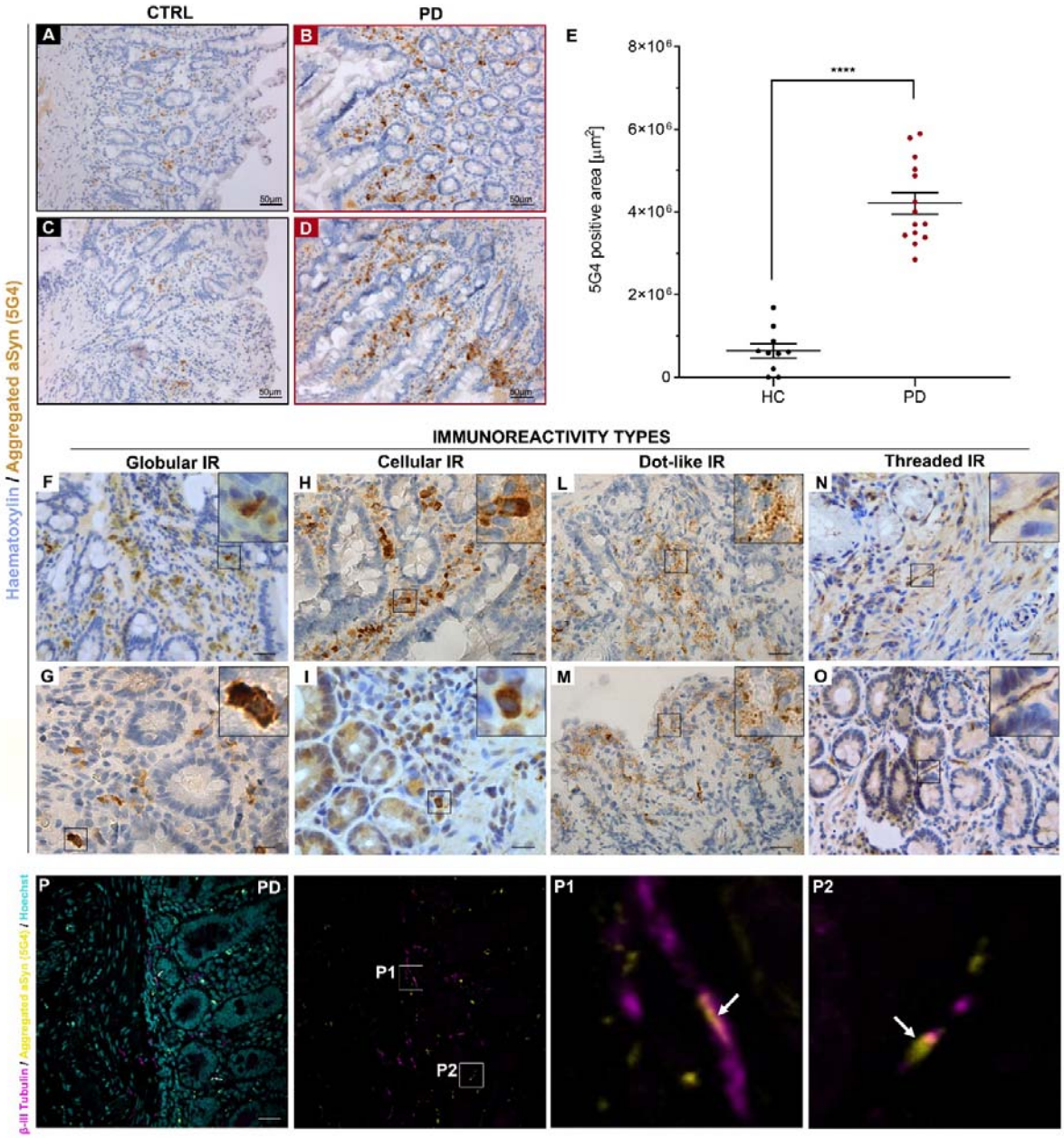
CTRL
PD
A
B
C
D
50µm
E
8×10⁶
6×10⁶
4×10⁶
2×10⁶
0
5G4 positive area [µm²]
****
HC
PD
Haematoxylin / Aggregated aSyn (5G4)
IMMUNOREACTIVITY TYPES
Globular IR
Cellular IR
Dot-like IR
Threaded IR
F
G
H
I
L
M
N
O
β-III Tubulin / Aggregated aSyn (5G4) / Hoechst
P
PD
P1
P2

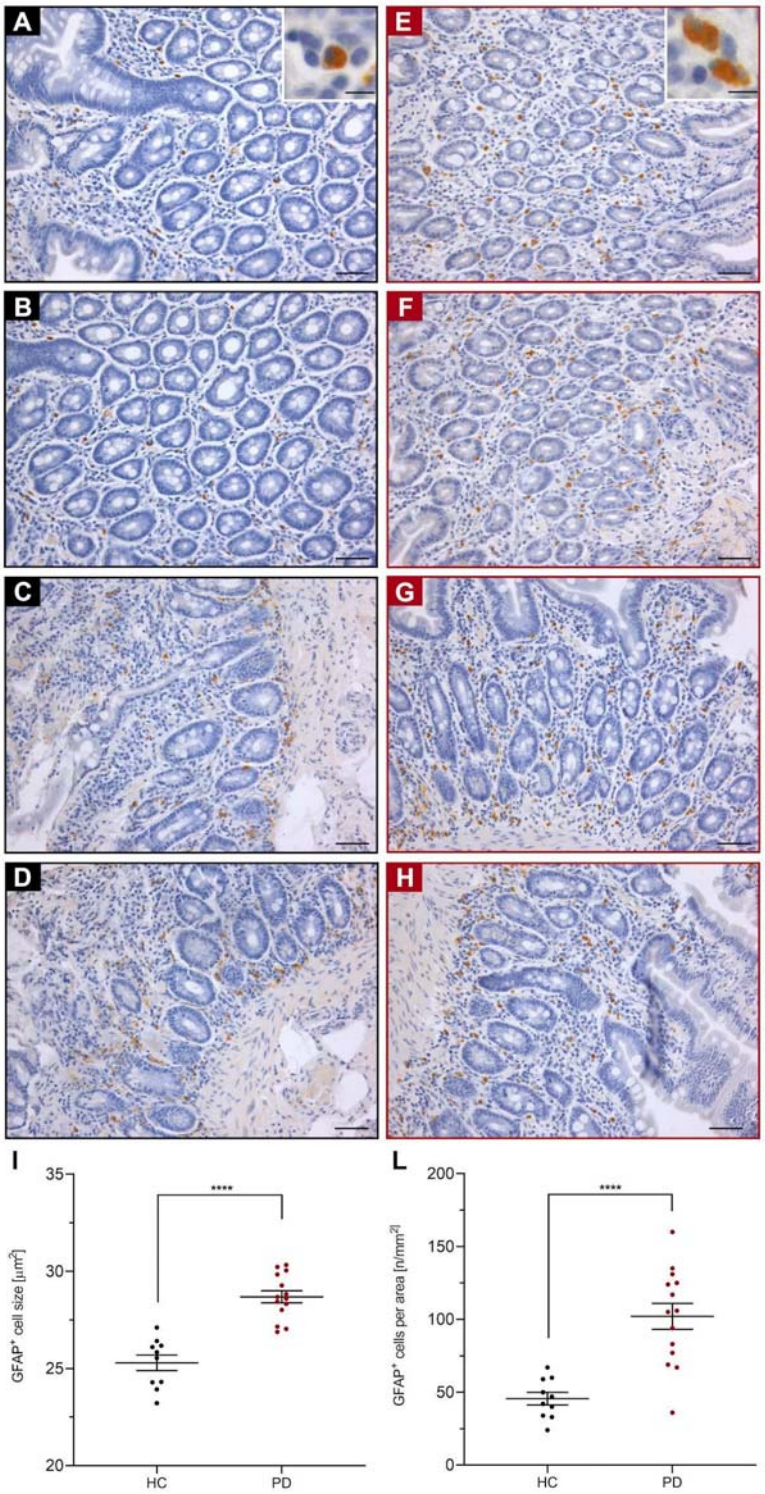
A
B
C
D
E
F
G
H
I
L
GFAP+ cell size [µm2]
35
30
25
20
****
HC
PD
GFAP+ cells per area [n/mm2]
200
150
100
50
0
****
HC
PD