Histopathological Characterization of Staged Lesion Topography in the Multiple Sclerosis Spinal Cord

Alex D. Waldman,[1,3] Cecilia Catania,[1] Marco Pisa[1], Mark Jenkinson[2], Michael Lenardo[3], and Gabriele C. De Luca[1]

Author Affiliations:

1 Academic Unit of Neuropathology, Nuffield Department of Clinical Neurosciences, John Radcliffe Hospital, Oxford, United Kingdom, OX3 9DU

2 Wellcome Center for Integrative Neuroimaging, Nuffield Department of Clinical Neurosciences, Oxford Centre for Functional MRI of the Brain, John Radcliffe Hospital, Oxford, United Kingdom, OX3 9DU

3 Molecular Development of the Immune System Section, Laboratory of Immune System Biology, National Institute of Allergy and Infectious Diseases, National Institutes of Health, Bethesda, MD, USA

Corresponding Author: Gabriele C. De Luca, M.D., D.Phil., FRCPath, FAAN. Associate Professor of Clinical Neurology, Nuffield Department of Clinical Neurosciences, University of Oxford. Director, Clinical Neurosciences Undergraduate Education, Oxford Medical School. Full Address: John Radcliffe Hospital, West Wing, Level 1, Department of Neuropathology, Headley Way, Headington, Oxford, United Kingdom, OX3 9DU. Email: gabriele.deluca@ndcn.ox.ac.uk

Abstract

Background: Spinal cord pathology is a major determinant of irreversible disability in progressive multiple sclerosis. The demyelinated lesion is a cardinal feature. Given the well-characterized anatomy of the spinal cord, the study of lesion topography and its extent of inflammatory activity may provide important clues about disease pathogenesis.

Methods: We studied a large cohort of cervical, thoracic, and lumbar spinal cord tissue derived from 119 pathologically confirmed multiple sclerosis cases. Immunohistochemistry was used to detect demyelination (proteolipid protein) and classify its inflammatory activity (CD68). Prevalence and distribution of demyelination, staged by lesion activity, was determined and topographical maps created to identify patterns of pathology using mixed models and permutation-based cluster analysis.

Results: Spinal cord lesions were observed in 76.5% of cases. Cases were more likely to harbour lesions at the cervical level compared to the lumbar region. Inflammatory activity (active or mixed active/inactive) was observed in 87.9% of cases. The distribution of lesions throughout the spinal cord mirrored the vascular network, spared the subpial surface, and consistently affected the dorsal columns, lateral corticospinal tracts, and the central canal. However, when present, subpial demyelination only affected a limited circumference of the spinal cord (<15%). Inflammatory lesions were more common in the white matter compared to grey matter. The presence of spinal cord lesions related strongly with clinical disease milestones, including time from onset to wheelchair and disease duration.

Conclusions: We demonstrate that spinal cord demyelination is common and highly inflammatory, has a predilection for the cervical level, and relates to clinical measures of disability even at late disease stages. Lesions relatively spare the subpial surface and instead preferentially affect the posterior and lateral columns and central canal, which points to a primary role of the vasculature in lesion pathogenesis. These findings fundamentally challenge the notion that demyelinating pathology in end-stage progressive multiple sclerosis is not inflammatory and that spinal cord lesions exhibit an outside-in topographical gradient. Taken together, this study highlights the importance of early intervention to target ongoing inflammatory demyelination and nominates vascular dysfunction as an important potential target to study further.

Introduction

The demyelinated lesion is the central hallmark of multiple sclerosis pathology.[1-6] While plaques were originally thought to be specific to the white matter, early studies quickly realized that the grey matter was not spared.[3,7,8] Heterogeneity in the extent and distribution of demyelination along the length of the neuraxis is a major contributor to the accumulation of irreversible disability.[9,10] The spinal cord represents a key anatomical site where demyelinating pathology underlies the sensorimotor manifestations that predominate the clinical profile of the disease, especially during the progressive phases.[11]

The etiopathogenesis of demyelinated lesions in multiple sclerosis is still the subject of much debate. Early neuropathological observations elegantly demonstrated that spinal cord lesion topography mirrors the architecture of the venous system.[3,4,12] Subsequent work by David Oppenheimer illustrated that plaques exhibit a strong predilection for the upper cervical cord in close opposition to the denticulate ligaments where tensile forces transmitted to the vasculature are likely strongest.[13] In contrast to this vascular-centric view of spinal cord lesion pathogenesis, more recent MRI studies have observed an outside-in gradient of demyelination in the cervical spinal cord that is most pronounced at surfaces in close opposition to the cerebrospinal fluid.

Given the lack of consensus regarding the vascular and meningeal contributions to the pathogenesis of spinal cord demyelination, we performed the largest neuropathological characterization of staged lesion topography along the length of the spinal cord to address this fundamental question. Compared to MRI approaches, neuropathology affords improved sensitivity for lesion detection and provides enhanced resolution to classify lesions by level of activity. Overall, we aimed to characterize the prevalence and distribution of staged lesions in the multiple sclerosis spinal cord and undercover nuanced relationships with clinical milestones obtained during life.

Methods

Study Population

A post-mortem cohort (n=119) of pathologically-confirmed MS cases derived from the United Kingdom MS Tissue Bank was available for study. Cases were selected based on the availability of formalin-fixed-frozen, paraffin-processed cervical, thoracic, and lumbar spinal cord material. Demographic, clinical, and pathological information was extracted from post-mortem reports (**Table 1**). Ethical approval was obtained (REC# 08/MRE09/31+5) and Human Tissue Act Guidelines were followed.

Neuropathological Assessment

Formalin-fixed-frozen, paraffin-processed material from the cervical, thoracic, and lumbar spinal cord was serially sectioned (6µm thick) before immunohistochemical evaluation of demyelination and myeloid cell inflammation by proteolipid protein (PLP) and CD68 primary antibodies, respectively. Immunohistochemical optimisation determined the appropriate antigen retrieval method, primary antibody concentration, and incubation conditions for staining (**Table 2**). Tissue was first deparaffinized and rehydrated. Endogenous peroxidase activity was quenched with 3% hydrogen peroxide prior to heat-induced antigen retrieval. Staining was performed using the semiautomatic Shandon Sequenza system. The DAKO envision DAB kit was used for signal development. Sections were counter-stained with hematoxylin. Omission of primary antibodies confirmed the specificity of the immunoreactions.

Slides were viewed on an Olympus BX43 Brightfield Microscope. Areas of demyelination were defined by complete loss of myelin in PLP-stained sections. Inflammatory activity of demyelinated lesions was assessed using established methods [14]. In short, lesion activity was classified broadly as 1) active, 2) mixed active/inactive, and 3) inactive by histologically assessing the abundance and distribution of myeloid cells in CD68-stained sections **(Figure 1)**. Active lesions exhibit a homogenous hypercellularity throughout the lesion environment. In contrast, mixed active/inactive lesions have a distinct topography that includes a hypocellular plaque core and palisading myeloid cells around the lesion rim. Lastly, inactive plaques are hypocellular throughout the lesion environment. Staged plaques were drawn by a trained microscopist (CC) onto standardized templates of cervical, thoracic, and lumbar spinal cord levels ensuring that proportionality of the affected regions was respected. A subset of cases

was also assessed by a trained neuropathologist (GDL) and consistent inter-rater reliability was observed. Representative histology images were captured using a Zeiss AxioCam MRc Color Camera.

Statistical Analysis

The following statistical analyses were performed in RStudio Version 1.4.1717. Lesion presence and proportion of the subpial circumference affected were used as an input for mixed effects logistic regression and zero-inflated beta regression using the glmmTMB package. Models included fixed effects terms of spinal cord level and lesion stage, where relevant, with a random effect of case. The emmeans package was used to extract estimated marginal means and assess the significance of pairwise comparisons.[15] A bias adjustment based on the value of sigma (standard deviation of the random effect) was applied. P-values were adjusted using the multivariate adjustment method. An adjusted p-value of 0.05 was used to define statistically significant comparisons. In addition, using the survival package, multivariate cox proportional hazards models were fit to understand the effects of lesion presence and inflammatory activity on clinical milestones obtained during life (time from onset wheelchair and time from onset to death) whilst controlling for sex and age of onset. Graphical representations of all results were created in Prism 9.

To identify lesion predilection sites, hand-drawn paper maps were digitized using the FMRIB Software Library (FSL). Non-parametric permutation-based cluster analysis was then used to generate probabilistic heatmaps of lesion distributions on a voxel-wise basis. In short, each voxel was designated as lesional or non-lesional and compared to a null distribution of 5000 permutations using randomly-assigned classes. Confounders (age, sex, and post-mortem interval) were included in the model to remove any potential statistical abberations.[16]

Results

Demographics

A total of 119 progressive MS cases contributed 102 cervical, 116 thoracic, and 107 lumbar spinal cord sections to the study for analysis. Cases with varied demographic profiles were included to maximize generalizability of the results (**Table 1**). In short, 83 cases were female (69.7%) and 36 were male (30.3%) with a mean age of 61.7 ± 12.5, disease duration of 28.4 ± 11.2 years, and time from onset to wheelchair of 17.3 ± 10.3 years. The mean post-mortem interval for the cohort was 16.7 ± 6.6.

Prevalence of Spinal Cord Demyelination and Inflammatory Activity

Across the cohort, 91/119 (76.5%) of cases harbored at least one lesion in the spinal cord with 80/91 (87.9%) exhibiting inflammatory demyelinating activity (active or mixed active/inactive lesions) (**Figure 2A**). Contrasts derived from logistic regression mixed models indicated that lesions were more likely to be present in the cervical spinal cord compared to the lumbar region (OR=10.01, SE=3.96, p=0.0056) (**Figure 2B**). Inflammatory sections predominanted over those that were found to be inactive at all spinal cord levels. However, when comparing across levels, sections from the cervical, thoracic, and lumbar spinal cord were equally likely to be inflammatory (**Figure 2C**).

Topography of Spinal Cord Demyelination and Inflammatory Activity

Representative histological patterns and summarized heatmaps of lesion predilection sites demonstrated that the dorsal columns, lateral corticospinal tracts, and the central canal were consistently affected by lesions. Interestingly, the subpial surface surrounding the spinal cord was spared across all spinal cord levels (**Figure 3A and 3B**). When stratified by inflammatory activity, inactive lesions predominated in the grey matter while lesions with inflammatory activity (active or mixed active/inactive) were common in the white matter (**Figure 3B**). A complementary analysis assessing lesion prevalence in the anterior, posterior, and lateral funiculi was undertaken (**Figure 4A**). The probability of a lesion affecting the lateral and posterior funiculi was consistently higher than the anterior funiculus (**Figure 4B**).

Extent and Distribution of Subpial Demyelination

Given the relative subpial sparing observed in histological sections, a more comprehensive analysis of demyelination at cerebrospinal fluid interfaces was undertaken. 76/119 (63.9%) cases exhibited demyelination of the white matter subpial surface with 61/76 (80.3%) exhibiting inflammatory demyelinating activity (active or mixed active/inactive lesions) (**Figure 5A**). Contrasts from derived from logistic regression mixed models indicated that subpial lesions were not significantly more likely to be at any spinal cord level (**Figure 5B**). Sections with inflammatory subpial involvement were more common than those that were found to be inactive. However, when comparing across levels, sections from the cervical, thoracic, and lumbar spinal cord were equally likely to have inflammatory subpial disease (**Figure 5C**). While subpial demyelination was observed to be common, the proportion of the subpial surface affected by lesions was observed to be low and did not differ significantly across levels (Cervical: 12.6%, Thoracic: 12.9%, Lumbar: 9.2%) (**Figure 5D**). Even when only considering cases that exhibited subpial involvement, the proportion of the subpial surface affected was still not striking (Cervical: 29.3%, Thoracic: 32.5%, Lumbar: 26.4%).

Clinicopathological Relationships

Given the heterogenous demographics of our large post-mortem cohort, we aimed to understand the relationship between spinal cord demyelination and clinical outcome. Time from disease onset to wheelchair and time from disease onset to death (disease duration) were used as surrogate markers of disease severity and response variables for multivariate cox proportional hazard analysis (**Figure 6A and 6B**). Given previous data, sex and age of onset were included as covariates in all analyses.[17] Cases with plaques present anywhere in the spinal cord were more likley to need use a wheelchair at a younger age (HR 2.45; 95% CI 1.43-4.20) and die earlier (HR 2.65; 95% CI 1.61-4.34). Earlier age of onset displayed a cosistent relationship with time to wheelchair and death in all analyses while sex was never a significant predictor of hazard. Interestingly, when comparing inflammatory and inactive cases, no significant differenes in time to wheelchair (HR 1.01; 95% CI 0.53-1.93) or time to death (HR 1.78 95% CI 0.93-3.38) were identified.

Discussion

Demyelination in the spinal cord, a cardinal feature of multiple sclerosis, has attracted particular attention over the years due to pathogenic insights that may be gleaned based on its topography. However, the study of the topography and morphology of spinal cord lesions has yielded discrepant interpretations and engendered considerable debate. Therefore, we performed the largest neuropathological characterization of the extent, distribution, and inflammatory activity of spinal cord lesions. We highlight that spinal cord lesions are a salient feature of multiple sclerosis pathology, are highly inflammatory, relate to clinical outcome, and display a unique distribution in which different anatomical compartments are differentially affected. These findings contribute novel insights into the topographical heterogeneity of multiple sclerosis demyelinating pathology and provide evidence that address conflicting views in the literature regarding the mechanisms involved in spinal cord demyelination.

Spinal cord demyelination was a common feature in our progressive multiple sclerosis cohort. It was present in 91/119 (76.5%) of cases. This is not surprising given that spinal cord involvement is included in the McDonald diagnostic criteria for multiple sclerosis to satisfy dissemination in space and imaging this structure has been reinforced by the 2021 MAGNIMS-CMSC-NAIMS consensus reccomendations.[18,19] Overall, the prevalence of spinal cord demyelination in our post-mortem cohort mirrors what has been seen in previous MRI studies that investigated demyelination across the entirety of the spinal cord.[20,21]

When stratified by level, 68/102 cases (66.7%), 66/116 cases (56.9%), and 52/107 cases (48.5%) harbored a lesion in the cervical, thoracic, and lumbar spinal cord, respectively. In general, this gradient of lesion prevalence along the entirety of the spinal cord recapitulates what has been seen in previous MRI studies of clinical cohorts.[20-22] However, our study identified many more thoracolumbar lesions. The fact that our study analyzed cases at the end of life may contribute to this discrepancy as our cohort has accumulated lesion burden throughout the length of the disease process. However, it is important to note that histopathology is the gold standard for detection of multiple sclerosis lesions, especially in difficult to image structures like the spinal cord. Therefore, it is likely that MRI assessment woefully underestimates lesion pathology in the lower levels of the spinal cord.

The extent of chronic inflammation in the multiple sclerosis spinal cord at end-stage disease has been relatively unexplored and our findings have proven to be striking. In cases with lesions, we detected evidence of demyelinating inflammatory activity (active or mixed active/inactive) in 80/91 (87.9%) cases. This goes against the notion that lesions become "burnt-out" at end-stage disease in a large proportion of individuals.[23,24] However, when stratified further, our data shows that the vast majority of inflammatory lesions are of the mixed active/inactive type and the contribution of active lesions to the ongoing inflammatory process in progressive MS is limited. MRI studies support this idea as contrast enhancing lesions decrease over the multiple sclerosis lifecycle and the presence of mixed active/inactive lesions by MRI has recently been appreciated with novel imaging sequences.[25-27] Overall, our results are in line with the idea that inflammatory activity within lesions is a common feature of multiple sclerosis pathology that warrants further exploration.[28]

Regarding lesion distribution, our study demonstrated that lesions throughout the length of the spinal cord neuraxis commonly affect the lateral corticospinal tracts, dorsal columns, and central canal. Lesions seemed to mirror the vascular network and spare the subpial zone. These findings are in line with previous pathological assessments and in contrast to a recent MRI-based report of a subpial gradient of demyelination in the spinal cord.[4,13,29] This discrepancy is likely because pathological studies have improved resolution to detect lesions. While 7T magnetic resonance imaging protocols improve lesion detection *in vivo* by upwards of 50%, many challenges remain that impede sensitivity. Given its small size, proximity to mobile tissues and fluids, relative shielding by bone and fat, visualization of the spinal cord is especially difficult.[30] The subpial signal changes may also reflect pathological processes apart from demyelination. Reactive microgliosis is a prime candidate as a subpial gradient of glial cell reactivity has also been observed in the spinal cord post-mortem.[31] Our data argues against an outside-in process of demyelination mediated by neurotoxic CSF but rather lends further support that mechanical forces at the denticulate ligament junction may contribute to vascular leakage and the downstream inflammatory cascade.[13] In fact, while work in the cortex has identified tertiary lymphoid follicles as major drivers of a gradient of cortical demyelination from the subpial surface inward, follicle positivity did not significantly increase the severity of demyelination in the spinal cord.[32] Representative images of demyelination from the study by Reali and colleagues also demonstrated that large portions of the subpial surface are spared in follicle positive individuals. We also illustrated that the demyelination is underrepresented in the anterior funiculus, an area where CSF stasis and meningeal inflammation is posited to be

at its highest. Discordant findings regarding the relative importance of CSF-derived factors and the vascular unit between the brain and spinal cord may be due to inherent topographical differences in 1) the mechanical forces imparted on these structures and 2) the intrinsic permeability of the blood-brain barrier (BBB) compared to the blood-spinal cord barrier (BSCB).[13,33] Overall, our findings suggest topographical differences play a major role in the pathogenesis of demyelination throughout the length of the neuraxis and that vascular mechanisms likely predominate in the spinal cord.

Our distributional analysis also allowed us to investigate differences between the white and grey matter of the spinal cord. Comparative analyses such as these have historically been inaccessible to MRI-based studies due to contrast and spatial resolution limitations.[34] In our work, inflammatory lesions commonly affected the white matter while inactive lesions demonstrated a predilection for the grey matter. This finding is in line with previous pathological studies that highlight a biologically-relevant difference between the pathogenesis of demyelination in the white and grey matter and continues to support a broader view of demyelination beyond the white matter.[8,35] Whether our findings support an entirely different pathogenic mechanism or a capacity for grey matter to better resolve inflammation remains to be seen and is the subject of future work.

Indexed clinical reports with metrics of disease outcome obtained during life allowed us to draw interesting clinicopathologic correlations. When controlling for sex and age of onset, spinal cord lesion presence were independent predictors of two definitive clinical endpoints, time from onset to wheelchair and death. These findings confirm the relevance of spinal cord demyelination to multiple sclerosis prognosis purported by MRI studies of clinical cohorts.[36-38] However, we did not observe that cases with inflammatory lesions had a significantly worse clinical course compared to inactive cases. This result is in direct contrast to a findings in a recent report by Luchetti et al.[28] The relatively small number of inactive cases (11) in our cohort likely contributed our inability to validate these findings.

We acknowledge the limitations inherent to neuropathological studies. Our case series represents the end-stage of the multiple sclerosis disease process. However, to address this, our study was powered by large sample sizes that are uncommon when working with post-mortem material, especially spinal cord. We also strategically included cases with heterogenous clinical trajectories defined during life to capture a more balanced spectrum of the disease. In our study, we employed strict criteria for the characterization of lesions. While this approach avoids any

possible confounding effects of pre-lesional or remyelinating areas, our lesion maps ultimately represent a static view of a dynamic process. In addition, our lesion maps are an extrapolation from individual spinal cord sections that were deemed representative of the cervical, thoracic, and lumbar levels. However, we attempted to mitigate this by transposing lesions for each case into a standard space. While measurement error is possible, anatomical landmarks were used to maintain proportional relationships required for downstream analyses and reliability was assessed with two expert raters. Paired statistical analyses also improved statistical power. In comparison to dedicated spinal cord MRI, our approach did not allow for the comprehensive profiling of lesion topography throughout the entirety of the spinal cord. However, we placed emphasis on relevant heterogeneity within each section and across levels more broadly (cervical, thoracic, and lumbar). Overall, compared to MRI, our histopathological approach provides increased sensitivity for lesion detection and enhanced resolution for the assessment of inflammatory activity.

In summary, we demonstrate that spinal cord lesions are an important feature of multiple sclerosis pathology. Spinal cord lesions are consistently inflammatory at end-stage disease, portend a worse clinical course, and exhibit a unique topographical pattern. The subpial zone is relatively spared across the cohort and lesion patterns mirror the trajectories of the vasculature (**Figure 7**). These findings begin to disentangle the complexities surrounding the relative contributions of the CSF and vascular unit to the pathogenesis of lesions in multiple sclerosis. Our study sets the stage for further exploration of the mechanisms that underly topographical variation in lesion biology along the length of the MS neuraxis.

Figures and Tables

Table 1. Post-mortem cohort demographics

		Multiple Sclerosis (*n*=119)
Number of Samples	*Cervical*	*102*
	Thoracic	*115*
	Lumbar	*106*
Disease Type*	*Primary Progressive*	18
	Secondary Progressive	91
	Relapsing-Remitting	1
	Unknown	9
Age (Mean ± SD)		61.7 ± 12.5
Sex (M:F)		36:83
Disease Duration in Years (Mean ± SD)*		28.4 ± 11.2
Time to Wheelchair (Mean ± SD)*		17.3 ± 10.3
PMI in Hours (Mean ± SD)		16.7 ± 6.6

*Data missing for disease type (*n*=9), disease duration (*n*=6), and time to wheelchair (*n*=20)

Table 2. Antibodies and conditions used for immunohistochemistry

Antibody	Clone	Classification	Antigen Retrieval	Dilution	Supplier	Catalogue Number
PLP	plpc	Mouse Monoclonal	Microwave, Citrate pH 6	1:1000	BioRad	MCA839 G
CD68	PGM1	Mouse Monoclonal	Microwave, Citrate pH 6	1:100	DAKO	M0876

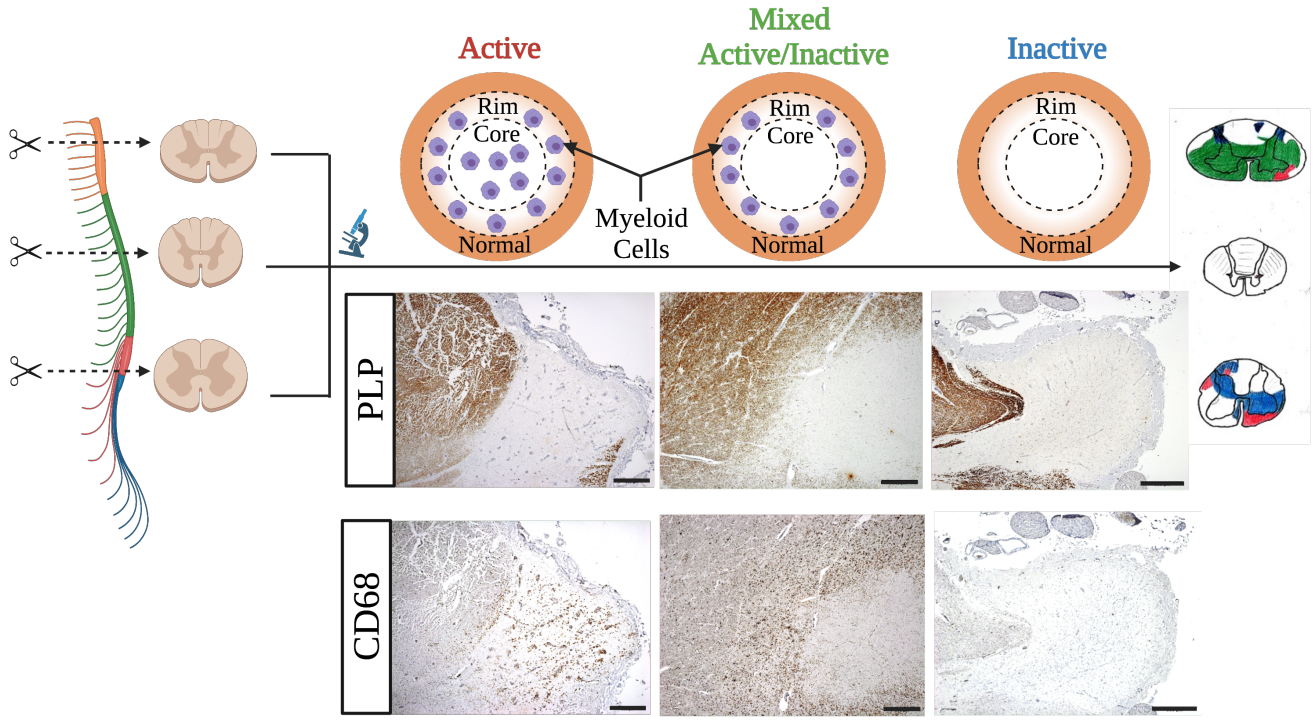

Figure 1. Methodological approach to assessing staged lesion topography. Spinal cord material from the cervical, thoracic, and lumbar region was sectioned and processed for immunohistochemistry to stain for myelin (PLP) and myeloid cells (CD68). Light microscopy was used to identify areas of complete myelin absence and infiltration by myeloid cells was used to stage each lesion (scale bars: 0.5mm). Staged lesions were carefully drawn onto standardized templates prior to downstream computational analyses.

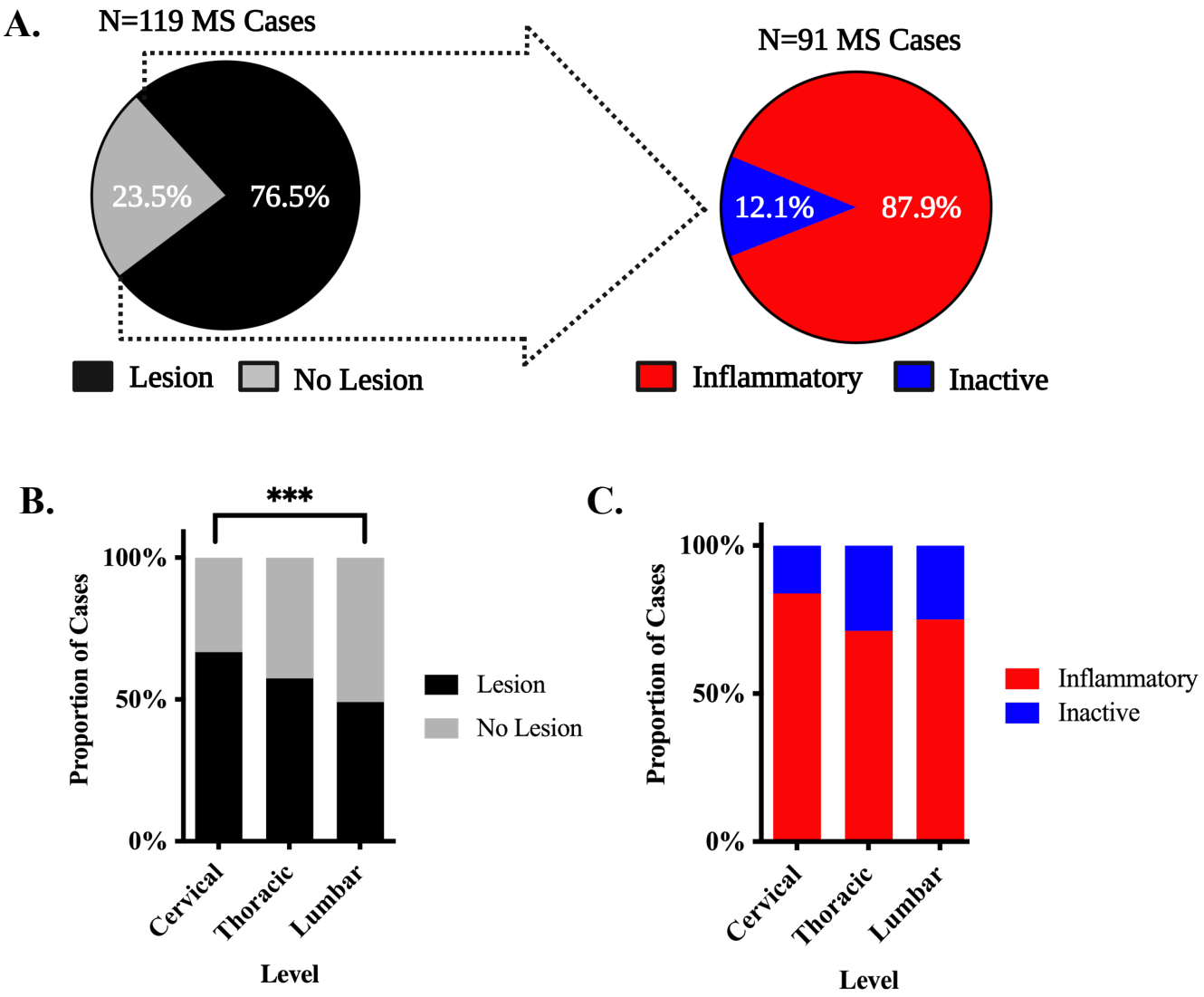

Figure 2. Prevalence of demyelination in the MS spinal cord. (A) Pie charts highlighting the observed proportion of cases with spinal cord lesions and those that harbored at least 1 inflammatory (active or mixed/active inactive) lesion. (**B-C**) Stacked bar charts depicting the proportion of MS cases that harbor lesions at each level of the spinal cord irrespective of stage (**B**) and classified by the presence of inflammation (**C**). Proportion values represent observed values and the asterisks indicate significant post-hoc pairwise comparisons following logistic mixed modelling (*p<0.05; **p<0.001; ***p<0.0001).

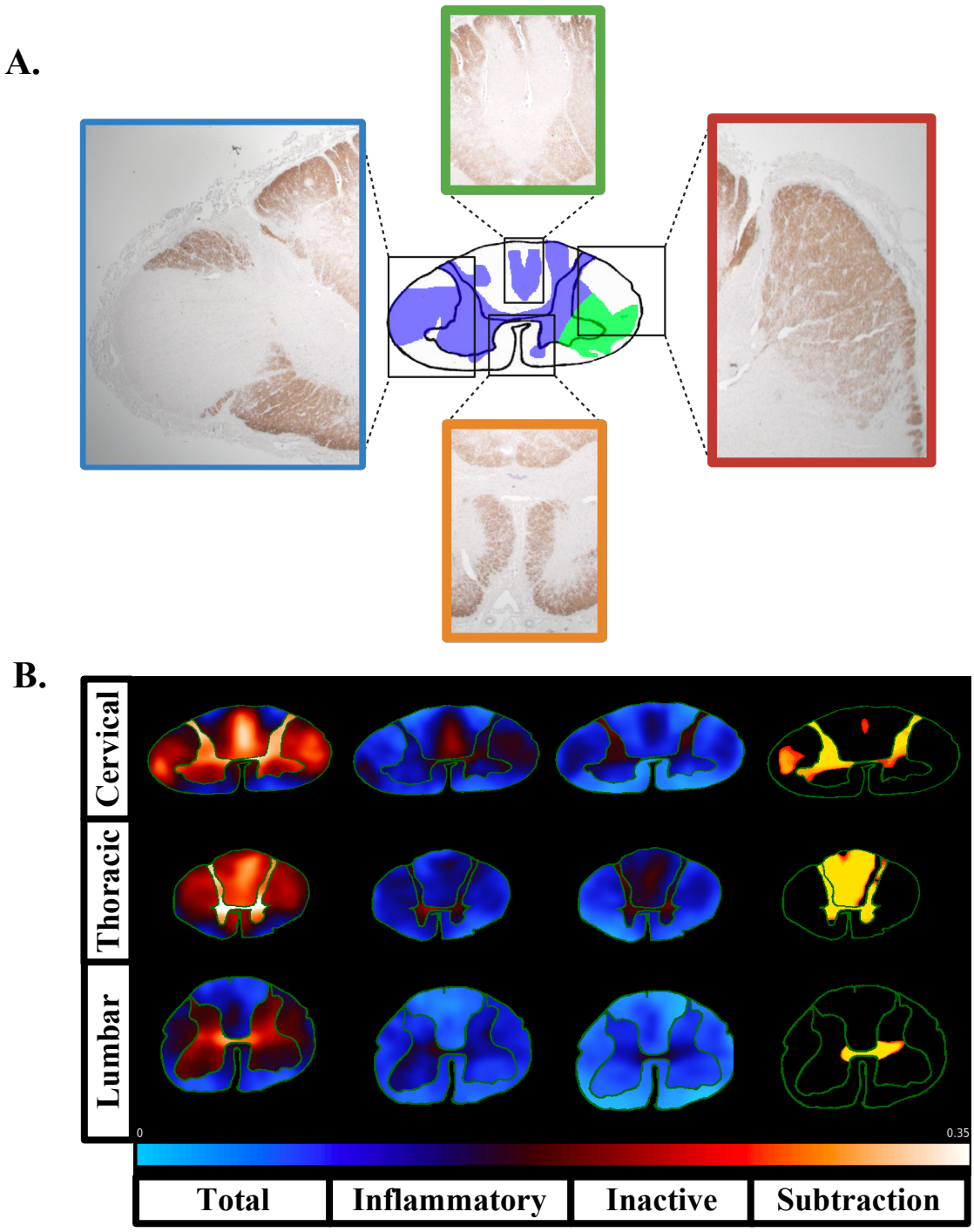

Figure 3. Pathological patterns of demyelination distribution. (A) Representative histological images of lesion distribution patterns. The dorsal columns (green box), lateral corticospinal tracts (red box), and the whole grey matter (orange box) were consistently affected throughout the cohort. Interestingly, the subpial surface was commonly spared (red, green, and orange boxes). However, when present, subpial demyelination only affected a limited circumference (blue box). **(B)** Heatmaps of lesion predilection sites generated from permutation-based cluster analyses.

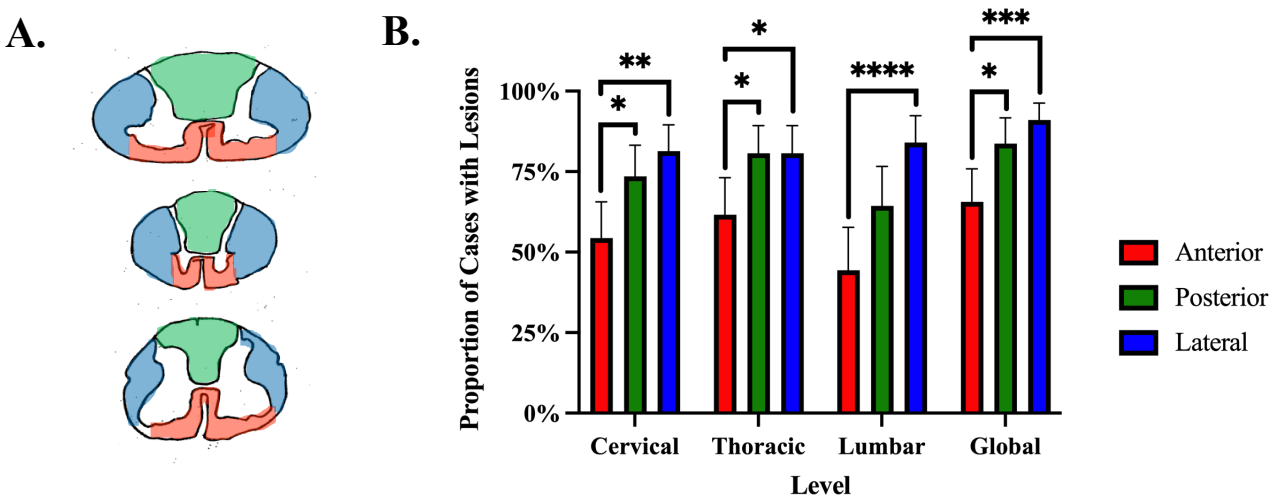

Figure 4. Funiculi affected by demyelination. (A) Cervical, thoracic, and lumbar sections with the anterior (red), posterior (green), and lateral (blue) funiculi highlighted. **(B)** Bar charts depicting the proportion of MS cases that exhibit demyelination of the anterior, posterior, and lateral funiculi at each level of the spinal cord and globally. Proportion values represent estimated marginal means and the 95% confidence interval derived from mixed logistic regression models. The asterisks indicate significant post-hoc pairwise comparisons (*converted pd to $p<0.05$; **converted pd to $p<0.001$; ***converted pd to $p<0.0001$).

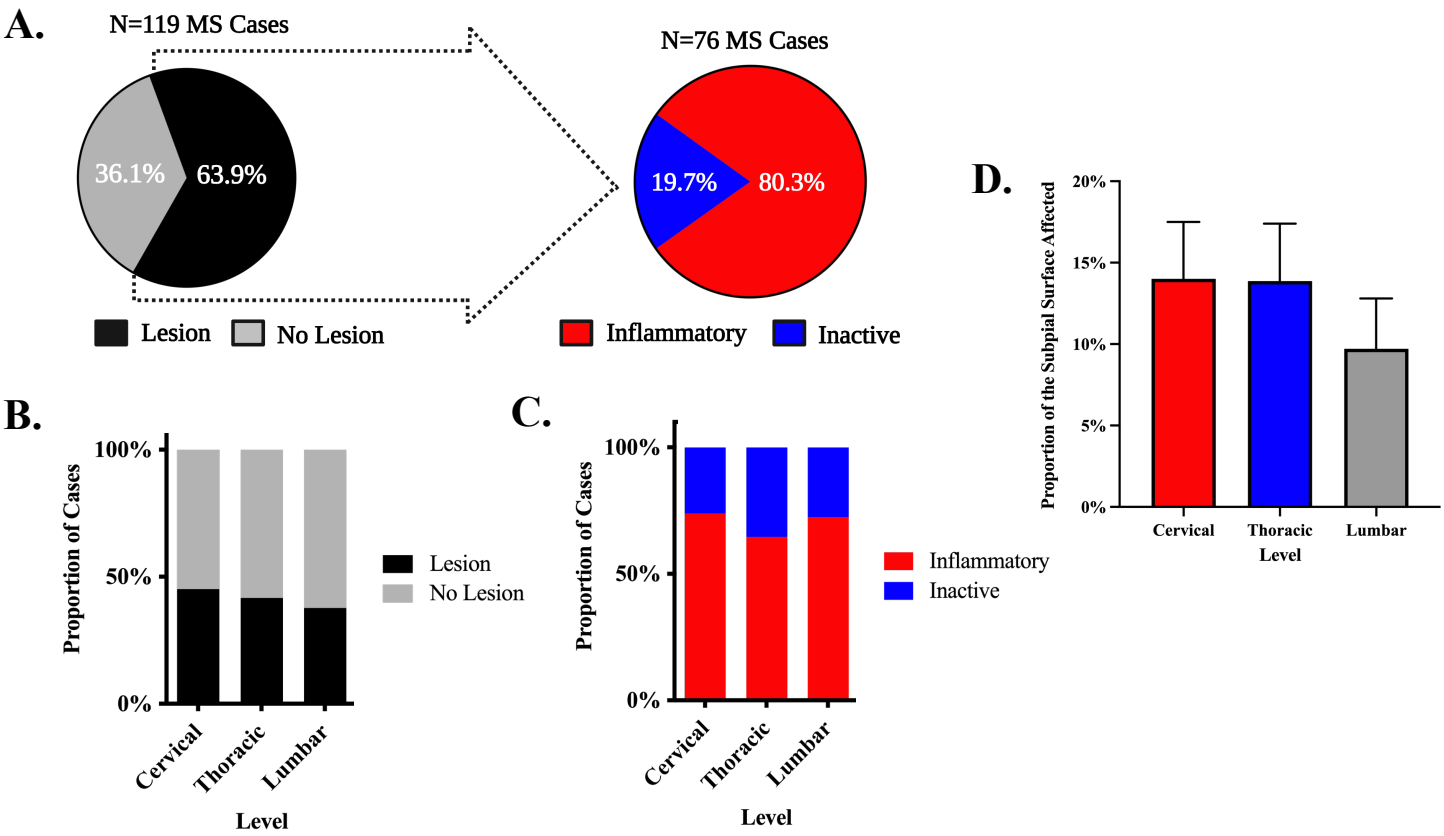

Figure 5. Prevalence and extent of subpial WM demyelination in the MS spinal cord. **(A)** Pie charts highlighting the observed proportion of cases with subpial WM spinal cord lesions and those that harbored at least 1 inflammatory (active or mixed/active inactive) subpial WM lesion. (**B-C**) Stacked bar charts depicting the proportion of MS cases that harbor subpial WM lesions at each level of the spinal cord irrespective of stage (**B**) and classified by the presence of inflammation (**C**). Proportion values represent observed values and the asterisks indicate significant post-hoc pairwise comparisons following logistic mixed modelling (*p<0.05; **p<0.001; ***p<0.0001). (**D**) Bar chart depicting the proportion of the subpial WM surface affected by lesions at each level of the spinal cord irrespective of stage. Proportion values represent estimated marginal means and the 95% credible interval derived from mixed zero-inflated beta regression models. The asterisks indicate significant post-hoc pairwise comparisons (* p<0.05; **p<0.001; ***p<0.0001).

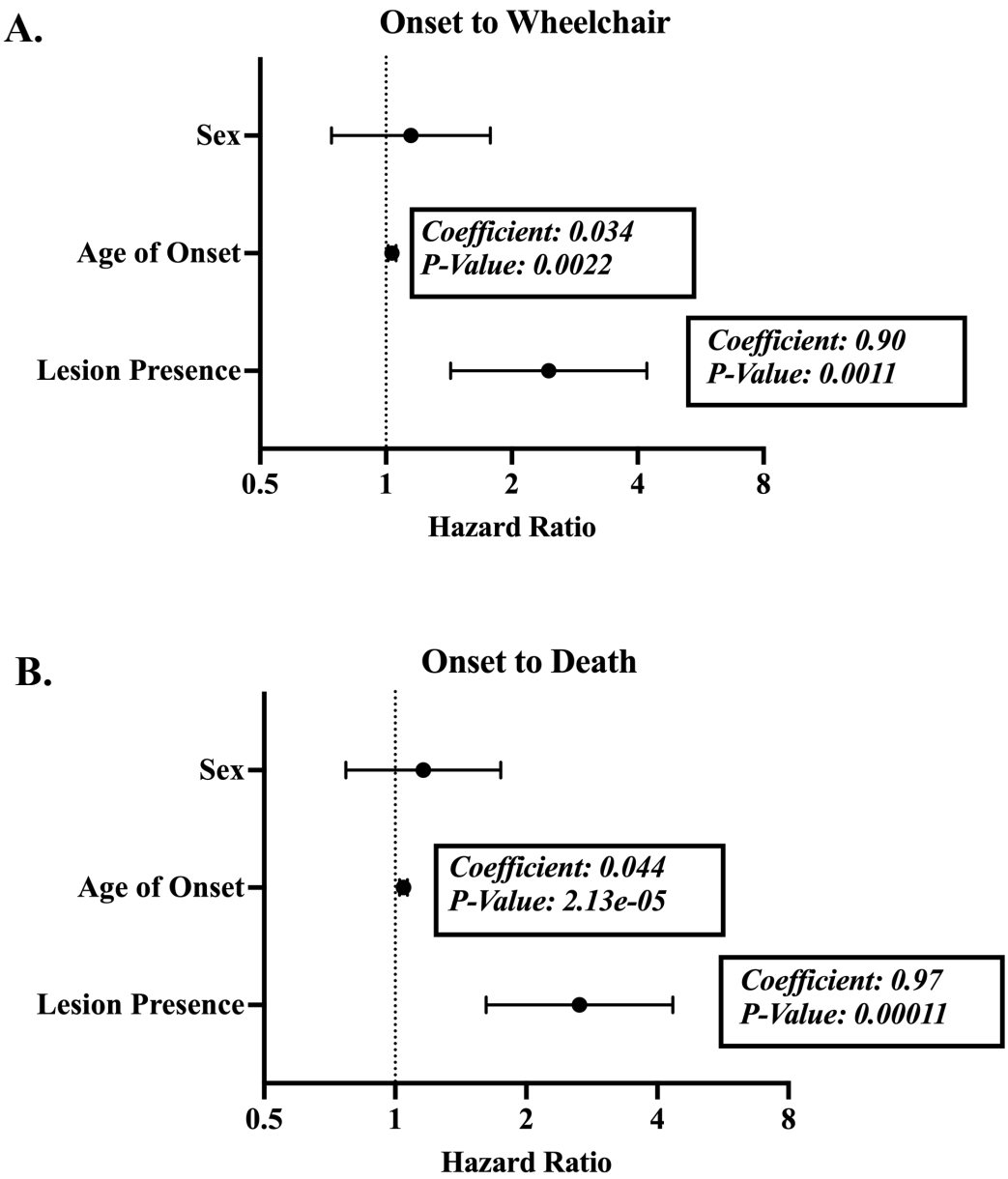

Figure 6. Clinicopathological relationships between demyelination and clinical milestones. Forest plots displaying the hazard ratio and 95% confidence interval are derived from multivariate cox proportional hazards models. The impact of spinal cord lesion presence on the time from onset to wheelchair (**A**) and onset to death (**B**) was tested whilst controlling for sex and age of onset. Coefficients and p-values are displayed for significant predictors ($p<0.05$) in the models.

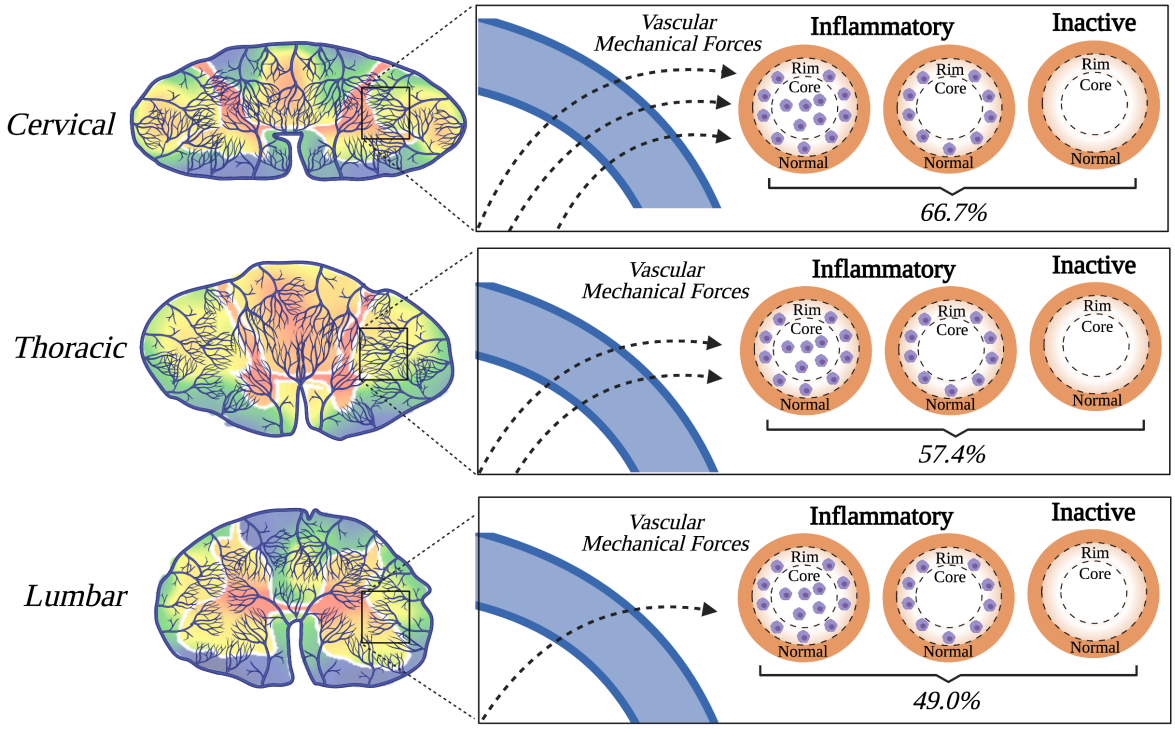

Figure 7. Working hypothesis. The topography of lesional pathology in the spinal cord across all levels spares the subpial surface and mirrors the distribution of venous drainage. The cervical spinal cord is more susceptible to chronic inflammatory demyelination when compared to the thoracic and lumbar regions. Heterogeneity in mechanical stress along the length of the spinal cord is hypothesized to underlie this enhanced susceptibility. Mobility of the cervical spinal cord is prominent and posited to transmit tensile forces onto the vasculature, ultimately promoting barrier dysfunction and myelinotoxic immune cell infiltration.

Data Sharing

The data that support the findings of this study are available from the corresponding author, upon reasonable request.

Declaration of Interests

Acknowledgements

A.D.W. was supported by the Emory University MD/PhD Program, NIH MD/PhD Partnerships Program, and NIH Oxford–Cambridge Scholars Program. The authors would like to thank the United Kingdom MS Tissue Bank as well as patient donors and their family members for the provision of spinal cord tissue and clinical information required to undertake this study. The authors also thank Jon Fitzi from the NIAID Biostatistics Research Branch and the GitHub community for biostatistical advice. Lastly, the authors acknowledge that Figure 1 was created with BioRender.com using the National Institutes of Allergy and Infectious Diseases (NIAID) institutional license. GC De Luca is supported by the NIHR Biomedical Research Centre (BRC), Oxford and has research funding from the Oxford BRC, MRC(UK), National Health and Medical Research Council (NHMRC), UK MS Society, the Oxford-Quinnipiac Partnership.

References

1. Charcot JM. Sclrose des cordons latÈraux de la moelle ÈpiniËre chez une femme hystÈrique atteinte de contracture permanente des quatre membres. [Paris]: [Typographie F. Malteste]; 1865.

2. Vulpian E. Note sur la sclérose en plaques de la moelle épinière. *L'Union Médicale* 1866; **30**: 459-65.
3. Dawson JW. The Histology of Disseminated Sclerosis. *Edinb Med J* 1916; **17**(4): 229-41.

4. Fog T. Topographic distribution of plques in the spinal cord in multiple sclerosis. *Archives of Neurology & Psychiatry* 1950; **63**(3): 382-414.

5. Fog T. The topography of plaques in multiple sclerosis with special reference to cerebral plaques. *Acta neurologica Scandinavica Supplementum* 1965; **15**: 1-161.

6. Rindfleisch E. Histologisches Detail zu der grauen Degeneration von Gehirn und Rückenmark. (Zugleich ein Beitrag zu der Lehre von der Entstehung und Verwandlung der Zelle.). *Archiv für pathologische Anatomie und Physiologie und für klinische Medicin* 1863; **26**(5): 474-83.

7. Bø L, Vedeler CA, Nyland HI, Trapp BD, Mørk SJ. Subpial demyelination in the cerebral cortex of multiple sclerosis patients. *Journal of neuropathology and experimental neurology* 2003; **62**(7): 723-32.

8. Gilmore CP, Bö L, Owens T, Lowe J, Esiri MM, Evangelou N. Spinal cord gray matter demyelination in multiple sclerosis-a novel pattern of residual plaque morphology. *Brain Pathol* 2006; **16**(3): 202-8.

9. Kerbrat A, Gros C, Badji A, et al. Multiple sclerosis lesions in motor tracts from brain to cervical cord: spatial distribution and correlation with disability. *Brain* 2020; **143**(7): 2089-105.

10. Reich DS, Lucchinetti CF, Calabresi PA. Multiple Sclerosis. *The New England journal of medicine* 2018; **378**(2): 169-80.

11. Rovaris M, Bozzali M, Santuccio G, et al. Relative contributions of brain and cervical cord pathology to multiple sclerosis disability: a study with magnetisation transfer ratio histogram analysis. *Journal of neurology, neurosurgery, and psychiatry* 2000; **69**(6): 723-7.

12. Adams CW, Abdulla YH, Torres EM, Poston RN. Periventricular lesions in multiple sclerosis: their perivenous origin and relationship to granular ependymitis. *Neuropathol Appl Neurobiol* 1987; **13**(2): 141-52.

13. Oppenheimer DR. The cervical cord in multiple sclerosis. *Neuropathol Appl Neurobiol* 1978; **4**(2): 151-62.

14. Kuhlmann T, Ludwin S, Prat A, Antel J, Brück W, Lassmann H. An updated histological classification system for multiple sclerosis lesions. *Acta Neuropathol* 2017; **133**(1): 13-24.

15. Searle SR, Speed FM, Milliken GA. Population Marginal Means in the Linear Model: An Alternative to Least Squares Means. *The American Statistician* 1980; **34**(4): 216-21.

16. Kincses ZT, Ropele S, Jenkinson M, et al. Lesion probability mapping to explain clinical deficits and cognitive performance in multiple sclerosis. *Mult Scler* 2011; **17**(6): 681-9.

17. Confavreux C, Vukusic S. Age at disability milestones in multiple sclerosis. *Brain* 2006; **129**(Pt 3): 595-605.

18. Thompson AJ, Banwell BL, Barkhof F, et al. Diagnosis of multiple sclerosis: 2017 revisions of the McDonald criteria. *The Lancet Neurology* 2018; **17**(2): 162-73.

19. Wattjes MP, Ciccarelli O, Reich DS, et al. 2021 MAGNIMS–CMSC–NAIMS consensus recommendations on the use of MRI in patients with multiple sclerosis. *The Lancet Neurology* 2021; **20**(8): 653-70.

20. Weier K, Mazraeh J, Naegelin Y, et al. Biplanar MRI for the assessment of the spinal cord in multiple sclerosis. *Mult Scler* 2012; **18**(11): 1560-9.

21. Bot JCJ, Barkhof F, Polman CH, et al. Spinal cord abnormalities in recently diagnosed MS patients. *Neurology* 2004; **62**(2): 226.

22. Poulsen EN, Olsson A, Gustavsen S, Langkilde AR, Oturai AB, Carlsen JF. MRI of the Entire Spinal Cord—Worth the While or Waste of Time? A Retrospective Study of 74 Patients with Multiple Sclerosis. *Diagnostics* 2021; **11**(8).

23. Frischer JM, Bramow S, Dal-Bianco A, et al. The relation between inflammation and neurodegeneration in multiple sclerosis brains. *Brain* 2009; **132**(Pt 5): 1175-89.

24. Frischer JM, Weigand SD, Guo Y, et al. Clinical and pathological insights into the dynamic nature of the white matter multiple sclerosis plaque. *Ann Neurol* 2015; **78**(5): 710-21.

25. Absinta M, Sati P, Masuzzo F, et al. Association of Chronic Active Multiple Sclerosis Lesions With Disability In Vivo. *JAMA Neurology* 2019; **76**(12): 1474-83.

26. Khaleeli Z, Ciccarelli O, Mizskiel K, Altmann D, Miller DH, Thompson AJ. Lesion enhancement diminishes with time in primary progressive multiple sclerosis. *Mult Scler* 2010; **16**(3): 317-24.

27. Dal-Bianco A, Grabner G, Kronnerwetter C, et al. Slow expansion of multiple sclerosis iron rim lesions: pathology and 7 T magnetic resonance imaging. *Acta Neuropathol* 2017; **133**(1): 25-42.

28. Luchetti S, Fransen NL, van Eden CG, Ramaglia V, Mason M, Huitinga I. Progressive multiple sclerosis patients show substantial lesion activity that correlates with clinical disease severity and sex: a retrospective autopsy cohort analysis. *Acta Neuropathol* 2018; **135**(4): 511-28.

29. Ouellette R, Treaba CA, Granberg T, et al. 7 T imaging reveals a gradient in spinal cord lesion distribution in multiple sclerosis. *Brain* 2020; **143**(10): 2973-87.

30. Bruschi N, Boffa G, Inglese M. Ultra-high-field 7-T MRI in multiple sclerosis and other demyelinating diseases: from pathology to clinical practice. *European Radiology Experimental* 2020; **4**(1): 59.

31. Grussu F, Schneider T, Tur C, et al. Neurite dispersion: a new marker of multiple sclerosis spinal cord pathology? *Ann Clin Transl Neurol* 2017; **4**(9): 663-79.

32. Reali C, Magliozzi R, Roncaroli F, Nicholas R, Howell OW, Reynolds R. B cell rich meningeal inflammation associates with increased spinal cord pathology in multiple sclerosis. *Brain Pathology* 2020; **30**(4): 779-93.

33. Bartanusz V, Jezova D, Alajajian B, Digicaylioglu M. The blood-spinal cord barrier: morphology and clinical implications. *Ann Neurol* 2011; **70**(2): 194-206.

34. Moccia M, Ruggieri S, Ianniello A, Toosy A, Pozzilli C, Ciccarelli O. Advances in spinal cord imaging in multiple sclerosis. *Therapeutic advances in neurological disorders* 2019; **12**: 1756286419840593-.

35. Gilmore CP, Donaldson I, Bö L, Owens T, Lowe J, Evangelou N. Regional variations in the extent and pattern of grey matter demyelination in multiple sclerosis: a comparison between the cerebral cortex, cerebellar cortex, deep grey matter nuclei and the spinal cord. *Journal of neurology, neurosurgery, and psychiatry* 2009; **80**(2): 182-7.

36. Sombekke MH, Wattjes MP, Balk LJ, et al. Spinal cord lesions in patients with clinically isolated syndrome: a powerful tool in diagnosis and prognosis. *Neurology* 2013; **80**(1): 69-75.

37. Brownlee WJ, Altmann DR, Alves Da Mota P, et al. Association of asymptomatic spinal cord lesions and atrophy with disability 5 years after a clinically isolated syndrome. *Mult Scler* 2017; **23**(5): 665-74.

38. Arrambide G, Rovira A, Sastre-Garriga J, et al. Spinal cord lesions: A modest contributor to diagnosis in clinically isolated syndromes but a relevant prognostic factor. *Mult Scler* 2018; **24**(3): 301-12.