Effects of gender-affirming hormone therapy on gray matter density, microstructure and monoamine oxidase A levels in transgender subjects

Handschuh PA*[1], Reed MB*[1], Murgaš M[1], Vraka C[2], Kaufmann U[3], Nics L[2], Klöbl M[1], Ozenil M[2], Konadu ME[1], Klebermass EM[2], Spurny-Dworak B[1], Wadsak W[2], Hahn A[1], Hacker M[2], Spies M[1], Baldinger-Melich P[1], Kranz GS[1,4], Lanzenberger R[1 #]. (*contributed equally)

[1] Department of Psychiatry and Psychotherapy, Medical University of Vienna, Austria

[2] Department of Biomedical Imaging and Image-guided Therapy, Division of Nuclear Medicine, Medical University of Vienna, Austria.

[3] Department of Obstetrics and Gynecology, Medical University of Vienna, Austria

[4] Department of Rehabilitation Sciences, Hong Kong Polytechnic University, Hong Kong, China

For submission to:

medRxiv

Word count	315	Abstract
	3932	Main section
Figures: 3, Tables: 1, References: 82		

[#] Correspondence to:

Prof. Rupert Lanzenberger, MD, PD

Email: rupert.lanzenberger@meduniwien.ac.at

ORCID: https://orcid.org/0000-0003-4641-9539

Telephone: +43 (0)1 40400-35760

Abstract

Alterations in gray matter (GM) and monoamine oxidase A (MAO-A) distribution across the brain have been found in various neuropsychiatric conditions. MAO-A catalyzes the oxidative degradation of various monoamines and is thus implicated in neuroplastic processes that influence GM density (GMD) and microstructure (GMM) of the brain. Sex-specific differences in these patterns are well documented, however studying the long-term effects of certain sex steroids on the brain are limited due to hormonal fluctuations under naturalistic conditions. Due to the exact monitoring of plasma hormone levels and sex steroid intake, transgender individuals undergoing gender-affirming hormone therapy represent a valuable cohort to investigate such changes of GM and concomitant MAO-A density. Here, we investigated the effects of long-term gender-affirming hormone therapy over a median time period of 4.5 months on GMD and GMM as well as MAO-A distribution volume. To this end, 20 cisgender women, 11 cisgender men, 20 transgender women and 10 transgender men were recruited. All participants underwent two MRI scans in a longitudinal design. PET scans using [^{11}C]harmine were performed before each MRI session in a subset of 35 individuals. Between baseline and follow-up imaging, transgender subjects underwent gender-affirming hormone therapy. GM changes determined by diffusion weighted imaging (DWI) metrics for GMM and voxel based morphometry (VBM) for GMD were estimated using repeated measures ANOVA. Regions showing significant changes of both GMM and GMD were used for the subsequent analysis of MAO-A density. These involved the fusiform gyrus, rolandic operculum, inferior occipital cortex, middle and anterior cingulum, bilateral insula, cerebellum and the lingual gyrus (post-hoc tests: $p_{FWE+Bonferroni} < 0.025$). In terms of MAO-A distribution volume, no significant effects were found. The present results are indicative of a reliable influence of gender-affirming hormone therapy on GMD and GMM following an interregional pattern. Nevertheless, future studies with larger sample sizes are needed to further investigate the relationship between sex steroids, gray matter alterations and MAO-A density.

Introduction

As pointed out in several reviews, meta- and mega-analyses that have been published over the last decades, a multitude of studies on sex-specific differences in brain structure have been performed, with many of them pointing towards significant effects of not only sex but also sex steroids in terms of global, inter- and intra-regional brain morphology (1-5). On average, female brains are smaller than that of males (6). Significant differences between male and female brains were also found regarding gray and white matter (WM) volumes (7, 8). Nevertheless, some studies failed to detect such differences in gray matter (GM) volume on a global scale, despite adjustment for total brain size (9). Both region-of-interest (ROI)-based approaches and voxel-wise analyses allow for the examination and classification of highly specific cortical and subcortical regions and thus shedding light on a vast number of potential regional and/or local sex differences (3-5). However, a closer look to the current evidence reveals some inconsistent results, questioning the theory of a sexually dimorphic brain and pointing towards a lack of features found reliably at one end of the continuum between typically female and male brains (10).

Even though previous literature has reported conflicting results, it is known that sex hormones are centrally involved in the biological mechanisms that drive sex-specific differences in brain structure. Hence, ongoing research focusing on the interaction of cycling sex steroid levels with components of the central nervous system is essential. Sex steroids are known to have both transcriptional as well as non-genomic effects (11-13), modifying the brain throughout the lifespan (14-17). Thus, distributional differences in sex hormone receptors across the brain (18-20) as well as sex-specific differences in axonal characteristics (21), neuroplasticity (22) and neurogenesis (23) can be found. Additionally, sex steroids are known to directly interact with various neurotransmitters (24-26) and their metabolism, e.g., by modulating the activity of cerebral MAO-A activity. This has already been shown in a number of animal models (27-30) and selected human studies (31),

however *in vivo* imaging data acquired via positron emission tomography (PET) remains scarce (32-34) and studies investigating the direct effects of exogenously administered sex hormones on cerebral MAO-A are specifically underrepresented (35). A further gap in the literature that needs to be addressed is given by studies investigating the effect of *MAOA* gene polymorphisms that were shown to interact with GM changes – despite knowledge on the influence of MAOA VNTR polymorphism on brain structure volumes (36), cortical thickness (37) and gray matter (38), the association of MAO-A protein expression as measured in human *in vivo* studies and GM is insufficiently investigated. Taking into account the relevance of MAO-A density and subsequent neurotransmitter metabolism on neuroplastic effects (39-41) and thus GM in the brain, the link between MAO-A distribution and GM needs to be explored with multimodal imaging techniques. Taking into account the additional effect of sex steroids on both MAO-A density (32-34) as well as GM (7, 8), sex-specific interrelations of MAO-A density and GM might be of specific interest.

Individuals with gender dysphoria (GD) receiving gender-affirming hormone therapy (GHT) represent a unique cohort to investigate the direct effects of sex hormones on human brain structure. As described in the 5th edition of the Diagnostic and Statistical Manual of Mental Disorders (DSM-V), GD is defined as an incongruence between the biological sex assigned at birth and the experienced gender later in life (42). GHT basically involves the long-term administration of an estrogen and a type of androgen blocker in transgender women (TW), whereas the masculinization of transgender men (TM) can be supported by testosterone treatment (43). As summarized by Kranz and colleagues, structural changes of the brain were observed after GHT in a wide range of studies (44), with effects of testosterone treatment on total brain volume (45, 46), GM and WM density (47-49) as well as cortical thickness, showing controversial results in the latter (47, 50). In terms of estrogen and antiandrogen treatment, a decrease in cortical thickness (47), total brain (45) as well as total GM and WM volume (46) was shown. Changes in diffusivity as it was found after sex steroid treatment both in TM and TW might be traced back to changes in the organizational properties of neural fibers (e.g., axon diameter, fiber density, myelin staining) (44). On a

molecular level, high-dose testosterone treatment was shown to influence the distribution volume (V_T) of MAO-A in transgender individuals (33).

In this longitudinal study, we aimed to investigate changes to brain morphology and microstructure and further explore the corresponding effects on MAO-A binding in transgender individuals after long-term GHT. To reveal alterations in gray matter density (GMD) and gray matter microstructure (GMM) via MRI, voxel-based morphometry (VBM) and diffusion weighted imaging (DWI) were applied. In a subset of participants, PET imaging using [^{11}C]harmine was conducted to uncover the effect of sex steroid treatment on cerebral MAO-A density and to elucidate potential interrelations between hormonally induced GM changes and alterations in MAO-A V_T.

Methods

This study was performed according to the Declaration of Helsinki, taking into account all current revisions and good scientific practice guidelines of the Medical University of Vienna. The study protocol was approved by the Ethics Committee of the Medical University of Vienna (EC number 1104/2015) and registered at clinicaltrials.gov (NCT02715232).

Participants

Twenty cisgender women (CW), 11 cisgender men (CM), 20 TW and 10 TM men were enrolled in the study. Transgender subjects were recruited at the Unit for Gender Identity Disorder at the Department of Obstetrics & Gynecology, Division of Gynecologic Endocrinology and Reproductive Medicine, Medical University of Vienna, Austria. Control subjects were recruited via designated message boards at the Medical University of Vienna and at other universities in Vienna as well as via social media platforms. CW and CM were age and education level matched to TW and TM, respectively. Importantly, for transgender individuals, inclusion criteria comprised a diagnosis of gender dysphoria as defined in the Diagnostic and Statistical Manual for Mental Disorders), version 5 (DSM-5: 302.85) or the International Classification of Diseases, version 10 (ICD-10: F64.1). Moreover, the absence of severe psychiatric, neurologic or internal comorbidities was ensured in case of study enrollment based on medical history, physical examination, electrocardiogram, laboratory screening and structural clinical interview (SCID) for DSM-V. All subjects gave written informed consent to take part in this study and received financial compensation for their participation. Subjects were excluded in case of major neurological or internal illnesses, pregnancy, current substance abuse (excluding smoking), any kind of pathologic laboratory values, GHT or any other treatment with exogenous sex hormones within 6 months prior to study enrollment, MRI contraindications, current or past substance-related disorder or non-compliance (all subjects), any kind of current or prior psychiatric diagnosis (CW and CM) or severe DSM-V comorbidities (TW and TM) as well as current (TW and TM) or prior (CW and CM) treatment with psychotropic agents.

Study design

All subjects underwent two MRI scans separated by a median time period of 4.5 months following a longitudinal study design. Each MRI session included structural (T1- and diffusion-weighted), task-based and resting-state MRI as well as MR spectroscopy. For the current analyses, only structural MRI data was used. Thirty-five subjects (9 CW, 8 CM, 7 TW and 11 TM), underwent PET scan(s) that were performed before MRI acquisition using the radiotracer [^{11}C]harmine. After the baseline imaging sessions, transgender subjects received GHT. Plasma hormone levels were assessed via blood draw right before or after each baseline and follow-up imaging session.

Medication

The following GHT protocol was applied at the Department of Obstetrics & Gynecology, Division of Gynecologic Endocrinology and Reproductive Medicine, Medical University of Vienna, Austria: TM were treated with either 1000 mg testosterone undecanoat every 8-16 weeks (Nebido 1000 mg / 4 ml i.m.), or up to 50 mg testosterone daily (Testogel 50 mg/day or Testavan 23 mg/pump 1-2 pumps/day or testosterone crème as a magistral formula 12,5 mg/pump 3-4 pumps/day transdermally). If menstruation was still observed, transgender male participants received either lynestrenol (Orgametril 5 mg 2-3 tablets/day p.o.) or desogestrel (Moniq Gynial or Cerazette 0.075 mg/day p.o.). TW received cyproterone acetate daily (Androcur 50 mg/day) and either estradiol transdermally (Estramon 100 µg transdermal patch 2x/week or Estrogel gel 0.75-1.5 mg/day transdermally) or oral estradiol (Estrofem 4 mg/day p.o.). In case of extensive hair loss, an alpha-5-reductase-inhibitor was prescribed (Finasterid 2.5 mg/48h Actavis/Arcana/Aurobindo p.o.). Furthermore, selected participants were treated with GnRH-analogues like triptorelin (decapeptyl 0.1 mg/day subcutaneously).

Sex steroid monitoring

Levels of luteinizing hormone (LH), follicle-stimulating hormone (FSH), progesterone, estradiol, testosterone, sex hormone binding globulin (SHBG) and dehydroepiandrosterone

sulfate were assessed via blood analysis at baseline and after a median time period of 4.5 months involving GHT in transgender subjects and no treatment in cisgender controls.

Magnetic resonance imaging acquisition

All MRI data were recorded using a Siemens Prisma 3T scanner and a 64-channel head coil. A whole-brain T1-weighted scan was acquired with the following parameters: TE / TR = 2.91 / 2000 ms; inversion time = 900 ms; flip angle = 9°; matrix = 240 x 256, 176 slices; voxel size = 1.0 mm^3; acquisition time = 7:59 min. Diffusion weighted images contained 64 diffusion encoded images, with a b-value of 800 s/mm^2 along with 7 non-diffusion (b=0) images (TE / TR=76 / 9400 ms, slice thickness = 1.6 mm, resolution=1.6 x 1.6 mm, matrix size=128 x 128 x 75, flip angle = 90°, acquisition time = 11:54 min). Subjects were instructed to stay awake with eyes open and keep their head as still as possible during the entire scan to minimize movement artifacts.

Positron emission tomography

Synthesis and quality control of [^{11}C]harmine, (7-[^{11}C]methoxy-1-methyl-9H-pyrido[3,4-b]indole) were performed as previously published (51). All PET scans were performed using a GE Advance full-ring scanner (General Electric Medical Systems, Milwaukee, WI, USA) at the Department of Biomedical Imaging and Image-guided Therapy, Division of Nuclear Medicine, Medical University of Vienna (52-54). A 5 min transmission scan was done at the beginning of the scan for tissue attenuation correction. Data acquisition started simultaneously with an intravenous bolus injection of [^{11}C]harmine (4.6 MBq/kg body weight). Ninety minutes of PET data were acquired in 3D mode and reconstructed using an iterative filtered backprojection algorithm, which was separated into 51 time frames with a spatial resolution of 4.36 mm with a FWHM of 1 cm next to the center of the field of view and reconstructed in 35 transaxial sectional volumes (128 × 128 matrix). Automatic arterial blood sampling was performed during the first 10 min at a rate of 4 ml/min (ALLOGG, Mariefred, Sweden) and manual samples were taken at 5, 6, 7, 8, 10, 20, 40, 60, and 80 min after bolus start (55). A gamma counter previously cross-calibrated to the PET scanner was used to

measure radioactivity concentrations in both whole blood and plasma. Furthermore, samples at 6, 7 and 8 min were used for individual cross-calibration between manual and automated blood sampling. Fractions of radioactive metabolites and the parent compound were determined with HPLC as described previously (56).

MRI data processing

Voxel-based morphometric changes were calculated and processed in the CAT12 toolbox (http://www.neuro.uni-jena.de/cat/, version r1742) in MATLAB (version 9.8) using the longitudinal pipeline with default settings unless otherwise specified. Prior to preprocessing, raw data was visually inspected for potential artifacts. In short, the T1 images from both time points were co-registered, resampled and bias-corrected. Each scan was then skull stripped and segmented into GM, white matter and cerebrospinal fluid, and resulting GMD was further used. Finally, GMD maps were normalized into MNI space and spatially smoothed using an 8-mm Gaussian kernel. Lastly, the CAT12 reports and data were visually controlled for registrations and segmentation errors.

As an estimate for GMM changes, DWI data was processed within the FMRIB software library (FSL, v. 6.0.05) (57) and unring (https://bitbucket.org/reisert/unring), ANTs (https://github.com/ANTsX/ANTs), MRtrix (https://www.mrtrix.org/) according to an optimized pipeline (58). All data was brain-masked, corrected for noise, movement, gradient, Gibbs ringing, bias field and eddy current distortions as well as for outliers in the form of signal dropouts (58). The diffusion tensors were fitted using the “dtifit” command as well as the rotated b-vectors and then smoothed using a 1 mm kernel (58). Mean diffusivity (MD) estimates were calculated and co-registered with the participant- and measurement-specific segmented GMD map. Thereafter, all images were normalized into MNI space and subsequently the GMD segmentation was thresholded and used to mask out non-GM voxels. Finally, the DWI MD estimates were smoothed using an 8 mm Gaussian kernel and masked again.

PET data processing and MAO-A quantification

MAO-A quantification was carried out using PMOD 3.509 (PMOD Technologies Ltd., Zurich, Switzerland; www.pmod.com). Whole blood data was fitted with the sum of three exponentials from the peak onward, plasma-to-whole blood ratio was fitted with a linear function and the parent fraction was modeled with a Watabe function. The arterial input function (AIF) was obtained by multiplying the fitted whole blood activity, plasma-to-whole blood ratio and the fraction of intact radioligand in plasma. The Logan plot was used to quantify voxel-wise MAO-A total V_T with the thalamus as high uptake region. Regional V_T were extracted using the activation map created from the overlap between GMD and DWI analyses.

Statistics

Structural changes determined by the MD DWI metric and GMD were estimated using 4 x 2 (group x time) repeated measures ANOVA (rmANOVA) implemented in SPM12. Interactions between group (TM, TW, CW, CM) by time (before and after min. 4 months of hormone therapy) were examined and further corrected for multiple testing using Gaussian random field theory as implemented in SPM12 and the threshold for significance was set at $p \leq 0.025$ family-wise error (FWE)-corrected according to (59) at the cluster-level following $P \leq 0.001$ uncorrected at the voxel-level. Further post-hoc comparisons and number of DWI metrics were adjusted again using the Bonferroni method. To account for the individualized GHT treatment, progesterone, testosterone and estradiol were added to both rmANOVA models as covariates. Furthermore, the total intracranial volume was added as a covariate in the VBM model. For both the GMD and DWI models each covariate was standardized, and group mean centered.

To provide a robust identification of hormonally induced gray matter alterations, the different structural changes reflected by both the GMD and DWI analyses were combined. The significant effects from both models were binarized and a conjunction map across both

imaging modalities was calculated as an intersection. The remaining brain regions included in this conjunction map were used for the subsequent MAO-A V_T analysis.

Interaction effects in MAO-A V_T before and after GHT for both cis- and transgender individuals were estimated using a linear mixed model in SPSS 25.0 (SPSS Inc., Chicago, Illinois; www.spss.com). Here, the global model consisted of group, time and ROI (extracted from the conjunction map) as factors and MAO-A V_T as the dependent variable. The model was reduced in case of non-significance. Again, the Bonferroni method was used to correct for multiple comparisons.

Results

Demographics and hormone levels are listed in table 1. Fewer TW and matched CM were recruited when compared to TM and CW. Due to irreversible damage to the PET imaging equipment, 35 participants partook in the PET part of the study, where only 17 completed both scans, see table 1 for a detailed breakdown of subgroups. Out of the 35 participants that underwent the PET scans, only 52 scans were suitable for further analysis.

Structural and MAO-A changes after GHT

For both the VBM and DWI analyses, significant 2-way (time-by-group) interaction effects were found. More widespread structural changes after a median of 4.5 months GHT using VBM were discovered, when compared to MD, see figure 1a + b. Combining the results from VBM and DWI analyses showed an overlap of changes in the fusiform gyrus, rolandic operculum, inferior occipital cortex, middle and anterior cingulum and insula, cerebellum and the lingual gyrus (figure 1c). Post-hoc tests revealed changes in GMD, see figure 2 and also for MD, figure 3, ($p_{FWE + Bonferroni} < 0.025$). An increase in GMD was found in the fusiform gyrus, cerebellum and lingual gyrus after GHT for transmen compared to both control groups. Transwomen contrastingly showed a decrease in GMD after GHT in the rolandic operculum, insula, posterior cingulum, cerebellum and lingual gyrus when compared to both cismales and cisfemales.

The opposite interaction effects were found in the MD of the fusiform and lingual gyrus for transmales compared to both cis control groups. An increase of MD in the insula was also found for transwomen after GHT when compared to both control groups.

When investigating regional changes in MAO-A V_T, no interaction and no main effects were significant.

Discussion

The present study aimed to investigate potential changes to GM and MAO-A density induced by GHT over a median time period of 4.5 months in subjects with GD. To reveal robust changes in both GD, morphometric differences in GMD and microstructural alterations as reflects by GMM were combined and subsequently used for assessment of MAO-A V_T. Significant changes in GMD and GMM after GHT that will be discussed in the following section were found in nine distinct brain regions. Across these regions, no significant changes of MAO-A V_T were found.

Structural changes after GHT

Significant 2-way (time-by-group) interaction effects induced by GHT, as reflected by both the VBM and DWI analyses, were found in the fusiform gyrus, rolandic operculum, inferior occipital cortex, middle and anterior cingulum, bilateral insula, cerebellum as well as the lingual gyrus. As discussed in the following section, our findings are in line with prior studies reporting significant changes in GMD and GMM. Moreover, in comparison to cross-sectional data (60-64), our longitudinal designallows for more accurate interpretation.

Fusiform gyrus:

As various other regions presenting significant changes to GMD and GMM reported here, the fusiform gyrus is implicated in own-body perception in the context of self (49, 65) and is known to show different functional connectivity patterns in GD when compared to cisgender controls (49). These functionally different patterns might be reflected by structural differences as well. Here, we found a GHT-induced increase of GMD and decrease of MD (as a marker for GMM) in the fusiform gyrus of TM, potentially indicating anticatabolic effects of testosterone (44, 66).

Cerebellum

A meta-analysis performed by Ruigrok et al. found that males have larger gray matter volumes than females in cerebellar regions (3). Interestingly, we found higher GMD after GHT in the cerebellum of TM as well as TW when compared to both CM and CW. Since both androgenizing as well as feminizing (of note, to a lesser extent) GHT resulted in increased cerebellar GMD, the question arises which mechanisms interact with exogenously administered sex steroids irrespective of whether androgens or estrogens are taken. As reviewed by Hammes and Levin, estrogens and androgens are similar in structure, and aromatization of androgens to estrogens with subsequent estrogen binding on estrogen receptors in the CNS is hypothesized to play an important role for typically male behavioral traits (67) in general. The cerebellum contains various estrogen receptors such as estrogen receptor alpha, estrogen receptor beta as well as GPR-30 (68, 69). Additionally, purkinje cells located in the cerebellum express multiple enzymes needed for intracerebral steroidogenesis, most importantly, cytochrome P450 aromatase that drives estrogen synthesis via testosterone aromatization (70, 71). In a human *in vivo* PET study (72), a high amount of aromatase was found in the cerebellum, where aromatase inhibition via letrozole was relatively low (indicating a more robust aromatase activity in comparison to other brain regions), suggesting a possible trait for the similar influence of both sex steroids on GMD found in this study.

Lingual gyrus, bilateral insula and posterior cingulum:

After androgenization of TM, Zubiaurre-Elorza and colleagues found a significant increase of cortical thickness in multiple brain regions, e.g., the left lingual gyrus (47). This is in line with our finding, however in the present study, GMD of the lingual gyrus increased and MD decreased bilaterally across TM after high-dose testosterone treatment. Of note, the lingual gyrus is centrally involved in processing visual information and thus visuospatial functioning. As men, on average, perform better than women in visuospatial functioning, and testosterone has been suggested to directly influence visuospatial functioning both in men (73) as well as women (74), it could be hypothesized that advantages in this skill could partially be traced

back to an interrelation of higher GMD and and lower and the influence of high-dose testosterone treatment. In addition, we found a significant decrease in GMD across the insula as well as the posterior cingulum of TW when compared to CW and CM. The insula belongs to the salience network (75), which plays a central role for interoceptive processes and own-body perception (65). Differences in functional connectivity were further shown in language and affective processing (76, 77) as well as in various neuropsychiatric conditions (78, 79). However, sex-based differences between cisgender men and women regarding the insula were not only shown in functional MRI, but also in structural analyses (3) and investigations of the GABAergic system in humans (80). Thus, changes to GMD might be seen as a marker for microstructural remodeling induced by estrogen and anti-androgen therapy, as it is needed for multifactorial adaptations that take place throughout GHT (49, 81). Our findings are in line with prior reports on decreased GMD, higher MD reflecting microstructural changes, and widespread cortical thinning in anti-androgen and estrogen treatment across TW (46, 47).

Changes to MAO-A distribution

In view of sexually dimorphic characteristics of multiple neuropsychiatric conditions, better understanding of how sex steroids interact with neurotransmitters on a molecular level, e.g., as reflected by MAO-A density, is of major interest. In the present study, none of the subgroups showed significant changes to MAO-A V_T in any of the brain regions that were found to be different in terms of GMD and GMM after GHT. In contrast, in a prior analysis of MAO-A density after GHT performed by our group, we found statistically significant reductions of MAO-A V_T in six of twelve previously defined regions of interest in TM after GHT for at least 4 months. These regions included the middle frontal cortex (−10%), anterior cingulate cortex (−9%), medial cingulate cortex (−10.5%), insula (−8%), amygdala (−9%) and hippocampus (−8.5%, all $p<0.05$)) (33). Of note, in the study by Kranz et al. regional MAOA V_T was estimated based on *a priori* defined regions-of-interest (ROIs) from a modified AAL atlas (33, 82), whereas here, MAO-A analysis was performed in regions that showed significant GMD and GMM changes after GHT.

Limitations

Some limitations of the present study need to be addressed. First, subgroups were not sufficiently balanced due to recruitment difficulties, especially in case of subjects with gender dysphoria. Second, the subgroup that underwent PET imaging comprised only 17 individuals due to irreparable damages to the PET equipment. Therefore, it cannot be ruled out that potential GHT-induced changes in MAO-A V_T both on a global as could not be detected in the present analyses.

Conclusion

Long-term GHT seems to have a considerable impact on GMD and GMM in the brain of transgender individuals. Specific effects of either androgenizing or feminizing sex steroids must be taken into account in most regions, however, in selected structures both types of GHT affected GMD and GMM in the same way, pointing towards mechanisms that are induced by GHT irrespective of whether feminizing or androgenizing steroids are used. The combined approach in analyzing structural MRI data has the potential to shed light on changes of GM as reflected by both morphometric as well as microstructural analyses after GHT in a longitudinal design and in comparison to cisgender individuals. Nevertheless, larger sample sizes are needed to detect reliable associations between GM and potential MAO-A density changes induced by GHT.

Acknowledgments

This research was funded in whole, or in part, by the Austrian Science Fund (FWF) [Grant number KLI 504, PI: Rupert Lanzenberger]. M. Murgaš is funded by the Austrian Science Fund (FWF) [Grant number DOC 33-B27, Supervisor R. Lanzenberger]. MB. Reed and M. Klöbl are recipients of a DOC fellowship of the Austrian Academy of Sciences at the Department of Psychiatry and Psychotherapy, Medical University of Vienna. This project was performed with the support of the Medical Imaging Cluster of the Medical University of Vienna, and by the grant „Interdisciplinary translational brain research cluster (ITHC) with highfield MR" from the Federal Ministry of Science, Research and Economy (BMWFW), Austria. We thank the graduated team members and the diploma students of the Neuroimaging Lab (NIL, headed by R. Lanzenberger) as well as the clinical colleagues from the Department of Psychiatry and Psychotherapy of the Medical University of Vienna for clinical and/or administrative support. In particular, we would like to thank R. Seiger (MRI) and L. Rischka (PET) for technical and methodological support and V. Ritter for administrative help. We would also like to thank N. Berroterán-Infante, T. Balber, C. Philippe for assistance with radioligand synthesis, K. Rebhan for radioligand metabolite processing, I. Leitinger, H. Ibeschitz, V. Weiss for assistance with PET measurements, and V. Pichler, M. Mitterhauser, T. Traub-Weidinger and S. Kasper for project supervision.

Conflict of Interest

With relevance to this work there is no conflict of interest to declare. R. Lanzenberger received travel grants and/or conference speaker honoraria within the last three years from Bruker BioSpin MR, Heel, and support from Siemens Healthcare regarding clinical research using PET/MR. He is a shareholder of the start-up company BM Health GmbH since 2019. G.S. Kranz declares that he received conference speaker honorarium from Roche, AOP Orphan and Pfizer. P. Handschuh received authorship honoraria from MedMedia Verlag. The other authors report no conflict of interest.

Data availability statement

Due to data protection laws processed data is available from the authors upon reasonable request. Please contact rupert.lanzenberger@meduniwien.ac.at with any questions or requests.

References

1. Cosgrove KP, Mazure CM, Staley JK. Evolving Knowledge of Sex Differences in Brain Structure, Function, and Chemistry. Biological psychiatry. 2007;62(8):847-55.

2. Luders E, Kurth F. Structural differences between male and female brains. Handbook of clinical neurology. 2020;175:3-11.

3. Ruigrok AN, Salimi-Khorshidi G, Lai MC, Baron-Cohen S, Lombardo MV, Tait RJ, et al. A meta-analysis of sex differences in human brain structure. Neuroscience and biobehavioral reviews. 2014;39(100):34-50.

4. Kong X-Z, Mathias SR, Guadalupe T, Glahn DC, Franke B, Crivello F, et al. Mapping cortical brain asymmetry in 17,141 healthy individuals worldwide via the ENIGMA Consortium. Proceedings of the National Academy of Sciences. 2018;115(22):E5154-E63.

5. Guadalupe T, Mathias SR, vanErp TGM, Whelan CD, Zwiers MP, Abe Y, et al. Human subcortical brain asymmetries in 15,847 people worldwide reveal effects of age and sex. Brain Imaging Behav. 2017;11(5):1497-514.

6. Allen JS, Damasio H, Grabowski TJ. Normal neuroanatomical variation in the human brain: an MRI-volumetric study. American journal of physical anthropology. 2002;118(4):341-58.

7. Gur RC, Turetsky BI, Matsui M, Yan M, Bilker W, Hughett P, et al. Sex differences in brain gray and white matter in healthy young adults: correlations with cognitive performance. The Journal of neuroscience : the official journal of the Society for Neuroscience. 1999;19(10):4065-72.

8. Luders E, Gaser C, Narr KL, Toga AW. Why Sex Matters: Brain Size Independent Differences in Gray Matter Distributions between Men and Women. The Journal of Neuroscience. 2009;29(45):14265.

9. Nopoulos P, Flaum M, O'Leary D, Andreasen NC. Sexual dimorphism in the human brain: evaluation of tissue volume, tissue composition and surface anatomy using magnetic resonance imaging. Psychiatry Res. 2000;98(1):1-13.

10. Joel D, Berman Z, Tavor I, Wexler N, Gaber O, Stein Y, et al. Sex beyond the genitalia: The human brain mosaic. Proceedings of the National Academy of Sciences. 2015;112(50):15468-73.

11. Singh M, Su C, Ng S. Non-genomic mechanisms of progesterone action in the brain. Frontiers in neuroscience. 2013;7:159.

12. Kawata M, Nishi M, Matsuda K, Sakamoto H, Kaku N, Masugi-Tokita M, et al. Steroid receptor signalling in the brain--lessons learned from molecular imaging. J Neuroendocrinol. 2008;20(6):673-6.

13. Simoncini T, Genazzani AR. Non-genomic actions of sex steroid hormones. European journal of endocrinology. 2003;148(3):281-92.

14. Koolschijn PCM, Peper JS, Crone EA. The influence of sex steroids on structural brain maturation in adolescence. PloS one. 2014;9(1):e83929.

15. Pike CJ. Sex and the development of Alzheimer's disease. Journal of neuroscience research. 2017;95(1-2):671-80.

16. Knickmeyer RC, Wang J, Zhu H, Geng X, Woolson S, Hamer RM, et al. Impact of sex and gonadal steroids on neonatal brain structure. Cerebral cortex (New York, NY : 1991). 2014;24(10):2721-31.

17. Mills KL, Lalonde F, Clasen LS, Giedd JN, Blakemore SJ. Developmental changes in the structure of the social brain in late childhood and adolescence. Social cognitive and affective neuroscience. 2014;9(1):123-31.

18. O□sterlund MK, Gustafsson J-Ak, Keller E, Hurd YL. Estrogen receptor β (ERβ) messenger ribonucleic acid (mRNA) expression within the human forebrain: distinct distribution pattern to ERα mRNA. The Journal of Clinical Endocrinology & Metabolism. 2000;85(10):3840-6.

19. Brinton RD, Thompson RF, Foy MR, Baudry M, Wang J, Finch CE, et al. Progesterone receptors: Form and function in brain. Frontiers in Neuroendocrinology. 2008;29(2):313-39.

20. Fernández-Guasti A, Kruijver FP, Fodor M, Swaab DF. Sex differences in the distribution of androgen receptors in the human hypothalamus. Journal of Comparative Neurology. 2000;425(3):422-35.

21. Ibanez C, Shields SA, El-Etr M, Leonelli E, Magnaghi V, Li WW, et al. Steroids and the reversal of age-associated changes in myelination and remyelination. Progress in neurobiology. 2003;71(1):49-56.

22. Baroncini M, Jissendi P, Catteau-Jonard S, Dewailly D, Pruvo J-P, Francke J-P, et al. Sex steroid hormones-related structural plasticity in the human hypothalamus. NeuroImage. 2010;50(2):428-33.

23. Heberden C. Sex steroids and neurogenesis. Biochemical pharmacology. 2017;141:56-62.

24. Di Paolo T. Modulation of brain dopamine transmission by sex steroids. Reviews in the neurosciences. 1994;5(1):27-42.

25. Dubol M, Epperson CN, Sacher J, Pletzer B, Derntl B, Lanzenberger R, et al. Neuroimaging the menstrual cycle: A multimodal systematic review. Frontiers in Neuroendocrinology. 2021;60:100878.

26. Zheng P. Neuroactive steroid regulation of neurotransmitter release in the CNS: action, mechanism and possible significance. Progress in neurobiology. 2009;89(2):134-52.

27. Luine VN, McEwen BS. Effect of oestradiol on turnover of type A monoamine oxidase in brain. Journal of neurochemistry. 1977;28(6):1221-7.

28. Holschneider DP, Kumazawa T, Chen K, Shih JC. Tissue-specific effects of estrogen on monoamine oxidase A and B in the rat. Life Sci. 1998;63(3):155-60.

29. Smith LJ, Henderson JA, Abell CW, Bethea CL. Effects of ovarian steroids and raloxifene on proteins that synthesize, transport, and degrade serotonin in the raphe region of macaques. Neuropsychopharmacology : official publication of the American College of Neuropsychopharmacology. 2004;29(11):2035-45.

30. Bethea CL, Phu K, Kim A, Reddy AP. Androgen metabolites impact CSF amines and axonal serotonin via MAO-A and -B in male macaques. Neuroscience. 2015;301:576-89.

31. Klaiber EL, Broverman DM, Vogel W, Peterson LG, Snyder MB. Individual differences in changes in mood and platelet monoamine oxidase (MAO) activity during hormonal replacement therapy in menopausal women. Psychoneuroendocrinology. 1996;21(7):575-92.

32. Rekkas PV, Wilson AA, Lee VW, Yogalingam P, Sacher J, Rusjan P, et al. Greater monoamine oxidase a binding in perimenopausal age as measured with carbon 11-labeled harmine positron emission tomography. JAMA psychiatry. 2014;71(8):873-9.

33. Kranz GS, Spies M, Vraka C, Kaufmann U, Klebermass E-M, Handschuh PA, et al. High-dose testosterone treatment reduces monoamine oxidase A levels in the human brain: A preliminary report. Psychoneuroendocrinology. 2021;133:105381.

34. Sacher J, Wilson AA, Houle S, Rusjan P, Hassan S, Bloomfield PM, et al. Elevated brain monoamine oxidase A binding in the early postpartum period. Archives of general psychiatry. 2010;67(5):468-74.

35. Kranz GS, Wadsak W, Kaufmann U, Savli M, Baldinger P, Gryglewski G, et al. High-Dose Testosterone Treatment Increases Serotonin Transporter Binding in Transgender People. Biological psychiatry. 2015;78(8):525-33.

36. Wassink TH, Hazlett HC, Davis LK, Reiss AL, Piven J. Testing for association of the monoamine oxidase A promoter polymorphism with brain structure volumes in both autism and the fragile X syndrome. Journal of neurodevelopmental disorders. 2014;6(1):6.

37. Cerasa A, Cherubini A, Quattrone A, Gioia MC, Magariello A, Muglia M, et al. Morphological correlates of MAO A VNTR polymorphism: new evidence from cortical thickness measurement. Behav Brain Res. 2010;211(1):118-24.

38. Meyer-Lindenberg A, Buckholtz JW, Kolachana B, A RH, Pezawas L, Blasi G, et al. Neural mechanisms of genetic risk for impulsivity and violence in humans. Proceedings of the National Academy of Sciences of the United States of America. 2006;103(16):6269-74.

39. Naoi M, Maruyama W, Shamoto-Nagai M. Type A monoamine oxidase and serotonin are coordinately involved in depressive disorders: from neurotransmitter imbalance to impaired neurogenesis. Journal of neural transmission (Vienna, Austria : 1996). 2018;125(1):53-66.

40. Godar SC, Bortolato M, Richards SE, Li FG, Chen K, Wellman CL, et al. Monoamine oxidase A is required for rapid dendritic remodeling in response to stress. International Journal of Neuropsychopharmacology. 2015;18(9):pyv035.

41. Soliman A, Udemgba C, Fan I, Xu X, Miler L, Rusjan P, et al. Convergent effects of acute stress and glucocorticoid exposure upon MAO-A in humans. Journal of Neuroscience. 2012;32(48):17120-7.

42. Association AP, DSM-IV. APATFo. Diagnostic and Statistical Manual of Mental Disorders, Fourth Edition: DSM-IV-TR®: American Psychiatric Association; 2000.

43. Hembree WC, Cohen-Kettenis PT, Gooren L, Hannema SE, Meyer WJ, Murad MH, et al. Endocrine Treatment of Gender-Dysphoric/Gender-Incongruent Persons: An Endocrine Society* Clinical Practice Guideline. The Journal of Clinical Endocrinology & Metabolism. 2017;102(11):3869-903.

44. Kranz GS, Zhang BBB, Handschuh P, Ritter V, Lanzenberger R. Gender-affirming hormone treatment - A unique approach to study the effects of sex hormones on brain structure and function. Cortex; a journal devoted to the study of the nervous system and behavior. 2020;129:68-79.

45. Pol HEH, Cohen-Kettenis PT, Van Haren NE, Peper JS, Brans RG, Cahn W, et al. Changing your sex changes your brain: influences of testosterone and estrogen on adult human brain structure. European Journal of Endocrinology. 2006;155(suppl_1):S107-S14.

46. Kilpatrick LA, Holmberg M, Manzouri A, Savic I. Cross sex hormone treatment is linked with a reversal of cerebral patterns associated with gender dysphoria to the baseline of cisgender controls. European Journal of Neuroscience. 2019;50(8):3269-81.

47. Zubiaurre-Elorza L, Junque C, Gómez-Gil E, Guillamon A. Effects of Cross-Sex Hormone Treatment on Cortical Thickness in Transsexual Individuals. The Journal of Sexual Medicine. 2014;11(5):1248-61.

48. Kranz GS, Hahn A, Kaufmann U, Tik M, Ganger S, Seiger R, et al. Effects of testosterone treatment on hypothalamic neuroplasticity in female-to-male transgender individuals. Brain Structure and Function. 2018;223(1):321-8.

49. Burke SM, Manzouri AH, Dhejne C, Bergström K, Arver S, Feusner JD, et al. Testosterone Effects on the Brain in Transgender Men. Cerebral Cortex. 2017;28(5):1582-96.

50. Hahn A, Kranz GS, Sladky R, Kaufmann U, Ganger S, Hummer A, et al. Testosterone affects language areas of the adult human brain. Hum Brain Mapp. 2016;37(5):1738-48.

51. Philippe C, Zeilinger M, Mitterhauser M, Dumanic M, Lanzenberger R, Hacker M, et al. Parameter evaluation and fully-automated radiosynthesis of [11C]harmine for imaging of MAO-A for clinical trials. Applied Radiation and Isotopes. 2015;97:182-7.

52. Baldinger-Melich P, Gryglewski G, Philippe C, James GM, Vraka C, Silberbauer L, et al. The effect of electroconvulsive therapy on cerebral monoamine oxidase A expression in treatment-resistant depression investigated using positron emission tomography. Brain stimulation. 2019;12(3):714-23.

53. Spies M, James GM, Vraka C, Philippe C, Hienert M, Gryglewski G, et al. Brain monoamine oxidase A in seasonal affective disorder and treatment with bright light therapy. 2018;8(1):198.

54. James GM, Baldinger-Melich P, Philippe C, Kranz GS, Vanicek T, Hahn A, et al. Effects of Selective Serotonin Reuptake Inhibitors on Interregional Relation of Serotonin Transporter Availability in Major Depression. Front Hum Neurosci. 2017;11:48.

55. Ginovart N, Meyer JH, Boovariwala A, Hussey D, Rabiner EA, Houle S, et al. Positron emission tomography quantification of [11C]-harmine binding to monoamine oxidase-A in the human brain. Journal of cerebral blood flow and metabolism : official journal of the International Society of Cerebral Blood Flow and Metabolism. 2006;26(3):330-44.

56. Hilton J, Yokoi F, Dannals RF, Ravert HT, Szabo Z, Wong DF. Column-switching HPLC for the analysis of plasma in PET imaging studies. Nuclear medicine and biology. 2000;27(6):627-30.

57. Smith SM, Jenkinson M, Woolrich MW, Beckmann CF, Behrens TEJ, Johansen-Berg H, et al. Advances in functional and structural MR image analysis and implementation as FSL. NeuroImage. 2004;23:S208-S19.

58. Maximov II, Alnæs D, Westlye LT. Towards an optimised processing pipeline for diffusion magnetic resonance imaging data: Effects of artefact corrections on diffusion metrics and their age associations in UK Biobank. Human Brain Mapping. 2019;40(14):4146-62.

59. Chen G, Cox RW, Glen DR, Rajendra JK, Reynolds RC, Taylor PA. A tail of two sides: Artificially doubled false positive rates in neuroimaging due to the sidedness choice with t-tests. Human brain mapping. 2019;40(3):1037-43.

60. Mueller SC, Landré L, Wierckx K, T'Sjoen G. A Structural Magnetic Resonance Imaging Study in Transgender Persons on Cross-Sex Hormone Therapy. Neuroendocrinology. 2017;105(2):123-30.

61. Simon L, Kozák LR, Simon V, Czobor P, Unoka Z, Szabó Á, et al. Regional grey matter structure differences between transsexuals and healthy controls--a voxel based morphometry study. PloS one. 2013;8(12):e83947.

62. Hoekzema E, Schagen SE, Kreukels BP, Veltman DJ, Cohen-Kettenis PT, Delemarre-van de Waal H, et al. Regional volumes and spatial volumetric distribution of gray matter in the gender dysphoric brain. Psychoneuroendocrinology. 2015;55:59-71.

63. Luders E, Sánchez FJ, Gaser C, Toga AW, Narr KL, Hamilton LS, et al. Regional gray matter variation in male-to-female transsexualism. NeuroImage. 2009;46(4):904-7.

64. Zubiaurre-Elorza L, Junque C, Gómez-Gil E, Segovia S, Carrillo B, Rametti G, et al. Cortical thickness in untreated transsexuals. Cerebral cortex (New York, NY : 1991). 2013;23(12):2855-62.

65. Feusner JD, Lidström A, Moody TD, Dhejne C, Bookheimer SY, Savic I. Intrinsic network connectivity and own body perception in gender dysphoria. Brain imaging and behavior. 2017;11(4):964-76.

66. Guillamon A, Junque C, Gómez-Gil E. A Review of the Status of Brain Structure Research in Transsexualism. Archives of Sexual Behavior. 2016;45(7):1615-48.

67. Hammes SR, Levin ER. Impact of estrogens in males and androgens in females. The Journal of clinical investigation. 2019;129(5):1818-26.

68. Ikeda Y, Nagai A. Differential expression of the estrogen receptors alpha and beta during postnatal development of the rat cerebellum. Brain research. 2006;1083(1):39-49.

69. Hazell GG, Yao ST, Roper JA, Prossnitz ER, O'Carroll AM, Lolait SJ. Localisation of GPR30, a novel G protein-coupled oestrogen receptor, suggests multiple functions in rodent brain and peripheral tissues. The Journal of endocrinology. 2009;202(2):223-36.

70. Azcoitia I, Yague JG, Garcia-Segura LM. Estradiol synthesis within the human brain. Neuroscience. 2011;191:139-47.

71. Hedges VL, Ebner TJ, Meisel RL, Mermelstein PG. The cerebellum as a target for estrogen action. Frontiers in Neuroendocrinology. 2012;33(4):403-11.

72. Biegon A, Kim SW, Alexoff DL, Jayne M, Carter P, Hubbard B, et al. Unique distribution of aromatase in the human brain: in vivo studies with PET and [N-methyl-11C]vorozole. Synapse (New York, NY). 2010;64(11):801-7.

73. O'Connor DB, Archer J, Hair WM, Wu FC. Activational effects of testosterone on cognitive function in men. Neuropsychologia. 2001;39(13):1385-94.

74. Aleman A, Bronk E, Kessels RPC, Koppeschaar HPF, van Honk J. A single administration of testosterone improves visuospatial ability in young women. Psychoneuroendocrinology. 2004;29(5):612-7.

75. Peters SK, Dunlop K, Downar J. Cortico-Striatal-Thalamic Loop Circuits of the Salience Network: A Central Pathway in Psychiatric Disease and Treatment. Frontiers in Systems Neuroscience. 2016;10.

76. Harrington GS, Farias ST. Sex differences in language processing: functional MRI methodological considerations. Journal of magnetic resonance imaging : JMRI. 2008;27(6):1221-8.

77. Duerden EG, Arsalidou M, Lee M, Taylor MJ. Lateralization of affective processing in the insula. NeuroImage. 2013;78:159-75.

78. Klabunde M, Weems CF, Raman M, Carrion VG. The moderating effects of sex on insula subdivision structure in youth with posttraumatic stress symptoms. Depression and anxiety. 2017;34(1):51-8.

79. Eisenberger NI, Inagaki TK, Rameson LT, Mashal NM, Irwin MR. An fMRI study of cytokine-induced depressed mood and social pain: the role of sex differences. NeuroImage. 2009;47(3):881-90.

80. Spurny-Dworak B, Handschuh P, Spies M, Kaufmann U, Seiger R, Klöbl M, et al. Effects of sex hormones on brain GABA and glutamate levels in a cis- and transgender cohort. Psychoneuroendocrinology. 2022;138:105683.

81. Lin CS, Ku HL, Chao HT, Tu PC, Li CT, Cheng CM, et al. Neural network of body representation differs between transsexuals and cissexuals. PloS one. 2014;9(1):e85914.

82. Savli M, Bauer A, Mitterhauser M, Ding Y-S, Hahn A, Kroll T, et al. Normative database of the serotonergic system in healthy subjects using multi-tracer PET. NeuroImage. 2012;63(1):447-59.

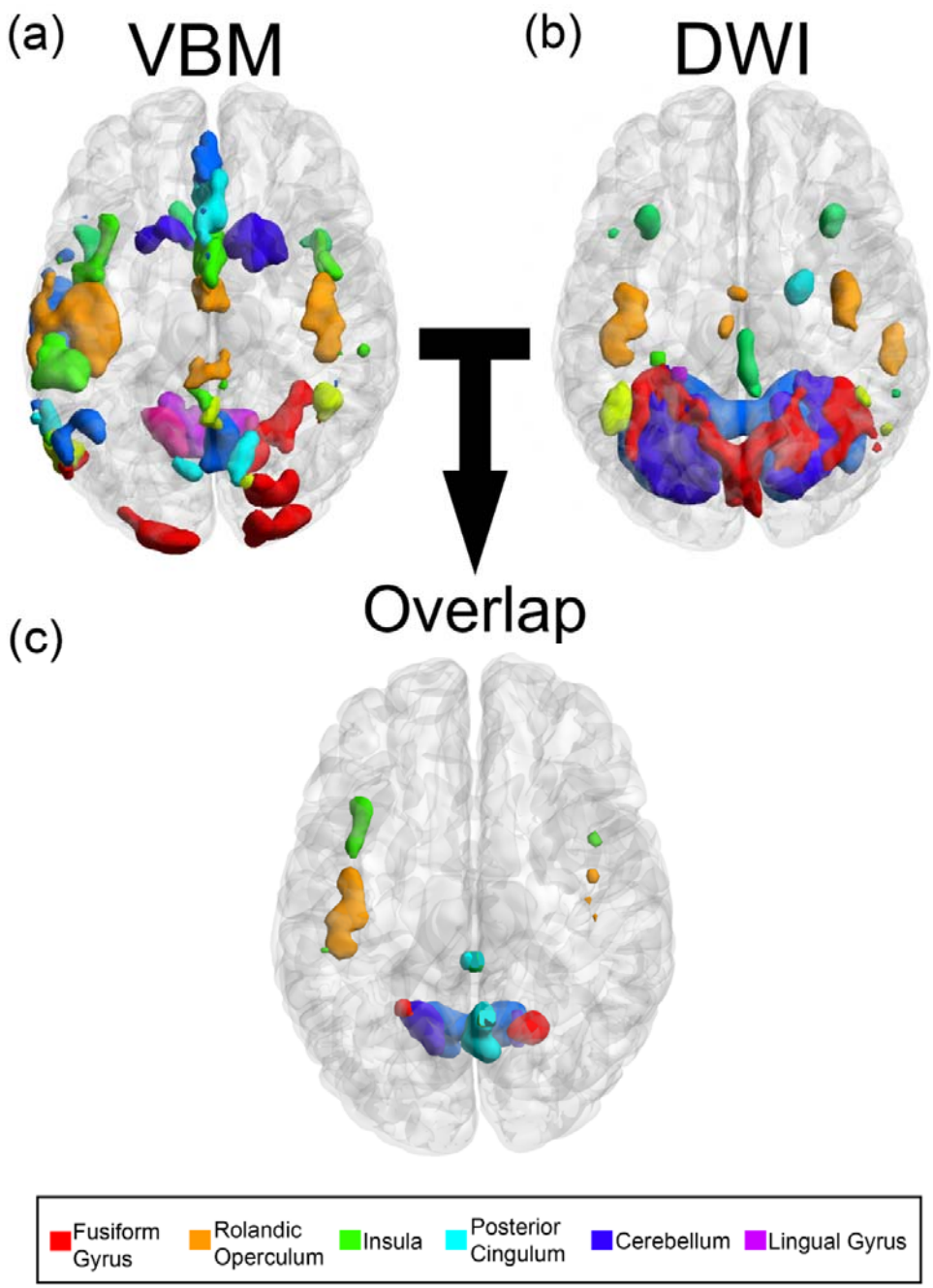

Figure 1: Structural changes after gender-affirming hormone therapy. *(a) Shows the significant changes derived from the voxel based morphometry (VBM) analysis, whereas (b) shows the mean diffusivity changes in gray matter for all transgender and cisgender groups after a median of 4.5 months of gender-affirming hormone therapy. (c) Indicates the overlapping regions between the VBM and DWI analyses.*

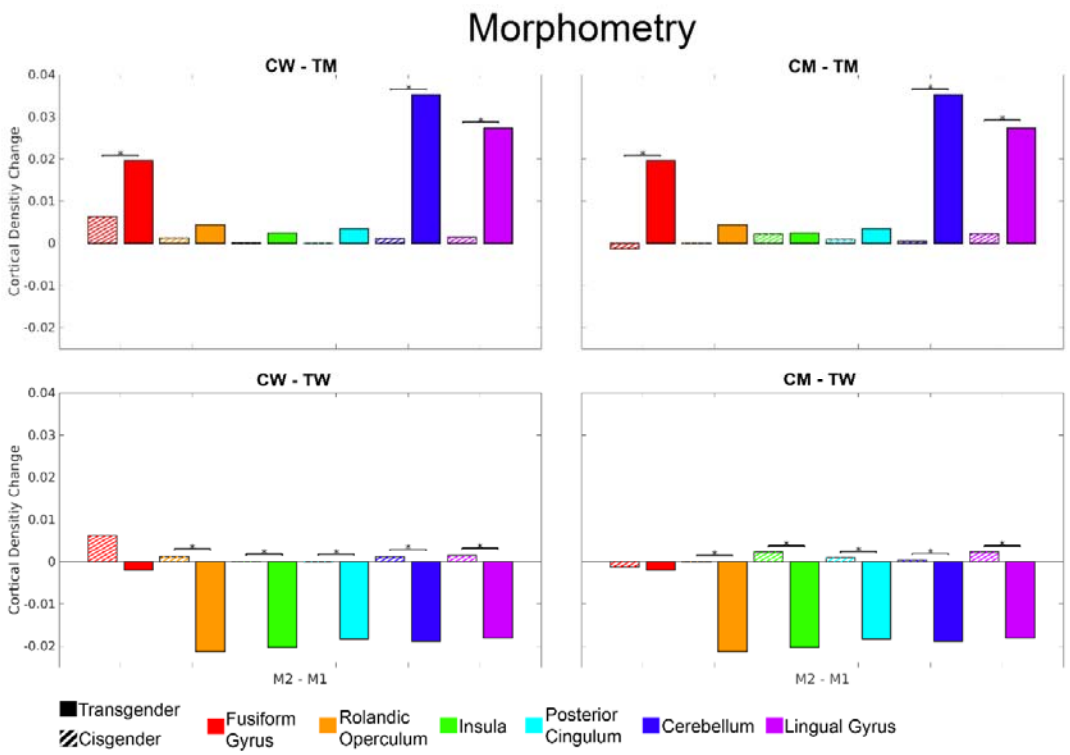

Figure 2: Voxel based morphometry regional changes. *Each bar represents the change in gray matter density (GMD) after 4 months of gender-affirming hormone therapy (GHT), where the hatched bars represent the cisgender groups of male (MC) and female controls (FC) and the solid bars the transgender groups, transmale (TM) and transfemale (TW). Here widespread regional interactions can be found in the TW group when compared to both CM and CW, whereas TM showed less regional interactions, however the significant interactions showed a greater magnitude of change. An increase in GMD was found for both TM and TW after a median of 4.5 months of GHT. Significant group-by-time interactions are denoted with a *.*

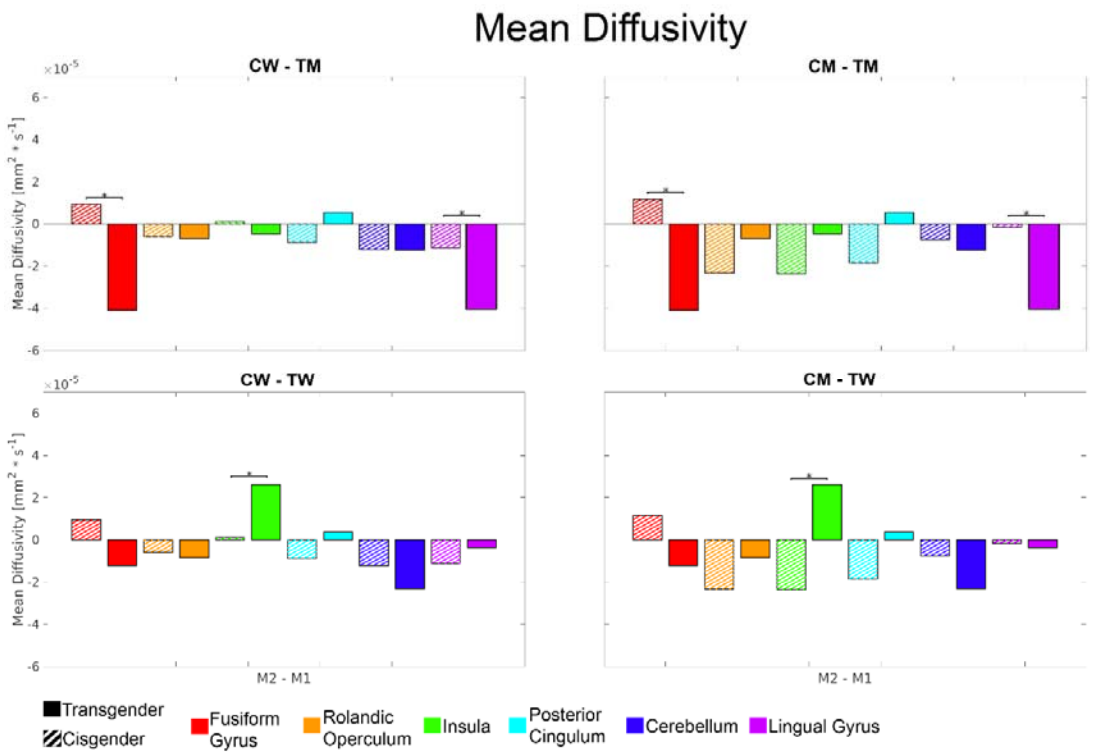

Figure 3: Mean diffusivity regional changes. *Each bar represents the average diffusivity change reflective of microstructural alterations after 4 months of gender-affirming hormone therapy, where the hatched bars represent the cisgender groups of male (MC) and female controls (FC) and the solid bars the transgender groups, transmale (TM) and transfemale (TW). Here, changes a decrease in both TM vs CW or CM and also TW vs CM were found. Significant group-by-time interactions are denoted with a *.*

	cisgender women		cisgender men		transgender women		transgender men	
N(VBM + DWI)	20		11		20		10	
Age [years]	25.3 ± 6.7		26.5 ± 8.0		28.6 ± 9.3		24.75 ± 7.3	
Completed	M1	M2	M1	M2	M1	M2	M1	M2
N(PET)	9	3	8	3	7	5	11	6
	Pre	Post	Pre	Post	Pre	Post	Pre	Post
DHEAS (µg/ml)	3.2 ± 0.9	3.2 ± 1.0	3.8 ± 1.9	2.6 ± 1.3	3.9 ± 1.1	3.8 ± 1.3	3.2 ± 1.9	3.3 ± 1.9
Estradiol (pg/ml)	81.2 ± 56.7	112.1 ± 79.5	22.7 ± 10.3	22.9 ± 9.0	35.7 ± 16.6	290.0 ± 299.1	111.2 ± 74.9	59.3 ± 50.3
FSH (µU/ml)	4.9 ± 1.4	4.9 ± 2.8	3.8 ± 1.6	3.8 ± 1.5	3.3 ± 1.7	0.2 ± 0.1	4.5 ± 2.5	5.6 ± 3.6
LH (µU/ml)	9.8 ± 6.4	9.5 ± 6.9	5.8 ± 1.9	6.5 ± 2.3	6.5 ± 2.9	0.1 ± 0.1	9.6 ± 5.9	8.6 ± 8.8
Progesterone (ng/ml)	1.3 ± 1.3	4.9 ± 5.6	0.4 ± 0.3	0.3 ± 0.2	0.3 ± 0.2	0.8 ± 0.9	4.9 ± 6.4	0.3 ± 0.2
SHBG (nmol/L)	67.4 ± 28.5	69.6 ± 27.6	45.3 ± 25.0	43.2 ± 19.3	45.7 ± 21.5	70.2 ± 39.4	65.3 ± 36.3	36.3 ± 15.1
Testosterone (ng/ml)	0.4 ± 0.2	0.3 ± 0.1	5.6 ± 2.1	5.0 ± 1.2	5.7 ± 1.7	0.3 ± 0.2	0.4 ± 0.2	4.3 ± 2.1

Table 1: Demographics of all participants for both DWI + VBM and PET analyses*, each divided into their respective subgroups. Age is given from the inclusion date. Hormone levels for the pre-treatment assessment and cisgender participants are provided for comparison only and were not used as covariates in the statistical analyses.*