

## **Global reports of takotsubo (stress) cardiomyopathy following COVID-19 vaccination: a systematic review and meta-analysis**

Sirwan Khalid Ahmed<sup>1</sup>, Mona Gamal Mohamed<sup>2</sup>, Rawand Abdulrahman Essa<sup>1</sup>, Eman Abdelaziz Ahmed Rashad Dabou<sup>2</sup>, Salar Omar Abdulqadir<sup>3</sup>, Rukhsar Muhammad Omar<sup>3</sup>

<sup>1</sup>Department of Emergency, Ranya Teaching Hospital, Ranya, Sulaimani, Kurdistan-region, Iraq

<sup>2</sup>Department of Adult Nursing, RAK Medical and Health Sciences University, Ras Al Khaimah, UAE.

<sup>3</sup>Department of Nursing, University of Raparin, Ranya, Sulaimani, Kurdistan-region, Iraq

### **Corresponding Author:**

Sirwan Khalid Ahmed

Department of Emergency, Ranya Teaching Hospital, Ranya, Sulaimani, Kurdistan-region, Iraq

TEL: +9647501553224

Email: [sirwan.ahmed1989@gmail.com](mailto:sirwan.ahmed1989@gmail.com)

## **Abstract**

Concerns have been raised recently about takotsubo cardiomyopathy (TCM) after receiving COVID-19 vaccines, particularly the messenger RNA (mRNA) vaccines. The goal of this study was to compile case reports to provide a comprehensive overview of takotsubo cardiomyopathy (TCM) associated with COVID-19 vaccines. A systematic literature search was conducted in PubMed, Scopus, Embase, Web of Science, and Google Scholar between 2020 and June 1, 2022. The study included individuals who developed cardiac takotsubo cardiomyopathy from receiving COVID-19 vaccinations. Ten studies, including 10 cases, participated in the current systematic review. The mean age was 61.8 years; 90% were female, while 10% were male. 80% of the patients received the mRNA COVID-19 vaccine, while 20% received other types. In addition, takotsubo cardiomyopathy (TCM) occurred in 50% of patients receiving the first dose and another 40% after the second dose of COVID-19 vaccines. Moreover, the mean number of days to the onset of symptoms was 2.62 days. All cases had an elevated troponin test and abnormal ECG findings. The left ventricular ejection fraction (LVEF) was lower than 50% in 90% of patients. In terms of the average length of hospital stay, 50% stayed for 10.2 days, and all cases recovered from their symptoms. In conclusion, takotsubo (stress) cardiomyopathy (TCM) complications associated with COVID-19 vaccination are rare but can be life-threatening. Chest pain should be considered an alarming symptom, especially in those who have received the first and second doses of the COVID-19 vaccine.

## **Keywords**

Takotsubo cardiomyopathy, stress cardiomyopathy, COVID-19 Vaccine, broken heart syndrome, mRNA vaccine, BNT162b2, mRNA-1273, ChadOX1 nCOV-19

## **Introduction**

The coronavirus (COVID-19) pandemic, caused by the severe acute respiratory syndrome coronavirus-2 (SARS-CoV-2), has hurt millions of people worldwide. The FDA granted emergency approval to Pfizer-

BioNTech (BNT162b2) and Moderna (mRNA-1273) COVID-19 vaccines in December 2020. SARS-CoV-2 vaccines are still the best hope for combating the global pandemic.

Takotsubo cardiomyopathy (TCM) is a type of heart disease frequently triggered by excessive physical and emotional stress. Although the pathophysiology of this condition is not fully understood, studies have suggested that it may be caused by the activation of central autonomic neurons expressing estrogen receptors. In addition, coronary vasospasm increases sensitivity to a surge in circulating catecholamines and metabolic dysfunction [1]. Catecholamine levels are higher in TCM than in STEMI [2,3]. As a result of the COVID-19 pandemic, TCM cases have risen from 1.5% to 7.8% [4]. TCM has already been linked to a 'cytokine storm' of interleukin 6 (IL-6) and tumor necrosis factor-alpha (TNF $\alpha$ ), which causes hyperinflammation in COVID-19 patients [5,6]. Individuals who presented without COVID-19 infection or other notable risk factors may have been infected with TCM due to the psychological stress of living in a pandemic [1]. TCM is more likely to occur in people with a history of mental illness before the pandemic outbreak [5,7–9]. The mRNA1273 and BNT1626b2 (COVID-19 mRNA vaccines) induce innate immunity, cytotoxic and helper T cell responses, and, in particular, B cell responses [10]. Pain, erythema, swelling, fever, headache, and myalgia were reported as the most common systemic or local reactions [11]. However, acute myocardial infarction, pulmonary embolism, stroke, and venous thromboembolism are all possible complications of mRNA-based COVID-19 vaccines [12–14]. There have been reports of takotsubo cardiomyopathy following the COVID-19 vaccination, particularly following the messenger RNA (mRNA) vaccines [1,15–23].

We are aware of no systematic review that has been conducted specifically for COVID-19 vaccine induced TCM. Given the rarity of adverse takotsubo syndrome associated with COVID19 vaccination, most of the peer-reviewed papers are case reports. The goal of this study was to compile case reports to provide a comprehensive overview of takotsubo cardiomyopathy (TCM) associated with COVID-19 vaccines.

## **Methods**

## **Review objectives**

This study's primary goal is to clarify the possibility of takotsubo cardiomyopathy (TCM) associated with COVID-19 vaccination. And to elaborate on the demographic and clinical characteristics of COVID-19 vaccinated individuals who develop takotsubo cardiomyopathy (TCM).

## **Protocol and Registration**

The review follows the PRISMA 2020 guidelines for reporting systematic reviews and meta-analyses [24]. The review protocol was recorded in the International Prospective Register of Systematic Reviews (PROSPERO) under the registration number CRD42022316515. Additionally, the AMSTAR-2 checklist was used to assess the quality of this review, which was found to be of high quality [25]. Ethical approval was not required for this review article.

## **Search strategy**

A comprehensive search of major online databases (PubMed, Scopus, Embase, Web of Science, and Google Scholar) was performed from 2020 until June 1, 2022, to discover all articles that had been published. The search strategy consisted of a combination of the following keywords: "COVID-19 vaccine" AND "takotsubo cardiomyopathy" OR "stress cardiomyopathy." OR "takotsubo syndrome". In addition, we checked the references of all relevant papers to ensure the search was complete.

## **Eligibility criteria**

1. All case series and case reports after the COVID-19 vaccine developed takotsubo cardiomyopathy (TCM) in humans, regardless of the type of Vaccine and dose, were included.
2. In this review, narrative and systematic reviews, as well as papers with insufficient data, were excluded. Furthermore, articles written in languages other than English were excluded.

## **Data extraction and selection process**

Every step of the data extraction process from the source was guided by PRISMA 2020. It was used to guide the process. Three independent authors (S.K.A., R.A.E., and M.G.M.) used the Rayyan website to screen abstracts and full-text articles based on inclusion and exclusion criteria [26]. Disagreements between the three independent authors were resolved by discussion. The data extraction process was carried out using predefined forms in Microsoft Office Excel. A total of the following information was extracted from each research study: author names, year of publication, age, gender, type of COVID-19 Vaccine, dose, troponin levels, days to symptom onset, symptoms, length of hospital stay/days, ECG, LVEF < 50% or LVEF > 50%, treatment, and their outcomes.

## **Critical appraisal**

We used the Joanna Briggs Institute's critical appraisal tool for case reports to evaluate all included studies [27]. Three authors evaluated each article independently (S.K.A, M.G.M, and R.A.E). The paper evaluation disagreements were resolved through discussion or by the first author (S.K.A.). The results of our systematic review were evaluated using the AMSTAR 2 criteria [25]. The overall quality of our systematic review was rated "moderate" by the AMSTAR 2 tool.

## **Data synthesis and analysis**

The data from the articles included in this systematic review were extracted and pooled. This data included (author names, year of publication, age, gender, type of COVID-19 vaccine, dose, troponin levels, days to symptoms onset, symptoms, length of hospital stay/days, ECG, LVEF <50% or LVEF >50%, treatment, and their outcomes). We collected this information from the findings of eligible studies. Categorical data were expressed as proportions (%), and numerical data were expressed as mean  $\pm$  standard deviation (SD). Statistical analysis will be performed using the Statistical Package for the Social

Sciences (SPSS) 25.0 software program (SPSS Inc., Chicago, IL, USA). We pooled the results of the studies into one table.

## **Results**

### **Selection of studies**

The search was performed on significant databases (PubMed, Scopus, Embase, Web of Science, and Google Scholar) between 2020 and June 1, 2022, and yielded 2371 articles relevant to our search criteria. The references were then organized using a citation manager tool (Mendeley), and 459 articles were automatically eliminated because they were duplicates. Then, a final check was performed on 1912 articles to ensure that their titles, abstracts, and full texts were accurate. One thousand eight hundred ninety-seven articles were rejected because they did not meet the requirements to be included. Aside from that, 15 articles were submitted for retrieval, with five being dismissed because they did not meet our inclusion criteria. Finally, our systematic review included only ten articles (**Fig 1**). Case report details are shown in (**Table 1**).

### **Characteristics of the included studies**

Table 2 shows an overview of the ten cases. The mean age and SD were  $61.8 \pm 13.68$  years; 90% were female, while 10% were male. 80% of the patients received the mRNA COVID-19 vaccine, either from Pfizer-BioNTech (BNT162b2) or Moderna COVID-19 Vaccine (mRNA-1273), while 20% of patients received other types, including AstraZeneca COVID-19 vaccine (ChAdOx1 nCoV-19). In addition, takotsubo cardiomyopathy occurred in 50% of patients receiving the first dose and another 40% after the second dose of COVID-19 vaccines. Moreover, the mean number of days to onset symptoms was  $2.62 \pm 2.19$  days. All cases had an elevated troponin test and abnormal ECG findings. The left ventricular ejection fraction (LVEF) was lower than 50% in 90% of patients. Regarding the average length of hospital stay, 50% stayed for  $10.20 \pm 3.96$  days, and all cases recovered from their symptoms.

## Discussion

COVID-19 vaccines protect the general public health and restrict viral propagation. Inactivated viral, DNA, mRNA, and protein-based vaccines are the four primary mechanisms that have been examined in this research for COVID-19 vaccines. DNA-based vaccinations use viral vectors to deliver the DNA coding for the SARS-CoV-2 spike protein into cells; mRNA vaccines typically deliver mRNA into cells via a lipid nanoparticle; protein vaccines use the spike proteins or their particles, and certain other vaccinations use inactivated viruses [44].

The COVID-19 pandemic has recorded the most extensive global vaccination program in history, with over 11.3 billion vaccination doses administered from December 2020 to December 2021. With increasing populations being vaccinated daily, we are seeing increased reports of associated side effects. The most common side effects are pain, swelling, and redness around the injection site. Systemic side effects like fever, tiredness, muscle pain, and headache can also happen to about one in four people. The females have noted a higher prevalence of these systematic effects [45]. Moreover, severe side effects have been reported and are under current monitoring: thrombocytopenic thrombosis, anaphylaxis, Bell's palsy, myocarditis, and capillary leak syndrome [46,58,68].

In this systematic review, half of the cases were from the United States, most of the participants were female, and their mean age was 61.6. It was found that the participants received different types of COVID-19 vaccinations, including Pfizer-BioNTech (40 %), Moderna (mRNA-1273) (40%), and Oxford AstraZeneca ChAdOx1 nCoV-19 (20 %). More than half of the symptoms triggered by the first dose of the COVID-19 vaccine. Another important finding is that the symptoms started to happen after the vaccine dose, with a mean of 2.62 days. In line with the current results, Jani et al. (2021) mentioned that up to now, few cases of TCM have been reported after first or second dose administration of SARS-CoV-2 vaccines, even including different types of vaccines like mRNA-1273, BNT162b2, and ChAdOx1 nCoV-19 [47]. Another case report supported that a case of TCM after administration of the second dose

of the DNA ChadOX1 nCOV-19 (AZD122) vaccination was reported, and this condition predominantly affects women (90%) at age 50 and above [48]. Also, Berto et al. (2021) wrote that a healthy 30-year-old Asian woman was brought to the emergency room with sudden chest pain and a cold sweat after receiving the second mRNA COVID-19 vaccine shot (Pfizer, New York City) 2 days prior [49].

Although the pathophysiology of TCM after COVID-19 vaccination is not well established, the proposed hypotheses are stunning changes in ischemia-induced myocardium. It could be secondary to microvessel or multi-vessel vasospasm and direct myocardial injury due to surge currents. Stress causes more release of catecholamine via excessive activation of sympathetic nervous system through the hypothalamic–pituitary-adrenal axis [50]. The limbic brain regions such as the amygdala, insula, anterior cingulate cortex, prefrontal cortex, and hippocampus have impaired neural networks during stress in TTS patients [51-54]. In a takotsubo rat model; epinephrin affinity switching from beta2-adrenoreceptors-Gs during low epinephrine amount to Gi when the amount of epinephrin is high causes acute apical cardiac depression, this process is protecting myocardium from toxicity during stress [55]. Scally et al., (2019) [6] has reported elevation of cytokines (serum interleukin-6, chemokine ligand 1, and classic CD14++CD16-) and infiltration of inflammatory myocardial macrophage in TTS patients. Naegele et al., (2016) [56] in his study found serious endothelial dysfunction in TTS patients. Another possible explanation is that the free-floating spike proteins may interact with angiotensin-converting enzyme 2. The imbalance between angiotensin II (overactivity) and angiotensin (deficiency) might play a role in the genesis of acute elevation in blood pressure, and this could be applied as a result of vaccination [62].

The diagnosis of takotsubo cardiomyopathy (TCM) was based on seven criteria put forward by the European Society of Cardiology [57]. The cardiac signs and symptoms, as well as electrocardiographic and laboratory findings, may be similar in patients who have TCM or myocarditis, which can make it very difficult to differentiate between the two conditions. Despite these difficulties, myocarditis is typically diagnosed with endomyocardial biopsy and cardiac magnetic resonance (CMR) [59]. Additionally, acute emotional or physical stressors induce increased levels of catecholamines and cortisol



in the blood. These elevations mediate multiple pathways, including pericardial coronary artery spasms, microvascular dysfunction, and direct muscle cell injury, are all critical findings of transthoracic echocardiography [60,61].

In this systematic review, all cases had elevated troponin levels, the ejection fraction was above 50 %, and the electrocardiogram showed abnormal findings. According to the Mayo Clinic criteria, TCM has left ventricular hypokinesia, akinesia, or dyskinesia. These local wall dyskinesia are specific epicardial vasculature boundaries, with or without apex involvement. It is diagnosed when it expands beyond that. No evidence by angiography of obstructive coronary artery disease or acute plaque rupture, new ST elevation or T wave inversion, or mild cardiac troponin elevation. TCM is triggered by emotional, physical, or unknown causes [63,64].

These findings matched Toida et al. (2021), who reported that patients received the first dose of the Pfizer-BioNTech COVID-19 vaccine. The day after the vaccination, she developed general fatigue and a loss of appetite. A physical examination revealed a systolic murmur of Levine 2/6 at the second left sternal border, clear lung sounds, and no leg edema. On admission, electrocardiography (ECG) revealed atrial fibrillation with a normal axis, negative T-waves in I, aVL, V3-6 leads, and a prolonged QTc interval of 495 ms [65].

In our review, more than half of the patients stayed in the hospital with a mean  $\pm$  SD of  $10.20 \pm 3.96$  days, and all recovered without complications. An outcomes study assessing the trends of hospitalized patients with takotsubo cardiomyopathy demonstrated an in-hospital mortality rate of 1.3%, a hospital discharge rate to the home of 73.6%, and 1-year mortality of 6.9% [66]. In addition, Đenić et al. (2022) reported that the patient was clinically improved and had no evidence of high-risk features on ECG or TTE [67]. However, these findings do not support the previous study by Toida et al. (2021), who showed the case report regarding takotsubo cardiomyopathy after the COVID-19 vaccine and found the patient's length of hospital stay was about five days [65].

## **Limitation**

We recognize that our systematic review has some limitations, which include only involving case reports and case series due to the limited numbers of original studies published on the takotsubo cardiomyopathy after taking COVID-19 vaccines, so the results should be interpreted with some caution. Moreover, we do not have any data about the previous history of COVID-19, which may affect the results since COVID-19 can also cause cardiac complications.

## **Conclusion**

Takotsubo cardiomyopathy (TCM) complications associated with COVID-19 vaccination are rare but can be life-threatening. Chest pain should be considered an alarming symptom, especially in those who have received a second dose of the vaccine in the last three days. For diagnosis, CK-MB and troponin are better biomarkers to confirm myocarditis than CRP, ESR, and NT-proBNP. All of the cases had wholly recovered without any irreversible cardiomyopathy changes.

## **Conflicts of interest**

There is no conflict to be declared.

## **Funding**

This research did not receive any specific grant from the public, commercial, or not-for-profit funding agencies.

## **Author Agreement Statement**

We declare that this manuscript is original, has not been published before, and is not currently being considered for publication elsewhere. We confirm that the manuscript has been read and approved by all named authors and that there are no other persons who satisfied the criteria for authorship but are not listed. We confirm that all have agreed with the order of authors listed in our manuscript. We understand

that the Corresponding Author is the sole contact for the Editorial process. He is responsible for communicating with the other authors about progress, submissions of revisions, and final approval of proofs.

### **Data availability Statement**

All relevant data are within the manuscript and its supporting information files.

**Authors' contributions:** Conception and design SKA acquisition of data SKA, RAE analysis and interpretation of data SKA, RAE, MGM, EEA, drafting of the manuscript SKA, RAE, MGM, EAA critical revision of the manuscript for effective intellectual content statistical analysis SKA, SAO and RMO, administrative SKA, RAE, MGM, EAA technical SKA, supervision SKA and all authors approving the final draft.

### **Provenance and peer review**

Not commissioned, externally peer-reviewed

### **Acknowledgments**

Not applicable

### **References**

- [1] C. Stewart, D.T. Gamble, D. Dawson, Novel case of takotsubo cardiomyopathy following COVID-19 vaccination, *BMJ Case Reports CP*. 15 (2022) e247291.
- [2] C. Templin, J.R. Ghadri, J. Diekmann, L.C. Napp, D.R. Bataiosu, M. Jaguszewski, V.L. Cammann, A. Sarcon, V. Geyer, C.A. Neumann, Clinical features and outcomes of takotsubo (stress) cardiomyopathy, *N Engl J Med*. 373 (2015) 929–938.
- [3] R. Ono, L.M. Falcão, Takotsubo cardiomyopathy systematic review: pathophysiologic process, clinical presentation and diagnostic approach to Takotsubo cardiomyopathy, *Int J Cardiol*. 209 (2016) 196–205.

- [4] R.M. Shah, M. Shah, S. Shah, A. Li, S. Jauhar, Takotsubo syndrome and COVID-19: associations and implications, *Curr Probl Cardiol.* 46 (2021) 100763.
- [5] S. Singh, R. Desai, Z. Gandhi, H.K. Fong, S. Doreswamy, V. Desai, A. Chockalingam, P.K. Mehta, R. Sachdeva, G. Kumar, Takotsubo syndrome in patients with COVID-19: a systematic review of published cases, *SN Compr Clin Med.* 2 (2020) 2102–2108.
- [6] C. Scally, H. Abbas, T. Ahearn, J. Srinivasan, A. Mezincescu, A. Rudd, N. Spath, A. Yucel-Finn, R. Yucel, K. Oldroyd, Myocardial and systemic inflammation in acute stress-induced (Takotsubo) cardiomyopathy, *Circulation.* 139 (2019) 1581–1592.
- [7] A. Jabri, A. Kalra, A. Kumar, A. Alameh, S. Adroja, H. Bashir, A.S. Nowacki, R. Shah, S. Khubber, K. Anmar, Incidence of stress cardiomyopathy during the coronavirus disease 2019 pandemic, *JAMA Netw Open.* 3 (2020) e2014780–e2014780.
- [8] L. Barbieri, F. Galli, B. Conconi, T. Gregorini, S. Lucreziotti, A. Mafri, G. Pravettoni, M. Sommaruga, S. Carugo, Takotsubo syndrome in COVID-19 era: Is psychological distress the key?, *J Psychosom Res.* 140 (2021) 110297.
- [9] J. Rivers, J.F. Ihle, COVID-19 social isolation-induced takotsubo cardiomyopathy, *Med J Aust.* 213 (2020) 336.
- [10] R. Verbeke, I. Lentacker, S.C. De Smedt, H. Dewitte, The dawn of mRNA vaccines: The COVID-19 case, *J Control Release.* 333 (2021) 511–520.
- [11] F.P. Polack, S.J. Thomas, N. Kitchin, J. Absalon, A. Gurtman, S. Lockhart, J.L. Perez, G.P. Marc, E.D. Moreira, C. Zerbini, Safety and Efficacy of the BNT162b2 mRNA Covid-19 Vaccine, *N Engl J Med.* 383 (2020) 2603–2615.
- [12] M. García-Grimshaw, L.E. Hernández-Vanegas, I. Núñez, N. Hernández-Valdivia, D.A. Carrillo-García, A. Michel-Chávez, J.A. Galnares-Olalde, G. Carbajal-Sandoval, M. del Mar

- Saniger-Alba, R.A. Carrillo-Mezo, Neurologic adverse events among 704,003 first-dose recipients of the BNT162b2 mRNA COVID-19 vaccine in Mexico: a nationwide descriptive study, *Clin Immunol.* 229 (2021) 108786.
- [13] B. Bozkurt, I. Kamat, P.J. Hotez, Myocarditis with COVID-19 mRNA vaccines, *Circulation.* 144 (2021) 471–484.
- [14] NP. Klein, N. Lewis, K. Goddard, B. Fireman, O. Zerbo, K.E. Hanson, J.G. Donahue, E.O. Kharbanda, A. Naleway, J.C. Nelson, Surveillance for adverse events after COVID-19 mRNA vaccination, *JAMA.* 326 (2021) 1390–1399.
- [15] M.B. Berto, G. Spano, B. Wagner, B. Bernhard, J. Häner, A.T. Huber, C. Gräni, Takotsubo cardiomyopathy after mRNA COVID-19 vaccination, *Hear Lung Circ.* 30 (2021) e119–e120.
- [16] C. Jani, J. Leavitt, O. Al Omari, A. Dimaso, K. Pond, S. Gannon, A.K. Chandran, C. Dennis, R. Colgrove, COVID-19 Vaccine–Associated Takotsubo Cardiomyopathy, *Am J Ther.* 28 (2021) 361–364.
- [17] R. Toida, S. Uezono, H. Komatsu, T. Toida, A. Imamura, S. Fujimoto, K. Kaikita, Takotsubo cardiomyopathy after vaccination for coronavirus disease 2019 in a patient on maintenance hemodialysis, *CEN Case Reports.* (2021) 1–5.
- [18] C. Fearon, P. Parwani, B. Gow-Lee, D. Abramov, Takotsubo syndrome after receiving the COVID-19 Vaccine, *J Cardiol Cases.* 24 (2021) 223–226.
- [19] H. Yamaura, H. Ishikawa, K. Otsuka, N. Kasayuki, Reverse Takotsubo Cardiomyopathy as a Cause of Acute Chest Pain in a Young Woman Following COVID-19 Vaccination, *Circ Cardiovasc Imaging.* 15 (2022) e013661.
- [20] P. Crane, C. Wong, N. Mehta, P. Barlis, Takotsubo (stress) cardiomyopathy after ChAdOx1 nCoV-19 vaccination, *BMJ Case Reports CP.* 14 (2021) e246580.

- [21] M.K. Vidula, M. Ambrose, H. Glassberg, N. Chokshi, T. Chen, V.A. Ferrari, Y. Han, Myocarditis and other cardiovascular complications of the mRNA-based COVID-19 vaccines, *Cureus*. 13 (2021).
- [22] A. Tedeschi, M. Camilli, U. Ianni, G. Tavecchia, M. Palazzini, I. Cartella, P. Gentile, G. Quattrocchi, F.M. Spanò, M. Cipriani, Takotsubo Syndrome after BNT162b2 mRNA Covid-19 vaccine: emotional or causative relationship with vaccination?, *Int J Cardiol Hear Vasc*. 40 (2022).
- [23] G. Ricci, G. Citarelli, D. De Laura, L. Degennaro, L. Ligurgo, M. Sassara, F. Corriero, S. Musci, P. Desario, D. Rutigliano, P311 TAKOTSUBO CARDIOMYOPATHY RELATED TO MRNA SARS–COV2 VACCINE, *Eur Hear J Suppl*. 24 (2022) suac012-298.
- [24] M.J. Page, J.E. McKenzie, P.M. Bossuyt, I. Boutron, T.C. Hoffmann, C.D. Mulrow, L. Shamseer, J.M. Tetzlaff, E.A. Akl, S.E. Brennan, The PRISMA 2020 statement: an updated guideline for reporting systematic reviews, *Int J Surg*. 88 (2021) 105906. <https://doi.org/https://doi.org/10.1016/j.ijisu.2021.105906>.
- [25] B.J. Shea, B.C. Reeves, G. Wells, M. Thuku, C. Hamel, J. Moran, D. Moher, P. Tugwell, V. Welch, E. Kristjansson, AMSTAR 2: a critical appraisal tool for systematic reviews that include randomised or non-randomised studies of healthcare interventions, or both, *Bmj*. 358 (2017).
- [26] M. Ouzzani, H. Hammady, Z. Fedorowicz, A. Elmagarmid, Rayyan—a web and mobile app for systematic reviews, *Syst Rev*. 5 (2016) 1–10.
- [27] S. Moola, Z. Munn, C. Tufanaru, E. Aromataris, K. Sears, R. Sfetcu, M. Currie, R. Qureshi, P. Mattis, K. Lisy, Chapter 7: Systematic reviews of etiology and risk, *Joanna Briggs Inst Rev Manual Joanna Briggs Inst*. 5 (2017). <https://synthesismanual.jbi.global/>.
- [28] A.L. Goss, R.D. Samudralwar, R.R. Das, A. Nath, ANA investigates: neurological

complications of COVID-19 vaccines, *Ann Neurol.* 89 (2021) 856.

- [29] K.J. Sonigra, K. Sarna, V.P. Vaghela, S. Guthua, An Interesting Case of Fatal Myasthenic Crisis Probably Induced by the COVID-19 Vaccine, *Cureus.* 14 (2022).
- [30] I.S. Wittstein, The sympathetic nervous system in the pathogenesis of Takotsubo syndrome, *Heart Fail Clin.* 12 (2016) 485–498.
- [31] I.S. Wittstein, D.R. Thiemann, J.A.C. Lima, K.L. Baughman, S.P. Schulman, G. Gerstenblith, K.C. Wu, J.J. Rade, T.J. Bivalacqua, H.C. Champion, Neurohumoral features of myocardial stunning due to sudden emotional stress, *N Engl J Med.* 352 (2005) 539–548.
- [32] A. Fazlollahi, M. Zahmatyar, M. Noori, S.A. Nejadghaderi, M.J.M. Sullman, R. Shekarritz-Foumani, A. Kolahi, K. Singh, S. Safiri, Cardiac complications following mRNA COVID-19 vaccines: A systematic review of case reports and case series, *Rev Med Virol.* (2021) e2318.
- [33] W. Elikowski, M. Małek-Elikowska, M. Lisiecka, Z. Trypuć, I. Mozer-Lisewska, Takotsubo cardiomyopathy triggered by influenza B, *Pol Merkur Lek.* 45 (2018) 67–70.
- [34] E. Nyman, E. Mattsson, P. Tornvall, Trigger factors in takotsubo syndrome—a systematic review of case reports, *Eur J Intern Med.* 63 (2019) 62–68.
- [35] J.-R. Ghadri, I.S. Wittstein, A. Prasad, S. Sharkey, K. Dote, YJ Akashi, V.L. Cammann, F. Crea, L. Galiuto, W. Desmet, International expert consensus document on Takotsubo syndrome (part I): clinical characteristics, diagnostic criteria, and pathophysiology, *Eur Heart J.* 39 (2018) 2032–2046.
- [36] J.-R. Ghadri, I.S. Wittstein, A. Prasad, S. Sharkey, K. Dote, YJ Akashi, V.L. Cammann, F. Crea, L. Galiuto, W. Desmet, International expert consensus document on Takotsubo syndrome (part II): diagnostic workup, outcome, and management, *Eur Heart J.* 39 (2018) 2047–2062.
- [37] A. Riad, A. Pokorná, M. Mekhemar, J. Conrad, J. Klugarová, M. Koščík, M. Klugar, S. Attia,

- Safety of ChAdOx1 nCoV-19 vaccine: independent evidence from two EU states, *Vaccines*. 9 (2021) 673.
- [38] MA Shabbir, F. Mehak, Z.M. Khan, W. Ahmed, S.M. Abrar-ul-Haq, M.R. Khan, Z.F. Bhat, R.M. Aadil, Delving the role of nutritional psychiatry to mitigate the COVID-19 pandemic induced stress, anxiety and depression, *Trends Food Sci Technol*. (2022).
- [39] R.M. Kaplan, A. Milstein, Influence of a COVID-19 vaccine's effectiveness and safety profile on vaccination acceptance, *Proc Natl Acad Sci*. 118 (2021).
- [40] G. Bogdanov, I. Bogdanov, J. Kazandjieva, N. Tsankov, Cutaneous adverse effects of the available COVID-19 vaccines, *Clin Dermatol*. 39 (2021) 523–531.
- [41] K. Murugiah, Y. Wang, N.R. Desai, E.S. Spatz, S. V Nuti, R.P. Dreyer, H.M. Krumholz, Trends in short-and long-term outcomes for takotsubo cardiomyopathy among medicare fee-for-service beneficiaries, 2007 to 2012, *JACC Hear Fail*. 4 (2016) 197–205.
- [42] SKS. Tejtel, F.M. Munoz, I. Al-Ammouri, F. Savorgnan, R.K. Guggilla, N. Khuri-Bulos, L. Phillips, R.J.M. Engler, Myocarditis and pericarditis: case definition and guidelines for data collection, analysis, and presentation of immunization safety data, *Vaccine*. (2022).
- [43] A. Đenić, Similarities and differences of cardiovascular complications of COVID-19 infection and COVID-19 vaccination, *Med Glas Spec Boln Za Boles Štitaste Žlezde i Boles Metab*. 27 (2022) 69–89.
- [44] Di Micco P, Camporese G, Cardillo G, Lodigiani C, Carannante N, Annunziata A, Fiorentino G, Russo V, Imbalzano E. Pathophysiology of vaccine-induced prothrombotic immune thrombocytopenia (VIPIT) and vaccine-induced thrombocytopenic thrombosis (VITT) and their diagnostic approach in emergency. *Medicina*. 2021 Oct;57(10):997.
- [45] Menni C, Klaser K, May A, Polidori L, Capdevila J, Louca P, Sudre CH, Nguyen LH, Drew DA,



- Merino J, Hu C. Vaccine side-effects and SARS-CoV-2 infection after vaccination in users of the COVID Symptom Study app in the UK: a prospective observational study. *The Lancet Infectious Diseases*. 2021 Jul 1;21(7):939-49.
- [46] Chu L, McPhee R, Huang W, Bennett H, Pajon R, Nestorova B, Leav B, mRNA-1273 Study Group. A preliminary report of a randomized controlled phase 2 trial of the safety and immunogenicity of mRNA-1273 SARS-CoV-2 vaccine. *Vaccine*. 2021 May 12;39(20):2791-9.
- [47] Jani C, Leavitt J, Al Omari O, Dimaso A, Pond K, Gannon S, Chandran AK, Dennis C, Colgrove R. COVID-19 Vaccine–Associated Takotsubo Cardiomyopathy. *American Journal of Therapeutics*. 2021 May 1;28(3):361-4.
- [48] Stewart C, Gamble DT, Dawson D. Novel case of takotsubo cardiomyopathy following COVID-19 vaccination. *BMJ Case Reports CP*. 2022 Jan 1;15(1):e247291.
- [49] Berto MB, Spano G, Wagner B, Bernhard B, Häner J, Huber AT, Gräni C. Takotsubo cardiomyopathy after mRNA COVID-19 vaccination. *Heart, Lung and Circulation*. 2021 Dec 1;30(12):e119-20.
- [50] X. Wang, J. Pei, X. Hu, The brain-heart connection in takotsubo syndrome: the central nervous system, sympathetic nervous system, and catecholamine overload, *Cardiol Res Pract*. 2020 (n.d.).
- [51] H. Suzuki, Y. Matsumoto, T. Kaneta, K. Sugimura, J. Takahashi, Y. Fukumoto, S. Takahashi, H. Shimokawa, Evidence for brain activation in patients with takotsubo cardiomyopathy, *Circ J*. 78 (2014) 256–258
- [52] A. Radfar, S. Abohashem, M.T. Osborne, Y. Wang, T. Dar, M.Z.O. Hassan, A. Ghoneem, N. Naddaf, T. Patrich, T. Abbasi, Stress-associated neurobiological activity associates with the risk for and timing of subsequent Takotsubo syndrome, *Eur Heart J*. 42 (2021) 1898–1908.

- [53] T. Hiestand, J. Hänggi, C. Klein, M.S. Topka, M. Jaguszewski, J.R. Ghadri, T.F. Lüscher, L. Jäncke, C. Templin, Takotsubo syndrome associated with structural brain alterations of the limbic system, *J Am Coll Cardiol.* 71 (2018) 809–811
- [54] V.H. Pereira, P. Marques, R. Magalhães, J. Português, L. Calvo, J.J. Cerqueira, N. Sousa, Central autonomic nervous system response to autonomic challenges is altered in patients with a previous episode of Takotsubo cardiomyopathy, *Eur Hear J Acute Cardiovasc Care.* 5 (2016) 152–163.
- [55] H. Paur, P.T. Wright, M.B. Sikkil, M.H. Tranter, C. Mansfield, P. O’gara, D.J. Stuckey, V.O. Nikolaev, I. Diakonov, L. Pannell, High levels of circulating epinephrine trigger apical cardiodepression in a  $\beta_2$ -adrenergic receptor/Gi-dependent manner: a new model of Takotsubo cardiomyopathy, *Circulation.* 126 (2012) 697–706
- [56] M. Naegele, A.J. Flammer, F. Enseleit, S. Roas, M. Frank, A. Hirt, P. Kaiser, S. Cantatore, C. Templin, G. Fröhlich, Endothelial function and sympathetic nervous system activity in patients with Takotsubo syndrome, *Int J Cardiol.* 224 (2016) 226–230.
- [57] Bybee KA, Kara T, Prasad A, Lerman A, Barsness GW, Wright RS, Rihal CS. Systematic review: transient left ventricular apical ballooning: a syndrome that mimics ST-segment elevation myocardial infarction. *Ann Intern Med* 2004;141:858–865.
- [58] Ahmed SK. Myocarditis after BNT162b2 and mRNA-1273 COVID-19 vaccination: A report of 7 cases. *Annals of Medicine and Surgery.* 2022 May 1;77:103657.
- [59] Mert GÖ, Radi F, Mert KU. The diagnostic challenge: Takotsubo cardiomyopathy vs. acute myocarditis. *Heart & Lung: The Journal of Cardiopulmonary and Acute Care.* 2018 Nov 1;47(6):646.
- [60] Wittstein IS. The sympathetic nervous system in the pathogenesis of Takotsubo syndrome.

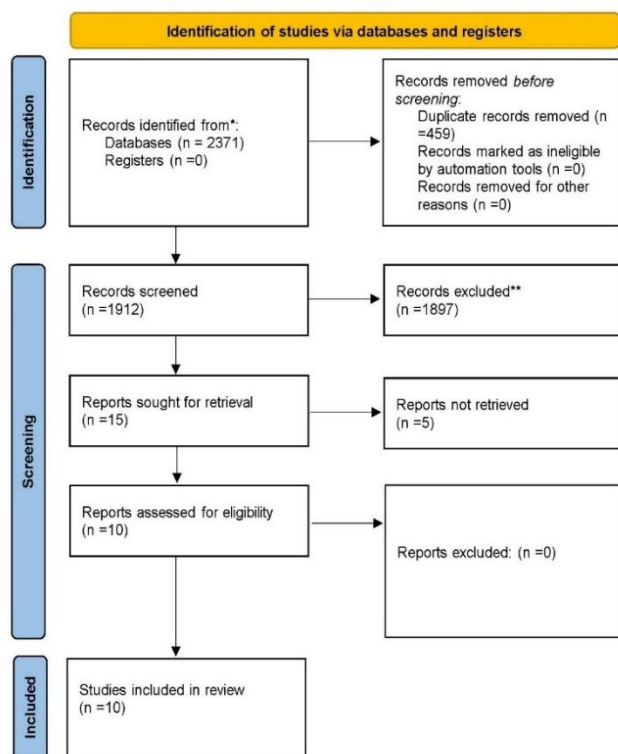
Heart failure clinics. 2016 Oct 1;12(4):485-98.

- [61] Wittstein IS, Thiemann DR, Lima JA, Baughman KL, Schulman SP, Gerstenblith G, Wu KC, Rade JJ, Bivalacqua TJ, Champion HC. Neurohumoral features of myocardial stunning due to sudden emotional stress. *New England journal of medicine*. 2005 Feb 10;352(6):539-48.
- [62] Ereda A, Toselli M, Palmisano A, Vignale D, Khokhar A, Campo G, Bertini M, Loffi M, Andreini D, Pontone G, Patelli G, Sangiorgi GM, Tumminello G, Elia M, Iacovoni A, Carugo S, Rapezzi C, Colombo A, Giannini F, Esposito A. Coronary calcium score as a predictor of outcomes in the hypertensive Covid-19 population: results from the Italian (S) Core-Covid-19 Registry. *Hypertens Res*. 2022 Feb;45(2):333-343. doi: 10.1038/s41440-021-00798-9. Epub 2021 Nov 18. PMID: 34789917; PMCID: PMC8598930.
- [63] Jani C, Leavitt J, Al Omari O, Dimaso A, Pond K, Gannon S, Chandran AK, Dennis C, Colgrove R. COVID-19 Vaccine–Associated Takotsubo Cardiomyopathy. *American Journal of Therapeutics*. 2021 May 1;28(3):361-4.
- [64] Nyman E, Mattsson E, Tornvall P. Trigger factors in takotsubo syndrome—a systematic review of case reports. *European Journal of Internal Medicine*. 2019 May 1;63:62-8.
- [65] Toida R, Uezono S, Komatsu H, Toida T, Imamura A, Fujimoto S, Kaikita K. Takotsubo cardiomyopathy after vaccination for coronavirus disease 2019 in a patient on maintenance hemodialysis. *CEN Case Reports*. 2021 Nov 3:1-5.
- [66] Tejtel SK, Munoz FM, Al-Ammouri I, Savorgnan F, Guggilla RK, Khuri-Bulos N, Phillips L, Engler RJ. Myocarditis and pericarditis: case definition and guidelines for data collection, analysis, and presentation of immunization safety data. *Vaccine*. 2022 Jan 31.
- [67] Đenić A. Similarities and differences of cardiovascular complications of COVID-19 infection and COVID-19 vaccination. *Medicinski glasnik Specijalne bolnice za bolesti štitaste žlezde i*

bolesti metabolizma'Zlatibor'. 2022;27(84):69-89.

- [68] Ahmed SK, Mohamed MG, Essa RA, Rashad EA, Ibrahim PK, Khdir AA, Wsu ZH. Global reports of myocarditis following COVID-19 vaccination: A systematic review and meta-analysis. *Diabetes & Metabolic Syndrome: Clinical Research & Reviews*. 2022 May 27:102513.

**Fig 1:** PRISMA flow diagram.



**Table 1:** Characteristics and outcomes of patients with takotsubo cardiomyopathy related to COVID-19

Vaccine.

Author/Year of publication	Berto et al 2021 [15]	Jani et al 2021 [16]	Reiko Toida et al 2021 [17]	Caitlin Stewart et al 2021 [1]	Colleen Fearon et al 2021 [18]	Hiroki Yamaura et al 2022 [19]	Phillip Crane et al 2021 [20]	Mahesh K. Vidula et al 2021 [21]	Tedeschi, et al 2022 [22]	Ricci et al 2022 [23]
Country	Switzerland	United States	Japan	United Kingdom	United States	Japan	Australia	United States	Italy	Italy
Age/years	63	65	80	50	73	30	72	60	71	54
Gender	Female	Female	Female	Female	Female	Female	Male	Female	Female	Female
Type of vaccine	mRNA-1273	mRNA-1273	BNT162b2	ChadOX1 nCOV-19	mRNA-1273	BNT162b2	ChadOX1 nCOV-19	BNT162b2	BNT162b2	mRNA-1273
Dose of Vaccine	1 <sup>st</sup>	1 <sup>st</sup>	1 <sup>st</sup>	2 <sup>nd</sup>	NA.	2 <sup>nd</sup>	1 <sup>st</sup>	2 <sup>nd</sup>	1 <sup>st</sup>	2 <sup>nd</sup>
Days to symptom onset	1	1	1	7	1	2	4	4	5 hours	Few hours
Symptoms	dyspnoea and fever.	Chest pain, myalgia, nausea, headache	General fatigue, loss of appetite	Chest pain	chest pain, shortness of breath, fatigue, nausea	chest pain and cold sweat	Chest pain, fatigue and myalgias, fever	Chest pain	chest pain and shortness of breath	palpitations, asthenia, and intermittent chest tightness
Troponin level	Elevated	Elevated	Elevated	Elevated	Elevated	Elevated	Elevated	Elevated	Elevated	Elevated
LVEF <50% or LVEF >50%	LVEF <50%	LVEF <50%	LVEF <50%	LVEF <50%	LVEF >50%	LVEF <50%	LVEF <50%	LVEF <50%	LVEF <50%	LVEF <50%
Electrocardiogram (ECG)	Abnormal	Abnormal	Abnormal	Abnormal	Abnormal	Abnormal	Abnormal	Abnormal	Abnormal	Abnormal
Length of hospital stay (days)	NA	NA	13	5	8	15	10	NA	NA	NA
Treatment	NA	Aspirin, atorvastatin, lisinopril, metoprolol succinate	Oxygen, IV fluid	Dual antiplatelet therapy	metoprolol succinate, losartan	The patient was managed without medical therapies	patient received appropriate introduction and titration of therapy	metoprolol succinate and lisinopril.	NA	NA
Outcome	Discharged	Discharged	Discharged	Discharged	Discharged	Discharged	Discharged	Discharged	Discharged	Discharged

**Table 2:** Summary of pooled data from included published research papers have been reported in the literature (n = 10)

<b>Variables</b>	<b>Results</b>
Age (Mean ± SD)	61.8 ± 13.68 years
Gender (n) %	Male – 1 (10%)
	Female – 9 (90%)
Type of COVID-19 vaccine (n) %	Pfizer-BioNTech (BNT162b2) – 4 (40%)
	Moderna COVID-19 Vaccine (mRNA-1273) - 4 (40%)
	Oxford, AstraZeneca COVID-19 vaccine ChAdOx1 nCoV-19 – 2 (20%)
Dose (n) %	First dose – 5 (50%)
	Second dose – 4 (40%)
	None reported 1 (10%)
Days to symptom onset (Mean ± SD)	2.62 ± 2.19 days
Troponin level (n) %	Elevated – 10 (100%)
	Not elevated – 0 (0%)
Left ventricular ejection fraction LVEF (n) %	LVEF >50% - 9 (90%)
	LVEF <50% - 1 (10%)
Electrocardiogram (ECG) (n) %	Abnormal – 10 (100%)
	Normal – 0 (0%)
Length of hospital stay (days) (Mean ± SD)	10.20 ± 3.96 days in 5 patients
	Unknown in 5 patients
Outcome	Recovered – 10 (100%)