Global reports of takotsubo (stress) cardiomyopathy following COVID-19 vaccination: a systematic review and meta-analysis

Sirwan Khalid Ahmed[1], Mona Gamal Mohamed[2], Rawand Abdulrahman Essa[1], Eman Abdelaziz Ahmed Rashad[2]

[1] Department of Emergency, Ranya Teaching Hospital, Ranya, Sulaimani, Kurdistan-region, Iraq

[2] Department of Adult Nursing, RAK Medical and Health Sciences University, Ras Al Khaimah, UAE

Corresponding Author:

Sirwan Khalid Ahmed

Department of Emergency, Ranya Teaching Hospital, Ranya 46012, Sulaimani, Kurdistan-region, Iraq

TEL: +9647501553224

Email: sirwan.ahmed1989@gmail.com

Abstract

Concerns have been raised recently about takotsubo cardiomyopathy after receiving COVID-19 vaccines, particularly the messenger RNA (mRNA) vaccines. The goal of this study was to compile case reports in order to provide a comprehensive overview of takotsubo cardiomyopathy associated with COVID-19 vaccines. A systematic literature search was conducted in PubMed, Scopus, Embase, Web of Science, and Google Scholar databases between 2020 and June 1, 2022. The study included individuals who developed cardiac takotsubo cardiomyopathy as a result of receiving COVID-19 vaccinations. Ten studies, including 10 cases, participated in the current systematic review. The mean age was 61.8 years; 90% were female, while 10% were male. 80% of the patients received the mRNA COVID-19 vaccine, while 20% received other types. In addition, takotsubo cardiomyopathy occurred in 50% of patients after receiving the first dose and another 40% after the second dose of COVID-19 vaccines. Moreover, the mean number of days to the onset of symptoms was 2.62 days. All cases had an elevated troponin test and abnormal ECG findings. The left ventricular ejection fraction (LVEF) was lower than 50% in 90% of patients. In terms of the average length of stay in the hospital, 50% stayed for 10.2 days, and all cases recovered from their symptoms. In conclusion, takotsubo (stress) cardiomyopathy complications that are associated with COVID-19 vaccination are rare, but they can be life-threatening. Chest pain should be considered an alarming symptom, especially in those who have received the first and/or second dose of the COVID-19 vaccine.

Keywords

Takotsubo cardiomyopathy, stress cardiomyopathy, COVID-19 Vaccine, broken heart syndrome, mRNA vaccine, BNT162b2, mRNA-1273, ChadOX1 nCOV-19

Introduction

The coronavirus (COVID)-19 pandemic, which was caused by the severe acute respiratory syndrome coronavirus-2 (SARS-CoV-2), has had a negative impact on millions of people all over the world. SARS-CoV-2 vaccines are still the best hope for combating the global pandemic. The FDA granted emergency approval to Pfizer-BioNTech (BNT162b2) and Moderna (mRNA-1273) COVID-19 vaccines in December 2020.

Takotsubo cardiomyopathy (TTS) is a type of heart disease that is frequently triggered by strong physical and/or emotional stress. Although the pathophysiology of this condition is not fully understood, studies have suggested that it may be caused by activation of central autonomic neurons expressing oestrogen receptors, coronary vasospasm, increased sensitivity to a surge in circulating catecholamines, and metabolic dysfunction [1]. Catecholamine levels have been found to be higher in TTS than in STEMI [2,3]. As a result of the COVID-19 pandemic, TTS cases have risen from 1.5% to 7.8% [4]. TTS has already been linked to a 'cytokine storm' of interleukin 6 (IL-6) and tumor necrosis factor alpha (TNFa), which causes hyperinflammation in COVID-19- patients [5,6]. Individuals who presented without COVID-19 infection or other notable risk factors may have been infected with TTS due to the psychological stress of living in a pandemic [1] . TTS is more likely to occur in people who have a history of mental illness before the outbreak of the pandemic [5,7–9]. Moderna mRNA1273 and Pfizer BioNTech BNT1626b2 (COVID-19 mRNA vaccines) induce innate immunity, cytotoxic and helper T cell responses, and in particular B cell responses [10]. Pain, erythema, swelling, fever, headache, and myalgia were the most common systemic or local reactions reported [11]. However, acute myocardial infarction, pulmonary embolism, stroke, and venous thromboembolism are all possible complications of mRNA based COVID-19 vaccines [12–14]. There have been reports of takotsubo cardiomyopathy following the COVID-19 vaccination, particularly following the messenger RNA (mRNA) vaccines [1,15–23].

We are aware of no systematic review that has been conducted specifically for COVID-19 vaccine induced stress cardiomyopathy (TTS). Given the rarity of adverse takotsubo cardiomyopathy

associated with COVID19 vaccination, the majority of the peer reviewed and published papers are case reports. The goal of this study was to compile case reports in order to provide a comprehensive overview of takotsubo cardiomyopathy (TTS) associated with COVID-19 vaccines.

Methods

Review objectives

In this study, the primary goal is to clarify the possibility of takotsubo cardiomyopathy associated with COVID-19 vaccination and to elaborate on the demographic and clinical characteristics of COVID-19 vaccinated individuals who develop takotsubo cardiomyopathy.

Protocol and Registration

The review follows the PRISMA 2020 guidelines for reporting systematic reviews and meta-analyses [24]. The review protocol was recorded in the International Prospective Register of Systematic Reviews (PROSPERO) under the registration number CRD42022316515. Additionally, the AMSTAR-2 checklist was used to assess the quality of this review, which was found to be of high quality [25]. Ethical approval was not required for this review article.

Search strategy

A comprehensive search of major online databases (PubMed, Scopus, Embase, Web of Science, and Google Scholar) was performed from 2020 until June 1, 2022, in order to discover all articles that had been published. The search strategy consisted of a combination of the following key words: “COVID-19 vaccine” AND “takotsubo cardiomyopathy” OR “stress cardiomyopathy”. In addition, we checked the references of all relevant papers to ensure the search was complete.

Eligibility criteria

1. All case series, and case reports after the COVID-19 vaccine developed takotsubo cardiomyopathy (TTS) in humans, regardless of the type of vaccine and dose, were included.

2. In this review, narrative and systematic reviews, as well as papers with insufficient data, were excluded. Furthermore, articles written in languages other than English were excluded.

Data extraction and selection process

Every step of the data extraction process from the original source was guided by PRISMA 2020, which was used to guide the process. Three independent authors (SKA, RAE, and MGM) used the Rayyan website to screen abstracts and full-text articles based on inclusion and exclusion criteria [26]. Disagreements between the three independent authors were resolved by discussion. The data extraction process was carried out using predefined forms in Microsoft Office Excel. A total of the following information was extracted from each research study: author names, year of publication, age, gender, type of COVID-19 vaccine, dose, troponin levels, days to symptoms onset, symptoms, length of hospital stay/days, ECG, LVEF < 50% or LVEF > 50%, treatment and their outcomes.

Critical appraisal

We used the Joanna Briggs Institute's critical appraisal tool for case reports to evaluate all included studies [27]. Each article was evaluated independently by three authors (SKA, MGM, and RAE). The paper evaluation disagreements were resolved either through discussion or by the first author (SKA). The results of our systematic review were evaluated using the AMSTAR 2 criteria [25]. The overall quality of our systematic review was rated "moderate" by the AMSTAR 2 tool.

Data synthesis and analysis

The data from all the articles included in this systematic review were extracted and pooled. This included (author names, year of publication, age, gender, type of COVID-19 vaccine, dose, troponin

levels, days to symptoms onset, symptoms, length of hospital stay/days, ECG, LVEF <50% or LVEF >50%, treatment and their outcomes). We collected this information from the findings of eligible studies. Statistical analysis will be performed using the Statistical Package for the Social Sciences (SPSS) 25.0 software program (SPSS Inc, Chicago, IL, USA). Categorical data will be expressed as proportions (%), and numerical data will be expressed as mean ± standard deviation (SD). We pooled the results of the studies into one table.

Results

Selection of studies

The search was performed on major databases (PubMed, Scopus, Embase, Web of Science, and Google Scholar) between 2020 and June 1, 2022 and yielded 2371 articles relevant to our search criteria. The references were then organized using a citation manager tool (Mendeley), and 459 articles were automatically eliminated because they were duplicates. Then, a final check was performed on 1912 articles to ensure that their titles, abstracts, and full texts were accurate. There were 1897 articles that were rejected because they did not meet the requirements to be included. Aside from that, 15 articles were submitted for retrieval, with five of them being rejected because they did not meet our inclusion criteria. Finally, our systematic review included only 10 articles (**Fig 1**). Case report details are shown in (**Table 1**).

Characteristics of the included studies

Table 2 shows an overview of the ten cases. The mean age and SD were 61.8 ±13.68 years; 90% were female, while %10 were male. %80 of the patients received the mRNA COVID-19 vaccine either from Pfizer-BioNTech (BNT162b2) or Moderna COVID-19 Vaccine (mRNA-1273), while 20% of patients received other types, including AstraZeneca COVID-19 vaccine (ChAdOx1 nCoV-19). In addition, takotsubo cardiomyopathy occurred in 50% of patients after receiving the first dose and another 40% after the second dose of COVID-19 vaccines. Moreover, the mean number of days

to the onset of symptoms was 2.62 ± 2.19 days. All cases had an elevated troponin test and abnormal ECG findings. The left ventricular ejection fraction (LVEF) was lower than 50% in 90% of patients. In terms of the average length of stay in the hospital, 50% stayed for 10.20 ± 3.96 days, and all cases recovered from their symptoms.

Discussion

Purposes of COVID-19 vaccinations

COVID-19 vaccines protect the general public and restrict viral propagation. Inactivated viral, DNA, mRNA, and protein-based vaccines are the four primary mechanisms examined in this research for COVID-19 vaccines. DNA-based vaccinations use viral vectors to deliver the DNA coding for the SARS-CoV-2 spike protein into cells; mRNA vaccines usually deliver mRNA into cells using a lipid nanoparticle; protein vaccines use the spike proteins or their particles; and some other vaccinations use inactivated viruses [28].

Vaccines are one of the most effective treatments to combat COVID-19, saving millions of lives each year. The rapid development of vaccines raises the potential for vaccine-related safety concerns. Many countries are developing vaccines to protect the population after the COVID 19 pandemic [29]. Many vaccines were available earlier than planned due to urgent needs. New technologies are also helping to develop much more effective vaccines. However, those potential adverse effects must be considered [30].

With increasing populations being vaccinated daily, we are seeing an increase in reports of associated side effects. The most common side effects reported are pain, swelling, and redness around the injection site. Systemic effects such as fever, fatigue, myalgia, and headache can also occur in around one in four. A higher prevalence of these systemic effects has been noted in women [31]. Moreover, serious side effects such as thrombocytopenic thrombosis, anaphylaxis, Bell's

palsy, myocarditis, increased blood pressure and capillary leak syndrome have been reported [32,33].

Pathophysiology and mechanism of injury of takotsubo syndrome.

Although the pathophysiology of takotsubo syndrome after COVID-19 vaccination is not well established, the proposed hypotheses are stunning changes in ischemia-induced myocardium secondary to micro vessel or multi vascular vasospasm; direct myocardial injury due to surge currents. Animal studies modelling the octopus trap showed high serum epinephrine levels and high apical-basal levels. Pleiotropic b2-adrenergic receptor gradient in the context of apical myocardial depression, consistent with typical takotsubo syndrome echocardiographic findings [34].

Also, the mechanism behind this is a controversy for which the decisive mechanism has not yet been identified. Some authors develop cytokine storms, cause systemic inflammatory response syndrome (SIRS), cause broken heart syndrome, and, despite aggressive treatment, cause heart failure that is difficult to withdraw from the ventilator [35]. Acute emotional or physical stressors induce increased levels and bioavailability of catecholamines and cortisol in the blood that mediate multiple pathways of pericardial coronary artery spasm, microvascular dysfunction, and direct muscle cell injury, which are all key findings of TTS. References to the essential role of catecholamines in TTS include, high plasma levels in affected patients and subsequent induction of TTS-like disease, administration of epinephrine or norepinephrine [36].

While producing catecholamines, the positive inotropic effects of Gs-coupling proteins activate 2 adrenergic receptors. The heart tissue is different if high levels of epinephrine (but no epinephrine) are present. Once secreted, the 2ad receptor switches from Gs to Gi coupling. This switch to Gi is predominant at the apex of heart tissue and is intended to be limited in the degree of myocardial injury during the catecholamine surge induced by cardiotoxic activation of 1 and 2 adrenergic receptors Gs pathway [37].

The release of several inflammatory cytokines, including interleukin-6 and tumor necrosis factor, in the cytokine storm that follows vaccination is multifactorial and mediated by direct effects of the cytokine storm and microvascular dysfunction. It is not clear, however, why a high incidence of TTS has been reported during a specific time post-vaccine. Moreover, TTS cases have been reported following COVID-19 vaccinations. It should be noted that disease-induced stress and catecholamine surge may also aggravate these pathways, and such an overlap in mechanisms seems reasonable. Elevated levels of catecholamines have been found in aortic roots and coronary sinuses in patients with COVID-19 vaccine and TTS [38,39]. In addition, in 2018, Chazal et al published a review paper in the journal of the American College of Cardiology that shows the pathophysiology of takotsubo cardiomyopathy (**Fig 2**).

In our systematic review, most of the participants were female, and their mean age was 61.8 years old. Other case reports who supported that, including a case of takotsubo cardiomyopathy (TTS) following administration of the second dose of the DNA ChadOX1 nCOV-19 (AZD122) vaccination, reported that this condition predominantly affects women (90%) at age 50 and above [1]. In our review, the patients received different types of COVID-19 vaccination, such as Pfizer-BioNTech (BNT162b2) or Moderna (mRNA-1273), and AstraZeneca (ChAdOx1 nCoV-19), and 50% of them had only received the first dose of COVID-19 vaccine. For example, Jani et al. (2021) mention that up to now, few cases of takotsubo cardiomyopathy have occurred after SARS-CoV-2 vaccines first or second dose administration have been reported, even including different types of vaccines (mRNA-1273, BNT162b2, and ChAdOx1 nCoV-19) [16]. Also, Berto et al. (2021) reported A healthy 30-year-old Asian woman was brought to the emergency room with sudden chest pain and a cold sweat. She received the second mRNA COVID-19 vaccine shot (Pfizer) 2 days prior [15].

Diagnostic criteria

TTS is diagnosed according to the Mayo Clinic criteria. According to these criteria, TTS has left ventricular hypokinesia, akinesia, or dyskinesia, and these local wall dyskinesias, with or without apex involvement, are specific epicardial vasculature boundaries. It is diagnosed when it expands beyond. No evidence by angiography of obstructive coronary artery disease or acute plaque rupture; new ST elevation or T wave inversion or mild cardiac troponin elevation; lack of brown cell tumor or myocarditis. TTS mimics myocardial infarction in clinical, electrocardiographic, echocardiographic, and hematological studies. TTS is triggered by emotional, physical, or unknown triggers. However, according to a recent review, physical triggers predominant in male and female patients. The discussion of TTS in index patients is clinical symptoms (abdominal chest pain), ECG (T wave reversal), echocardiography (apical and apex hypomotility), and elevated troponin, CKMB, and proBNP [16,40]. Other criteria for diagnosed takotsubo cardiomyopathy was developed by Ghadri et al and published in the European Heart Journal [41] is International Takotsubo Diagnostic Criteria (InterTAK Diagnostic Criteria) (**Table 3**). Furthermore, an algorithm for the diagnosis of takotsubo syndrome (also known as TTS) has been proposed by the expert committee [42] (**Fig 3**).

Another important finding in the current systematic review, the initiation of symptoms post vaccine about three days, all of cases had elevated troponin level, the left ventricular ejection fraction LVEF was lower than 50% in 90% patients and electrocardiogram shown abnormal finding.

These findings matched with Toida et al. 2021, who reported that patient had received the first dose of the Pfizer-BioNTech COVID-19 vaccine. The day after the vaccination, she developed general fatigue and loss of appetite. At admission, systolic/diastolic blood pressure was 82/47 mmHg, and heart rate was 114 bpm with an irregular rhythm. A physical examination revealed a systolic murmur of Levine 2/6 at the second left sternal border, clear lung sounds, and no leg edema. On admission, electrocardiography (ECG) newly revealed atrial fibrillation with a normal axis, negative T-waves in I, aVL, and V3-6, and a prolonged QTc interval of 495 ms [17].

Management and outcome

The optimal management of myocardial injury post-COVID-19 vaccine has not yet been established. Therefore, for the management of patients with myocardial disorders, including patients with suspected TTS, support measures such as angiotensin receptor inhibitors and angiotensin converting enzyme (ACE) inhibitors are necessary. This includes treatment of arrhythmias and avoidance of heart toxins; alternatively, angiotensin receptor blockers (ARBs), which are used to reduce ejection fraction and treat heart failure [43].

Medical management for Takotsubo cardiomyopathy (TTS) is based on the presence or absence of hemodynamic stability and other complications. Patients who have complications such as acute heart failure without LV outflow tract obstruction should receive diuretics, angiotensin-converting enzyme (ACE) inhibitors or angiotensin II receptor blockers, and beta-blockers [44].

However, in contrast to the mortality benefit realized in other types of heart failure, therapy with beta-blockers and ACE inhibitors does not discuss significant survival benefits in patients with Takotsubo cardiomyopathy (TTS). In addition, only ACE inhibitors were shown to help prevent the recurrence of takotsubo cardiomyopathy [45]. The role of aldosterone antagonists has not been well-established, but they have been hypothesized to be potentially cardioprotective due to anti-catecholamine effects [46].

Guidelines on the duration of treatment are lacking, but patients are typically treated for 4 weeks until the improvement of LVEF. There are no studies that have evaluated the role of goal-directed medical therapy on atypical variant takotsubo [18].

Patients with takotsubo syndrome generally have a good prognosis. An outcomes study assessing trends of hospitalized patients with takotsubo cardiomyopathy demonstrated an in-hospital mortality rate of 1.3% [95% confidence interval (CI) 1.1–1.6], hospital discharge rate to the home of 73.6% (95% CI 72.7–74.6), and 1-year mortality of 6.9% (95% CI 6.4–7.5) [47]. Consistent with the prior case experiences of post-DCCV takotsubo syndrome, and was discharged home without the need

for post-acute care services. Repeat TTE at 2 months showed complete global and regional restoration of LV function [48]. We found the patient's length of hospital stay Mean ± SD were 10.20 ± 3.96 days and all of them recovered without any complications. These findings are in contrast with Toida et al. (2021), who showed the case report regarding takotsubo cardiomyopathy after the COVID-19 vaccine and found the patient length of hospital stay was about 5 days post-event [17].

Support for our finding by Đenić et al. 2022, who reported the patient improved clinically and had no evidence of high-risk features on 12-lead ECG or TTE. The patient was followed up after 3 months. Her follow-up CMR showed resolving myocardial edema in the apex and septum. Repeat TTE showed normal left ventricular (LV) systolic function and resolution of previously noted wall motion abnormalities [49].

While takotsubo cardiomyopathy (TTS) after COVID-19 vaccine pathogenesis is incompletely understood, catecholamine excess mediated myocardial stunning is favoured, with excess release precipitated by a physical or emotional triggering event. Primarily seen in aged women, the diagnosis of takotsubo is made on presentation and triggers characteristic imaging and exclusion of acute coronary syndrome and myocarditis. A cytokine storm has been described as an excessive and uncontrolled inflammatory response, and there is a feedback loop between catecholamines and cytokines [22].

Limitation

We recognize that our systematic review has some limitations, which include: only involved case reports and case series due to the limited numbers of original studies published on the takotsubo cardiomyopathy after taken COVID-19 vaccines so the results should be interpreted with some caution. Moreover, we do not have any data about the previous history of COVID-19, which may affect the results since COVID-19 can also cause cardiac complications.

Conclusion

Takotsubo (stress) cardiomyopathy (TTS) complications that are associated with COVID-19 vaccination are rare, but they can be life-threatening. Chest pain should be considered an alarming symptom, especially in those who have received a second dose of the vaccine in the last 3 days. For diagnosis, CK-MB and troponin are better biomarkers to confirm myocarditis than CRP, ESR, and NT□proBNP. All of the cases had completely recovered without any irreversible cardiomyopathy changes.

Conflicts of interest

There is no conflict to be declared.

Funding

This research did not receive any specific grant from funding agencies in the public, commercial, or not-for-profit sectors.

Author Agreement Statement

We declare that this manuscript is original, has not been published before and is not currently being considered for publication elsewhere. We confirm that the manuscript has been read and approved by all named authors and that there are no other persons who satisfied the criteria for authorship but are not listed. We confirm that the order of authors listed in the manuscript has been approved by all of us. We understand that the Corresponding Author is the sole contact for the Editorial process. He is responsible for communicating with the other authors about progress, submissions of revisions and final approval of proofs.

Data availability Statement

All relevant data are within the manuscript and its supporting information files.

Authors' contributions: Conception and design SKA acquisition of data SKA, RAE, MGM, EAA analysis and interpretation of data SKA, RAE, MGM, EEA, drafting of the manuscript SKA, RAE, MGM, EAA critical revision of the manuscript for important intellectual content statistical analysis SKA, administrative SKA, RAE, MGM, EAA technical SKA, supervision SKA and all authors approving final draft.

Provenance and peer review

Not commissioned, externally peer-reviewed

Acknowledgments

Not applicable

References

[1] C. Stewart, D.T. Gamble, D. Dawson, Novel case of takotsubo cardiomyopathy following COVID-19 vaccination, BMJ Case Reports CP. 15 (2022) e247291.

[2] C. Templin, J.R. Ghadri, J. Diekmann, L.C. Napp, D.R. Bataiosu, M. Jaguszewski, V.L. Cammann, A. Sarcon, V. Geyer, C.A. Neumann, Clinical features and outcomes of takotsubo (stress) cardiomyopathy, N Engl J Med. 373 (2015) 929–938.

[3] R. Ono, L.M. Falcão, Takotsubo cardiomyopathy systematic review: pathophysiologic process, clinical presentation and diagnostic approach to Takotsubo cardiomyopathy, Int J Cardiol. 209 (2016) 196–205.

[4] R.M. Shah, M. Shah, S. Shah, A. Li, S. Jauhar, Takotsubo syndrome and COVID-19: associations and implications, Curr Probl Cardiol. 46 (2021) 100763.

[5] S. Singh, R. Desai, Z. Gandhi, H.K. Fong, S. Doreswamy, V. Desai, A. Chockalingam, P.K. Mehta, R. Sachdeva, G. Kumar, Takotsubo syndrome in patients with COVID-19: a systematic review of published cases, SN Compr Clin Med. 2 (2020) 2102–2108.

[6] C. Scally, H. Abbas, T. Ahearn, J. Srinivasan, A. Mezincescu, A. Rudd, N. Spath, A. Yucel-Finn, R. Yuecel, K. Oldroyd, Myocardial and systemic inflammation in acute stress-induced (Takotsubo) cardiomyopathy, Circulation. 139 (2019) 1581–1592.

[7] A. Jabri, A. Kalra, A. Kumar, A. Alameh, S. Adroja, H. Bashir, A.S. Nowacki, R. Shah, S. Khubber, K. Anmar, Incidence of stress cardiomyopathy during the coronavirus disease 2019 pandemic, JAMA Netw Open. 3 (2020) e2014780–e2014780.

[8] L. Barbieri, F. Galli, B. Conconi, T. Gregorini, S. Lucreziotti, A. Mafrici, G. Pravettoni, M. Sommaruga, S. Carugo, Takotsubo syndrome in COVID-19 era: Is psychological distress the key?, J Psychosom Res. 140 (2021) 110297.

[9] J. Rivers, J.F. Ihle, COVID□19 social isolation□induced takotsubo cardiomyopathy, Med J Aust. 213 (2020) 336.

[10] R. Verbeke, I. Lentacker, S.C. De Smedt, H. Dewitte, The dawn of mRNA vaccines: The COVID-19 case, J Control Release. 333 (2021) 511–520.

[11] F.P. Polack, S.J. Thomas, N. Kitchin, J. Absalon, A. Gurtman, S. Lockhart, J.L. Perez, G.P. Marc, E.D. Moreira, C. Zerbini, Safety and Efficacy of the BNT162b2 mRNA Covid-19 Vaccine, N Engl J Med. 383 (2020) 2603–2615.

[12] M. García-Grimshaw, L.E. Hernández-Vanegas, I. Núñez, N. Hernández-Valdivia, D.A. Carrillo-García, A. Michel-Chávez, J.A. Galnares-Olalde, G. Carbajal-Sandoval, M. del Mar Saniger-Alba, R.A. Carrillo-Mezo, Neurologic adverse events among 704,003 first-dose recipients of the BNT162b2 mRNA COVID-19 vaccine in Mexico: a nationwide descriptive study, Clin Immunol. 229 (2021) 108786.

[13] B. Bozkurt, I. Kamat, P.J. Hotez, Myocarditis with COVID-19 mRNA vaccines, Circulation. 144 (2021) 471–484.

[14] N.P. Klein, N. Lewis, K. Goddard, B. Fireman, O. Zerbo, K.E. Hanson, J.G. Donahue, E.O. Kharbanda, A. Naleway, J.C. Nelson, Surveillance for adverse events after COVID-19 mRNA vaccination, JAMA. 326 (2021) 1390–1399.

[15] M.B. Berto, G. Spano, B. Wagner, B. Bernhard, J. Häner, A.T. Huber, C. Gräni, Takotsubo cardiomyopathy after mRNA COVID-19 vaccination, Hear Lung Circ. 30 (2021) e119–e120.

[16] C. Jani, J. Leavitt, O. Al Omari, A. Dimaso, K. Pond, S. Gannon, A.K. Chandran, C. Dennis, R. Colgrove, COVID-19 Vaccine–Associated Takotsubo Cardiomyopathy, Am J Ther. 28 (2021) 361–364.

[17] R. Toida, S. Uezono, H. Komatsu, T. Toida, A. Imamura, S. Fujimoto, K. Kaikita, Takotsubo cardiomyopathy after vaccination for coronavirus disease 2019 in a patient on maintenance hemodialysis, CEN Case Reports. (2021) 1–5.

[18] C. Fearon, P. Parwani, B. Gow-Lee, D. Abramov, Takotsubo syndrome after receiving the COVID-19 vaccine, J Cardiol Cases. 24 (2021) 223–226.

[19] H. Yamaura, H. Ishikawa, K. Otsuka, N. Kasayuki, Reverse Takotsubo Cardiomyopathy as a Cause of Acute Chest Pain in a Young Woman Following COVID-19 Vaccination, Circ Cardiovasc Imaging. 15 (2022) e013661.

[20] P. Crane, C. Wong, N. Mehta, P. Barlis, Takotsubo (stress) cardiomyopathy after ChAdOx1 nCoV-19 vaccination, BMJ Case Reports CP. 14 (2021) e246580.

[21] M.K. Vidula, M. Ambrose, H. Glassberg, N. Chokshi, T. Chen, V.A. Ferrari, Y. Han, Myocarditis and other cardiovascular complications of the mRNA-based COVID-19 vaccines, Cureus. 13 (2021).

[22] A. Tedeschi, M. Camilli, U. Ianni, G. Tavecchia, M. Palazzini, I. Cartella, P. Gentile, G.

Quattrocchi, F.M. Spanò, M. Cipriani, Takotsubo Syndrome after BNT162b2 mRNA Covid-19 vaccine: emotional or causative relationship with vaccination?, Int J Cardiol Hear Vasc. 40 (2022).

[23] G. Ricci, G. Citarelli, D. De Laura, L. Degennaro, L. Ligurgo, M. Sassara, F. Corriero, S. Musci, P. Desario, D. Rutigliano, P311 TAKOTSUBO CARDIOMYOPATHY RELATED TO MRNA SARS–COV2 VACCINE, Eur Hear J Suppl. 24 (2022) suac012-298.

[24] M.J. Page, J.E. McKenzie, P.M. Bossuyt, I. Boutron, T.C. Hoffmann, C.D. Mulrow, L. Shamseer, J.M. Tetzlaff, E.A. Akl, S.E. Brennan, The PRISMA 2020 statement: an updated guideline for reporting systematic reviews, Int J Surg. 88 (2021) 105906. https://doi.org/https://doi.org/10.1016/j.ijsu.2021.105906.

[25] B.J. Shea, B.C. Reeves, G. Wells, M. Thuku, C. Hamel, J. Moran, D. Moher, P. Tugwell, V. Welch, E. Kristjansson, AMSTAR 2: a critical appraisal tool for systematic reviews that include randomised or non-randomised studies of healthcare interventions, or both, Bmj. 358 (2017).

[26] M. Ouzzani, H. Hammady, Z. Fedorowicz, A. Elmagarmid, Rayyan—a web and mobile app for systematic reviews, Syst Rev. 5 (2016) 1–10.

[27] S. Moola, Z. Munn, C. Tufanaru, E. Aromataris, K. Sears, R. Sfetcu, M. Currie, R. Qureshi, P. Mattis, K. Lisy, Chapter 7: Systematic reviews of etiology and risk, Joanna Briggs Inst Rev Manual Joanna Briggs Inst. 5 (2017). https://synthesismanual.jbi.global/.

[28] P. Di Micco, G. Camporese, G. Cardillo, C. Lodigiani, N. Carannante, A. Annunziata, G. Fiorentino, V. Russo, E. Imbalzano, Pathophysiology of vaccine-induced prothrombotic immune thrombocytopenia (VIPIT) and vaccine-induced thrombocytopenic thrombosis (VITT) and their diagnostic approach in emergency, Medicina (B Aires). 57 (2021) 997.

[29] T. Yoda, H. Katsuyama, Willingness to receive COVID-19 vaccination in Japan, Vaccines. 9 (2021) 48. https://doi.org/10.3390/vaccines9010048.

[30] K. Shahzamani, F. Mahmoudian, S. Ahangarzadeh, M.M. Ranjbar, L. Beikmohammadi, S. Bahrami, E. Mohammadi, S. Esfandyari, A. Alibakhshi, S.H. Javanmard, Vaccine design and delivery approaches for COVID-19, Int Immunopharmacol. 100 (2021) 108086.

[31] C. Menni, K. Klaser, A. May, L. Polidori, J. Capdevila, P. Louca, C.H. Sudre, L.H. Nguyen, D.A. Drew, J. Merino, Vaccine side-effects and SARS-CoV-2 infection after vaccination in users of the COVID Symptom Study app in the UK: a prospective observational study, Lancet Infect Dis. 21 (2021) 939–949.

[32] L. Chu, R. McPhee, W. Huang, H. Bennett, R. Pajon, B. Nestorova, B. Leav, mRNA-1273 S. Group, A preliminary report of a randomized controlled phase 2 trial of the safety and immunogenicity of mRNA-1273 SARS-CoV-2 vaccine, Vaccine. 39 (2021) 2791–2799.

[33] S.K. Ahmed, Myocarditis after BNT162b2 and mRNA-1273 COVID-19 vaccination: A report of 7 cases, Ann Med Surg. (2022) 103657. https://doi.org/10.1016/J.AMSU.2022.103657.

[34] A.L. Goss, R.D. Samudralwar, R.R. Das, A. Nath, ANA investigates: neurological complications of COVID□19 vaccines, Ann Neurol. 89 (2021) 856.

[35] K.J. Sonigra, K. Sarna, V.P. Vaghela, S. Guthua, An Interesting Case of Fatal Myasthenic Crisis Probably Induced by the COVID-19 Vaccine, Cureus. 14 (2022).

[36] I.S. Wittstein, The sympathetic nervous system in the pathogenesis of Takotsubo syndrome, Heart Fail Clin. 12 (2016) 485–498.

[37] I.S. Wittstein, D.R. Thiemann, J.A.C. Lima, K.L. Baughman, S.P. Schulman, G. Gerstenblith, K.C. Wu, J.J. Rade, T.J. Bivalacqua, H.C. Champion, Neurohumoral features

of myocardial stunning due to sudden emotional stress, N Engl J Med. 352 (2005) 539–548.

[38] A. Fazlollahi, M. Zahmatyar, M. Noori, S.A. Nejadghaderi, M.J.M. Sullman, R. Shekarriz□Foumani, A. Kolahi, K. Singh, S. Safiri, Cardiac complications following mRNA COVID□19 vaccines: A systematic review of case reports and case series, Rev Med Virol. (2021) e2318.

[39] W. Elikowski, M. Małek-Elikowska, M. Lisiecka, Z. Trypuć, I. Mozer-Lisewska, Takotsubo cardiomyopathy triggered by influenza B, Pol Merkur Lek. 45 (2018) 67–70.

[40] E. Nyman, E. Mattsson, P. Tornvall, Trigger factors in takotsubo syndrome–a systematic review of case reports, Eur J Intern Med. 63 (2019) 62–68.

[41] J.-R. Ghadri, I.S. Wittstein, A. Prasad, S. Sharkey, K. Dote, Y.J. Akashi, V.L. Cammann, F. Crea, L. Galiuto, W. Desmet, International expert consensus document on Takotsubo syndrome (part I): clinical characteristics, diagnostic criteria, and pathophysiology, Eur Heart J. 39 (2018) 2032–2046.

[42] J.-R. Ghadri, I.S. Wittstein, A. Prasad, S. Sharkey, K. Dote, Y.J. Akashi, V.L. Cammann, F. Crea, L. Galiuto, W. Desmet, International expert consensus document on Takotsubo syndrome (part II): diagnostic workup, outcome, and management, Eur Heart J. 39 (2018) 2047–2062.

[43] A. Riad, A. Pokorná, M. Mekhemar, J. Conrad, J. Klugarová, M. Koščík, M. Klugar, S. Attia, Safety of ChAdOx1 nCoV-19 vaccine: independent evidence from two EU states, Vaccines. 9 (2021) 673.

[44] M.A. Shabbir, F. Mehak, Z.M. Khan, W. Ahmed, S.M. Abrar-ul-Haq, M.R. Khan, Z.F. Bhat, R.M. Aadil, Delving the role of nutritional psychiatry to mitigate the COVID-19 pandemic induced stress, anxiety and depression, Trends Food Sci Technol. (2022).

[45] R.M. Kaplan, A. Milstein, Influence of a COVID-19 vaccine's effectiveness and safety profile on vaccination acceptance, Proc Natl Acad Sci. 118 (2021).

[46] G. Bogdanov, I. Bogdanov, J. Kazandjieva, N. Tsankov, Cutaneous adverse effects of the available COVID-19 vaccines, Clin Dermatol. 39 (2021) 523–531.

[47] K. Murugiah, Y. Wang, N.R. Desai, E.S. Spatz, S. V Nuti, R.P. Dreyer, H.M. Krumholz, Trends in short-and long-term outcomes for takotsubo cardiomyopathy among medicare fee-for-service beneficiaries, 2007 to 2012, JACC Hear Fail. 4 (2016) 197–205.

[48] S.K.S. Tejtel, F.M. Munoz, I. Al-Ammouri, F. Savorgnan, R.K. Guggilla, N. Khuri-Bulos, L. Phillips, R.J.M. Engler, Myocarditis and pericarditis: case definition and guidelines for data collection, analysis, and presentation of immunization safety data, Vaccine. (2022).

[49] A. Đenić, Similarities and differences of cardiovascular complications of COVID-19 infection and COVID-19 vaccination, Med Glas Spec Boln Za Boles Štitaste Žlezde i Boles Metab. 27 (2022) 69–89.

[50] H. Medina de Chazal, M.G. Del Buono, L. Keyser-Marcus, L. Ma, F.G. Moeller, D. Berrocal, A. Abbate, Stress cardiomyopathy diagnosis and treatment: JACC state-of-the-art review, J Am Coll Cardiol. 72 (2018) 1955–1971.

Fig 1: PRISMA flow diagram.

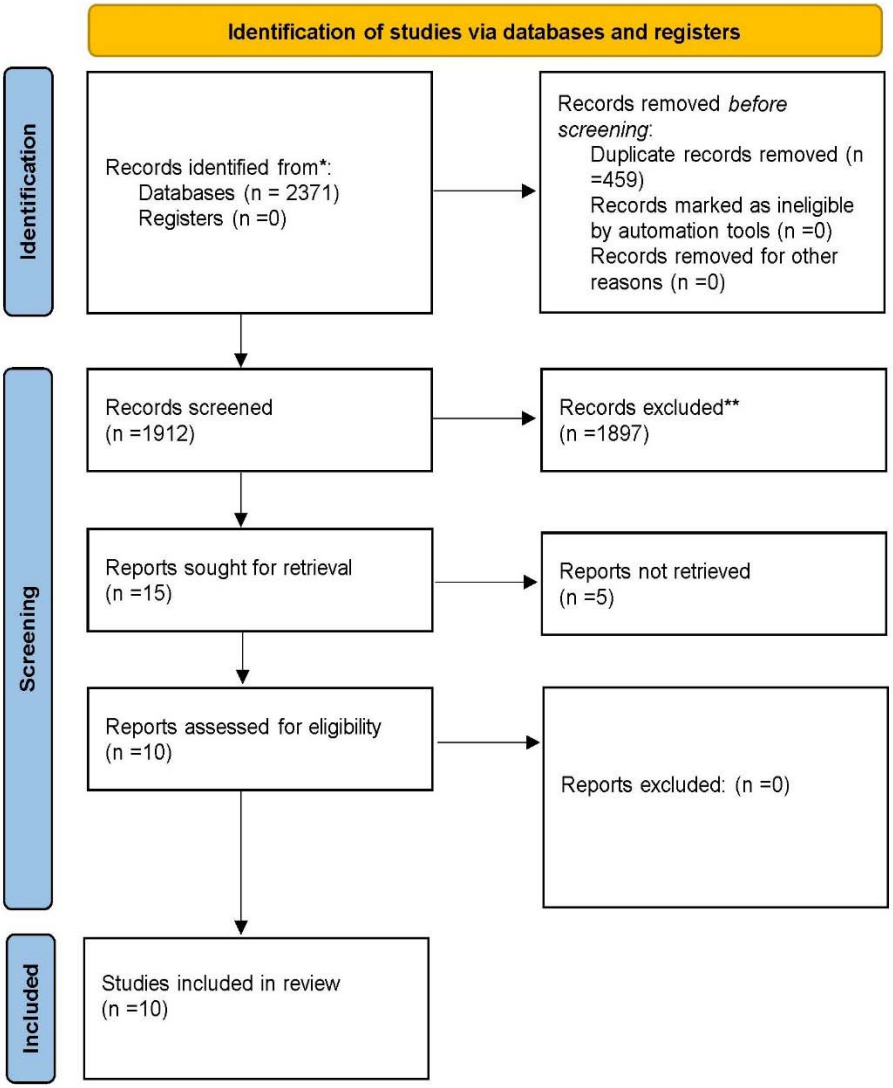

Fig 2: Shows the pathophysiology of stress cardiomyopathy [50].

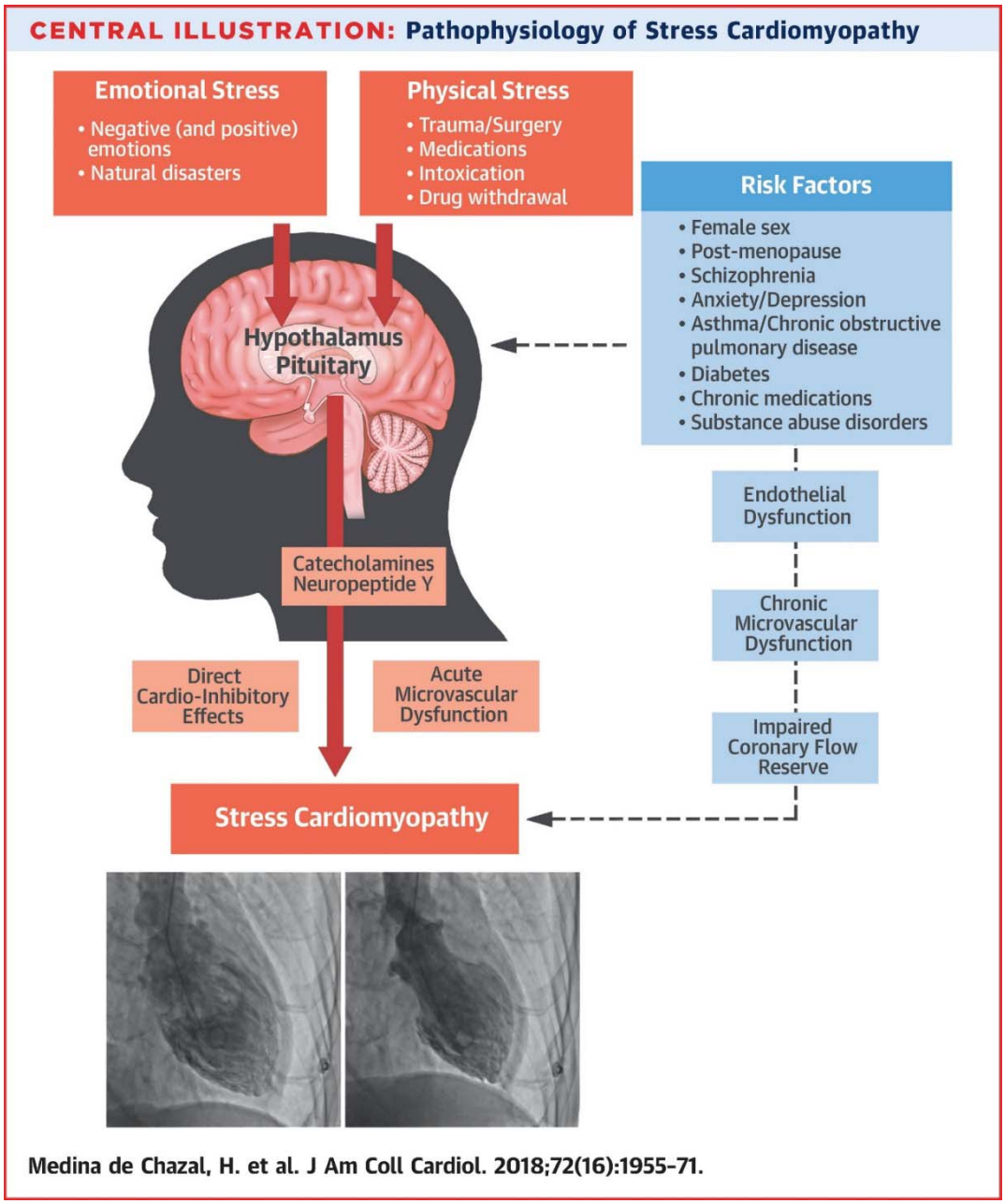

Fig 3: Diagnostic algorithm of takotsubo syndrome.

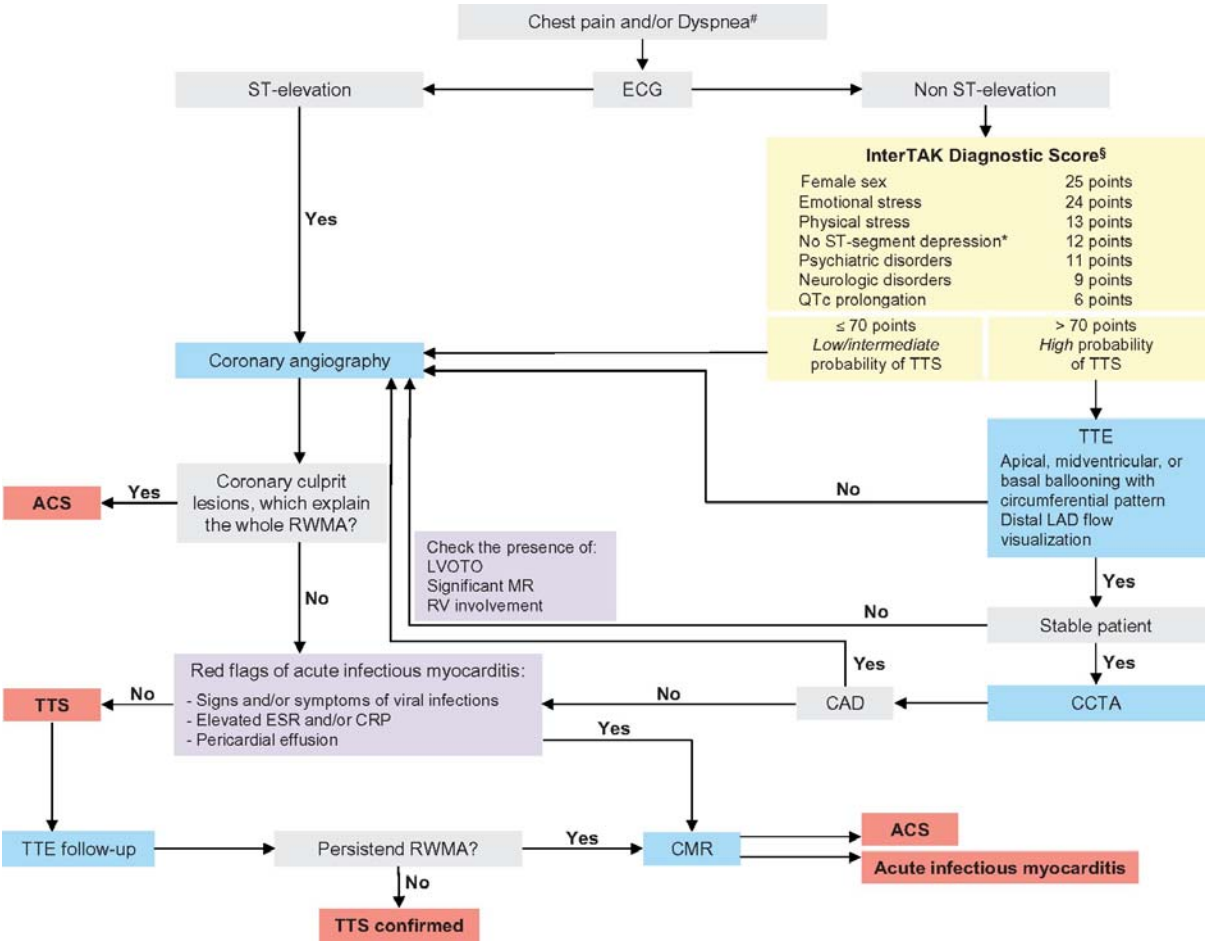

Source: Ghadri et al [42]

Abbreviations: ACS, acute coronary syndrome; CAD, coronary artery disease; CCTA, coronary computed tomography angiography; CMR, cardiac magnetic resonance; CRP, c-reactive protein; ECG, electrocardiogram; ESR, erythrocyte sedimentation rate; InterTAK, International Takotsubo Registry; LAD, left anterior descending coronary artery; LVOTO, left ventricular outflow tract obstruction; MR, mitral regurgitation; QTc, QT-time corrected for heart rate; RV, right ventricle; RWMA, regional wall motion abnormality; TTE, transthoracic echocardiography; TTS, takotsubo syndrome.

Table 1: Characteristics and outcomes of patients with takotsubo cardiomyopathy related to COVID-19 vaccine.

Author/Year of publication	Berto et al 2021 [15]	Jani et al 2021 [16]	Reiko Toida et al 2021 [17]	Caitlin Stewart et al 2021 [1]	Colleen Fearon et al 2021 [18]	Hiroki Yamaura et alt 2022 [19]	Phillip Crane et al 2021 [20]	Mahesh K. Vidula et al 2021 [21]	Tedeschi, et al 2022 [22]	Ricci et al 2022 [23]
Country	Switzerland	United States	Japan	United Kingdom	United States	Japan	Australia	United States	Italy	Italy
Age/years	63	65	80	50	73	30	72	60	71	54
Gender	Female	Female	Female	Female	Female	Female	Male	Female	Female	Female
Type of vaccine	mRNA-1273	mRNA-1273	BNT162b2	ChadOX1 nCOV-19	mRNA-1273	BNT162b2	ChadOX1 nCOV-19	BNT162b2	BNT162b2	mRNA-1273
Dose of vaccine	1st	1st	1st	2nd	NA	2nd	1st	2nd	1st	2nd
Days to symptom onset	1	1	1	7	1	2	4	4	5 hours	Few hours
Symptoms	dyspnoea and fever.	Chest pain, myalgia, nausea, headache	General fatigue, loss of appetite	Chest pain	chest pain, shortness of breath, fatigue, nausea	chest pain and cold sweat	Chest pain, fatigue and myalgias, fever	Chest pain	chest pain and shortness of breath	palpitations, asthenia, and intermittent chest tightness
Troponin level	Elevated	Elevated	Elevated	Elevated	Elevated	Elevated	Elevated	Elevated	Elevated	Elevated
LVEF <50% or LVEF >50%	LVEF <50%	LVEF <50%	LVEF <50%	LVEF <50%	LVEF >50%	LVEF <50%	LVEF <50%	LVEF <50%	LVEF <50%	LVEF <50%
Electrocardiogram (ECG)	Abnormal	Abnormal	Abnormal	Abnormal	Abnormal	Abnormal	Abnormal	Abnormal	Abnormal	Abnormal
Length of hospital stay (days)	NA	NA	13	5	8	15	10	NA	NA	NA
Treatment	NA	Aspirin, atorvastatin, lisinopril, metoprolol succinate	Oxygen, IV fluid	Dual antiplatelet therapy	metoprolol succinate, losartan	The patient was managed without medical therapies	patient received appropriate introduction and titration of therapy	metoprolol succinate and lisinopril.	NA	NA
Outcome	Discharged	Discharged	Discharged	Discharged	Discharged	Discharged	Discharged	Discharged	Discharged	Discharged

Table 2: Summary of pooled data from included published research papers have been reported in the literature (n = 10)

Variables	**Results**
Age (Mean ± SD)	61.8 ± 13.68 years
Gender (n) %	Male – 1 (10%)
	Female – 9 (90%)
Type of COVID-19 vaccine (n) %	Pfizer-BioNTech (BNT162b2) – 4 (40%)
	Moderna COVID-19 Vaccine (mRNA-1273) - 4 (40%)
	Oxford, AstraZeneca COVID-19 vaccine ChAdOx1 nCoV-19 – 2 (20%)
Dose (n) %	First dose – 5 (50%)
	Second dose – 4 (40%)
	None reported 1 (10%)
Days to symptom onset (Mean ± SD)	2.62 ± 2.19 days
Troponin level (n) %	Elevated – 10 (100%)
	Not elevated – 0 (0%)
Left ventricular ejection fraction LVEF (n) %	LVEF >50% - 9 (90%)
	LVEF <50% - 1 (10%)
Electrocardiogram (ECG) (n) %	Abnormal – 10 (100%)
	Normal – 0 (0%)
Length of hospital stay (days) (Mean ± SD)	10.20 ± 3.96 days in 5 patients
	Unknown in 5 patients
Outcome	Recovered – 10 (100%)

Table 3: International Takotsubo Diagnostic Criteria (InterTAK Diagnostic Criteria).

1. Patients show transient[a] left ventricular dysfunction (hypokinesia, akinesia, or dyskinesia) presenting as apical ballooning or midventricular, basal, or focal wall motion abnormalities. Right ventricular involvement can be present. Besides these regional wall motion patterns, transitions between all types can exist. The regional wall motion abnormality usually extends beyond a single epicardial vascular distribution; however, rare cases can exist where the regional wall motion abnormality is present in the subtended myocardial territory of a single coronary artery (focal TTS).[b]
2. An emotional, physical, or combined trigger can precede the takotsubo syndrome event, but this is not obligatory.
3. Neurologic disorders (e.g. subarachnoid haemorrhage, stroke/transient ischaemic attack, or seizures) as well as pheochromocytoma may serve as triggers for takotsubo syndrome.
4. New ECG abnormalities are present (ST-segment elevation, ST-segment depression, T-wave inversion, and QTc prolongation); however, rare cases exist without any ECG changes.
5. Levels of cardiac biomarkers (troponin and creatine kinase) are moderately elevated in most cases; significant elevation of brain natriuretic peptide is common.
6. Significant coronary artery disease is not a contradiction in takotsubo syndrome.
7. Patients have no evidence of infectious myocarditis.[b]
8. Postmenopausal women are predominantly affected.

Source: Ghadri et al [41].

[a]Wall motion abnormality may remain for a prolonged period of time or documentation of recovery may not be possible. For example, death before evidence of recovery is captured.

[b]Cardiac magnetic resonance imaging is recommended to exclude infectious myocarditis and diagnosis confirmation of takotsubo syndrome.