Tongue Coating in COVID-19 Patients: A Case-Control Study

Zhi Chun Wang* [1], Xi Hong Cai* [2], Jeremy Chan[1], Yi Yi Chan[1], Xiaotong Chen[3], Ching Wan Cheng[1], Donghui Huang[# 4], Luqi Huang[# 5], Bei-ni Lao[6,7], Xu-sheng Liu[7], Aiping Lu[1], Wenliang Lv[8], Huixian Wang[4], Helen Zhang[9], Xuebin Zhang[1], Shi Ping Zhang[# 1]

1. Hong Kong Baptist University, Hong Kong, China.
2. The Third Affiliated Hospital of Guangzhou University of Chinese Medicine, Guangdong, China.
3. The University of Hong Kong, Hong Kong, China.
4. Guangdong Provincial Hospital of traditional Chinese Medicine, Zhuhai, Guangdong, China.
5. China Academy of Chinese Medical Sciences, Beijing, China.
6. Second Clinical Medical College of Guangzhou University of Chinese Medicine, Guangzhou, China
7. Guangdong Provincial Hospital of Traditional Chinese Medicine, Guangzhou, China
8. China Academy of Chinese Medical Sciences, Guang'anmen Hospital, Beijing, China.
9. Hong Kong Northern District Hospital, Hong Kong, China.

*These authors contributed equally to this article.

[#]Correspondinng authors

Abstract

It has been suggested that COVID-19 patients have distinct tongue features, which may help to monitor the development of their condition. To determine if there was any specific tongue coating feature in COVID-19, this study investigated the difference in tongue coating between COVID-19 subjects and subjects with other acute inflammatory diseases characterized by fever. Tongue images taken with smartphones from three age-matched groups, namely, COVID group (n=92), non-COVID febrile group (n=92), and normal control group (n=92), were analyzed by two blinded raters according to a tongue coating scoring scheme, which assessed the levels of thick fur, slimy or greasy fur, discolored fur and composite index of tongue coating. Compared with control, significant increases in all coating indexes were found in the COVID group ($P<0.001$), as well as in the non-COVID febrile group ($P<0.001$). However, no difference was observed between COVID and non-COVID febrile groups for all coating indexes measured. In COVID-19 subjects, their scores of coating indexes had weak but significant correlations with certain inflammatory biomarkers, including WBC and neutrophil - lymphocyte ratio. It is concluded that COVID-19 subjects have pathological tongue coating patterns that are associated with inflammatory responses, and these coating patterns can help to indicate the direction of disease development.

Keywords

COVID-19, febrile disease, tongue diagnosis, inflammatory biomarkers, tongue coating index

Introduction

COVID-19 is caused by infection with the severe acute respiratory syndrome coronavirus 2 (SARS-CoV-2) virus strain [1]. As an acute febrile illness, COVID-19 has led to severe health consequence worldwide. According to the World Health Organization, as of Febuary 2022, over 426 million cases have been confirmed, with more than 5.9 million confirmed deaths attributed to COVID-19, making it one of the deadliest pandemics in history [2]. It is axiomatic that symptom detection and monitoring are important in the fight against the disease.

One of the commonly seen symptoms of COVID-19 is the loss of taste sensation and a change in tongue appearance. An autopsy study with matched nasopharyngeal and saliva samples showed distinct virus shedding dynamics, and saliva viral load was associated with COVID-19 symptoms, including loss of taste [3]. It has been proposed that SARS-CoV-2 virus attacks the mucosa of oral cavity by targeting ACE2 receptors, which are highly enriched in epithelial cells of the tongue [4]. Early report from China suggested that certain specific tongue patterns such as tongue discoloration and pathological tongue coating were found in COVID-19 subjects [5-8]. A Spanish study of 666 COVID-19 patients found that half of the victims displayed symptoms of the tongue, including transient lingual papillitis, glossitis with lateral indentations, glossitis with patchy depapillation, burning sensation and taste disturbances [9]. It has been proposed that a specific type of tongue symptom, called “COVID tongue”, should be included into the list of common symptoms of COVID-19 [10].

However, the existence of COVID tongue has been questioned, with the argument that the changes of tongue appearance might be an anatomical variation of normality, rather than pathological [11]. Moreover, age is an important factor in tongue appearance [5]. However, in previous studies of COVID tongue [7-9], age matching has not been performed, exposing the results to bias.

Tongue coating changes had been proposed as a convenient sign for early detection of COVID-19 [8]. In our previous study, we evaluated the reliability of tongue diagnosis in traditional Chinese medicine (TCM) using images from smartphones, and found that the majority of tongue coating features, corresponding to different types of tongue fur in TCM, could be reliably represented in smartphone tongue images [12]. In view of the highly contagious nature of COVID-19, the possibility of using self-recorded tongue images obtained by smartphone to aid symptom detection and monitoring has practical appeals. Therefore, we carried out the present study with age matching to evaluate the differences in tongue coating features between COVID, non-COVID febrile and normal control subjects, based on tongue images captured with smartphones. The hypotheses to be tested was that there were significant differences in tongue coating features between COVID and non-COVID febrile subjects, and between COVID and normal subjects. Since the studied conditions involved inflammation, we also examined the correlations between tongue coating changes and inflammatory biomarkers.

Methods

Data collection

This study had obtained ethical approval from the relevant IRBs of institutions of contributing authors. Informed consent was obtained from healthy participants and non-COVID febrile subjects, but was waived for COVID subjects due to the retrospective nature of the study and the exceptional circumstances. A total of 478 images from COVID subjects, including their partial anonymous medical records, were provided by rapid response medical teams working in Wuhan during Feb-March 2020. After initial screening of their images and corresponding medical records, 141 patients were retained for further analysis. All the images from COVID patients were taken by smartphones with unknown methods. The included subjects had records of

age, gender, diagnosis of COVID-19, and some had laboratory tests and outcomes of hospital stay, i.e., returning to home care or being transferred to another hospital for more intensive care.

For non-COVID febrile patients and control subjects, their tongue images were collected with a standardized smartphone photographic protocol using smartphones of common brand names, including iPhone, HUAWEI, and Samsung, as described in our previous paper [12]. The non-COVID febrile group was made-up of subjects from the Guangdong Province in the Third Affiliated Hospital of Guangzhou University of Chinese Medicine and the Guangdong Chinese Medicine Hospital Zhuhai Branch. These subjects had acute fever for various reasons but were tested negative for COVID-19. The normal control group consisted of subjects without any acute illness. To control for local diet, 51 subjects in the normal control group were derived from employees of a Wuhan catering company (Wuhan Xiao Pan Jing Hotel Management Co. Ltd), who underwent regular COVID-19 testing during the data collection period because of the nature of their job. The remaining control subjects (n=41), whose data were retrieved randomly from a tongue image database of our previous studies [12], were from Guangdong and Hong Kong.

As shown in Figure 1, the 92 subjects in COVID group were matched by subjects from the two other groups based on age (See Figure 1). There is no significant difference in gender composition between the three groups in the marched dataset (see Table 1).

Figure 2. Flow-chart showing the process of subject matching for comparison of tongue coating

Figure 2. Smartphone tongue image from a COVID-19 subject (left) and diagram (right) showing an example of the subdivision and scoring schemes for calculation of tongue coating indexes. TCI: tongue coating index; SBI: slimy biofilm index; TDI: tongue discoloration index; and CTCI: composite tongue coating index.

Table 3. Data source and Baseline Information

Group	COVID-19	Non-COVID Febrile	Control

Data Source	Wuhan	Guangdong	Wuhan	Guangdong, Hong Kong
Recorded Diagnosis	Mild COVID-19 (N=6) Moderate COVID-19 (N=23) Severe COVID-19 (N=11) Unclassified COVID-19 (N=203)	Upper respiratory tract infection (N=15) Acute urethritis (N=4) Acute gastroenteritis (N=4) Lupus erythematosus (N=2) Lower respiratory tract infection (N=2) Chickenpox (N=1) Common cold (N=128)	N/A	
Imaging Method	Unknown method	Standardized photographic protocol	Standardized photographic protocol	
Initial Dataset	243	157	92	508
Screened Dataset	141	151	51	497
Matched Dataset	92	92	51	41
Average Age after Matching	53.1±1.6 (N=92) #	49.8±1.9 (N=92) #	49.8±1.9 (N=92) #	

Data are presented as Mean ± SEM for age. # $P>0.05$ (Student's t test) when comparing difference between groups.

Scoring for tongue coating indexes

Firstly, the color temperature of smartphone tongue images was adjusted using white balancing function of a commercial software (Adobe Photoshop CC 2019) to reduce the influence of different light sources. Then the method described by Winkel etc. [13] was used for scoring tongue coating indexes. Briefly, the tongue surface was divided into six areas (see Figure 2), and raters assigned three categories of scores to each area, quantifying the thickness of tongue coating (tongue coating index; TCI), the presence of slimy or greasy tongue fur (slimy biofilm index; SBI) and the presence of discoloration on tongue fur (tongue discoloration index; TDI). The scores from the six areas in each category were then added up respectively to become an index score for the tongue image. TCI as assessed by zooming in the photograph to observe individual papillae. SBI examined the presence of slimy biofilm, which was a white to whitish-yellow creamy confluent plaques (milk curd or cottage cheese-like). TDI indicated a change in color of tongue fur, which in normal subjects should be whitish or pink. The details of the scoring method are shown in Table 2. A composite tongue coating index (CTCI) was calculated by the sum of the three indexes. An example of the application of these indexes is shown in Figure 2.

Table 2. Rating Scheme for Tongue Fur Features at Each Subdivision

Tongue Fur Features	Score	Explanation
Thick Fur	0	Normal thin coating or no coating
	1	Thick coating, papillae of tongue just visible
	2	Very thick coating, papillae of tongue not visible
Slimy Fur	0	Absence of slimy biofilm
	1	Slimy biofilm occupying ≤50% of the area
	2	Slimy biofilm occupying >50% of the area
Fur discoloration	0	Pink color, or whitish color
	1	Other colors occupying ≤50% of the area
	2	Other colors >50% of the area

Because there was no common standard in quantifying COVID tongue coating features, we conducted a pilot study on method agreement using six raters to evaluate a test set of COVID tongue images (n=100). The raters consisted of three Chinese medicine practitioners (CYC, YYC, BNL) and three Chinese medicine students (XTC, QYC, JC), who were blinded to the source and diagnosis of the images. We found that the interrater correlations on coating indexes between two raters ranged from 0.648 - 0.773 and identified two raters (YYC & JC) who had the highest correlation coefficient amongst all the combinations of pair. Since YYC was not available for further image assessment, we trained two student raters (QYC and JC) working together until their scoring of the test set reached a strong agreement (Pearson correlation = 0.762, $P<0.001$). The two raters then used the same method to score the final image sets of the three matched groups, which were mixed together with group status concealed. The average scores of their rating for each image were used for statistical analysis.

Statistical analysis

Data were analyzed with IBM SPSS Statistics (version 26.0) and GraphPad Prism (version 8.0.2). Continuous variables were compared using the Student's t test or the Mann-Whitney U test, depending on

the distribution of the data. Correlation coefficient was calculated using Pearson correlation coefficient. Results with $P < 0.05$ are considered to be statistically significant.

Results

Comparison of tongue coating indexes between groups

Three age-matched groups of 92 subjects each were included in the comparative analysis (Table 1), with older age subjects in the COVID-19 group being excluded due to the lack of matching subjects. As seen in Table 3, the median scores of TCI, SBI, TDI and CITC of the COVID group and of the non-COVID febrile group are significantly higher than those of the control group (P<0.001). However, there was no significant difference in the median scores of TCI, SBI, TDI and CITC between the COVID group and the non-COVID febrile group.

Table 3. Comparison of Tongue Coating Indexes in Different Groups

Index	COVID (N=92)	Non-COVID Febrile (N=92)	Control (N=92)	*P* between COVID & Non-COVID Febrile	*P* between COVID & Control	*P* between Non-COVID Febrile & Control
TCI	4.0 (2.0-6.0)	4.3 (1.1-7.0)	1.0 (0.0-2.0)	0.484	<0.001***	<0.001***
SBI	2.0 (0.0-4.0)	2.5 (0.6-5.0)	0.0 (0.0-1.0)	0.144	<0.001***	<0.001***
TDI	1.5 (0.0-4.0)	2.0 (0.1-5.0)	0.0 (0.0-1.0)	0.197	<0.001***	<0.001***
CTCI	8.5 (3.0-13.0)	9.5 (3.0-15.0)	2.0 (0.0-5.8)	0.253	<0.001***	<0.001***

Data are presented as Median (IQR). *P* values were calculated by Mann-Whitney U test. **P*<0.05, ***P*<0.01, ****P*<0.001.

Comparison between tongue coating indexes with inflammatory biomarkers

We performed subgroup analysis in COVID-19 and non-COVID febrile patients of their tongue coating indexes and inflammatory biomarkers including C-reactive protein (CRP), white blood cell count (WBC), lymphocytes, hemoglobin, blood platelet count (BPC), neutrophils, neutrophils lymphocytes ratio (NLR) and platelet lymphocytes ratio (PLR). For COVID-19 patients, weak but significant correlations were observed between tongue coating indexes and WBC, neutrophils and NLR. For non-COVID febrile patients,

only weak correlations were found between CRP and SBI, TDI and CTCI, with no correlation found between other biomarkers and tongue coating idexes (see Table 4).

Table 4. Correlation Coefficients between Tongue Coating Indexes and Biomarkers

Indexes	COVID-19 patients					Non-COVID Febrile patients				
	N	TCI	SBI	TDI	CTCI	N	TCI	SBI	TDI	CTCI
CRP	85	-0.021	0.073	0.171	0.078	109	0.130	0.194*	0.224*	0.209*
WBC	89	0.258*	0.301**	0.349**	0.332**	109	-0.055	0.033	0.044	0.005
Lymphocytes	89	-0.063	-0.107	-0.124	-0.107	109	0.013	-0.024	-0.04	-0.018
Hemoglobin	89	-0.118	-0.056	-0.103	-0.103	109	-0.033	-0.168	-0.174	-0.139
BPC	89	-0.194	-0.029	-0.039	-0.099	109	0.001	-0.01	0.016	0.003
Neutrophils	89	0.266*	0.308**	0.347**	0.337**	109	-0.062	0.045	0.059	0.012
NLR	89	0.287**	0.258*	0.294**	0.308**	109	-0.087	0.031	0.062	-0.002
PLR	89	-0.005	0.059	0.085	0.05	109	-0.114	-0.037	-0.016	-0.067

CRP: C-reactive protein, WBC: white blood cell, BPC: blood platelet count, NLR: neutrophil-lymphocyte ratio, PLR: platelet-lymphocyte ratio; * Correlation is significant at the 0.05 level (2-tailed), ** Correlation is significant at the 0.01 level (2-tailed).

Time course analysis of tongue coating indexes in the COVID group

We also conducted subgroup analysis for COVID patients based on whether they were discharged for home care upon recovery or transferred to another hospital for more intensive care(Figure 3). For each patient, we calculated the initial scores from the first tongue image taken during hospitalization and the last tongue image taken at the end of the hospital stay. As shown in Table 5, initial scores and final scores were compared for patients in the discharged group and the transferred group. For the discharged group, TCI decreased towards the end, with the other indexes showing no significant change. In contrast, for the transferred group, all indexes except the TDI increased before the patient was transferred for more intensive care (Table 5), indicating that tongue coating indexes change according to the direction of disease development.

Figure 3. A. Typical examples of tongue images from COVID-19 patients in the Discharged Group and in the Transferred Group. B. Histograms showing the same time sequence of tongue coating indexes of subjects from A. X axis indicates the date of hospital admission.

Table 5. Coating indexes at the beginning and towards the end of hospitalization

Indexes		Discharged group (N=19)		Transferred group (N=13)	
		Mean ± SEM	*P*	Mean ± SEM	*P*
TCI	Initial score	8.26 ± 0.64	0.026*	6.92 ± 0.92	0.005**
	Final score	6.42 ± 0.86		9.31 ± 0.79	
SBI	Initial score	6.37 ± 0.52	0.236	5.31 ± 0.87	0.022*
	Final score	5.21 ± 0.78		6.69 ± 0.79	
TDI	Initial score	4.57 ± 0.79	0.704	1.92 ± 0.69	0.225
	Final score	4.05 ± 0.98		3.31 ± 1.03	
CTCI	Initial score	19.21 ± 1.51	0.167	14.15 ± 2.04	0.007**
	Final score	15.68 ± 1.98		19.31 ± 1.55	

Data are presented as Mean ± SEM. *$P<0.05$, **$P<0.01$ (Student's t test)

Discussion

Using smartphone images of the tongue, this study quantified changes in serval pathological features of tongue coating associated with COVID-19 infection using a comparative approach, controlling for common confounding factors such as acute inflammation, age and diet. We found a significant increase in the appearance of thick, slimy and discolored tongue coating in COVID-19 patients, compared to normal subjects. However, we found no significant difference in all the tongue coating features studied between the COVID and the non-COVID febrile groups. In the longitudinal analysis of COVID-19 patients, we found a reduction in the thickness of tongue coating when the patient recovered from the disease, and increases in coating thickness and slimy biofilm upon further progression of the disease.

Normal tongue coating is a whitish layer, which consists of desquamated epithelial cells, blood cells, metabolites and bacteria adherent to the dorsum of the tongue [14,15]. Increase in coating thickness has been attributed to epithelial cell hyperproliferation with reduced apoptosis and differentiation [16]. Hypothetically, SARS-CoV-2 virus may cause changes in the expression levels of the genes coding related to apoptosis of epithelial cells, causing the accumulation of oral epithelial cells and lead to an increase in coating thickness. In this regard, it is interesting to note that in patients with chronic hepatitis, the level of human epithelial growth factor (EGF) in both saliva and the blood were significantly higher in the thick coating group, corresponding to higher viral load in the liver tissue, compared with the normal coating group

[17]. In patients with acute cerebral infarction, thick coating is associated with higher neutrophil count and elevated level of fibrinogen in the blood, compared to patients with normal coating [18]. These studies suggest that the thickness of tongue coating could be associated with viral load and/or inflammation. Our findings that compared with normal subjects, COVID-19 patients have significantly thicker coating, which is correlated with biomarkers of inflammation, and that there is a correlation between coating thickness and disease recovery, support the role of tongue coating thickness in indicating the level of inflammatory response in COVID-19.

The formation of slimy biofilm, corresponding to greasy tongue fur, is a complex phenomenon. Both mucins secreted by salivary glands and epithelial cells, and polysaccharides synthesized by certain microbial cells, may play significant roles in the formation of slimy biofilm [19, 20]. Over production of mucin is a defense response to external stimuli, likely to happen when the oral mucosa is attached by virus directly [4]. However, previous report [5] that COVID-19 patients had more incidents of greasy tongue coating was not substantiated by the current study using non-COVID febrile subjects as control. On the other hand, greasy tongue fur had been reported to be associated with elevated blood level of fibrinogen in stroke patients [18], and with enhanced activity of glossal epithelial cells and increased vascular permeability in rats [21]. The present study found that there was a correlation between the levels of WBC and neutrophils and the level of SBI in COVID-19 patients. In contrast, in non-COVID febrile patients, SBI was correlated with the level of CRP. The reason for such difference in correlation is unclear. It is important to note that oral candidiasis, often caused by compromised immune function, is closely associated with the presence of slimy biofilm on the tongue [22]. Also worth noting are the possibilities that the two groups of patients might be at different stage of their infection and likely to have a different profile in their immune reaction, and that the slimy biofilm is susceptible to oral hygiene and tongue brushing [23]. The myriad of possible factors influencing the appearance of slimy biofilm call for cautions in the interpretation of current results regarding SBI, and

further studies are needed to better understand the relationship between COVID-19 and slimy biofilm formation.

Tongue fur discoloration may be caused by several factors. Yellow tongue coating was found to be associated with tongue coating microbiome [24], and it is also susceptible to oral hygiene and smoking [23,25]. Compared with normal subjects, tongue epithelial apoptosis was significantly reduced, and the total number of bacteria was increased in subjects with yellow coating [16]. In patients with acute cerebral infarction, thick and yellow tongue coating was associated with higher neutrophil count and elevated level of fibrinogen [18]. In the current findings, TDI had the highest correlation coefficients with the inflammatory biomarkers WBC and neutrophils, compared with other coating indexes of COVID-19 patients. Therefore, tongue fur discoloration may be indicative for the level of inflammatory response in COVID-19 patients.

Taken together, notwithstanding the complex mechanisms associated with various pathological coating features, a clear picture emerging from the current study is the association between pathological tongue coating and inflammatory responses in COVID-19, as indicated in the correlation analysis between coating indexes and inflammatory biomarkers. Although the correlation is weak in general, they are consistent across several inflammatory biomarkers and pathological coating features. The reason for a different pattern of correlation between pathological tongue coating and inflammatory biomarkers seen in the non-COVID febrile group may be due to different nature of the associated inflammatory and immune responses [26].

To our knowledge, this is the first COVID tongue study that has employed a quantitative method and has controlled for important confounding factors influencing tongue coating [5, 27, 28]. Our findings are consistent with the results of many other previous studies, which have showed that thick, slimy and yellow

tongue coating are characteristics of febrile subjects [5, 29]. Also in agreement with previous reports are the findings that tongue thickness coating reduces as patients recovering from COVID-19 [5, 30]. Previous studies suggested that slimy biofilm was a significant characteristic of patients with COVID-19 [5, 30]. While we could not find any difference in the level of slimy biofilm between COVID and non-COVID febrile subjects, we did find that COVID patients with worsening condition showed increased levels of thick and slimy coating, compared with their own tongue coating at the beginning of COVID infection. Furthermore, we have demonstrated a specific correlation pattern between pathological tongue coating and inflammatory biomarkers in COVID-19. These findings are of practical interest, suggesting that tongue coating changes could be used as one of the indicators for the direction of disease development in COVID-19 patients. Specifically, reduction in coating thickness may indicate recovery and persistent increase in coating thickness and/or slimy biofilm coverage may signify deterioration.

There are many strengths of the current study. Firstly, this study controlled for major confounding factors known to influence tongue coating, including acute infection, age and diet. Second, it adopted quantitative methods for tongue coating assessment, allowing for correlation analysis with inflammatory biomarkers. Last but not the least, it went through a lengthy process of evaluating rater consistency and training of assessors, and used blinding for tongue coating assessment to reduce assessor bias. Taken together, the current study is underpinned by vigorous methodological design and its results are expected to have good validity in the real world.

There are a number of limitations in this study that are worth noting. For example, the source of COVID-19 patients are all from Wuhan at a particular time period. Thus, it is not known whether new COVID variants could produce specific tongue coating patterns not seen in the current study. Due to the lack of matching

subjects, we have to exclude many older age COVID-19 patients, resulting in a relatively small sample size. As well, because the medical records of COVID-19 patients are incomplete, it is not possible to control for any comorbid disease in the study population. Therefore, findings from the current study should be interpreted with the above limitation in mind.

In conclusion, COVID-19 patients have pathological tongue coating that is associated with inflammatory responses, and their coating changes may indicate the direction of disease development. Further studies are warranted to explore the application of tongue imaging as an adjunct diagnostic method in monitoring the development of COVID-19.

Acknowledgements

We thank Dr Fan Mingcong and staff of Wuhan Xiao Pan Jing Hotel Management Co. Ltd for contributing tongue images.

Compliance with ethics guidelines

Zhi Chun Wang, Xi Hong Cai, Jeremy Chan, Yi Yi Chan, Xiaotong Chen, Ching Wan Cheng, Donghui Huang, Luqi Huang, Bei-ni Lao, Xu-sheng Liu, Aiping Lu, Wenliang Lv, Huixian Wang, Helen Zhang, Xuebin Zhang, Shi Ping Zhang declare that they have no conflict of interest.

Given the retrospective nature of this study, informed consent was waived in the collection of tongue images from COVID-19 subjects.

The study was approved by the Ethics Committee of Hong Kong Baptist University (REC/19-20/0400), Ethics Committee of The Third Affiliated Hospital of Guangzhou University of Chinese Medicine (AF/SC-07/02.0) and Ethics Committee of Guangdong Provincial Hospital of Chinese Medicine (AF/04-06.1/10.0).

References

1. Hu, Ben; Guo, Hua; Zhou, Peng; Shi, Zheng-Li (6 October 2020). "Characteristics of SARS-CoV-2 and COVID-19". Nature Reviews. Microbiology: 1–14. doi:10.1038/s41579-020-00459-7. ISSN 1740-1526. PMC 7537588. PMID 33024307.
2. WHO Epidemiological update on COVID-19. accessed 7 September 2021. 2021. https://www.who.int/publications/m/item/weekly-epidemiological-update-on-covid-19---7-september-2021
3. Huang, N., Pérez, P., Kato, T. et al. SARS-CoV-2 infection of the oral cavity and saliva. Nat Med 27, 892–903 (2021). https://doi.org/10.1038/s41591-021-01296-8
4. Xu, H., Zhong, L., Deng, J., Peng, J., Dan, H., Zeng, X., Li, T., & Chen, Q. (2020). High expression of ACE2 receptor of 2019-nCoV on the epithelial cells of oral mucosa. International journal of oral science, 12(1), 8. https://doi.org/10.1038/s41368-020-0074-x
5. Pang, W., Zhang, D., Zhang, J., Li, N., Zheng, W., Wang, H. & Pang, B. (2020). Tongue features of patients with coronavirus disease 2019: a retrospective cross-sectional study. Integrative medicine research, 9(3), 100493.
6. Xu, J., & Zhang, Y. (2020). Traditional Chinese medicine treatment of COVID-19. Complementary therapies in clinical practice, 39, 101165.
7. Jin, Y. H., Cai, L., Cheng, Z. S., Cheng, H., Deng, T., Fan, Y. P., ... & Wang, X. H. (2020). A rapid advice guideline for the diagnosis and treatment of 2019 novel coronavirus (2019-nCoV) infected pneumonia (standard version). Military Medical Research, 7(1), 1-23.
8. Liang, K., Huang, X., Chen, H., Qiu, L., Zhuang, Y., Zou, C., ... & Huang, Y. (2020). Tongue diagnosis and treatment in traditional Chinese medicine for severe COVID-19: a case report. Annals of Palliative Medicine, 9(4), 2400-2407.

9. Nuno-Gonzalez, A., Martin-Carrillo, P., Magaletsky, K., Rios, M. M., Mañas, C. H., Almazan, J. A., ... & Pinto, P. H. (2020). Prevalence of mucocutaneous manifestations in 666 patients with COVID-19 in a field hospital in Spain: oral and palmoplantar findings. British journal of dermatology.
10. NBC News 'Covid tongue' may be another coronavirus symptom, British researcher suggests. 2021. https://www.nbcnews.com/health/health-news/covid-tongue-may-be-another-coronavirus-symptom-british-researcher-suggests-n1256078
11. Pérez-Sayáns, M., Ortega, K. L., Braz-Silva, P. H., Carreras-Presas, C. M., & Carrión, A. B. (2021). Can "COVID-19 tongue" be considered a pathognomonic finding in SARS-CoV-2 infection. Oral Diseases. doi: 10.1111/odi.13807.
12. Wang, Z. C., Zhang, S. P., Yuen, P. C., Chan, K. W., Chan, Y. Y., Cheung, C. H., ... & Zhang, X. (2020). Intra-rater and inter-rater reliability of tongue coating diagnosis in traditional chinese medicine using smartphones: Quasi-delphi study. JMIR mHealth and uHealth, 8(7), e16018.
13. Winkel EG, Roldan S, Van Winkelhoff AJ, Herrera D, Sanz M. The clinical effects of a new mouth rinse containing chlorhexidine, cetylpyridinium chloride and zinc-lactate on oral halitosis. A dual-center, double-blind placebo-controlled study. J Clin Periodontol 2003; 30: 300–7.
14. Casemiro LA, Martins CH, de Carvalho TC, Panzeri H, Lavrador MA, Pires-de-Souza Fde C: Effectiveness of a new toothbrush design versus a conventional tongue scraper in improving breath odor and reducing tongue microbiota. J Appl Oral Sci 2008; 16: 271–274.
15. Lundgren T, Mobilia A, Hallstrom H, Egelberg J: Evaluation of tongue coating indices. Oral Dis 2007; 13: 177–180.
16. Wu Z, Li M, Zhang Y, Chen M: Study on relationship between the thickness of tongue fur and the expressions of apoptosis-related genes of the tongue epithelial cells in patients with diseases of the digestive system. J Tradit Chin Med 2007;27:148–152.

17. Liu, X. H., X. Q. Zhou, and Y. Y. Luo. Study of the Correlation between Tongue Coatings of Patients with CHB, the Content of EGF in Saliva and Serum the Apoptosis of Tongue Epithelium, and the Serum Levels of Hepatitis B Virus DNA. Journal of Gannan Medical University 28.6 (2008): 812-817.
18. Gao L, Liu P, Song JX, Liu Q, Xu CM, Huang LY, Wang PP, Zhao HP, Luo YM: Study on the correlation of tongue manifestation with fibrinogen and neutrophil in acute cerebral infarction patients. Chin J Integr Med 2012;18:942–945.
19. Limoli, D. H., Jones, C. J., & Wozniak, D. J. (2015). Bacterial extracellular polysaccharides in biofilm formation and function. Microbiology spectrum, 3(3), 3-3.
20. Frenkel, E. S., & Ribbeck, K. (2015). Salivary mucins protect surfaces from colonization by cariogenic bacteria. Applied and environmental microbiology, 81(1), 332-338.
21. Qi WJ, Zhang MM, Wang H, Wen Y, Wang BE, Zhang SW: Research on the relationship between thick greasy tongue fur formation and vascular endothelial cell permeability with the protein expression of zonula occludens-1. Chin J Integr Med 2011;17:510–516
22. Ramage, G., Vande Walle, K., Wickes, B. L., & López-Ribot, J. L. (2001). Biofilm formation by Candida dubliniensis. Journal of Clinical Microbiology, 39(9), 3234-3240.
23. Lasserre, J. F., Brecx, M. C., & Toma, S. (2018). Oral microbes, biofilms and their role in periodontal and peri-implant diseases. Materials, 11(10), 1802.
24. Jiang, Bai, et al. "Integrating next-generation sequencing and traditional tongue diagnosis to determine tongue coating microbiome." Scientific reports 2.1 (2012): 1-15.
25. Tomooka, K., Saito, I., Furukawa, S., Maruyama, K., Eguchi, E., Iso, H., & Tanigawa, T. (2017). Yellow tongue coating is associated with diabetes mellitus among Japanese non-smoking men and women: the toon health study. Journal of epidemiology, JE20160169.
26. Mishra, Kamla Prasad, Ajay Kumar Singh, and Shashi Bala Singh. "Hyperinflammation and immune response generation in COVID-19." Neuroimmunomodulation (2020): 1-7.

27. Christensen GJ (1998) Why clean your tongue? J. Am. Dent. Assoc. 129 1605–1607

28. Wenlan, L., Rong, L., & Jiaxu, C. (2001). Relationship between the thickness of the tongue coating and cell apoptosis in the patients with acute infection of respiratory tract. JOURNAL-BEIJING UNIVERSITY OF TRADITIONAL CHINESE MEDICINE, 24(2), 24-26.

29. Cui, J., Cui, H., Yang, M., Du, S., Li, J., Li, Y., ... & Li, S. (2019). Tongue coating microbiome as a potential biomarker for gastritis including precancerous cascade. Protein & cell, 10(7), 496-509.

30. Abdul, Muqthadir Siddiqui Mohammed, et al. "Oral Manifestations of Covid-19-Are they the introductory symptoms?." Journal of Advanced Medical and Dental Sciences Research 8.5 (2020): 41-43.

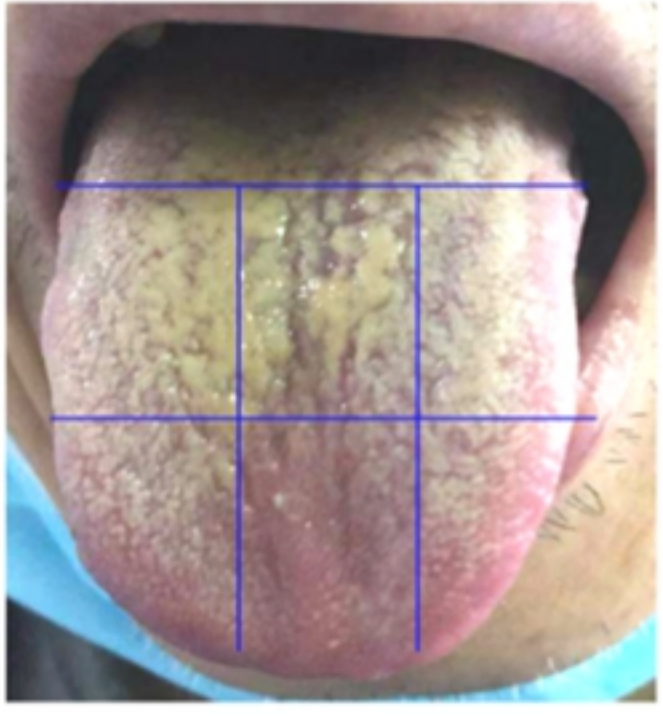

TCI			SBI			TDI		
2	2	1	2	2	2	2	2	2
2	1	1	1	0	1	2	1	2

9 + 8 + 11

CTCI = 28

Figure2

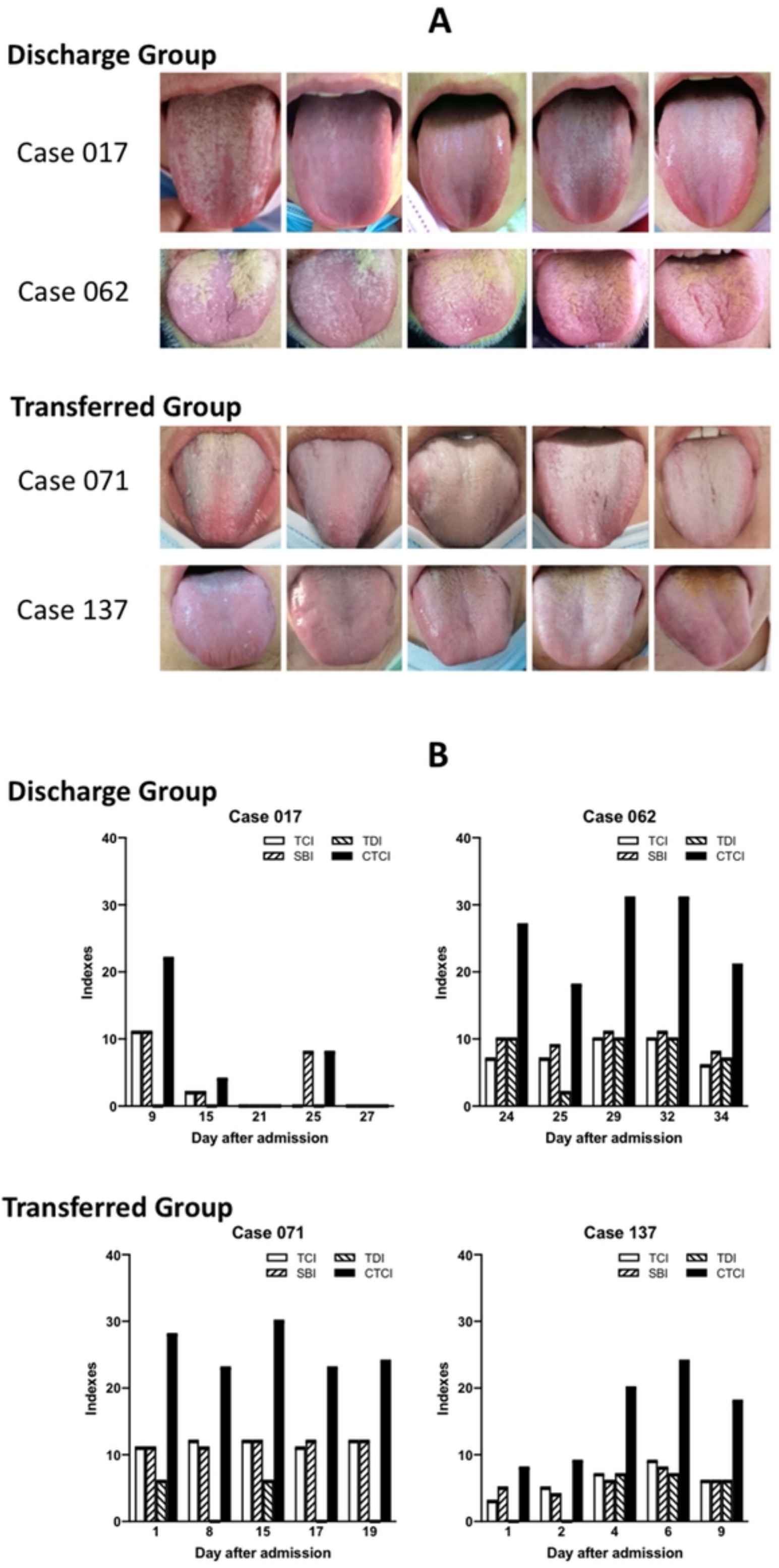
A
Discharge Group
Case 017
Case 062
Transferred Group
Case 071
Case 137
B
Discharge Group
Case 017
Case 062
Transferred Group
Case 071
Case 137
TCI
TDI
SBI
CTCI
Indexes
Day after admission

Figure

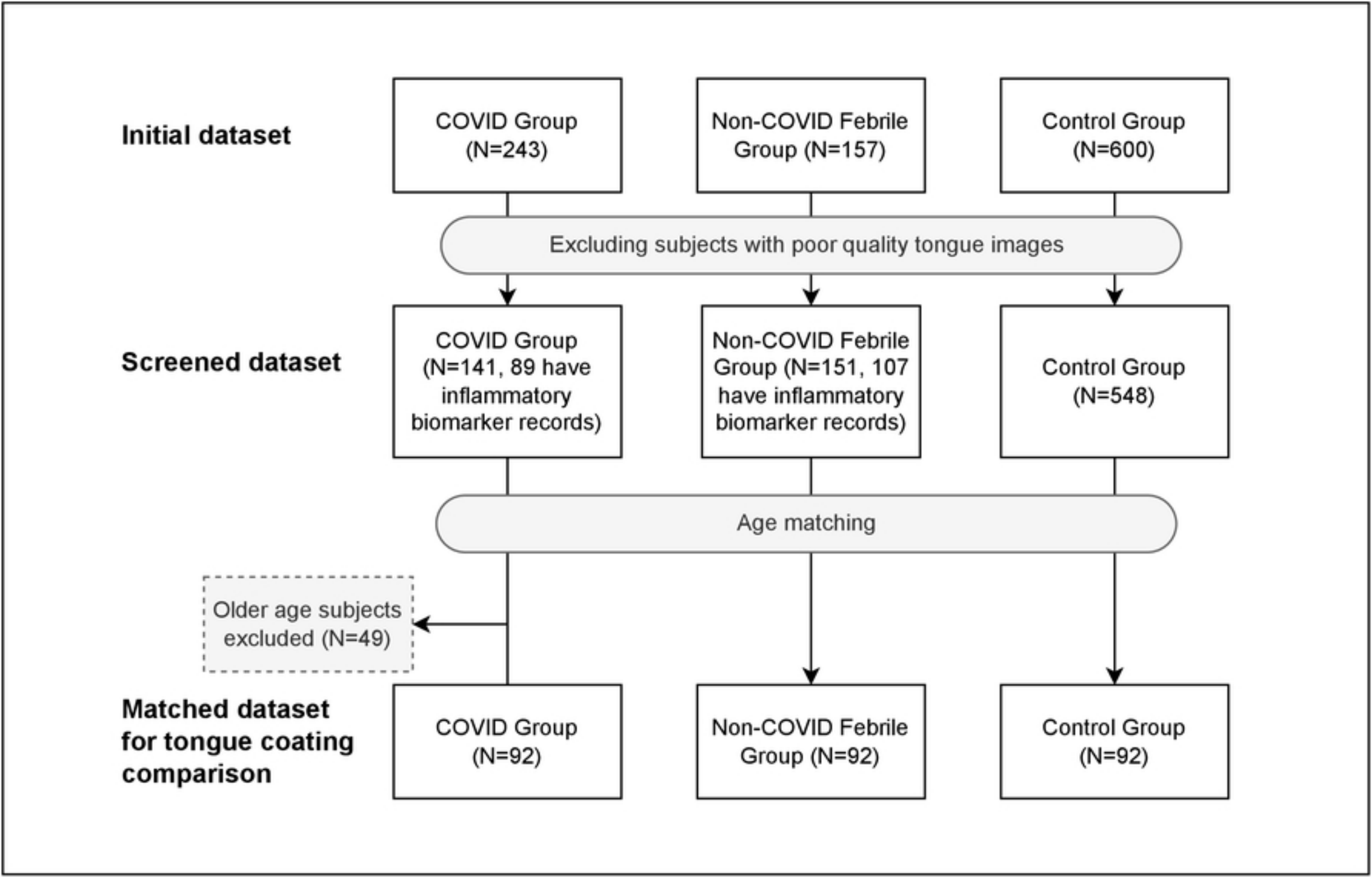
Initial dataset
COVID Group (N=243)
Non-COVID Febrile Group (N=157)
Control Group (N=600)
Excluding subjects with poor quality tongue images
Screened dataset
COVID Group (N=141, 89 have inflammatory biomarker records)
Non-COVID Febrile Group (N=151, 107 have inflammatory biomarker records)
Control Group (N=548)
Age matching
Older age subjects excluded (N=49)
Matched dataset for tongue coating comparison
COVID Group (N=92)
Non-COVID Febrile Group (N=92)
Control Group (N=92)

Figure1