medRxiv preprint doi: https://doi.org/10.1101/2022.01.25.22269823; this version posted January 25, 2022. The copyright holder for this preprint (which was not certified by peer review) is the author/funder, who has granted medRxiv a license to display the preprint in perpetuity. It is made available under a CC-BY-NC-ND 4.0 International license .

Immunogenetics of Gastrointestinal Cancers: A Systematic Review of Inborn Errors of Immunity in Humans

Beishi Zheng[1,2], Howard Chung[1], Chen Bing[1], Siming Sun[1], Benjamin Lebwohl[1], Peter HR. Green[1], Timothy C. Wang[1], Xiao-Fei Kong[1*]

1. Division of Digestive and Liver Disease, Department of Medicine, Columbia University Irving Medical Center, New York, NY, 10032
2. Department of Internal Medicine, Woodhull Medical and Mental Health Center, Brooklyn, NY, 11206

*Corresponding author: Xiao-Fei Kong (xk2137@cumc.columbia.edu)

Address: 622 West 168th St, PH7W, Suite 318, New York, NY, 10032

NOTE: This preprint reports new research that has not been certified by peer review and should not be used to guide clinical practice.

medRxiv preprint doi: https://doi.org/10.1101/2022.01.25.22269823; this version posted January 25, 2022. The copyright holder for this preprint (which was not certified by peer review) is the author/funder, who has granted medRxiv a license to display the preprint in perpetuity. It is made available under a CC-BY-NC-ND 4.0 International license .

Abstract:

Background/Aims: The immune system plays a key role in cancer surveillance and modulation of the tumor microenvironment. Humans with inborn errors of immunity (IEI), or primary immunodeficiencies, may be prone to recurrent mucosal bacterial and viral infections and chronic inflammation, associated with intrinsic or secondary epithelium dysfunction, a potential risk factor for early-onset gastrointestinal (GI) cancer.

Methods: We systematically reviewed all cases with clinical diagnoses of both an IEI and a GI cancer in three databases (MEDLINE, SCOPUS, EMBASE). In total, 76 publications satisfying our inclusion criteria were identified, and data for 149 cases were analyzed.

Results: Of the 149 patients with IEIs, 95 presented with gastric cancer, 13 with small bowel cancer, 35 with colorectal cancer, and six with unspecified cancer or cancer at another site. Gastric and colonic adenocarcinoma was the most common. For both gastric and colorectal cancer, age at onset was significantly earlier in patients with IEIs than in the general population, based on the SEER database. Common variable immune deficiency (CVID) was the most common IEI associated with gastrointestinal cancer. About 12% of patients had molecular genetic diagnoses, the three most frequently implicated genes being *ATM*, *CARMIL2*, *CTLA4*. Impaired humoral immunity and Epstein-Barr virus (EBV) infection were frequently reported as the factors potentially underlying early-onset GI malignancy in patients with IEIs.

Conclusion:

Patients with IEIs should be considered at risk of early-onset GI cancers, and should therefore undergo cancer screening at an earlier age. Surveillance guidance based on stratifications for genetic risk should be revised to take into account the immunogenetic contribution to GI cancers.

medRxiv preprint doi: https://doi.org/10.1101/2022.01.25.22269823; this version posted January 25, 2022. The copyright holder for this preprint (which was not certified by peer review) is the author/funder, who has granted medRxiv a license to display the preprint in perpetuity. It is made available under a CC-BY-NC-ND 4.0 International license .

Introduction

Cancer immunosurveillance, first proposed by Frank Macfarlane Burnet and Lewis Thomas in 1957, plays an indispensable role in the prevention of gastrointestinal cancers [1]. Cancers were found to occur more frequently in immunocompromised individuals in studies of AIDS patients or organ recipients, particularly for non-melanoma skin cancer [2, 3]. Studies of transgenic mice with defects of crucial components of the immune system have improved our understanding of the effector molecules involved in immunosurveillance and led to the development of immune checkpoint inhibitors, a key breakthrough in immunotherapy for cancer treatment [4, 5]. Inborn errors of immunity (IEIs), also known as primary immunodeficiencies, manifest as recurrent infections, autoimmunity, autoinflammatory diseases, allergy, and cancer [6]. Humans with IEIs provide us with a unique angle of study, or an experiment in nature, for elucidating immunosurveillance for GI cancer and the interaction between environment and host. However, the rare cases of GI cancer in patients with IEIs are challenging for the physicians responsible for their care. For instance, IEIs can manifest as an early-onset GI cancer, but unlike high-risk hereditary risk factors for gastrointestinal cancer, IEIs are not yet generally considered as a risk factor for GI cancers, and there are currently no practice guidelines for screening for gastrointestinal cancers in patients with IEIs [7, 8].

The diagnosis of an early-onset (before the age of 50 years) gastrointestinal cancer, whether gastric or colorectal cancer, is devastating for any patient [9-11]. In 5-6% of patients with gastrointestinal cancers, the cancer can be directly attributed to well-established germline genetic factors. However, the current genetic testing panel focuses on genes causing Lynch syndrome or lactate dehydrogenase 1 (*LDH1*) deficiency, rather than genes causing IEIs [12-14]. The field of primary immunodeficiencies has progressed considerably with recent advances in genetic sequencing technology, which are facilitating genetic diagnosis and discoveries. More than 400 genes have been shown to cause a wide array of immunodysregulation, with a broad spectrum of clinical presentations, some dominant and others recessive, and

medRxiv preprint doi: https://doi.org/10.1101/2022.01.25.22269823; this version posted January 25, 2022. The copyright holder for this preprint (which was not certified by peer review) is the author/funder, who has granted medRxiv a license to display the preprint in perpetuity. It is made available under a CC-BY-NC-ND 4.0 International license .

complete or incomplete penetrance [6]. Epidemiological data suggest that inborn errors of immunity are more prevalent than previously thought, affecting about 1:8,500 to 1:100,000 individuals in the general population [15]. With earlier clinical recognition, appropriate treatments, and hematopoietic stem cell transplantation, many patients with IEIs now survive into adulthood, overcoming severe infections or inflammation. Given these improvements in the overall survival of patients with IEI, physicians may begin to see more delayed clinical phenotypes with an incomplete penetrance, including gastrointestinal cancers.

It is often difficult to understand the human genetics and immunologic basis of IEIs, due to phenotypic and allelic heterogeneity, differences in expressivity and incomplete penetrance. Gastrointestinal manifestations of IEIs can be the first clinical phenotype for several well-described primary immunodeficiencies, including enteropathy in patients with *FOXP3* deficiency, and very-early onset inflammatory bowel disease in patients with *IL10RB* deficiency [16, 17]. Given the complexity of human genetics and immunology, and the rareness of individuals with identified IEIs and gastrointestinal cancer, we systematically reviewed all the reported cases with both an IEI and a gastrointestinal cancer. We summarized their genetic and immunological features and highlighted the elements of importance for the clinical surveillance and management of this special population.

Methods

Case identification and literature search

We followed a Preferred Reporting Items for Systemic Reviews and Meta-Analysis (PRISMA)[18] flow chart for the literature search and data collection for this systematic review (Supplementary Figure 1). Briefly, we conducted a search of the MEDLINE, SCOPUS, EMBASE databases for all publications up to December 1, 2020, focusing on IEIs and GI cancers. We focused on luminal GI cancers, and excluded pancreatic or hepatobiliary cancers. We followed the International Union of Immunological Societies (IUIS) guidelines [6] to ensure the inclusion of all IEIs. We

medRxiv preprint doi: https://doi.org/10.1101/2022.01.25.22269823; this version posted January 25, 2022. The copyright holder for this preprint (which was not certified by peer review) is the author/funder, who has granted medRxiv a license to display the preprint in perpetuity. It is made available under a CC-BY-NC-ND 4.0 International license .

searched three databases for the following terms: "gastrointestinal neoplasms", "primary immunodeficiency", "agammaglobulinemia", "common variable immunodeficiency", "dysgammaglobulinemia", "lymphopenia", "immune dysregulation" and 14 additional Medical Subject Headings (MeSH) terms relating to IEIs in the title, abstract, or keywords of articles (Supplementary Table 1). The results of three database searches (*n*=1146) were then carefully reviewed, as illustrated in Supplementary Figure 1. Additional publications (*n*=24) were identified and included manually if missed by the search strategy described above search. Duplicated articles were consolidated. All records (*n*=1099) were then reviewed independently by two authors (B.Z and H.C) by comprehensive reading, and any discrepancies were resolved by a third author (X-F.K). The inclusion criteria were as follows: 1) Clinical diagnosis of IEI for cases; 2) Clinical diagnosis of gastrointestinal cancers for cases. Exclusion criteria were: 1) Not written in English; 2). Lack of detailed clinical information, such as age, sex, and age-at-onset data for the patient. In total, 76 articles satisfied with our inclusion criteria and had no exclusion criteria.

Data curation, quality assessment and statistical analysis

We collected information by scrutinizing the publications identified to generate a dataset with the following information: author and year of publication of the article and, for the patients, sex, ethnicity, age at cancer diagnosis, genetic defects, immunological dysfunctions, IEI diagnosis, cancer histology and prognosis. Standardized forms were used to extract the required information from the articles. A quality assessment form was developed based on the CARE (CAse REports) [18] tool for quality assessment (Supplementary Table 2). The expected distributions of age, sex, and survival interval of GI cancers were calculated from the data in the SEER (Surveillance, Epidemiology and End Results) database. Time-to-event and survival analyses were performed in GraphPad Prism 8.0 to calculate the hazard ratio. Categorical variables were analyzed with a *Chi*-squared test. Continuous variables were analyzed with *t*-tests. All data were analyzed with the statistical packages in R software (4.0.0).

medRxiv preprint doi: https://doi.org/10.1101/2022.01.25.22269823; this version posted January 25, 2022. The copyright holder for this preprint (which was not certified by peer review) is the author/funder, who has granted medRxiv a license to display the preprint in perpetuity. It is made available under a CC-BY-NC-ND 4.0 International license .

Results

1. A clinical summary of GI cancers in patients with IEIs

The 76 publications identified [19-94] included 149 cases in which both IEIs and gastrointestinal cancers have been diagnosed. A summary of the clinical characteristics of the patients concerned is provided in Figure 1. Briefly, 95 cases were diagnosed with gastric cancer, 13 cases presented with small bowel cancer, 35 cases with colorectal cancer, three cases with esophageal cancer, and three cases with a GI tract tumor unspecified location (Figure 1A). In total, 59 cases (40%) were reported after 2010 (Figure 1B). The dataset consisted of 84 (56.4%) male patients, 58(38.9%) female patients and seven patients for whom sex was not specified (Figure 1C). Age at onset for the cancer ranged from three to 82 years, with a median age at onset of 42 years (Figure 1D). Most of the reported cases (64.4%) were diagnosed before the age of 50 years and their cancers should therefore be considered early-onset. Age at onset for GI was normally distributed, contrasting with the left-skewed distribution in the general population. Fisher's exact test showed that the proportion of male patients was higher in the younger age groups (ages 0-40) than the older age groups (ages above 40, p=0.034) (Figure 1D). Age at onset of the GI cancer was 20 to 35 years lower for the individuals with IEIs than for the general population, according to the data of the SEER database. Ethnicity data were available for only 18 patients: seven white, four non-Hispanic, three Asian, two African American, and two Hispanic or Latino individuals. The IEI diagnosis was common variable immunodeficiency (CVID) for 88 patients in the cohort. The other IEI diagnoses included X-linked agammaglobulinemia (XLA) in 11 patients, selective IgA deficiency (SIgAD) in 10 patients, and ataxia-telangiectasia mutated gene deficiency (*ATM*) in 10 patients. The rate of molecular genetic diagnosis for IEIs was low, with disease-causing genotypes reported for only 18/149 (12.1%).

medRxiv preprint doi: https://doi.org/10.1101/2022.01.25.22269823; this version posted January 25, 2022. The copyright holder for this preprint (which was not certified by peer review) is the author/funder, who has granted medRxiv a license to display the preprint in perpetuity. It is made available under a CC-BY-NC-ND 4.0 International license .

2. Gastric cancers in patients with IEIs

Our literature search identified 95 patients with IEIs and gastric cancer, which was the most common GI cancer (Supplementary Table 3). Most (87/95, 91.5%) of the patients were diagnosed with gastric adenocarcinoma. The other cancer diagnosed were lymphoma (7/95, 7.4%), and neuroendocrine carcinoma (1/95, 1.1%) (Figure 2A). The mean age at gastric cancer diagnosis was 45.86 years, male patients outnumbered female patients in this group (55.8% vs 43.2%), and there were no significant differences with respect to the expected value (Figure 2B). Age at onset of gastric cancer in patients with IEIs was significantly different from that in the general population, with most patients with IEIs diagnosed with gastric cancer before the age of 65 years (Figure 2B). Gastric cancer was diagnosed between the ages of 25 and 44 years in 32.6% of IEI cases, whereas such early diagnosis was uncommon in the general population (Figure 2B). A time-to-event data analysis based on the observed and expected age at onset for gastric cancer yielded a hazard ratio (HR) of 3.57 for the IEI group, indicating a significantly earlier than expected age at onset for this group (Figure 2C). Prognosis was as follows: 31 (32.6%) patients died within one year, and nine (9.5%) patients died within five years of a gastric cancer diagnosis. The five-year survival rate in IEI patients with gastric cancer was 27.3%, which is close to the value reported for the general population, as shown by the survival analysis (Figure 2D). CVID was the most common IEI and was found in 69 cases (72.6%) of gastric cancer. *ATM* defects and XLA were the next most frequent IEIs (Figure 2E). Four patients with *CTLA4* deficiency and one patient with *LRBA* deficiency were reported to have gastric cancer. However, most of the publications did not report the history of *Helicobacter pylori* infection. In summary, inborn errors resulting in B-cell defects, or dysfunctions of humoral immunity were the most common IEIs associated with gastric cancer.

3. Small bowel cancers reported in patients with IEIs

The small bowel is an uncommon site for cancers. To date, 13 patients with IEIs and small bowel cancer have been reported (Supplementary Table 4). Lymphoma was the

medRxiv preprint doi: https://doi.org/10.1101/2022.01.25.22269823; this version posted January 25, 2022. The copyright holder for this preprint (which was not certified by peer review) is the author/funder, who has granted medRxiv a license to display the preprint in perpetuity. It is made available under a CC-BY-NC-ND 4.0 International license .

most common type of cancer (11/13, 84.6%) affecting the small bowel, with 10 cases of B-cell lymphoma, one of T-cell lymphoma. Neuroendocrine carcinoma and reticular lymphosarcoma were reported in one case. Mean age at cancer diagnosis was 43.92 years and there were seven male patients and six female patients. CVID (41.6%, 6/13) was the most common IEIs associated with small bowel cancer, consistent with the recent meta-analysis of CVID patients showing that lymphoma was the cancer most frequently reported in these patients [95]. Chronic diarrhea was reported in 40% of CVID patients, possibly related to chronic small-bowel inflammation, enteropathy, and high levels of intraepithelial lymphocytosis [96], all of which could contribute to the risk of small-bowel lymphoma. One patient with Wiskott-Aldrich syndrome and another with familial Mediterranean fever were reported. Overall, 41.6% (6/13) of the patients survived for more than five years, 15.4% (2/13) survived for less than three years, and 23.1% (3/13) died within one year. The genetic etiology of small-bowel lymphoma in CVID remains to be explored.

4. Colorectal cancers in patients with IEIs

There were 35 cases of colorectal cancer reported in patients with IEIs (Supplementary Table 5). The most common type of cancer was adenocarcinoma (68.1%, 24/35), followed by lymphoma (11.4%, 4/35), and smooth-muscle tumors (5.7%, 2/35) (Figure 3A). Other cellular types of cancer were reported in one case each, including neuroendocrine carcinoma, rhabdomyosarcoma, and squamous cell carcinoma (Figure 3A). Mean age at onset was 32.94 years, and this group comprised 60% (21/35) male and 28.6% (10/35) female patients. Most of the cases (71.4%, 25/35) were diagnosed before 45 years of age, which is significantly younger than expected (Figure 3B). Time-to-event analysis (Figure 3C) revealed a HR of 5.23 (95% CI 2.65- 10.30) for the IEI group. Overall, 42.9% (15/35) of the patients with IEIs died within one year of colon cancer diagnosis, and five-year survival rate for IEIs patients with colon cancer was 31.4% (11/35). A survival analysis showed prognosis to be worse for the IEI group than for the general population (HR = 2.55, p = 0.002) (Figure 3D). The most common immune dysregulations were B-cell defects (71.4%,

medRxiv preprint doi: https://doi.org/10.1101/2022.01.25.22269823; this version posted January 25, 2022. The copyright holder for this preprint (which was not certified by peer review) is the author/funder, who has granted medRxiv a license to display the preprint in perpetuity. It is made available under a CC-BY-NC-ND 4.0 International license .

25/35), including CVID, XLA or selective IgA deficiency. However, DNA repair defects, including *BLM*, *NBS1* and *ATM* gene mutations, accounted for 20% (7/35) of IEI cases with colorectal cancer (Figure 3E). In summary, colorectal cancer in patients with IEIs appeared to be more heterogeneous in terms of immunological dysfunction and to lead to worse outcomes than such cancers in the general population.

Discussion

Current guidelines recommend genetic testing and screening for those with potential inherited syndromes, including Lynch syndrome and familial adenomatous polyposis, and for those with a family history of early-onset colorectal cancers [7, 14, 97]. The Fearon-Volgelstein model has prevailed over the last few decades, and genetic practices for GI cancer have now emerged and can facilitate the management of about 3% to 5% of all colorectal cancer patients[13]. Pathogenic variants with various degrees of clinical penetrance have been identified in 9-26% of patients with early-onset colorectal cancer [98]. However, the detection of such mutations, as part of what is known as precision medicine, is limited by a lack of knowledge of the full genetic landscape for GI cancers. We investigated the immunogenetic determinants of GI cancers by performing a systemic review of cases in patients with IEIs, who usually have a genetic predisposition for cancer and abnormal immunological dysregulation. Even though IEIs are usually diagnosed during childhood and mortality rates are high at a young age, 2-10% of patients have been found to develop cancers with their short lifespans [83]. Our analysis indicates that patients with IEIs may be prone to early-onset GI cancers with a poor prognosis. Longitudinal data from a large IEI cohort are lacking, but our findings are consistent with previous CVID studies [63, 99]. So, should gastroenterologists screen for GI cancers early in patients with IEIs? Further studies are required to delineate the clinical epidemiology of IEIs in patients with early-onset GI cancers, through immunological or genetic testing. Meanwhile, gastroenterologists should be familiar with the clinical manifestations in patients with both IEIs and GI symptoms. Indeed, a collaboration between clinical immunologists and pediatricians might facilitate GI cancer surveillance in individuals with IEIs. We

medRxiv preprint doi: https://doi.org/10.1101/2022.01.25.22269823; this version posted January 25, 2022. The copyright holder for this preprint (which was not certified by peer review) is the author/funder, who has granted medRxiv a license to display the preprint in perpetuity. It is made available under a CC-BY-NC-ND 4.0 International license .

also need to address the question as to whether there is an association between clinical symptoms or biomarkers of IEIs and early-onset GI cancer? It would be intriguing to determine whether immunoglobulin level, lymphocytopenia, a clinical diagnosis of CVID, or a history of IVIG use is associated with early-onset GI cancer, ideally based on data from a large registry of GI cancer patients.

Several factors could, conceivably, account for the early-onset gastrointestinal cancers observed in patients with IEIs. First, primary immunodeficiency may lead to chronic mucocutaneous infection (with *Helicobacter. pylori* or EBV, for example,) in the gastrointestinal tract, which is a risk factor for gastric cancer. *CARMIL2* deficiency has been associated with EBV^+ smooth muscle tumors in the GI tract [70]. Previous studies on CVID have revealed a high prevalence of *H. pylori* infection and multifocal atrophic gastritis, but *H.pylori* infection rates in CVID patients vary between reports and may not, necessarily, explain the risk of GI cancer [72]. Nevertheless, one recent large CVID cohort meta-analysis [95] on 8123 CVID patients revealed an estimated prevalence of gastric cancer in CVID patients of about 1.5%, lower than the prevalence of 4.1% for lymphoma, consistent with another report suggesting that gastric cancer may be the leading cause of death in CVID patients [72]. GWAS studies on *H.pylori* infection and peptic ulcer disease have identified many loci associated with the observed phenotypes, but the mechanisms by which susceptibility loci cause disease are poorly understood. It remains unclear whether there is a Mendelian susceptibility for *H.pylori* infection or persistence.

Gastrointestinal cancers may also arise due to defects of immune cells in the mucosa. As most reported cases have impaired humoral immunity, this suggests that B cells may play an important role in gastrointestinal mucosal surveillance. Only a few cases with genetic abnormalities have been reported, but several genetic disorders have well-defined B-cell abnormalities, including *CTLA4*, *LBRA*, and *CARMIL2* mutations.

A third plausible explanation is related to intrinsic epithelium abnormalities due to the pleiotropic effects of some genes. Three disorders, ataxia-telangiectasia due to *ATM* mutations, Nijmegen breakage syndrome due to *NBS1* defects, and Bloom syndrome due to *BLM* mutations, have been reported to cause heterogeneous clinical phenotypes

medRxiv preprint doi: https://doi.org/10.1101/2022.01.25.22269823; this version posted January 25, 2022. The copyright holder for this preprint (which was not certified by peer review) is the author/funder, who has granted medRxiv a license to display the preprint in perpetuity. It is made available under a CC-BY-NC-ND 4.0 International license .

and chromosomal instability. ATM is a serine/threonine kinase activated by DNA damage, it phosphorylates several tumor suppressors, including p53, NBS1, and H2AX. Eight patients (9.5%) with ataxia-telangiectasia due to biallelic *ATM* gene mutations have been reported to have gastric cancer and immunodeficiency [38, 55, 81, 87, 88, 90]. Individuals with heterozygous germline *ATM* mutations might have an increased risk for early-onset gastric and pancreatic cancer [100]. However, some IEIs characterized by impaired DNA, such as MCM4 or GINS1 deficiencies, have not been found to lead to cancers [101, 102]. It is possible that GI cancers in patients with DNA repair disorders are more strongly related to intrinsic epithelial cell defects than to compromised immunity. With advances in human genetics and immunological technologies, studies of humans with IEIs might improve our understanding of immune surveillance in the gastrointestinal tract in general.

Figure and table legend:

Figure 1: A descriptive summary of patients with inborn errors of immunity and GI cancers. A. A schematic presentation of the numbers of esophageal, gastric, small bowel and colon cancers reported in patients with IEIs. B. The table describes the number of cases published over the last six decades. C. A pie chart of the sex distribution for this cohort. D. A histogram presents the age and sex distributions of the cohort. NA: Not available.

Figure 2: Gastric cancers reported in patients with IEIs. A. Cellular types of gastric cancer reported in patients with IEIs. Adenoca: Adenocarcinoma, NET: Neuroendocrine tumor. B. The table shows the sex and age distributions of gastric cancer patients from the IEI cohort relative to the expected numbers imputed from the SEER database. C. A pie chart of the different types of IEI and numbers of cases with gastric cancer. CVID: Common variable immune deficiency; ATM: Ataxia-telangiectasia mutated, XLA: X-linked agammaglobulinemia, CTLA4: Cytotoxic T-lymphocyte associated Protein 4, SIgAD: Selective IgA deficiency, FMF: Familial Mediterranean fever, LRBA: LPS responsive beige-like anchor protein. D.

medRxiv preprint doi: https://doi.org/10.1101/2022.01.25.22269823; this version posted January 25, 2022. The copyright holder for this preprint (which was not certified by peer review) is the author/funder, who has granted medRxiv a license to display the preprint in perpetuity. It is made available under a CC-BY-NC-ND 4.0 International license .

Survival curve for gastric cancer comparing patients with and without IEIs. NA: Not available.

Figure 3: Colon cancer in patients with IEIs. A. Cellular types of colon cancer reported in patients with IEIs. Adenoca: Adenocarcinoma, NET: Neuroendocrine tumor, SMT: Smooth muscle tumor, RMS: Rhabdomycosarcoma, GS: Granulocytic sarcoma, SCC: Squamous cell carcinoma. B. The table shows the sex and age distribution of colon cancer patients from the IEI cohort relative to the expected numbers imputed from the SEER database. C. A pie chart of the different types of IEIs and numbers of cases with colon cancer. CVID: Common variable immune deficiency; ATM: Ataxia-telangiectasia mutated, XLA: X-linked agammaglobulinemia, BLM: Bloom syndrome, SIgAD: Selective IgA deficiency, *CARMIL2*: Capping Protein Regulator And Myosin 1 Linker 2, ATM: Ataxia-telangiectasia mutated, FMF: Familial Mediterranean fever, NBS: Nijmegen breakage syndrome. D. Survival curve for colon cancer comparing patients with and without IEIs. NA: Not available.

Acknowledgments:

We thank Dr. Jean-Laurent Casanova and Anil K Rustgi for their careful reading of the manuscript and suggestions. Research reported in this publication was supported by the National Institute Of Diabetes And Digestive And Kidney Diseases of the National Institutes of Health under Award Number K08DK128631. The content is solely the responsibility of the authors and does not necessarily represent the official views of the National Institutes of Health. Figure 1 was created with BioRender.com.

Reference:

[1] Burnet M. Cancer; a biological approach. I. The processes of control. Br Med J. 1957;1:779-86.

[2] Frisch M, Biggar RJ, Engels EA, Goedert JJ, Group AI-CMRS. Association of

medRxiv preprint doi: https://doi.org/10.1101/2022.01.25.22269823; this version posted January 25, 2022. The copyright holder for this preprint (which was not certified by peer review) is the author/funder, who has granted medRxiv a license to display the preprint in perpetuity. It is made available under a CC-BY-NC-ND 4.0 International license .

cancer with AIDS-related immunosuppression in adults. JAMA. 2001;285:1736-45.

[3] Ramsay HM, Fryer AA, Hawley CM, Smith AG, Harden PN. Non-melanoma skin cancer risk in the Queensland renal transplant population. Br J Dermatol. 2002;147:950-6.

[4] Kroemer G, Zitvogel L. Immune checkpoint inhibitors. J Exp Med. 2021;218.

[5] Kim W, Chu TH, Nienhuser H, Jiang Z, Del Portillo A, Remotti HE, et al. PD-1 Signaling Promotes Tumor-Infiltrating Myeloid-Derived Suppressor Cells and Gastric Tumorigenesis in Mice. Gastroenterology. 2021;160:781-96.

[6] Tangye SG, Al-Herz W, Bousfiha A, Chatila T, Cunningham-Rundles C, Etzioni A, et al. Human Inborn Errors of Immunity: 2019 Update on the Classification from the International Union of Immunological Societies Expert Committee. J Clin Immunol. 2020;40:24-64.

[7] Shaukat A, Kahi CJ, Burke CA, Rabeneck L, Sauer BG, Rex DK. ACG Clinical Guidelines: Colorectal Cancer Screening 2021. Am J Gastroenterol. 2021;116:458-79.

[8] Milne AN, Offerhaus GJ. Early-onset gastric cancer: Learning lessons from the young. World J Gastrointest Oncol. 2010;2:59-64.

[9] Bergquist JR, Leiting JL, Habermann EB, Cleary SP, Kendrick ML, Smoot RL, et al. Early-onset gastric cancer is a distinct disease with worrisome trends and oncogenic features. Surgery. 2019;166:547-55.

[10] Kolb JM, Ahnen DJ, Samadder NJ. Evidenced-Based Screening Strategies for a Positive Family History. Gastrointest Endosc Clin N Am. 2020;30:597-609.

[11] Machlowska J, Baj J, Sitarz M, Maciejewski R, Sitarz R. Gastric Cancer: Epidemiology, Risk Factors, Classification, Genomic Characteristics and Treatment Strategies. Int J Mol Sci. 2020;21.

[12] Laszkowska M, Silver ER, Schrope B, Kastrinos F, Wang TC, Hur C. Optimal Timing of Total Gastrectomy to Prevent Diffuse Gastric Cancer in Individuals With Pathogenic Variants in CDH1. Clinical gastroenterology and hepatology : the official clinical practice journal of the American Gastroenterological Association2020. p. 822-9.e4.

[13] Stoffel EM, Boland CR. Genetics and Genetic Testing in Hereditary Colorectal

medRxiv preprint doi: https://doi.org/10.1101/2022.01.25.22269823; this version posted January 25, 2022. The copyright holder for this preprint (which was not certified by peer review) is the author/funder, who has granted medRxiv a license to display the preprint in perpetuity. It is made available under a CC-BY-NC-ND 4.0 International license .

Cancer. Gastroenterology. 2015;149:1191-203 e2.

[14] Rustgi AK. The genetics of hereditary colon cancer. Genes Dev. 2007;21:2525-38.

[15] Kobrynski L, Powell RW, Bowen S. Prevalence and morbidity of primary immunodeficiency diseases, United States 2001-2007. J Clin Immunol. 2014;34:954-61.

[16] Bennett CL, Christie J, Ramsdell F, Brunkow ME, Ferguson PJ, Whitesell L, et al. The immune dysregulation, polyendocrinopathy, enteropathy, X-linked syndrome (IPEX) is caused by mutations of FOXP3. Nat Genet. 2001;27:20-1.

[17] Glocker EO, Kotlarz D, Boztug K, Gertz EM, Schaffer AA, Noyan F, et al. Inflammatory bowel disease and mutations affecting the interleukin-10 receptor. N Engl J Med. 2009;361:2033-45.

[18] Tawfik GM, Dila KAS, Mohamed MYF, Tam DNH, Kien ND, Ahmed AM, et al. A step by step guide for conducting a systematic review and meta-analysis with simulation data. Tropical medicine and health2019. p. 46.

[19] Aguilar FP, Alfonso V, Rivas S, López Aldeguer J, Portilla J, Berenguer J. Jejunal malignant lymphoma in a patient with adult-onset hypo-gamma-globulinemia and nodular lymphoid hyperplasia of the small bowel. The American journal of gastroenterology1987. p. 472-5.

[20] Cunningham-Rundles C, Siegal FP, Cunningham-Rundles S, Lieberman P. Incidence of cancer in 98 patients with common varied immunodeficiency. Journal of clinical immunology1987. p. 294-9.

[21] Durham JC, Stephens DS, Rimland D, Nassar VH, Spira TJ. Common variable hypogammaglobulinemia complicated by an unusual T-suppressor/cytotoxic cell lymphoma. Cancer1987. p. 271-6.

[22] Takemiya M, Shiraishi S, Teramoto T, Miki Y. Bloom's syndrome with porokeratosis of Mibelli and multiple cancers of the skin, lung and colon. Clinical genetics1987. p. 35-44.

[23] Conley ME, Ziegler MM, Borden St, Huff DS, Boyle JT. Multifocal adenocarcinoma of the stomach in a child with common variable immunodeficiency.

medRxiv preprint doi: https://doi.org/10.1101/2022.01.25.22269823; this version posted January 25, 2022. The copyright holder for this preprint (which was not certified by peer review) is the author/funder, who has granted medRxiv a license to display the preprint in perpetuity. It is made available under a CC-BY-NC-ND 4.0 International license .

Journal of pediatric gastroenterology and nutrition1988. p. 456-60.

[24] Cunningham-Rundles C. Clinical and immunologic analyses of 103 patients with common variable immunodeficiency. Journal of clinical immunology1989. p. 22-33.

[25] Vorechovsky I, Litzman J, Lokaj J, Hausner P, Poch T. Common variable immunodeficiency and malignancy: a report of two cases and possible explanation for the association. Cancer immunology, immunotherapy : CII1990. p. 250-4.

[26] Paraf F, Paraf A, Brousse N. Primary gastric lymphoma occurring in familial Mediterranean fever. Journal of clinical gastroenterology1991. p. 587-8.

[27] Adachi Y, Mori M, Kido A, Shimono R, Suehiro T, Sugimachi K. Multiple colorectal neoplasms in a young adult with hypogammaglobulinemia. Report of a case. Diseases of the colon and rectum1992. p. 197-200.

[28] Castellano G, Moreno D, Galvao O, Ballestín C, Colina F, Mollejo M, et al. Malignant lymphoma of jejunum with common variable hypogammaglobulinemia and diffuse nodular hyperplasia of the small intestine. A case study and literature review. Journal of clinical gastroenterology1992. p. 128-35.

[29] Matz J, Routes JM, Borish LC. Diffuse pulmonary infiltrates in hypogammaglobulinemia. Annals of allergy1992. p. 485-90.

[30] de Bruin NC, de Groot R, den Hollander JC, Agoston SI, van Dongen JJ, Neijens HJ. Small-cell undifferentiated (neuroendocrine) carcinoma of the cecum in a child with common variable immunodeficiency. The American journal of pediatric hematology/oncology1993. p. 258-61.

[31] Lavilla P, Gil A, Rodríguez MC, Dupla ML, Pintado V, Fontán G. X-linked agammaglobulinemia and gastric adenocarcinoma. Cancer1993. p. 1528-31.

[32] Ohnoshi T, Hayashi K, Tagawa S, Saito S, Matsutomo S, Kawashima K, et al. Successful treatment of non-Hodgkin's lymphoma in a patient with common variable immunodeficiency. Internal medicine (Tokyo, Japan)1993. p. 152-5.

[33] van der Meer JW, Weening RS, Schellekens PT, van Munster IP, Nagengast FM. Colorectal cancer in patients with X-linked agammaglobulinaemia. Lancet (London, England)1993. p. 1439-40.

[34] Chiaramonte C, Glick SN. Nodular lymphoid hyperplasia of the small bowel

medRxiv preprint doi: https://doi.org/10.1101/2022.01.25.22269823; this version posted January 25, 2022. The copyright holder for this preprint (which was not certified by peer review) is the author/funder, who has granted medRxiv a license to display the preprint in perpetuity. It is made available under a CC-BY-NC-ND 4.0 International license .

complicated by jejunal lymphoma in a patient with common variable immune deficiency syndrome. AJR American journal of roentgenology1994. p. 1118-9.

[35] Cox JE, Ott DJ. Gastric adenocarcinoma in a patient with common variable immunodeficiency. Abdominal imaging1994. p. 501-2.

[36] Zirkin HJ, Levy J, Katchko L. Small cell undifferentiated carcinoma of the colon associated with hepatocellular carcinoma in an immunodeficient patient. Human pathology1996. p. 992-6.

[37] Balci S, Aktas D. Mucinous carcinoma of the colon in a 16-year-old Turkish boy with Bloom syndrome: cytogenetic, histopathologic, TP53 gene and protein expression studies. Cancer genetics and cytogenetics1999. p. 45-8.

[38] Murphy RC, Berdon WE, Ruzal-Shapiro C, Hall EJ, Kornecki A, Daneman A, et al. Malignancies in pediatric patients with ataxia telangiectasia. Pediatric radiology1999. p. 225-30.

[39] Wang J, German J, Ashby K, French SW. Ulcerative colitis complicated by dysplasia-adenoma-carcinoma in a man with Bloom's syndrome. Journal of clinical gastroenterology1999. p. 380-2.

[40] Zullo A, Romiti A, Rinaldi V, Vecchione A, Tomao S, Aiuti F, et al. Gastric pathology in patients with common variable immunodeficiency. Gut1999. p. 77-81.

[41] Bachmeyer C, Monge M, Cazier A, Le Deist F, de Saint Basile G, Durandy A, et al. Gastric adenocarcinoma in a patient with X-linked agammaglobulinaemia. European journal of gastroenterology & hepatology2000. p. 1033-5.

[42] Mellemkjaer L, Hammarstrom L, Andersen V, Yuen J, Heilmann C, Barington T, et al. Cancer risk among patients with IgA deficiency or common variable immunodeficiency and their relatives: a combined Danish and Swedish study. Clinical and experimental immunology2002. p. 495-500.

[43] Meyer S, Kingston H, Taylor AMR, Byrd PJ, Last JIK, Brennan BMD, et al. Rhabdomyosarcoma in Nijmegen breakage syndrome: strong association with perianal primary site. Cancer genetics and cytogenetics2004. p. 169-74.

[44] Lackmann GM, Wahn V, Poremba C, Niehues T. A teenager with X-linked agammaglobulinemia and vitamin B12 deficiency anemia. Journal of pediatric

medRxiv preprint doi: https://doi.org/10.1101/2022.01.25.22269823; this version posted January 25, 2022. The copyright holder for this preprint (which was not certified by peer review) is the author/funder, who has granted medRxiv a license to display the preprint in perpetuity. It is made available under a CC-BY-NC-ND 4.0 International license .

gastroenterology and nutrition2005. p. 360-2.

[45] Delia M, Liso V, Capalbo S, Napoli A, Ricco R, Semenzato G, et al. Common variable immunodeficiency patient with large granular lymphocytosis developing extranodal diffuse large B-cell lymphoma: a case report. Haematologica2006. p. ECR61.

[46] Desar IME, Keuter M, Raemaekers JMM, Jansen JBMJ, van Krieken JHJ, van der Meer JWM. Extranodal marginal zone (MALT) lymphoma in common variable immunodeficiency. The Netherlands journal of medicine2006. p. 136-40.

[47] Gabizon I, Giladi H, Ovnat A, Dukhno O, Flusser D, Sukenik S. Small bowel obstruction by a carcinoid tumor in a patient with familial Mediterranean fever. The Israel Medical Association journal : IMAJ2006. p. 359-60.

[48] Daniels JA, Lederman HM, Maitra A, Montgomery EA. Gastrointestinal tract pathology in patients with common variable immunodeficiency (CVID): a clinicopathologic study and review. The American journal of surgical pathology2007. p. 1800-12.

[49] Dunnigan M, Yfantis H, Rapoport AP, Hosseinzadeh K, Gocke CD, Cross RK. Large cell lymphoma presenting as a flare of colitis in a patient with common variable immune deficiency. Digestive diseases and sciences2007. p. 830-4.

[50] Purim O, Sulkes A, Brenner B. Adjuvant chemotherapy with 5-fluorouracil in a patient with colorectal cancer and Familial Mediterranean Fever. Anti-cancer drugs2007. p. 733-5.

[51] Brosens LAA, Tytgat KMAJ, Morsink FHM, Sinke RJ, Ten Berge IJM, Giardiello FM, et al. Multiple colorectal neoplasms in X-linked agammaglobulinemia. Clinical gastroenterology and hepatology : the official clinical practice journal of the American Gastroenterological Association2008. p. 115-9.

[52] Malhotra RK, Li W. Poorly differentiated gastroenteropancreatic neuroendocrine carcinoma associated with X-linked hyperimmunoglobulin M syndrome. Archives of pathology & laboratory medicine2008. p. 847-50.

[53] Rosa DD, Pasqualotto AC, Denning DW. Chronic mucocutaneous candidiasis and oesophageal cancer. Medical mycology2008. p. 85-91.

medRxiv preprint doi: https://doi.org/10.1101/2022.01.25.22269823; this version posted January 25, 2022. The copyright holder for this preprint (which was not certified by peer review) is the author/funder, who has granted medRxiv a license to display the preprint in perpetuity. It is made available under a CC-BY-NC-ND 4.0 International license .

[54] Thomas ERA, Shanley S, Walker L, Eeles R. Surveillance and treatment of malignancy in Bloom syndrome. Clinical oncology (Royal College of Radiologists (Great Britain))2008. p. 375-9.

[55] Otabor IA, Abdessalam SF, Erdman SH, Hammond S, Besner GE. Gastric outlet obstruction due to adenocarcinoma in a patient with Ataxia-Telangiectasia syndrome: a case report and review of the literature. World journal of surgical oncology2009. p. 29.

[56] Yap YL, So JBY. Gastric adenocarcinoma occurring in a young patient with common variable immunodeficiency syndrome. Singapore medical journal2009. p. e201-3.

[57] Benjazia E, Turki H, Atig A, Khalifa M, Letaief A, Bahri F, et al. Bloom syndrome complicated by colonic cancer in a young Tunisian woman. Clinics and research in hepatology and gastroenterology2011. p. 682-4.

[58] Dhalla F, da Silva SP, Lucas M, Travis S, Chapel H. Review of gastric cancer risk factors in patients with common variable immunodeficiency disorders, resulting in a proposal for a surveillance programme. Clinical and experimental immunology2011. p. 1-7.

[59] Slotta JE, Heine S, Kauffels A, Krenn T, Grünhage F, Wagner M, et al. Gastrectomy with isoperistaltic jejunal parallel pouch in a 15-year-old adolescent boy with gastric adenocarcinoma and autosomal recessive agammaglobulinemia. Journal of pediatric surgery2011. p. e21-4.

[60] Turkbeyler IH, Pehlivan Y, Comez G, Pehlivan D, Sevinc A, Kalender ME, et al. Esophagus cancer and IgA deficiency in a patient with Dubowitz syndrome: a case report. The Tokai journal of experimental and clinical medicine2011. p. 29-30.

[61] Watkins C, Sahni R, Holla N, Litchfield J, Youngberg G, Krishnaswamy G. Malignancy in Common Variable Immune Deficiency: Report of Two Rare Cases of Gastrointestinal Malignancy and a Review of the Literature. Cardiovascular & Hematological Disorders-Drug Targets: Bentham Science Publishers Ltd.; 2012. p. 21-7.

[62] Patiroglu T, Eke Gungor H, Arslan D, Deniz K, Unal E, Coskun A. Gastric signet

medRxiv preprint doi: https://doi.org/10.1101/2022.01.25.22269823; this version posted January 25, 2022. The copyright holder for this preprint (which was not certified by peer review) is the author/funder, who has granted medRxiv a license to display the preprint in perpetuity. It is made available under a CC-BY-NC-ND 4.0 International license .

ring carcinoma in a patient with ataxia-telangiectasia: a case report and review of the literature. Journal of pediatric hematology/oncology2013. p. e341-3.

[63] De Petris G, Dhungel BM, Chen L, Chang Y-HH. Gastric adenocarcinoma in common variable immunodeficiency: features of cancer and associated gastritis may be characteristic of the condition. International journal of surgical pathology2014. p. 600-6.

[64] Loh KP, Hunt JP, Mehendiratta V. Education and imaging. Gastrointestinal: Incidentally detected gastric carcinoma in patient with common variable immunoglobulin deficiency. Journal of gastroenterology and hepatology2014. p. 1127.

[65] Staines Boone AT, Torres Martínez MG, López Herrera G, de Leija Portilla JO, Espinosa Padilla SE, Espinosa Rosales FJ, et al. Gastric adenocarcinoma in the context of X-linked agammaglobulinemia: case report and review of the literature. Journal of clinical immunology2014. p. 134-7.

[66] Vlkova M, Ticha O, Nechvatalova J, Kalina T, Litzman J, Mauri C, et al. Regulatory B cells in CVID patients fail to suppress multifunctional IFN-γ+ TNF-α+ CD4+ T cells differentiation. Clinical immunology (Orlando, Fla)2015. p. 292-300.

[67] Goldberg A, Rose L, McCue P. Common Variable Immunodeficiency Disease and Rectal Squamous Cell Carcinoma: a Case Report of a Rare Syndromic Tumor Type. Journal of gastrointestinal cancer2016. p. 470-3.

[68] Hayakawa S, Okada S, Tsumura M, Sakata S, Ueno Y, Imai K, et al. A Patient with CTLA-4 Haploinsufficiency Presenting Gastric Cancer. Journal of Clinical Immunology: Springer New York LLC; 2016. p. 28-32.

[69] Bratanič N, Kovač J, Pohar K, Trebušak Podkrajšek K, Ihan A, Battelino T, et al. Multifocal gastric adenocarcinoma in a patient with LRBA deficiency. Orphanet journal of rare diseases2017. p. 131.

[70] Schober T, Magg T, Laschinger M, Rohlfs M, Linhares ND, Puchalka J, et al. A human immunodeficiency syndrome caused by mutations in CARMIL2. Nature Communications: Nature Publishing Group; 2017. p. 1-13.

[71] Egg D, Schwab C, Gabrysch A, Arkwright PD, Cheesman E, Giulino-Roth L, et

medRxiv preprint doi: https://doi.org/10.1101/2022.01.25.22269823; this version posted January 25, 2022. The copyright holder for this preprint (which was not certified by peer review) is the author/funder, who has granted medRxiv a license to display the preprint in perpetuity. It is made available under a CC-BY-NC-ND 4.0 International license .

al. Increased Risk for Malignancies in 131 Affected CTLA4 Mutation Carriers. Frontiers in immunology2018. p. 2012.

[72] Pulvirenti F, Pecoraro A, Cinetto F, Milito C, Valente M, Santangeli E, et al. Gastric Cancer Is the Leading Cause of Death in Italian Adult Patients With Common Variable Immunodeficiency. Frontiers in immunology2018. p. 2546.

[73] Varricchi G, Pecoraro A, Crescenzi L, Marone G, Travaglino A, D'Armiento FP, et al. Gastroduodenal Disorders in Patients with CVID Undergoing Immunoglobulin Therapy. Current pharmaceutical biotechnology2018. p. 734-41.

[74] Li M, Chen W, Sun X, Wang Z, Zou X, Wei H, et al. Metastatic colorectal cancer and severe hypocalcemia following irinotecan administration in a patient with X-linked agammaglobulinemia: a case report. BMC medical genetics2019. p. 157.

[75] Antunes PdSL, Tersariol HG, Veiga MMB, Menezes MCSd, Bernardi FDC, Forte WCN. NEUROENDOCRINE TUMOR IN A CHILD WITH COMMON VARIABLE IMMUNODEFICIENCY. Revista paulista de pediatria : orgao oficial da Sociedade de Pediatria de Sao Paulo2020. p. e2018146.

[76] HUIZENGA KA, WOLLAEGER EE, GREEN PA, McKENZIE BF. Serum globulin deficiencies in non-tropical sprue, with report of two cases of acquired agammaglobulinemia. The American journal of medicine1961. p. 572-80.

[77] KILDEBERG P. The Aldrich syndrome. Report of a case and discussion of pathogenesis. Pediatrics1961. p. 362-9.

[78] Hermans PE, Huizenga KA, Hoffman HN, Brown AL, Markowitz H. Dysgammaglobulinemia associated with nodular lymphoid hyperplasia of the small intestine. The American journal of medicine1966. p. 78-89.

[79] Miller DG. The association of immune disease and malignant lymphoma. Annals of internal medicine1967. p. 507-21.

[80] Rádl J, Masopust J, Houstěk J, Hrodek O. Paraproteinaemia and unusual dys-gamma-globulinaemia in a case of Wiskott-Aldrich syndrome. An immunochemical study. Archives of disease in childhood1967. p. 608-14.

[81] Haerer A. Ataxia- Telangiectasia With gastric adenocarcinoma. Journal of American Medical Association1969.

medRxiv preprint doi: https://doi.org/10.1101/2022.01.25.22269823; this version posted January 25, 2022. The copyright holder for this preprint (which was not certified by peer review) is the author/funder, who has granted medRxiv a license to display the preprint in perpetuity. It is made available under a CC-BY-NC-ND 4.0 International license .

[82] Fraser KJ, Rankin JG. Selective deficiency of IgA immunoglobulins associated with carcinoma of the stomach. Australasian annals of medicine1970. p. 165-7.

[83] Kersey JH, Spector BD, Good RA. Primary immunodeficiency diseases and cancer: The immunodeficiency-cancer registry. International Journal of Cancer1973. p. 333-47.

[84] Hamoudi AB, Ertel I, Newton WA, Reiner CB, Clatworthy HW. Multiple neoplasms in an adolescent child associated with IGA deficiency. Cancer1974. p. 1134-44.

[85] Faraci RP, Hoffstrand HJ, Witebsky FG, Blaese RM, Beazley RM. Malignant lymphoma of the jejunum in a patient with Wiskott-Aldrich syndrome. Surgical treatment. Archives of surgery (Chicago, Ill : 1960)1975. p. 218-20.

[86] Hermans PE, Diaz-Buxo JA, Stobo JD. Idiopathic late-onset immunoglobulin deficiency. Clinical observations in 50 patients. The American journal of medicine1976. p. 221-37.

[87] Siegel SE, Hays DM, Romansky S, Isaacs H. Carcinoma of the stomach in childhood. Cancer1976. p. 1781-4.

[88] Watanabe A, Hanazono H, Sogawa H, Takaya H. Stomach cancer of a 14-year-old boy with ataxia-telangiectasia. The Tohoku journal of experimental medicine1977. p. 127-31.

[89] Battle WM, Brooks FP. Adenocarcinoma of the stomach with common variable immunodeficiency syndrome. Archives of internal medicine1978. p. 1682-4.

[90] Frais MA. Gastric adenocarcinoma due to ataxia-telangiectasia (Louis-Bar syndrome). Journal of medical genetics1979. p. 160-1.

[91] Lamers CB, Wagener T, Assmann KJ, van Tongeren JH. Jejunal lymphoma in a patient with primary adult-onset hypogammaglobulinemia and nodular lymphoid hyperplasia of the small intestine. Digestive diseases and sciences1980. p. 553-7.

[92] Gonzalez-Vitale JC, Gomez LG, Goldblum RM, Goldman AS, Patterson M. Immunoblastic lymphoma of small intestine complicating late-onset immunodeficiency. Cancer1982. p. 445-9.

[93] Mir-Madjlessi SH, Vafai M, Khademi J, Kamalian N. Coexisting primary

medRxiv preprint doi: https://doi.org/10.1101/2022.01.25.22269823; this version posted January 25, 2022. The copyright holder for this preprint (which was not certified by peer review) is the author/funder, who has granted medRxiv a license to display the preprint in perpetuity. It is made available under a CC-BY-NC-ND 4.0 International license .

malignant lymphoma and adenocarcinoma of the large intestine in an IgA-deficient boy. Diseases of the colon and rectum1984. p. 822-4.

[94] Kinlen LJ, Webster AD, Bird AG, Haile R, Peto J, Soothill JF, et al. Prospective study of cancer in patients with hypogammaglobulinaemia. Lancet (London, England)1985. p. 263-6.

[95] Kiaee F, Azizi G, Rafiemanesh H, Zainaldain H, Sadaat Rizvi F, Alizadeh M, et al. Malignancy in common variable immunodeficiency: a systematic review and meta-analysis. Expert review of clinical immunology2019. p. 1105-13.

[96] Jørgensen SF, Reims HM, Frydenlund D, Holm K, Paulsen V, Michelsen AE, et al. A Cross-Sectional Study of the Prevalence of Gastrointestinal Symptoms and Pathology in Patients With Common Variable Immunodeficiency. The American journal of gastroenterology2016. p. 1467-75.

[97] American Gastroenterological A. American Gastroenterological Association medical position statement: hereditary colorectal cancer and genetic testing. Gastroenterology. 2001;121:195-7.

[98] Daca Alvarez M, Quintana I, Terradas M, Mur P, Balaguer F, Valle L. The Inherited and Familial Component of Early-Onset Colorectal Cancer. Cells. 2021;10.

[99] Pedini V, Verga JU, Terrenato I, Menghini D, Mezzanotte C, Danieli MG. Incidence of malignancy in patients with common variable immunodeficiency according to therapeutic delay: an Italian retrospective, monocentric cohort study. Allergy, asthma, and clinical immunology : official journal of the Canadian Society of Allergy and Clinical Immunology2020. p. 54.

[100] van Os NJH, Jansen AFM, van Deuren M, Haraldsson A, van Driel NTM, Etzioni A, et al. Ataxia-telangiectasia: Immunodeficiency and survival. Clinical immunology (Orlando, Fla)2017. p. 45-55.

[101] Gineau L, Cognet C, Kara N, Lach FP, Dunne J, Veturi U, et al. Partial MCM4 deficiency in patients with growth retardation, adrenal insufficiency, and natural killer cell deficiency. J Clin Invest. 2012;122:821-32.

[102] Cottineau J, Kottemann MC, Lach FP, Kang YH, Vely F, Deenick EK, et al. Inherited GINS1 deficiency underlies growth retardation along with neutropenia and

medRxiv preprint doi: https://doi.org/10.1101/2022.01.25.22269823; this version posted January 25, 2022. The copyright holder for this preprint (which was not certified by peer review) is the author/funder, who has granted medRxiv a license to display the preprint in perpetuity. It is made available under a CC-BY-NC-ND 4.0 International license .

NK cell deficiency. J Clin Invest. 2017;127:1991-2006.

Figure 1

A.

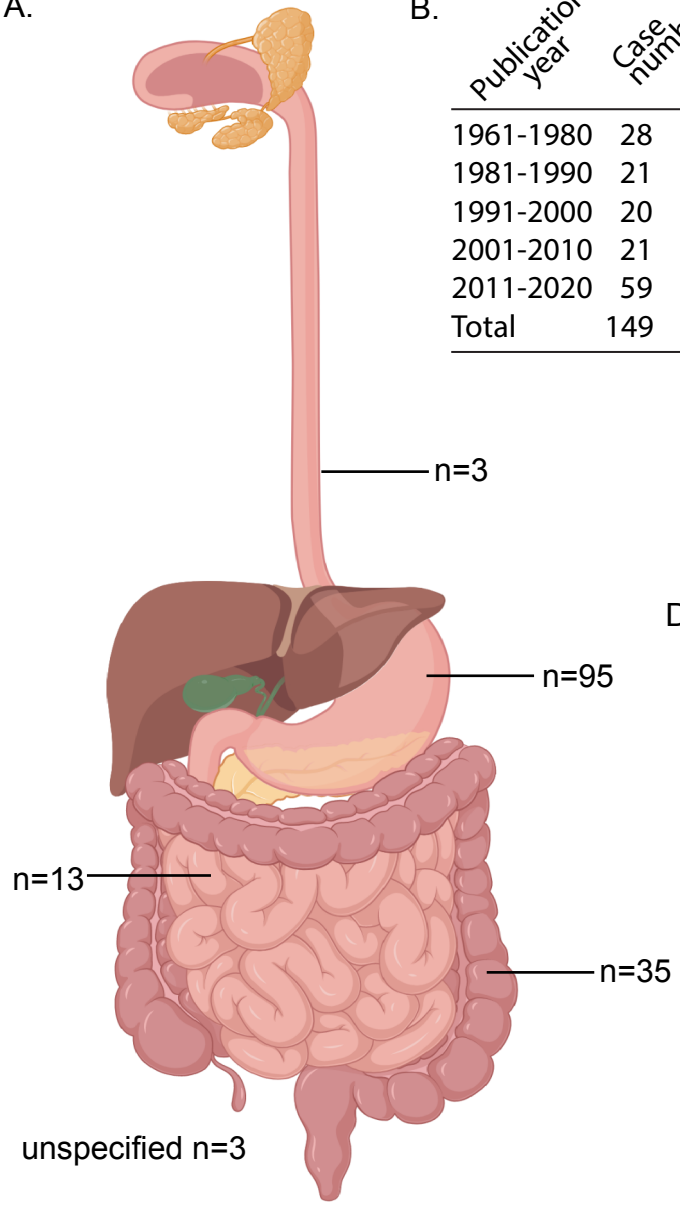

B.

Publication year	Case number
1961-1980	28
1981-1990	21
1991-2000	20
2001-2010	21
2011-2020	59
Total	149

C.

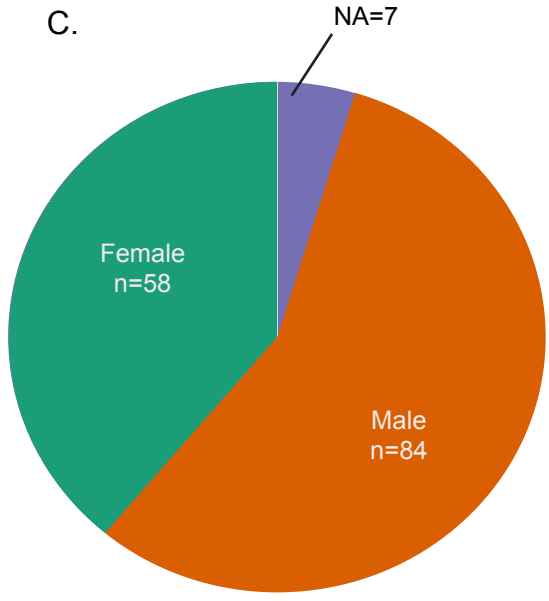

D.

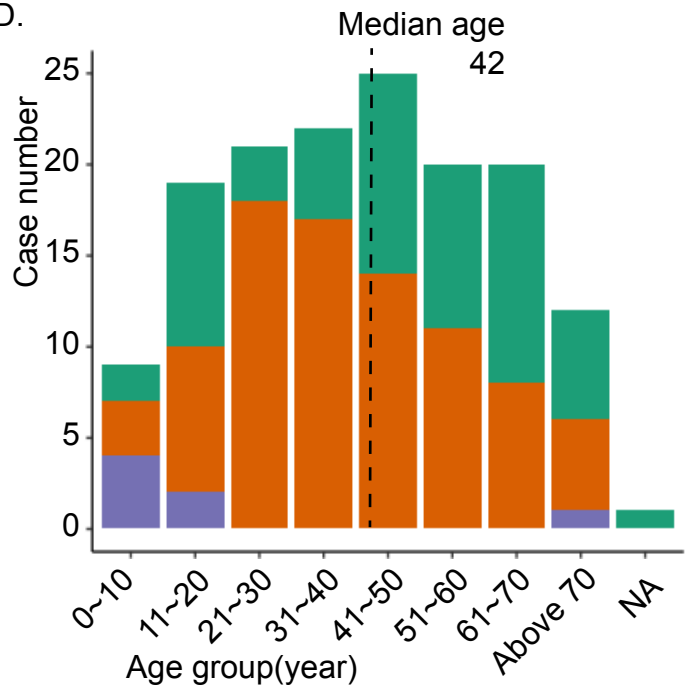

Figure 2. Gastric cancer reported in patients with inborn errors of immunity

A.

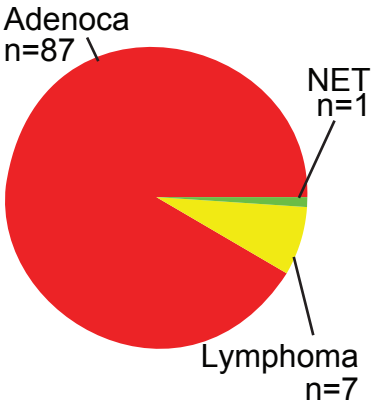

B.

	Observed	Expected*	P value	OR
Sex				
Male	53(55.8%)	62(65.1%)	0.18	0.67
Female	41(43.2%)	33(34.9%)	0.23	1.43
NA	1(1.1%)			
Age group				
0-24	14(14.7%)	0(0.1%)	0.0001	∞
25-44	31(32.6%)	3(2.9%)	3.22e-07	14.85
45-64	29(30.5%)	17(17.7%)	0.04	2.02
≥65	20(21.1%)	75(79.1%)	4.68e-15	0.07
NA	1(1.1%)			

C.

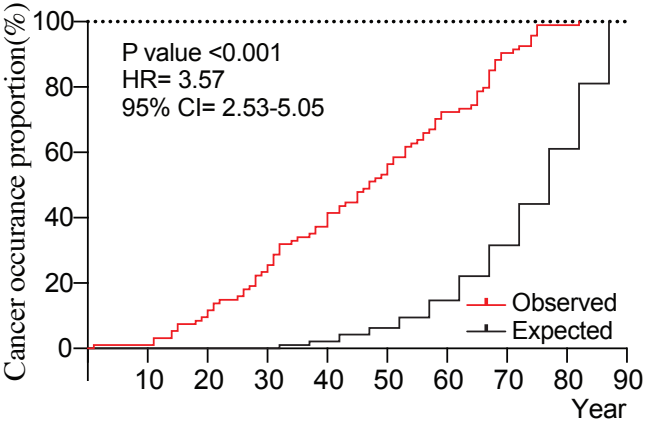

D.

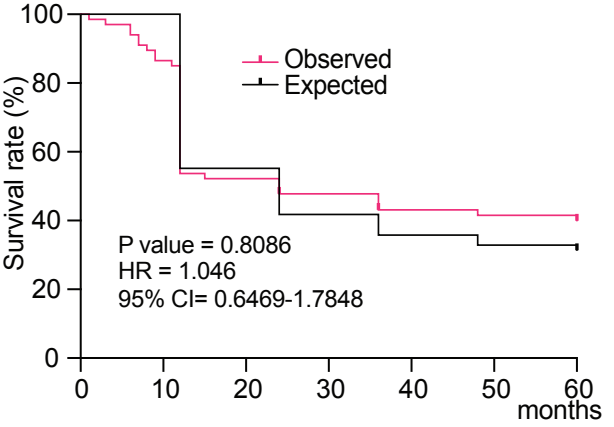

E.

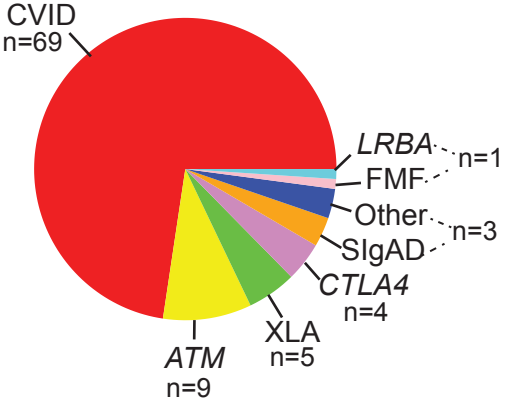

Figure 3. Colon cancer in patients with inborn errors of immunity

A.

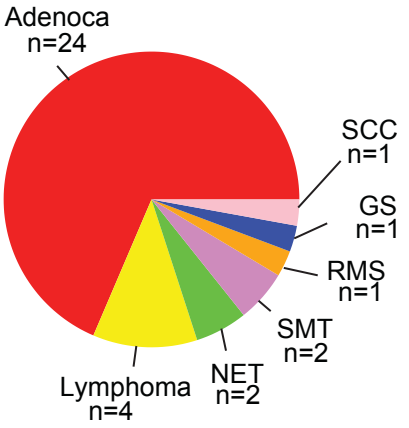

B.

	Observed	Expected*	P value	OR
Sex				
Male	21(60%)	20(56.5%)	0.81	1.13
Female	10(28.6%)	15(43.5%)	0.21	0.53
NA	4(11.4%)			
Age group				
0-24	16(45.7%)	0(0.3%)	1.96e-05	∞
25-44	9(25.7%)	1(2.7%)	0.01	11.77
45-64	7(20.0%)	6(17.0%)	0.76	1.21
≥65	3(8.6%)	28(80%)	7.70e-09	0.02

C.

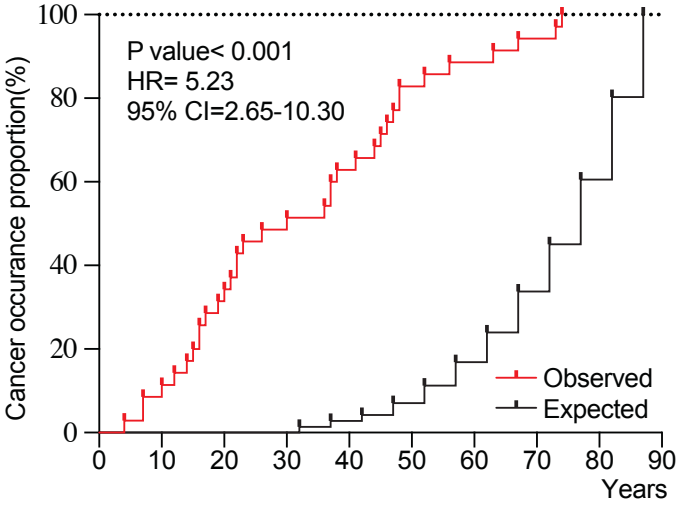

D.

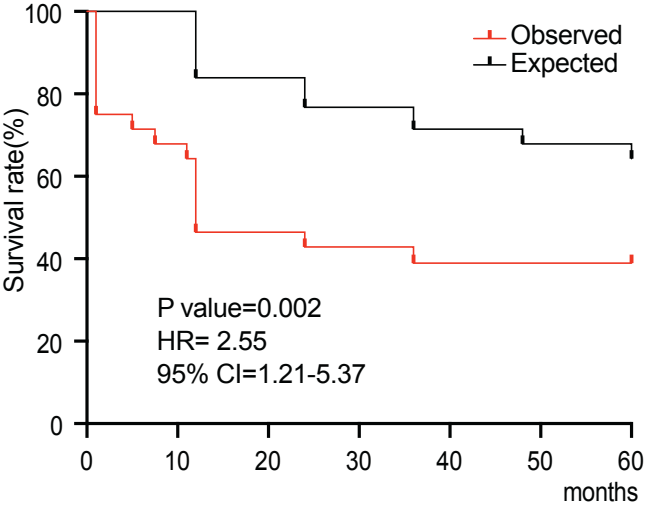
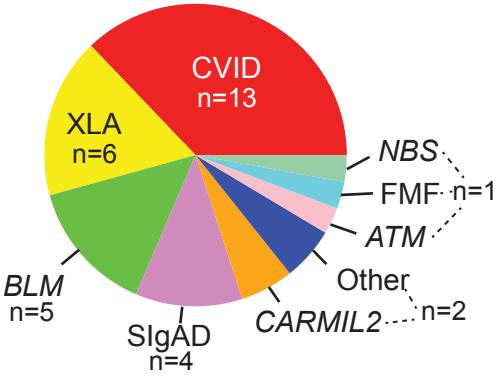
E.