Surgical interventions targeting the nucleus caudalis: a systematic review and historical perspective.

Brendan Santyr M.D.[1], Mohamad Abbass M.D.[1], Alan Chalil, M.D.[1], Amirti Vivekanandan, M.D.[1], Margaret Tindale, M.D.[2], Nicholas M. Boulis, M.D.[3], Jonathan C. Lau, M.D., Ph.D., FRCSC.[1]

[1]Division of Neurosurgery, Department of Clinical Neurological Sciences, Western University, London, Ontario, Canada.
[2]Division of Emergency Medicine, Western University, London, Ontario, Canada.
[3]Department of Neurosurgery, Emory University, Atlanta, Georgia, USA.

Conflict of interest:
The authors declare that the research was conducted in the absence of any commercial or financial relationships that could be construed as a potential conflict of interest.

Disclosure of funding:
No funding was received for the completion of this work.

Corresponding Author:
Jonathan C. Lau, M.D., Ph.D., FRCSC
Department of Clinical Neurological Sciences
University Hospital
339 Windermere Rd, London, Ontario, Canada
N6A 5A5
Tel. 519-685-8500 x33707
jonathan.lau@lhsc.on.ca

Keywords: Neurosurgery, Neuromodulation, Pain, Facial Pain, Nucleus Caudalis, Trigeminal Nucleus.

Abstract

Introduction: Chronic facial pain is a prevalent group of conditions and when refractory to common treatments poses a social and economic burden. The last decade has seen a multitude of advancements in the multimodal management of pain. Ablative or neuromodulatory interventions targeting the nucleus caudalis (NC) of the trigeminocervical complex is one such treatment that has remained underutilized.

Methods: Here we present a systematic review of the literature and historical perspective regarding interventions targeting the NC. We examine the various intervention techniques, clinical indications, and procedural efficacy. A novel outcome reporting scheme was devised to allow comparison between studies using differing outcome reporting methods.

Results: A review of the literature revealed 49 retrospective studies published over the last 80 years, reporting on 858 patients. The most common technique was the open NC dorsal root entry zone nucleotomy/tractotomy (n=515, 60.0%); however, there has been an emergence of novel approaches such as endoscopic (n=6, 0.7%) and spinal cord stimulation (n=20, 2.3%) in the last 10 years. Regardless of intervention technique or preoperative diagnosis, 90.4% of patients demonstrated some improvement from treatment.

Conclusion: This systematic review highlights recent advancements in NC intervention technique and the wide range of facial pain syndromes for which these interventions show promising efficacy. New and less invasive techniques continue to emerge, however prospective studies remain absent in the literature. Future work should address efficacy comparisons between intervention type and preoperative diagnosis.

Introduction

Refractory craniofacial pain is a heterogeneous group of disorders with multiple classification systems depending on clinical features including anatomic distribution, anatomical origin, pathology, and symptomatology.[1] The prevalence of craniofacial pain is estimated to be 26%.[2] Epidemiological studies have yet to define the social and economic burden of this complex and debilitating group of diseases, however estimates may be made from the literature on trigeminal neuralgia (TN), the best studied of the chronic craniofacial pain syndromes outside the realm of headache. TN has been reported to impact multiple health status domains including activity, mood, ambulation, work, relationships, sleep, and life enjoyment.[3] More than one-third of patients with TN had employment impacted, either through work hour reduction, disability, or unemployment.[3] Despite advancements over the past 2 decades, many TN patients remain refractory to medical and conventional surgical options.[4] Conventional surgical approaches to treat TN have targeted the nerve root and ganglion with demonstrated efficacy in treating typical paroxysmal TN type 1 pain but are relatively ineffective at treating the background pain characteristic of atypical TN type 2.[5] Worsening of constant background pain and the development of neuropathic pain can be seen with repeated treatments targeting the anterior system (distal to the nerve root).[6] Therefore, investigation into alternative surgical approaches and treatment options for these pain syndromes remains crucial adequate pain management.

Nociceptive facial sensation, temperature, and crude touch for the Vth, VIIth, IXth, and Xth cranial nerves are carried by second order neurons within the nucleus caudalis (NC) of the trigeminocervical complex.[7] Ascending connections from the trigeminal nucleus caudalis to the thalamus, hypothalamus, locus coeruleus, periaqueductal gray, and other structures involved in processing of nociceptive stimuli then modulate the perception of pain.[8] There is partial functional overlap between the C2 and C3 substantia gelatinosa and the NC, and it is this close anatomical relationship that inspired the use of dorsal root entry zone (DREZ) lesioning techniques to treat facial pain.[8]

Interruption of the trigeminocervical complex at the level of the brainstem in humans was first reported in 1938.[9] Introduced in1968, DREZ procedures for chronic pain have progressed to include various methods of lesioning, ablating, or modulating the DREZ at the spinal level of the pain, attempting to eliminate hyperactivity and spontaneous discharges that result in central perception of pain.[10–13] Favorable outcomes in DREZ operations for other pain syndromes and advancements in techniques for open and stereotactic trigeminal tractotomy helped provide motivation for NC DREZ procedures for facial pain.[14–17] Similar to standard spinal DREZ procedures that target the dorsal horn of the spine, NC DREZ operations target the spinal trigeminal nucleus pars caudalis at the cervicomedullary junction, relieving pain through destruction of the second order neurons.[10,17–19]

Although the first application of lesioning of the trigeminocervical complex dates back to the 1930s, prospective studies assessing its efficacy and indications are still lacking. Evidence supporting the use of surgical techniques targeting the NC is limited to small retrospective case reports and case series. A clear summary of the efficacy, indications, and variations in

intervention technique has yet to be reported. In the present study we performed a systematic review of the literature published regarding the surgical intervention of the NC, and also providing a historical perspective for the development of NC related interventions to the present day.

Methods

Literature Search and Inclusion Criteria

Here we conducted a systematic review according to the Preferred Reporting Items for Systematic Reviews and Meta-Analyses (PRISMA) for Protocol guidelines. Embase, MEDLINE and Cochrane central databases were queried using the search strategy indicated in Supplementary Materials 1 on May 31, 2021. The search comprised of the following search terms (combination of subject headings and keywords): “caudalis”, “trigeminal nucleus”, “trigeminal tractotomy”, “trigeminal nucleotractotomy”, “trigeminal nucleotomy”, “dorsal root entry zone”, “ablation”, “lesion”, “stimulation”, and various combinations of the above.

The search strategies were modified for each database to include database-specific thesaurus terms, syntax, and field names. Additional relevant studies that met our inclusion criteria were identified through examination of bibliographies of relevant articles and selected reviews. Conference abstracts and unpublished studies were excluded. Non-human studies, anatomical studies, descriptions and advancements in technique, studies reporting on the same patient population, reviews, and any study not reporting surgical lesioning or stimulation of the nucleus caudalis and response to treatment were excluded. Only original peer-reviewed clinical studies in humans published in the English language were included. Studies were not restricted based on age, diagnosis, or the lesioning/stimulation method.

Quality Assessment

Two reviewers (B.S., M.A.) independently screened each article title and abstract for relevance. Disagreements were resolved by discussion and consensus in the presence of a third reviewer (A.C.). All authors reviewed preliminary results and the final analysis.

Data Collection and Outcome Measures

Of the included studies, information regarding study type, study size, mean follow-up duration, lesioning technique, preoperative diagnosis, and pre- and post-operative pain rating was collected (Table 1). Postoperative pain rating was considered a primary outcome. Mean follow-up duration was collected in years following intervention. All reported preoperative diagnoses were collected and classified based on available information. Diagnosis classification included trigeminal neuralgia or neuropathic pain, oncologic facial pain, post herpetic pain, anesthesia dolorosa, traumatic facial pain, glossopharyngeal neuralgia, post-stroke facial pain, headache or migraine, multiple sclerosis related facial pain, and geniculate neuralgia. The majority of the literature failed to distinguish between different classifications or causes of facial pain, thereby necessitating the combination of these pathophysiological entities. Intervention techniques were classified into all procedural variations of open procedures targeting the NC or trigeminocervical complex, including nucleotomy, nucleotomy/tractotomy, and DREZ lesioning procedures;

computed tomography (CT) guided and free-hand percutaneous nucleotomy/tractotomy; endoscopic DREZ nucleotomy/tractotomy; cervical spinal cord stimulation (SCS); ultrasonic nucleotomy; and gamma knife radiosurgery. Information regarding surgical complications were collected. Total number of reported complications were recorded in addition to postoperative facial dysfunction (pain, numbness, weakness, corneal anesthesia, oropharyngeal dysfunction (dysarthria, dysphagia, vocal cord paralysis), ataxia, limb dysfunction (pain, numbness, weakness, dysmetria), transient dysfunction (pain, numbness, weakness, ataxia), reoperation rate, general medical complication, and mortality.

Various methods of reporting pain are present in the literature. Most commonly qualitative and non-standardized methods were used to report pain outcomes. To accommodate this and facilitate comparison, a composite rating scale was employed in this review (Table 2). A composite pain score of 1 includes patients that are pain free, Visual Analog Scale (VAS) 0, or have had a 100% pain reduction. Pain score of 2 includes those with “good” response, VAS 1-3, or a >50% pain reduction. Pain score of 3 includes those with “satisfactory” or “fair” response, VAS 4-6, or a <50% pain reduction. Finally, a pain score of 4 includes those who experienced no improvement, pain worsening, or VAS 7-10.

The fraction of patients demonstrating any symptomatic improvement post procedure (pain score of 1-3) was calculated as a percentage of the total number of subjects included in the study (Table 1). To determine the relative surgical success between intervention technique, the techniques were divided as follows: open focal lesioning techniques (nucleotomy/tractotomy), DREZ (multipoint lesioning technique), percutaneous nucleotomy/tractotomy, and neuromodulation (cervical SCS). Pain outcome distribution was then compared between each using a Chi Squared test. The fraction of patients with post procedural improvement, as a measure of relative procedural success, was assessed with respect to publication date to determine the influence of procedural modification over time (Supplemental Materals 2). This analysis was achieved using a linear model and all intervention types as well as individually for open and percutaneous procedures as these were the only procedures with an adequate number of studies. Linear models, covariance, and correlation were implemented using the R statistical language and environment and the functions lm(), var(), and cor() respectively.[20] Event rates for composite scores and complications were pooled across studies, and logit transformed with 95% confidence intervals calculated assuming a binomial distribution. This was calculated using MATLAB R2019b.[21]

Results

A total of 782 articles were identified through the literature search and underwent title and abstract review (Figure 1). Two separate reviewers (B.S. and M.A.) screened each article to meet inclusion/exclusion criteria and remove duplicates, resulting in 33 studies meeting the inclusion criteria. A review of bibliographies from relevant articles identified an additional 16 studies, thereby bringing the total of included studies to 49 eligible studies with a total of 858 subjects as summarized in Table 1. Disagreement was resolved by a third reviewer (A.C.). All identified studies for inclusion were either case reports or case series published between 1940

and 2020. No randomized or prospective trials were identified. The results of the data extraction for included studies are summarized in Table 1. The publications included in this work represent an 80-year history of techniques targeting the NC for treatment of facial pain (Figure 2). The rate of publications continues to increase over time and there are emerging techniques including endoscopic approaches and spinal cord stimulation (SCS) seen in the last 10 years (Figure 2).

Preoperative Diagnosis

Treatments targeting the nucleus caudalis have been used to ameliorate facial pain in a wide range of patient populations. Of the 858 patients included in this review, 40.4% (n=347) had a diagnosis of trigeminal neuralgia or neuropathic pain (Figure 3). Oncologic facial pain comprised 19.2% (n=165), 9.4% (n=81) had post herpetic pain, 6.1% (n=52) had anesthesia dolorosa, 5.5% (n=47) had traumatic facial pain, 3.5% (n=30) had glossopharyngeal neuralgia, 2.1% (n=18) had post-stroke facial pain, 0.9% (n=8) had headache or migraine, 0.7% (n=6) had multiple sclerosis related facial pain, 0.6% (n=5) had geniculate neuralgia, and 11.5% (n=99) had multiple diagnoses or unspecified facial pain (Figure 3).

Intervention Technique

Review of the included articles revealed 6 intervention techniques targeting the nucleus caudalis for facial pain (Figure 4). The most common approach was open NC DREZ nucleotomy/tractotomy, reported in 29 studies and comprising 60.0% of patients (n=515). CT guided and free-hand percutaneous nucleotomy/tractotomy is reported in 11 studies and 35.1% of patients (n=301). Cervical SCS is reported in 5 studies and 2.3% of patients (n=20). Ultrasonic nucleotomy is reported in one study and 1.6% of patients (n=14). Endoscopic DREZ nucleotomy/tractotomy is reported in 2 studies and 0.7% of patients (n=6). Finally, Gamma Knife radiosurgery was reported in one study and 0.2% of patients (n=2).

Open intervention techniques were further divided base on target location. Of the open procedures the most common was trigeminal tractotomy comprising 212 patients (41.2%). Multilesional DREZ procedures make up 180 patients (35.0%), trigeminal nucleotomy makes up 99 patients (19.2%), and finally combined nucleotomy and tractotomy procedures make up 24 patients (4.7%).

Treatment Outcomes

As mentioned above, various pain reporting methods are utilized in the studies reviewed. To facilitate comparison of treatment outcomes between studies, a composite pain rating scale was developed and outlined in Table 2. Briefly, post-intervention pain is divided into 4 levels of increasing pain severity (1-4) as previously described. Preoperative pain is even less consistently reported. Despite this, VAS remains the most common pain reporting scale for this cohort. Mean follow-up duration was 2.52 years. Of the 858 included patients, 150 (17.5%) have preoperative VAS reported with a mean of 8.7. Interventions targeting the NC resulted in a composite pain score of 1 (i.e., pain freedom, VAS 0, or 100% pain reduction) in 256 patients (29.8%), pain score of 2 (i.e., “good” response, VAS 1-3, or a >50% pain reduction) in 222 patients (25.9%), pain score of 3 (i.e., “satisfactory” or “fair” response, VAS 4-6, or a <50% pain reduction) in 36 patients (4.2%), pain score of 4 (i.e., no improvement, pain worsening, or VAS

7-10) in 49 patients (5.7%) (Figure 5). The treatment outcome was unknown in 295 patients (34.4%). This includes patients lost to follow-up, passed away, or inadequately reported.

Excluding the unknown outcome values, the intervention types were reclassified as open focal lesioning techniques (nucleotomy/tractotomy) (n patients = 162), open DREZ (multipoint lesioning technique) (n patients = 150), percutaneous nucleotomy/tractotomy (n patients = 231), and cervical SCS (n patients = 20) (Figure 6). Chi squared demonstrates a significant difference in the outcome distribution between the intervention types ($\chi^2(12, n = 563) = 56.3125$, $p < 0.001$) (Supplemental Material 2).

Linear regression revealed a non-significant trend towards greater fraction of patients demonstrating postoperative improvement in all interventions over the 80-year history. The correlation coefficient is 0.18, the covariance is 0.52, and p-value is 0.24 (Supplemental Materials 3). A similar trend is seen in open and percutaneous procedures individually (Supplemental Material 3). The other procedures had an inadequate number of studies to assess meaningfully.

Complications

A total of 269 complications are reported across all included articles. The proportion of individual complications per intervention type are presented in Figure 7. All complications except corneal anesthesia (n = 5) and limb dysfunction (n = 15) demonstrate a statistically significant difference in distribution between intervention types (focal lesioning techniques, DREZ, percutaneous, and neuromodulation) ($p < 0.01$) (Supplemental Material 4).

Discussion

In this study we explore emerging intervention options for the complex and heterogeneous group of refractory chronic facial pain syndromes. A systematic review of the published literature regarding the surgical interventions of the NC was performed to investigate the efficacy and indications for these procedures. The first application of lesioning of the trigeminocervical complex dates back to the 1930s[9]; however, evidence supporting its use is limited to small retrospective case series and case reports. Our review of the literature identified 49 retrospective studies reporting on 858 patients without any prospective studies. There is ongoing interest in targeting the NC for facial pain as evidenced by the 80 years of literature identified here. Despite progress made in the multimodal management of facial pain, up to 27% of patients undergoing surgical treatment have insufficiently managed pain at 5 years.[2,22] The present study demonstrates that there has been a recent increase in publication rate along these lines. Contributing to this is not only advancements in open and percutaneous techniques but also the emergence of new approaches, such as ultrasonic lesioning, radiosurgery, and SCS. However, prospective support for the use of any of these procedures is still lacking.

The studies included in this review report on multiple diagnoses resulting in chronic facial pain, including post-herpetic pain, trigeminal neuralgia or neuropathic pain, oncological pain, migraine, multiple sclerosis related facial pain, and geniculate neuralgia. A detailed description

regarding the pathophysiology of pain associated with each of these conditions is outside the scope of this review; however, common to each of these diseases is injury (compression, denervation/deafferentation, demyelination) of the general somatic afferent fibers of the Vth, VIIth, IXth, or Xth cranial nerves. These fibers synapse onto second order neurons within the descending trigeminocervical complex, which extend from the pons to the upper cervical spinal cord on the ventral surface of the brainstem.[23] Based on anatomic and clinical data, the nucleus caudalis was identified as the most important locus for modulation, integration, and conduction of nociception from craniofacial structures to higher-order intracranial structures for pain perception.[9,24–27] This provides a logical target for treatment of pain associated with injury to cranial nerves V, VII, IX, and X. Intervention techniques such as the NC DREZ nucleotomy/tractotomy utilize a small suboccipital craniectomy and C1-C2 laminectomy to elevate the cerebellar tonsils and visualize the obex. The NC occupies the triangular area between the dorsolateral sulcus and the emerging points of the accessory nerve. It tapers caudally before joining the spinal DREZ of C2. During NC DREZ nucleotomy/tractotomy multiple rostrocaudal and mediolateral lesions are made at a depth of 3-4mm covering 5mm below the obex to the upper dorsal rootlets of C2.[23]

The identified articles here also reveal progressive adaptation of intervention techniques targeting the NC. Most studies (29 studies comprising 60.0% of patients) report on the open NC DREZ nucleotomytractotomy. Open procedures in this region date back to the 1930s where Sjoqvist demonstrated that sectioning of the trigeminocervical complex at the level of the medulla above the obex resulted in ipsilateral thermoanalgesia of the face.[9] Although initially plagued by complications, a near century of surgical advancement has considerably improved its safety and efficacy, including the development of the more selective vertical trigeminal partial nucleotomy in 1965.[28] The 1970s saw the emergence of stereotactic and percutaneous targeting techniques, improving pain outcomes through patient cooperation and intraoperative monitoring of lesion-induced analgesia under local anesthetic.[15] Surgical refinement and improved anatomical understanding of the region in the 1970s and 80s resulted in specific open NC DREZ lesioning procedures gaining popularity with higher immediate success rates.[29] In recent decades a trend towards less invasive techniques is apparent, as morbidity related to injury of nearby structures of the spinal cord and medulla from open procedures remain high.[23] Endoscopic NC DREZ nucleotomy/tractotomy procedures have been developed to minimize the morbidity associated with large incisions and craniotomies.[30,31] Noninvasive techniques using ultrasound[32] and Gamma Knife radiosurgery[33] have similarly been developed. Finally, the most recent adaptation of techniques targeting the NC is in the form of spinal cord stimulation as a titratable and reversible neuromodulation of the region.[34–38]

It is clear that the techniques targeting the NC for ablation or neuromodulation represent an additional option for treatment of intractable facial pain of diverse pathophysiological origins. Despite the variations in intervention technique and preoperative diagnosis, out of all the articles reviewed that reported outcome, 90.4% demonstrated some improvement from treatment. Furthermore, 45.5% reported complete pain freedom postoperatively, demonstrating remarkable efficacy for a group of treatments typically reserved for complex and otherwise surgically and medically refractory facial pain. Although this might be an overestimation of the overall

effectiveness of these procedures due to publication bias, it is nevertheless encouraging for continued use of these procedures. Possibly also attributable to publication bias, this work demonstrates a trend towards improved clinical efficacy over time, perhaps representing an influence from progressive procedural refinement. We do demonstrate here significant differences in outcome distributions between different procedural techniques, however due to inconsistencies in outcome reporting and limited number of subjects, efficacy comparisons between intervention type or preoperative diagnosis could not be reliably made. There have been efforts in the literature to standardize pain outcome reporting, with multiple well validated pain rating scales available.[39] Here we present added evidence for the need to continually report outcomes in a way that allows for robust comparisons.

Analysis of reported complication rates demonstrates significant differences in complications between the different intervention techniques. The data support percutaneous interventions having a relatively lower rate of complications compared to others (Figure 7). These results should be interpreted cautiously as they are certainly confounded by publication bias, inadequacies in complete reporting of complications, and limited duration of follow-up (2.52 years). Ideally, future prospective trials can address such lingering questions directly.

As mentioned above the limitations encountered are an insufficient quantity of studies, a lack of prospective studies, and inadequate reporting to make outcome comparisons between intervention types and diagnosis possible. Historical studies, as encountered in this work, particularly suffer from lack of access to modern outcome reporting schemes and classification systems, for example contemporary classification of trigeminal neuralgia and differentiating trigeminal neuropathic pain could not be done here. Furthermore, heterogeneity of included studies with respect to intervention, diagnosis, and outcome reporting measures necessitated grouping all these factors together and creating a custom post-procedural pain reporting scale. This may limit the strength of efficacy conclusions; however, it does contribute greatly to the generalizability of the included results. Additionally, information regarding follow-up and treatment outcome durability is almost universally lacking among included articles and 34.4% of patients are without reported outcome data. Finally, limited access to historic reports and English language inclusion criteria remains a barrier to accurate representation.

Conclusion

This review summarizes 80 years of literature regarding interventions targeting the NC for chronic refractory facial pain. It highlights recent advancements in intervention technique and the wide range of facial pain syndromes for which these interventions show promising efficacy. New and less invasive techniques continue to emerge, however prospective studies remain absent in the literature. Additional studies addressing efficacy comparisons between intervention type or preoperative diagnosis would help solidify these techniques in the armamentarium of facial pain treatments.

References

1. Zakrzewska JM. Facial pain: neurological and non-neurological. *Journal of neurology, neurosurgery, and psychiatry*. 2002;72 Suppl 2:ii27-ii32. doi:10.1136/jnnp.72.suppl_2.ii27
2. Macfarlane T v., Blinkhorn AS, Davies RM, Kincey J, Worthington H v. Oro-facial pain in the community: prevalence and associated impact. *Community Dentistry and Oral Epidemiology*. 2002;30(1):52-60. doi:10.1034/J.1600-0528.2002.300108.X
3. Tolle T, Dukes E, Sadosky A. Patient Burden of Trigeminal Neuralgia: Results from a Cross-Sectional Survey of Health State Impairment and Treatment Patterns in Six European Countries. *Pain Practice*. 2006;6(3):153-160. doi:10.1111/j.1533-2500.2006.00079.x
4. Cruccu G, Aziz TZ, Garcia-Larrea L, et al. EFNS guidelines on neurostimulation therapy for neuropathic pain. *European Journal of Neurology*. 2007;14(9):952-970. http://ovidsp.ovid.com/ovidweb.cgi?T=JS&CSC=Y&NEWS=N&PAGE=fulltext&D=emed10&AN=47300786
5. Tyler-Kabara EC, Kassam AB, Horowitz MH, et al. Predictors of outcome in surgically managed patients with typical and atypical trigeminal neuralgia: comparison of results following microvascular decompression. *Journal of Neurosurgery*. 2002;96(3):527-531. doi:10.3171/jns.2002.96.3.0527
6. Broggi G, Ferroli P, Franzini A, Galosi L. The role of surgery in the treatment of typical and atypical facial pain. *Neurological Sciences*. 2005;26(SUPPL. 2). doi:10.1007/s10072-005-0418-5
7. Bullard DE, Nashold Jr. BS. The caudalis DREZ for facial pain. *Stereotactic & Functional Neurosurgery*. 1997;68(1-4 Pt 1):168-174. http://ovidsp.ovid.com/ovidweb.cgi?T=JS&CSC=Y&NEWS=N&PAGE=fulltext&D=med4&AN=9711711
8. Goadsby PJ, Holland PR, Martins-Oliveira M, Hoffmann J, Schankin C, Akerman S. Pathophysiology of Migraine: A Disorder of Sensory Processing. *Physiological Reviews*. 2017;97(2):553. doi:10.1152/PHYSREV.00034.2015
9. SJOQVIST, O. Studies of pain conduction in the trigeminal nerve. *Act Psychiat Neurol Scand Suppl*. 1938;17:1-139. Accessed October 26, 2021. https://ci.nii.ac.jp/naid/10008988203
10. Loeser JD, Ward AA, White LE. Chronic Deafferentation of Human Spinal Cord Neurons. *Journal of Neurosurgery*. 1968;29(1):48-50. doi:10.3171/JNS.1968.29.1.0048
11. Guenot M, Bullier J, Rospars JP, Lansky P, Mertens P, Sindou M. Single-Unit Analysis of the Spinal Dorsal Horn in Patients With Neuropathic Pain. *Journal of Clinical Neurophysiology*. 2003;20(2):143-150. doi:10.1097/00004691-200304000-00009
12. Sindou M. Drez lesions for brachial plexus injury. *Neurosurgery*. 1988;23(4):528. doi:10.1097/00006123-198810000-00025
13. Drake CG, Stavraky GW. AN EXTENSION OF THE “LAW OF DENERVATION” TO AFFERENT NEURONES. *Journal of Neurophysiology*. 1948;11(3):229-238. doi:10.1152/jn.1948.11.3.229
14. MCKENZIE KG. Trigeminal tractotomy. *Clinical neurosurgery*. 1954;2:50-69; discussion, 69-70. Accessed October 26, 2021. http://www.ncbi.nlm.nih.gov/pubmed/13270405

15. Hitchcock ER, Schvarcz JR. Stereotaxic trigeminal tractotomy for post-herpetic facial pain. *Journal of Neurosurgery*. 1972;37(4):412-417. doi:10.3171/JNS.1972.37.4.0412
16. Schvarcz JR. Spinal Cord Stereotactic Techniques re Trigeminal Nucleotomy and Extralemniscal Myelotomy. *Stereotactic and Functional Neurosurgery*. 1978;41(1-4):99-112. doi:10.1159/000102406
17. Gorecki JP, Nashold Jr. BS, Rubin L, Ovelmen-Levitt J. The Duke experience with nucleus caudalis DREZ coagulation. *Stereotactic & Functional Neurosurgery*. 1995;65(1-4):111-116. http://ovidsp.ovid.com/ovidweb.cgi?T=JS&CSC=Y&NEWS=N&PAGE=fulltext&D=med3&AN=8916338
18. Anderson LS, Black RG, Abraham J, Ward AA. Neuronal hyperactivity in experimental trigeminal deafferentation. *Journal of Neurosurgery*. 1971;35(4):444-452. doi:10.3171/JNS.1971.35.4.0444
19. Bernard Jr EJ, Nashold Jr BS, Caputi F, Moossy JJ. Nucleus caudalis DREZ lesions for facial pain. *British Journal of Neurosurgery*. 1987;1(1):81-92. http://ovidsp.ovid.com/ovidweb.cgi?T=JS&CSC=Y&NEWS=N&PAGE=fulltext&D=emed3&AN=18068984
20. Bunn A, Korpela M. R: A language and environment for statistical computing. Published online 2013. doi:10.1016/j.dendro.2008.01.002
21. Lau JC, Kosteniuk SE, Walker T, Iansavichene A, Macdonald DR, Megyesi JF. Operative Complications with and without Image Guidance: A Systematic Review and Meta-Analysis of the Ommaya Reservoir Literature. *World Neurosurgery*. 2019;122:404-414. doi:10.1016/j.wneu.2018.11.036
22. Al-Quliti KW. Update on neuropathic pain treatment for trigeminal neuralgia. *Neurosciences*. 2015;20(2):107-114. doi:10.17712/nsj.2015.2.20140501
23. Teixeira MJ, Fonoff ET. Technique of Trigeminal Nucleotractotomy. *Textbook of Stereotactic and Functional Neurosurgery*. Published online 2009:2097-2123. doi:10.1007/978-3-540-69960-6_124
24. Hu JW, Sessle BJ. Trigeminal nociceptive and non-nociceptive neurones: brain stem intranuclear projections and modulation by orofacial, periaqueductal gray and nucleus raphe magnus stimuli. *Brain Research*. 1979;170(3):547-552. doi:10.1016/0006-8993(79)90973-9
25. Hosobuchi Y, Rutkin B. Descending trigeminal tractotomy. Neurophysiological approach. *Archives of neurology*. 1971;25(2):115-125. doi:10.1001/ARCHNEUR.1971.00490020033004
26. Wall PD, Taub A. FOUR ASPECTS OF TRIGEMINAL NUCLEUS AND A PARADOX. *Journal of Neurophysiology*. 1962;25(1):110-126. doi:10.1152/jn.1962.25.1.110
27. Broton JG, Rosenfeld JP. Rostral trigeminal projections signal perioral facial pain. *Brain Research*. 1982;243(2):395-400. doi:10.1016/0006-8993(82)90269-4
28. Kunc Z. Treatment of Essential Neuralgia of the 9th Nerve by Selective Tractotomy. *Journal of Neurosurgery*. 1965;23(5):494-500. doi:10.3171/jns.1965.23.5.0494
29. Bernard Jr EJ, Nashold Jr BS, Caputi F. Clinical review of nucleus caudalis dorsal root entry zone lesions for facial pain. *Applied Neurophysiology*. 1988;51(2-5):218-224.

http://ovidsp.ovid.com/ovidweb.cgi?T=JS&CSC=Y&NEWS=N&PAGE=fulltext&D=emed4&AN=18121840

30. Teixeira MJ, de Almeida FF, de Oliveira YS, Fonoff ET. Microendoscopic stereotactic-guided percutaneous radiofrequency trigeminal nucleotractotomy. *Journal of Neurosurgery*. 2012;116(2):331-335. http://ovidsp.ovid.com/ovidweb.cgi?T=JS&CSC=Y&NEWS=N&PAGE=fulltext&D=med9&AN=21999320

31. Rahimpour S, Patel V. Endoscopic trigeminal nucleus caudalis doral root entry zone lesioning for atypical facial pain. *Clinical Neurosurgery*. 2015;62 (Supplement 1):205. http://ovidsp.ovid.com/ovidweb.cgi?T=JS&CSC=Y&NEWS=N&PAGE=fulltext&D=emed16&AN=624269046

32. Grigoryan Yu A, Slavin K v, Ogleznev Ky. Ultrasonic lesion of the trigeminal nucleus caudalis for deafferentation facial pain. *Acta Neurochirurgica*. 1994;131(3-4):229-235. http://ovidsp.ovid.com/ovidweb.cgi?T=JS&CSC=Y&NEWS=N&PAGE=fulltext&D=med3&AN=7754827

33. Chang JW, Choi JY, Yoon Y, Park YG, Chung SS. Unusual causes of trigeminal neuralgia treated by gamma knife radiosurgery. Report of two cases. *Journal of Neurosurgery*. 2002;97(5 Suppl):533-535. http://ovidsp.ovid.com/ovidweb.cgi?T=JS&CSC=Y&NEWS=N&PAGE=fulltext&D=med4&AN=12507091

34. Yearwood TL, Venkatesan L, Harrell CC. Resolution of primary cervicogenic headache with sub-perception active recharge spinal cord stimulation (10721). *Neuromodulation*. 2016;19 (3):e150. http://ovidsp.ovid.com/ovidweb.cgi?T=JS&CSC=Y&NEWS=N&PAGE=fulltext&D=emed17&AN=72286353

35. Richter B, Tomycz ND, Patterson M. C1 retrograde spinal cord stimulation for trigeminal deafferentation pain. case study with long-term follow-up. *Neuromodulation*. 2017;20 (7):e165. http://ovidsp.ovid.com/ovidweb.cgi?T=JS&CSC=Y&NEWS=N&PAGE=fulltext&D=emed18&AN=619001349

36. Patel K v, Lohani M. “Paresthesia-free relief: Higher frequency stimulation of high cervical leads for patients with chronic facial pain.” *Neuromodulation*. 2018;21 (3):e28. http://ovidsp.ovid.com/ovidweb.cgi?T=JS&CSC=Y&NEWS=N&PAGE=fulltext&D=emed19&AN=621997721

37. Velásquez C, Tambirajoo K, Franceschini P, Eldridge PR, Farah JO. Upper Cervical Spinal Cord Stimulation as an Alternative Treatment in Trigeminal Neuropathy. *World Neurosurgery*. 2018;114:e641-e646. doi:10.1016/j.wneu.2018.03.044

38. Jones MR, Rosenow JM. Importance of Laterality in Cervical Spinal Cord Stimulation for Facial Pain: Case Report and Anatomic Review. *Operative Neurosurgery*. 2020;19(1):E83-E86. doi:10.1093/ons/opz381

39. Younger J, McCue R, Mackey S. Pain outcomes: A brief review of instruments and techniques. *Current Pain and Headache Reports*. 2009;13(1):39-43. doi:10.1007/s11916-009-0009-x

40. Grant F, Groff R, FH Lewy. Section of the descending spinal root of the fifth cranial nerve. *Archives of Neurology & Psychiatry*. Published online 1940. Accessed November 1, 2021. https://jamanetwork.com/journals/archneurpsyc/article-abstract/648387?casa_token=F6XWxXw0YTsAAAAA:vlIlZs5646NFijw8tywI9eJce9dlhZnwCtw74NXCQeT-zWpvuK6P9Fq0C9jj1YvNMdU2gCKoFw
41. GRANT FC. EXPERIENCES WITH INTRAMEDULLARY TRACTOTOMY. *Archives of Surgery*. 1941;42(4):681. doi:10.1001/archsurg.1941.01210100041004
42. OLIVECRONA H. TRACTOTOMY FOR RELIEF OF TRIGEMINAL NEURALGIA. *Archives of Neurology And Psychiatry*. 1942;47(4):544. doi:10.1001/archneurpsyc.1942.02290040034002
43. HAMBY W, SHINNERS B, MARSH I. Trigeminal tractotomy: Observations on forty-eight cases. *Archives of Surgery*. Published online 1948. Accessed November 2, 2021. https://jamanetwork.com/journals/jamasurgery/article-abstract/548105?casa_token=el4PG2XRRbIAAAAA:hB4eu_aqNL5sx8FJPrzDmRJXeH-_dvqeNBbFA8m8j1U-36GlVO2cLrXqReFcBMgG6j0ua-0_-g
44. Falconer MA. INTRAMEDULLARY TRIGEMINAL TRACTOTOMY AND ITS PLACE IN THE TREATMENT OF FACIAL PAIN. *Journal of Neurology, Neurosurgery, and Psychiatry*. 1949;12(4):297. doi:10.1136/JNNP.12.4.297
45. Guidetti B. Tractotomy for the Relief of Trigeminal Neuralgia: Observations in 124 Cases. *Journal of Neurosurgery*. 1950;7(6):499-508. doi:10.3171/JNS.1950.7.6.0499
46. Raney R, Raney AA, Hunter CR. Treatment of major trigeminal neuralgia through section of the trigeminospinal tract in the medulla. *The American Journal of Surgery*. 1950;80(1):11-17. doi:10.1016/0002-9610(50)90550-2
47. Todd EM, Crue BL, Carregal EJA. Posterior Percutaneous Tractotomy and Cordotomy. *Stereotactic and Functional Neurosurgery*. 1969;31(1-2):106-115. doi:10.1159/000103470
48. Fox JL. Intractable Facial Pain Relieved by Percutaneous Trigeminal Tractotomy. *JAMA: The Journal of the American Medical Association*. 1971;218(13):1940. doi:10.1001/jama.1971.03190260054019
49. Crue BL, Carregal EJA, Felsoory A. Percutaneous Stereotactic Radiofrequency Trigeminal Tractotomy with Neurophysiological Recordings1. *Confin neurol*. 1972;34:389-397.
50. Fox JL. Percutaneous trigeminal tractotomy for facial pain. *Acta Neurochirurgica*. 1973;29(1-2):83-88. doi:10.1007/BF01414619
51. Hitchcock E, Teixeira MJ. Pontine stereotactic surgery and facial nociception. *Neurological Research*. 1987;9(2):113-117. http://ovidsp.ovid.com/ovidweb.cgi?T=JS&CSC=Y&NEWS=N&PAGE=fulltext&D=med2&AN=2886939
52. Plangger CA, Fischer J, Grunert V, Mohsenipour I. Tractotomy and partial vertical nucleotomy--for treatment of special forms of trigeminal neuralgia and cancer pain of face and neck. *Acta Neurochirurgica - Supplementum*. 1987;39:147-150. http://ovidsp.ovid.com/ovidweb.cgi?T=JS&CSC=Y&NEWS=N&PAGE=fulltext&D=med2&AN=3478977

53. Ishijima B, Shimoji K, Shimizu H, Takahashi H, Suzuki I. Lesions of spinal and trigeminal dorsal root entry zone for deafferentation pain. Experience of 35 cases. *Applied Neurophysiology*. 1988;51(2-5):175-187. http://ovidsp.ovid.com/ovidweb.cgi?T=JS&CSC=Y&NEWS=N&PAGE=fulltext&D=med3&AN=3389794

54. Rossitch Jr. E, Zeidman SM, Nashold Jr. BS. Nucleus caudalis DREZ for facial pain due to cancer. *British Journal of Neurosurgery*. 1989;3(1):45-49. http://ovidsp.ovid.com/ovidweb.cgi?T=JS&CSC=Y&NEWS=N&PAGE=fulltext&D=med3&AN=2789713

55. Young JN, Nashold Jr. BS, Cosman ER. A new insulated caudalis nucleus DREZ electrode. Technical note. *Journal of Neurosurgery*. 1989;70(2):283-284. http://ovidsp.ovid.com/ovidweb.cgi?T=JS&CSC=Y&NEWS=N&PAGE=fulltext&D=med3&AN=2913226

56. Spiegelmann R, Friedman WA, Ballinger WE, Tedeschi H. Anatomic examination of a case of open trigeminal nucleotomy (nucleus caudalis dorsal root entry zone lesions) for facial pain. *Stereotactic & Functional Neurosurgery*. 1991;56(3):166-178. http://ovidsp.ovid.com/ovidweb.cgi?T=JS&CSC=Y&NEWS=N&PAGE=fulltext&D=med3&AN=1796221

57. Morita M, Hosobuchi Y. Descending Trigeminal Tractotomy for Trigeminal Neuralgia after Surgical Failure. *Stereotactic and Functional Neurosurgery*. 1992;59(1-4):52-55. doi:10.1159/000098917

58. Sampson JH, Nashold Jr. BS. Facial pain due to vascular lesions of the brain stem relieved by dorsal root entry zone lesions in the nucleus caudalis. Report of two cases. *Journal of Neurosurgery*. 1992;77(3):473-475. http://ovidsp.ovid.com/ovidweb.cgi?T=JS&CSC=Y&NEWS=N&PAGE=fulltext&D=med3&AN=1506898

59. Nashold BS, El-Naggar AO, Ovelmen-Levitt J, Abdul-Hak M. A new design of radiofrequency lesion electrodes for use in the caudalis nucleus DREZ operation. *Journal of Neurosurgery*. 1994;80(6):1116-1120. doi:10.3171/jns.1994.80.6.1116

60. Kanpolat Y, Cosman ER. Special Radiofrequency Electrode System for Computed Tomography-guided Pain-relieving Procedures. *Neurosurgery*. 1996;38(3):600-603. doi:10.1097/00006123-199603000-00040

61. Husain AM, Elliott SL, Gorecki JP, et al. Neurophysiological monitoring for the nucleus caudalis dorsal root entry zone operation. *Neurosurgery*. 2002;50(4):822-828. http://ovidsp.ovid.com/ovidweb.cgi?T=JS&CSC=Y&NEWS=N&PAGE=fulltext&D=emed7&AN=36322808

62. Delgado-Lopez P, Garcia-Salazar F, Mateo-Sierra O, Carrillo-Yague R, Llaurado G, Lopez E. Trigeminal nucleus caudalis dorsal root entry zone radiofrequency thermocoagulation for invalidating facial pain. *Neurocirugia (Asturias, Spain)*. 2003;14(1):25-32; discussion 32. http://ovidsp.ovid.com/ovidweb.cgi?T=JS&CSC=Y&NEWS=N&PAGE=fulltext&D=med5&AN=12655381

63. Teixeira MJ, Lepski G, Aguiar PHP, Cescato VAS, Rogano L, Alaminos AB. Bulbar Trigeminal Stereotactic Nucleotractotomy for Treatment of Facial Pain. *Stereotactic and Functional Neurosurgery*. 2003;81(1-4):37-42. doi:10.1159/000075102
64. Teixeira MJ, Fonoff ET, Montenegro MC. Dorsal root entry zone lesions for treatment of pain-related to radiation-induced plexopathy. *Spine*. 2007;32(10):E316-E319. http://ovidsp.ovid.com/ovidweb.cgi?T=JS&CSC=Y&NEWS=N&PAGE=fulltext&D=emed10&AN=46686000
65. Kanpolat Y, Kahilogullari G, Ugur HC, Elhan AH. Computed tomography-guided percutaneous trigeminal tractotomy-nucleotomy. *Neurosurgery*. 2008;63(1 SUPPL.). doi:10.1227/01.NEU.0000320139.27501.69
66. Kanpolat Y, Tuna H, Bozkurt M, Elhan AH. Spinal and nucleus caudalis dorsal root entry zone operations for chronic pain. *Neurosurgery*. 2008;62(3 Suppl 1):235-242; discussion 242-4. http://ovidsp.ovid.com/ovidweb.cgi?T=JS&CSC=Y&NEWS=N&PAGE=fulltext&D=med7&AN=18424991
67. Raslan AM. Percutaneous computed tomography-guided radiofrequency ablation of upper spinal cord pain pathways for cancer-related pain. *Neurosurgery*. 2008;62(3 SUPPL. 1):ONS226-ONS233. http://ovidsp.ovid.com/ovidweb.cgi?T=JS&CSC=Y&NEWS=N&PAGE=fulltext&D=emed10&AN=351572640
68. Samreen N, Friedman WA. Nucleus caudalis dorsal root entry zone lesions: a clinical-radiographic case report. *Stereotactic & Functional Neurosurgery*. 2009;87(5):314-321. http://ovidsp.ovid.com/ovidweb.cgi?T=JS&CSC=Y&NEWS=N&PAGE=fulltext&D=med7&AN=19713731
69. Sandwell SE, El-Naggar AO. Nucleus caudalis dorsal root entry zone lesioning for the treatment of anesthesia dolorosa. *Journal of Neurosurgery*. 2013;118(3):534-538. http://ovidsp.ovid.com/ovidweb.cgi?T=JS&CSC=Y&NEWS=N&PAGE=fulltext&D=med10&AN=23240704
70. Thompson EM, Burchiel KJ, Raslan AM. Percutaneous trigeminal tractotomy-nucleotomy with use of intraoperative computed tomography and general anesthesia: report of 2 cases. *Neurosurgical focus*. 2013;35(3):E5. http://ovidsp.ovid.com/ovidweb.cgi?T=JS&CSC=Y&NEWS=N&PAGE=fulltext&D=emed14&AN=603362808
71. Chivukula S, Tempel ZJ, Chen CJ, Shin SS, Gande A v, Moossy JJ. Spinal and Nucleus Caudalis Dorsal Root Entry Zone Lesioning for Chronic Pain: Efficacy and Outcomes. *World Neurosurgery*. 2015;84(2):494-504. http://ovidsp.ovid.com/ovidweb.cgi?T=JS&CSC=Y&NEWS=N&PAGE=fulltext&D=med12&AN=25900792
72. Kanpolat Y, Al-Beyati E, Yakupoglu H. Staged Bilateral Nucleus Caudalis DREZ Lesioning for Persistent Idiopathic Facial Pain: Exceptional Case Report. *Turkish neurosurgery*. 2017;27(2):316-320. http://ovidsp.ovid.com/ovidweb.cgi?T=JS&CSC=Y&NEWS=N&PAGE=fulltext&D=med14&AN=27349397

Table 1: Summary of articles reporting interventions targeting the nucleus caudalis for facial pain.

Author (year)	Patients, #	Diagnoses (n)	Intervention Technique	Fraction of patients improved
Grant (1940)[40]	12	TN (4) Oncologic (8)	Open DREZ nucleotomy/tractotomy	100%
Grant (1941)[41]	17	TN (6) Oncologic (11)	Open DREZ nucleotomy/tractotomy	88%
Olivecrona (1942)[42]	34	TN (34)	Open DREZ nucleotomy/tractotomy	91%
Hamby (1948)[43]	48	TN (35) Oncologic (13)	Open DREZ nucleotomy/tractotomy	67%
Falconer (1949)[44]	20	TN (13) Postherpetic (4) Anesthesia Dolorosa (2) Not specified (1)	Open DREZ nucleotomy/tractotomy	84%
Guidetti (1950)[45]	97	TN (97)	Open DREZ nucleotomy/tractotomy	Not reported
Raney (1950)[46]	59	TN (59)	Open DREZ nucleotomy/tractotomy	62%
Kunc (1965)[28]	6	Glossopharyngeal Neuralgia (6)	Open DREZ nucleotomy/tractotomy	100%
Todd (1969)[47]	3	TN (3)	Percutaneous nucleotomy/tractotomy	100%
Fox (1971)[48]	12	TN (1) Oncologic (7) Postherpetic (2) Anesthesia Dolorosa (2)	Percutaneous nucleotomy/tractotomy	67%
Hosobuchi (1971)[25]	6	TN (1) Oncologic (3) Anesthesia Dolorosa (1) Not specified (1)	Open DREZ nucleotomy/tractotomy	100%
Crue (1972)[49]	12	TN (4) Oncologic (8)	Percutaneous nucleotomy/tractotomy	100%
Hitchcock (1972)[15]	3	Postherpetic (3)	Open DREZ nucleotomy/tractotomy	100%
Fox (1973)[50]	18	Oncologic (14) Postherpetic (2) Anesthesia Dolorosa (1) Not specified (1)	Percutaneous nucleotomy/tractotomy	61%
Schvarcz (1978)[16]	100	TN (19) Oncologic (31) Trauma (25)	Percutaneous nucleotomy/tractotomy	77%

		Anesthesia Dolorosa (14) Postherpetic (8) Glossopharyngeal Neuralgia (2) MS (1)		
Hitchcock (1987)[51]	4	Not specified (4)	Open DREZ nucleotomy/tractotomy	75%
Plangger (1987)[52]	20	TN (12) Oncologic (6) Postherpetic (1) Anesthesia Dolorosa (1)	Open DREZ nucleotomy/tractotomy	100%
Bernard Jr. (1988)[29]	27	Not specified (27)	Open DREZ nucleotomy/tractotomy	95%
Ishijima (1988)[53]	4	Postherpetic (4)	Open DREZ nucleotomy/tractotomy	100%
Rossitch Jr. (1989)[54]	5	Oncologic (5)	Open DREZ nucleotomy/tractotomy	100%
Young (1989)[55]	9	Not specified (9)	Open DREZ nucleotomy/tractotomy	Not reported
Spiegelmann (1991)[56]	2	Postherpetic (1) Anesthesia Dolorosa (1)	Open DREZ nucleotomy/tractotomy	100%
Morita (1992)[57]	7	TN (7)	Open DREZ nucleotomy/tractotomy	100%
Sampson (1992)[58]	2	Post Stroke (2)	Open DREZ nucleotomy/tractotomy	100%
Grigoryan (1994)[32]	14	Oncologic (10) Postherpetic (4)	Ultrasonic nucleotomy	93%
Nashold Jr. (1994)[59]	21	TN (8) Oncologic (1) Postherpetic (5) Anesthesia Dolorosa (1) Traumatic (1) Post Stroke (3) MS (1) Headache (1)	Open DREZ nucleotomy/tractotomy	57%
Gorecki (1995)[17]	46	Oncologic (1) Postherpetic (8) Anesthesia Dolorosa (15) Post Stroke (5) MS (1) Headache (4) Not specified (12)	Open DREZ nucleotomy/tractotomy	83%
Kanpolat (1996)[60]	19	TN (14) Oncologic (5)	Percutaneous nucleotomy/tractotomy	Not reported
Bullard (1997)[7]	25	TN (8) Oncologic (1)	Open DREZ nucleotomy/tractotomy	100%

		Postherpetic (1) Anesthesia Dolorosa (3) Traumatic (4) Post Stroke (1) MS (3) Not specified (4)		
Chang (2002)[33]	2	TN (2)	Gamma Knife Radiosurgery	100%
Husain (2002)[61]	5	Postherpetic (1) Traumatic (2) Headache (1) Not specified (1)	Open DREZ nucleotomy/tractotomy	80%
Delgado-Lopez (2003)[62]	6	Anesthesia Dolorosa (6)	Open DREZ nucleotomy/tractotomy	83%
Teixeira (2003)[63]	58	TN (2) Postherpetic (28) Oncologic (14) Post Stroke (7) Not specified (7)	Percutaneous nucleotomy/tractotomy	90%
Teixeira (2007)[64]	2	Anesthesia Dolorosa (2)	Percutaneous nucleotomy/tractotomy	100%
Kanpolat (2008a)[65]	65	TN (5) Oncologic (13) Postherpetic (3) Anesthesia Dolorosa (1) Glossopharyngeal Neuralgia (17) Geniculate Neuralgia (4) Headache (1) Not specified (21)	Percutaneous nucleotomy/tractotomy	95%
Kanpolat (2008b)[66]	11	TN (5) Oncologic (3) Glossopharyngeal Neuralgia (2) Geniculate Neuralgia (1)	Open DREZ nucleotomy/tractotomy	73%
Raslan (2008)[67]	10	Oncologic (10)	Percutaneous nucleotomy/tractotomy	80%
Samreen (2009)[68]	1	Postherpetic (1)	Open DREZ nucleotomy/tractotomy	100%
Teixeira (2012)[30]	1	Postherpetic (1)	Endoscopic DREZ nucleotomy/tractotomy	100%
Sandwell (2013)[69]	1	Anesthesia Dolorosa (1)	Open DREZ nucleotomy/tractotomy	100%
Thompson (2013)[70]	2	Postherpetic (1) Anesthesia Dolorosa (1)	Percutaneous nucleotomy/tractotomy	100%
Chivukula	16	TN (9)	Open DREZ	100%

(2015)[71]		Postherpetic (3) Glossopharyngeal Neuralgia (3) Traumatic (1)	nucleotomy/tractotomy	
Rahimpour (2015)[31]	5	Not specified (5)	Endoscopic DREZ nucleotomy/tractotomy	80%
Yearwood (2016)[34]	1	Headache (1)	Cervical SCS	100%
Kanpolat (2017)[72]	1	Not specified (1)	Open DREZ nucleotomy/tractotomy	100%
Richter (2017)[35]	1	TN (1)	Cervical SCS	100%
Patel (2018)[36]	5	Not specified (5)	Cervical SCS	100%
Velasquez (2018)[37]	12	Traumatic (12)	Cervical SCS	75%
Jones (2020)[38]	1	Traumatic (1)	Cervical SCS	100%

Abbreviations: DREZ, dorsal root entry zone; MS; multiple sclerosis; SCS, spinal cord stimulation; TN, Trigeminal Neuralgia/neuropathic pain.

Table 2: Composite pain reporting scale.

Composite pain score	Description
1	Pain free, VAS 0, 100% pain reduction
2	“Good” response, VAS 1-3, >50% pain reduction
3	“Satisfactory” or “fair” response, VAS 4-6, <50% pain reduction
4	No improvement, pain worsening, VAS 7-10

Abbreviations: VAS, visual analog scale.

Figure 1: Schematic outlining article selection.

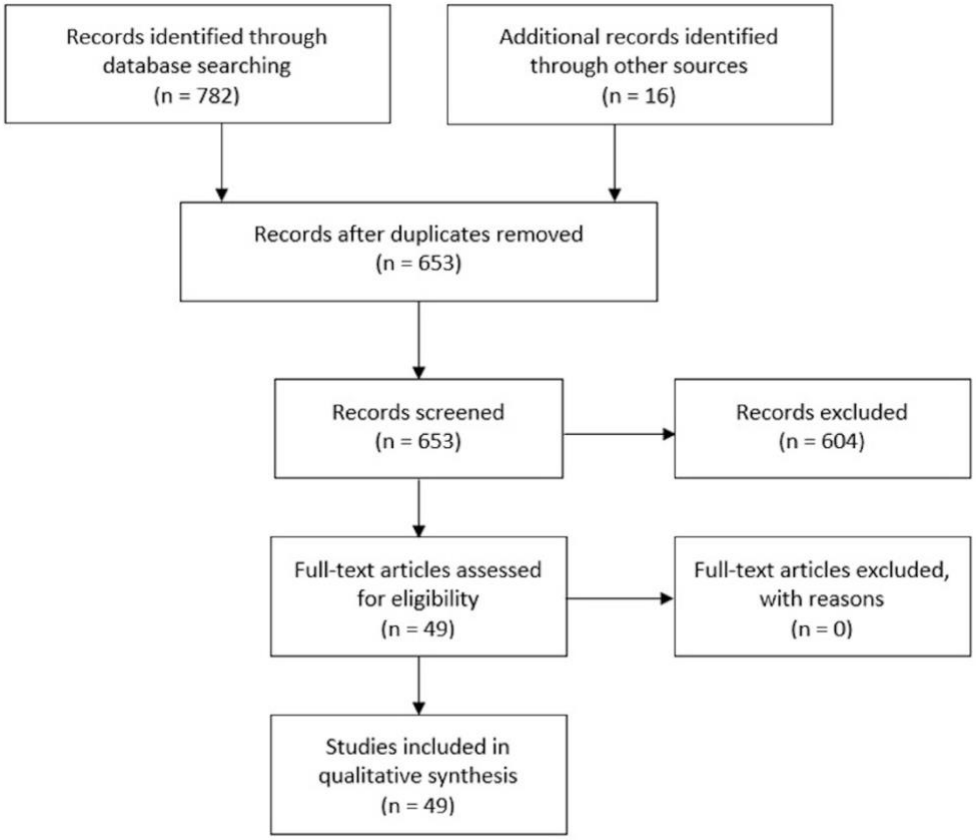

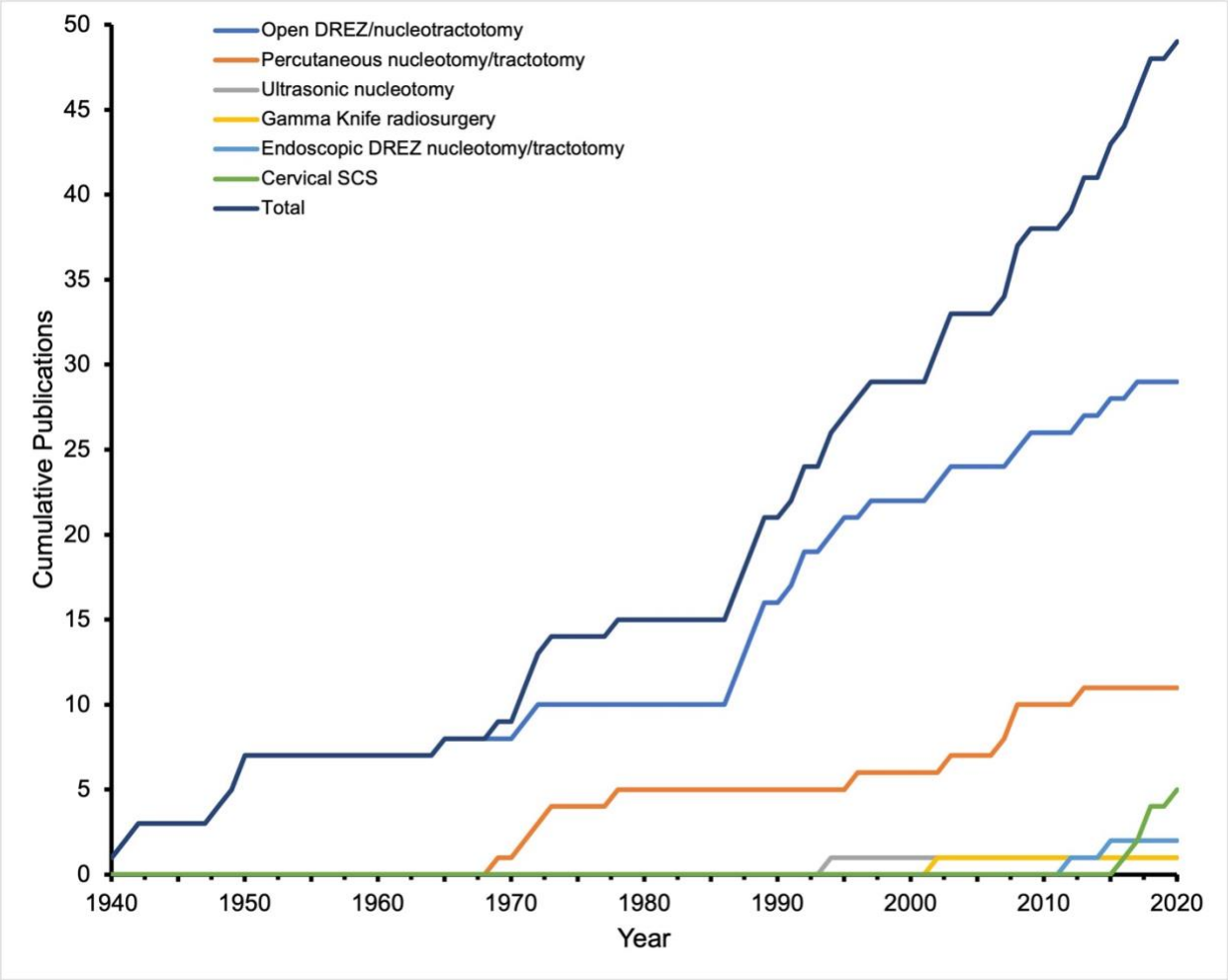

Figure 2: Cumulative number of studies examining nucleus caudalis targeting interventions in the treatment of facial pain. Over the last 80 years, 49 articles have been published investigating techniques targeting the NC for treatment of facial pain. The 1940s and 1970s saw the development of open (blue) and percutaneous approaches (orange) respectively. The rate of publication continues to increase over time and novel techniques continue to emerge including endoscopic approaches (light blue) and SCS (green) seen in the last 10 years and ultrasonic (grey) and radiosurgery (yellow) previously. Abbreviations: DREZ, dorsal root entry zone; NC, nucleus caudalis; SCS, spinal cord stimulation.

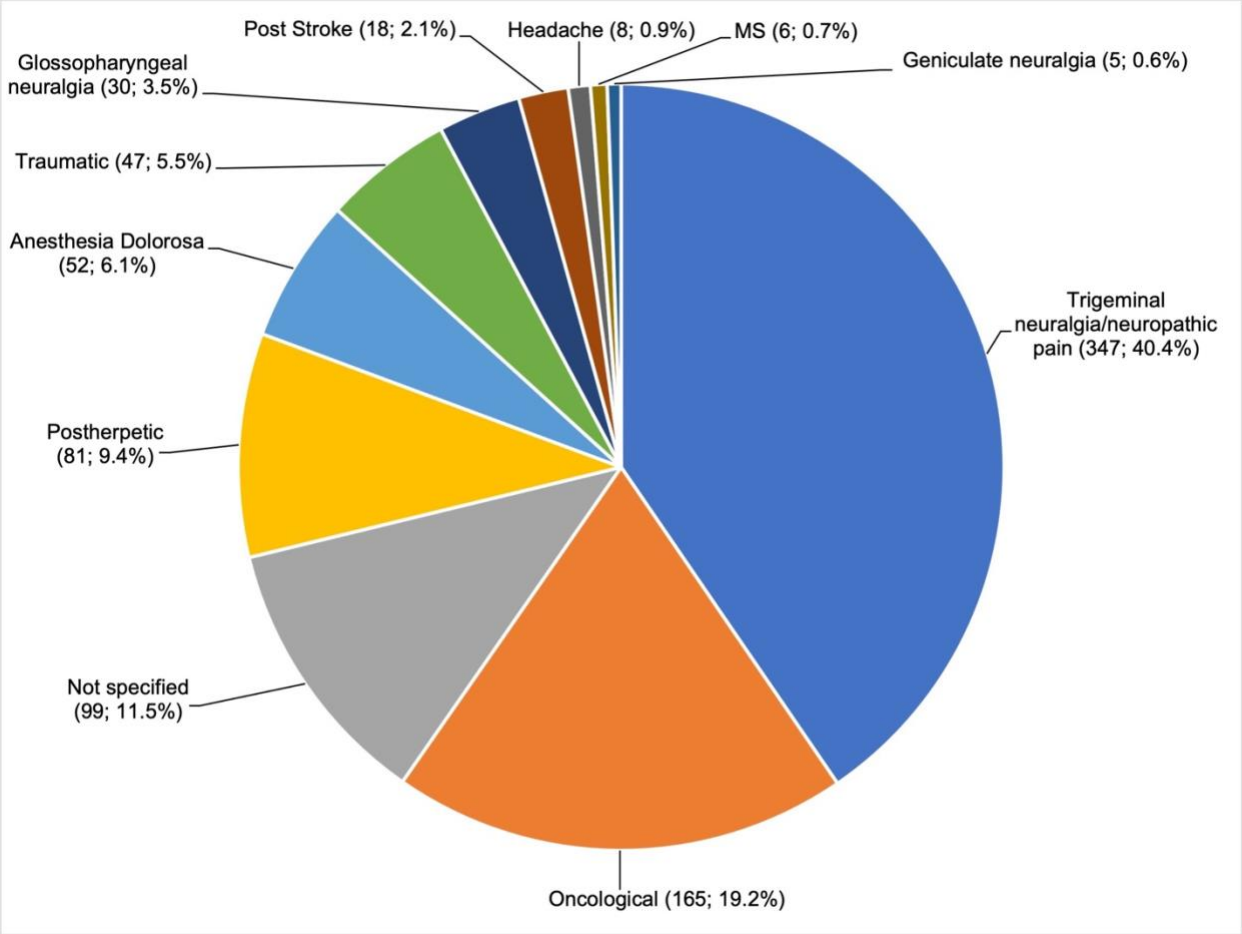

Figure 3: Distribution of preoperative diagnoses. Forty-nine articles reporting on 858 patients demonstrate a wide range of sources of facial pain treated with NC interventions. The most common being trigeminal neuralgia/neuropathic pain (n=347, 40.4%), oncological (n=165, 19.2%), and postherpetic pain (n=81, 9.4%). Rarer causes of facial pain are also represented, such as headache (n=8, 0.9%), MS (n=6, 0.7%), and geniculate neuralgia (n=5, 0.6%). Abbreviations: MS, multiple sclerosis; NC, nucleus caudalis.

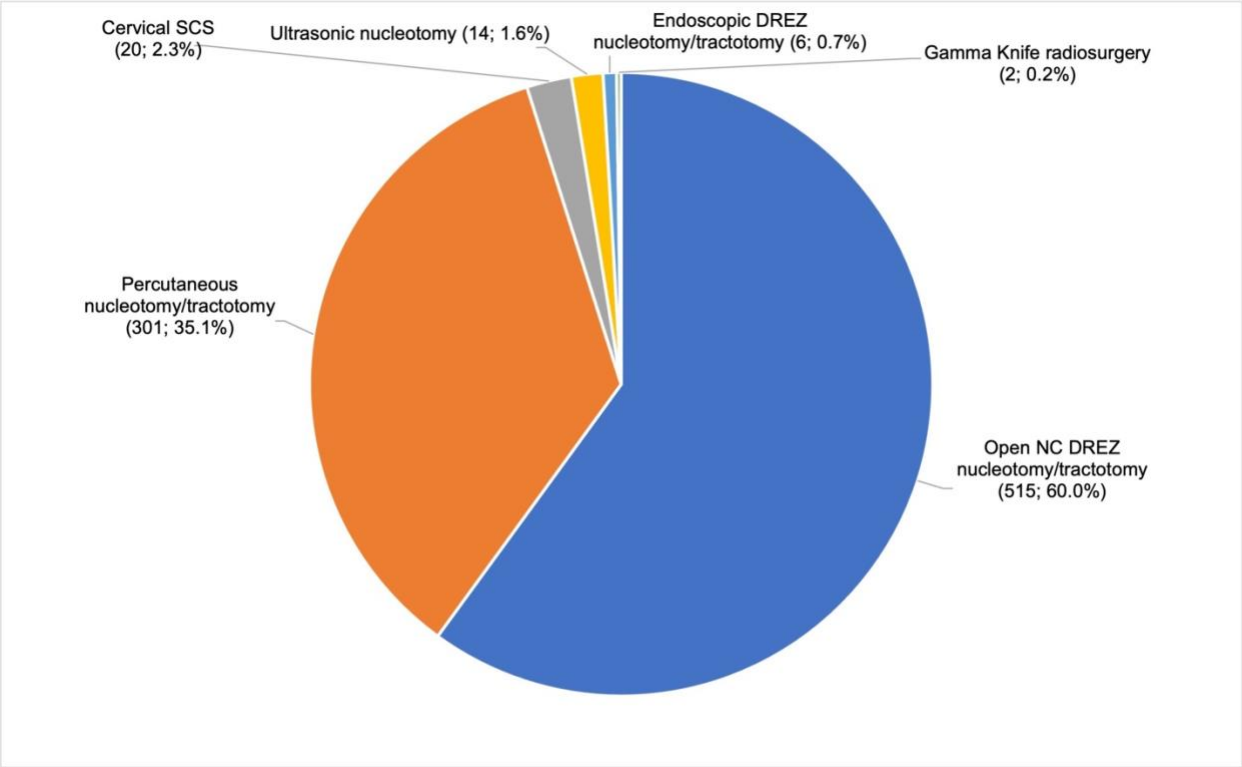

Figure 4: Distribution of intervention technique. The included studies encompass 6 main intervention techniques targeting the NC. In order of decreasing prevalence: Open NC DREZ nucleotomy/tractotomy (n=515, 60.0%), Percutaneous nucleotomy/tractotomy (n=301, 35.1%), Cervical SCS (n=20, 2.3%), Ultrasonic nucleotomy (n=14, 1.6%), Endoscopic DREZ nucleotomy/tractotomy (n=6, 0.7%), and Gamma Knife radiosurgery (n=2, 0.2%). Abbreviations: DREZ, dorsal root entry zone; NC, nucleus caudalis; SCS, spinal cord stimulation.

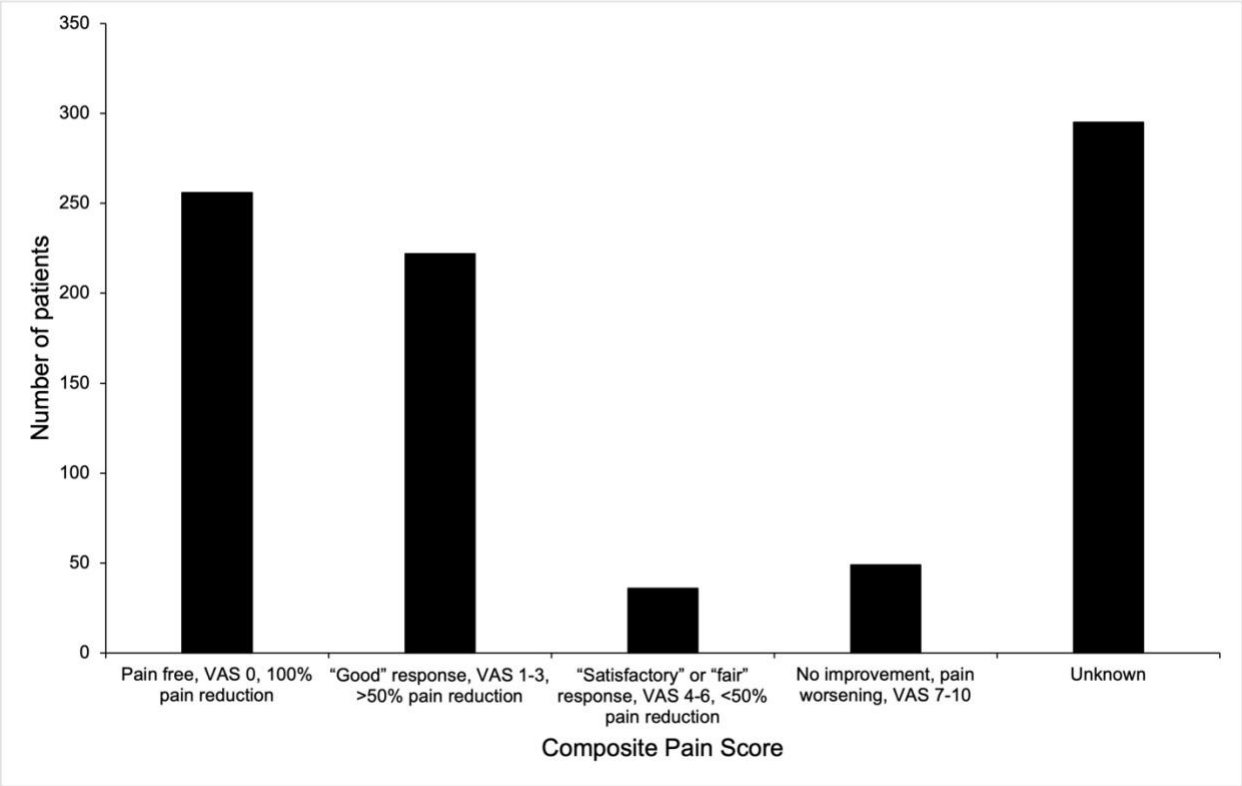

Figure 5: Post-intervention facial pain outcome. Intervention efficacy was reported for 563 patients in the form of varying descriptive and quantitative methods. Outcome was not reported in 295 patients. A composite pain score was created to facilitate comparison. Of those with reported outcome 45.5% (n=256) were pain free, 39.4% (n=222) had a "good" response, 6.4% (n=36) had a "satisfactory" response, and 8.7% (n=49) had no improvement or worsening pain. Abbreviation: VAS, visual analog scale.

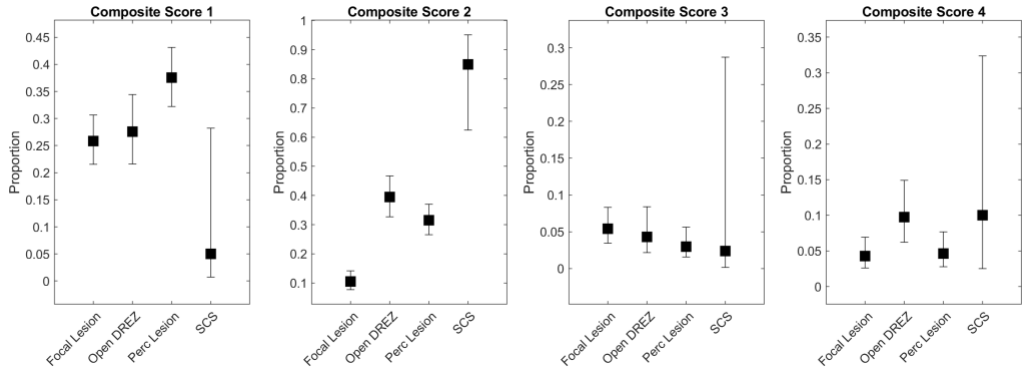

Figure 6: Distribution of pain outcomes by intervention technique. Excluding the unknown outcome values, the intervention types were reclassified as open focal lesioning techniques (nucleotomy/tractotomy) (n patients = 162), open DREZ (multipoint lesioning technique) (n patients = 150), percutaneous nucleotomy/tractotomy (n patients = 231), and cervical SCS (n patients = 20). Proportion of patients with a given outcome is reported with error bars representing 95% confidence intervals. Chi squared demonstrates a significant difference in the outcome distribution between the intervention types ($\chi^2(12, n = 563) = 56.3125$, $p < 0.001$). Abbreviations: DREZ, dorsal root entry zone; Perc, percutaneous; SCS, spinal cord stimulation.

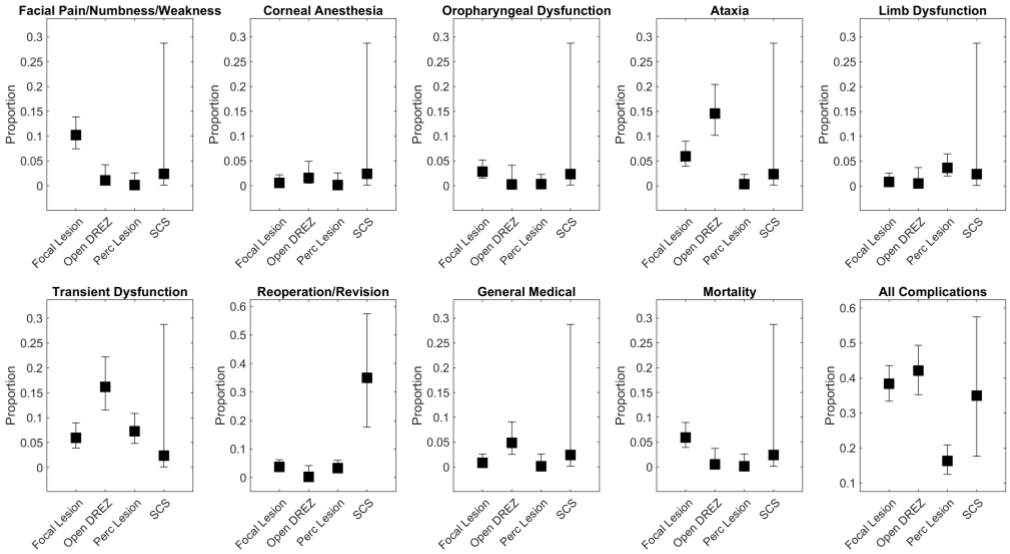

Figure 7: Proportion of patients with a given complication by intervention technique. All complications except corneal anesthesia (n = 5) and limb dysfunction (n = 15) demonstrate a statistically significant difference in distribution between intervention types. Proportion of patients with a given complication is reported with error bars representing 95% confidence intervals. See Supplemental Material 4 for data and statistical results. Abbreviations: DREZ, dorsal root entry zone; Perc, percutaneous; SCS, spinal cord stimulation.