

**Title: Higher Limbic and Basal Ganglia volumes in surviving COVID-negative patients and the relations to fatigue.**

**Authors:** Rakibul Hafiz<sup>1</sup>, Tapan Kumar Gandhi<sup>2</sup>, Sapna Mishra<sup>2</sup>, Alok Prasad<sup>3</sup>, Vidur Mahajan<sup>4</sup>, Xin Di<sup>1</sup>, Benjamin H. Natelson<sup>5</sup>, Bharat B. Biswal<sup>\*1</sup>

<sup>1</sup>*Department of Biomedical Engineering, New Jersey Institute of Technology (NJIT), 323 Dr Martin Luther King Jr Blvd, Newark, NJ 07102, USA.*

<sup>2</sup>*Department of Electrical Engineering, Indian Institute of Technology (IIT), Block II, IIT Delhi Main Rd, IIT Campus, Hauz Khas, New Delhi, Delhi 110016, India.*

<sup>3</sup>*Internal Medicine, Irene Hospital & Senior Consultant Medicine, Metro Heart and Super-specialty Hospital, New Delhi, India.*

<sup>4</sup>*Centre for Advanced Research in Imaging, Neuroscience & Genomics, Mahajan Imaging, New Delhi, India.*

<sup>5</sup>*Director, Pain & Fatigue Study Center, Icahn School of Medicine at Mount Sinai, The Mount Sinai Hospital, 5 East 98th Street, 7th Floor, New York, NY 10029.*

**\* Corresponding Author:** Bharat B. Biswal

**E-mail:** [bharat.biswal@njit.edu](mailto:bharat.biswal@njit.edu)

**Number of Characters in Title:** 92 Characters (no spaces)

**Number of Words in the Abstract:** 243

**Number of Words in the Introduction:** 1094

**Number of Words in the Discussion:** 807

**Number of Words in the Body:** 3517

**Number of Figures:** 4

**Number of Color Figures:** 4

**Number of Tables:** 1

## **Abstract**

Severe Acute Respiratory Syndrome Coronavirus 2 (SARS-CoV-2) has caused a global pandemic. Among several systemic abnormalities, little is known about the critical attack on the central nervous system (CNS). Several patient reports with multiple pathologies – ischemic strokes, mild infarcts, encephalitis, cerebro-vascular abnormalities, cerebral inflammation, and loss of consciousness, indicate CNS involvement. However, due to limited neuroimaging studies, conclusive group level effects are scarce in the literature and replication studies are necessary to verify if these effects persist in surviving acute-COVID patients. Furthermore, recent reports indicate fatigue is highly prevalent among slowly recovering patients. How early structural changes relate to fatigue need to be investigated. Our goal was to address this by scanning COVID subjects two weeks after hospital discharge. We hypothesized these surviving patients will demonstrate altered gray matter volume (GMV) when compared to healthy controls and further demonstrate correlation of GMV with fatigue. Voxel-based morphometry was applied to T1-weighted MRI images between 46 patients with COVID and 32 healthy controls. Significantly higher GMV in the *Limbic System* and *Basal Ganglia* regions were observed in surviving COVID-19 patients when compared to healthy controls. Moreover, within the patient group, there was a significant positive correlation between GMV and self-reported fatigue scores during work, within the *ventral Basal Ganglia* and *Ventromedial Prefrontal Cortex* regions. Therefore, our results align with both single case acute patient reports and current group level neuroimaging findings. Finally, we newly report a positive correlation of GMV with fatigue in COVID survivors.

**Keywords: COVID-19, VBM, Limbic, Basal Ganglia, Fatigue, Ventromedial Prefrontal Cortex**

## Introduction

SARS-CoV-2 is a highly contagious novel coronavirus, which spreads from person to person primarily through respiratory droplets [1]. Recent data table from the world health organization (WHO) shows nearly 219 million confirmed cases of COVID-19 and approximately 4.55 million deaths world-wide [2]. Mass vaccinations have mitigated cases in USA, but infections continue to rise – especially in India. Single case reports showing structural brain abnormalities have been reported but is unclear how long these anatomic abnormalities persist in acute patients, even after becoming COVID-negative upon polymerase chain reaction (PCR) retesting.

Attack on the central nervous system (CNS) in acutely ill COVID-19 patients has revealed a broad range of pathology including ischemic strokes, encephalitis [3], inflammatory vascular pathologies in cerebral vessels [4, 5], and microhemorrhages [6] among many others. A study conducted over multiple centers (11 hospitals, n = 64) reported a high percentage of ischemic strokes (27%) and encephalitis (13%), confusion (53%), impaired consciousness (39%) along with agitation (31%) and headaches (16%) [3]. Brain lesions, detected using fluid-attenuated inversion recovery (FLAIR) imaging, were also reported within frontal, parietal, occipital, temporal, and insular lobes [7]. Another study reported abnormal uptake on FLAIR imaging within the hypothalamus, temporal lobe, and the thalamus among three COVID patients with autoimmune and hemorrhagic encephalitis [8]. Therefore, the current neuroimaging literature needs to move from individual cases to conclusive group level estimates delineating structural brain alterations between COVID-19 patients and healthy controls (HCs).

Recently a few neuroimaging studies have emerged to address this gap with moderate [9, 10] to large sample sizes [11], including follow-up [12, 13] and longitudinal designs [11]. Lu et al., 2020 [12] had reported neurological symptoms in over 68% (41/60) of hospitalized patients and after a 3 month-follow-up assessment, they found persisting neurological symptoms in 55% (33/60) of patients. They had also used MRI imaging to assess both gray matter volume (GMV)

and white matter (WM) structural alterations. An atlas based regional assessment showed significantly higher GMV in several regions of interest (ROIs) – Rolandic operculum, bilateral olfactory, insular, and hippocampal regions, as well as in the right cingulate gyrus and left Heschl’s gyrus. There have been new reports of surviving COVID patients undergoing a sequela of symptoms [14-16] which converge to the brain as the responsible organ. Therefore, changes in brain structure could correlate to the severity of these symptoms. In regard to that, another follow-up study [13] assessed structural and functional changes related to post-traumatic stress symptoms (PTSS), where they investigated COVID-19 patients in two consecutive time points - 3 months and 6 months after initial infection. Their study showed increased GMV in bilateral hippocampus and amygdala. Moreover, the self-reported Posttraumatic Stress Disorder Checklist for DSM-5 (PCL-5) scores from COVID subjects were negatively correlated to left hippocampal and amygdala volumes. This could also relate to the interval after hospital discharge and the severity of symptoms can alter with time. For example, the study from Tu et al., 2021 also show that the PCL-5 scores from Session1 (3 months) correlated with the time after discharge and the total PCL-5 scores from these survivors increased by ~20% at Session2 (6 months).

It is possible that the COVID and control groups do not show any significant changes in GMV overall, however, symptomatic severity such as fever or hypoxemic conditions can modulate the brain structure, which could relate to clinical measures more locally. For instance, a recent study used source-based morphometry (SBM), a multivariate alternate to VBM, on Computed Tomography (CT) scans to show that the fronto-temporal network is more susceptible to fever and reduced oxygen levels in COVID patients, despite no overall difference in GMV between the COVID and control groups [9]. Furthermore, the modified Rankin Scale (mRS), a clinical disability score, significantly correlated with lower GMV in the frontal gyrus both during discharge and after a 6 month-follow-up.

But what if the patients never showed any neurological manifestations in the acute stage?

Can they develop neurological symptoms during recovery? How are these developments different in mild and severe patients? A recent attempt to answer these questions was made by a group from the epicenter of the disease itself, Wuhan, China. They had designed the study with 2 sub-types (mild and severe) who had no signs of any neurological manifestations during the acute stage [10]. However, after a 3 month-follow-up MRI scan, they reported reduced cortical thickness in the left insula, hippocampus, and superior temporal gyrus. It is possible that these changes could be caused by inflammatory storms, which can be identified at the acute stage. For example, they reported that the left hippocampal cortical thickness was negatively correlated with the inflammatory biomarker procalcitonin (PCT) in the severe group.

Another important question is how these neurological changes develop in individuals before and after infection with COVID-19. A recent longitudinal study [11] used a large pool of patients (N=785,  $n_{\text{COVID}} = 401$ ) from the UK Biobank COVID-19 reimaging study, to show reduced GM thickness and contrast in the orbitofrontal and Parahippocampal gyrus, as well as, in insula, amygdala and the anterior cingulate cortex. In addition, they report increased tissue damage in brain regions functionally associated with the piriform cortex and the olfactory system, as well as higher volumes in CSF. Therefore, the literature shows mixed evidence of increased GMV and contrarily, reduced GM thickness from cross-sectional, follow-up and longitudinal designs, nevertheless, in quite consistent anatomical locations. Our goal was to first assess, if the participants from our study, scanned after a much shorter interval from hospital discharge (2 weeks), demonstrated altered GMV in regions that are consistent with both acute stage single case reports and more recent group level neuroimaging reports from lengthy recovering (3 to 6 months) patients. Moreover, since fatigue is the highest reported symptom from surviving patients [14-16], we wanted to ask, if self-reported fatigue (during work) independently correlated to voxel-wise GMV in regions, known to be functionally associated with fatigue.

In this study, we try to address this by recruiting a group of patients, hospitalized due to a

positive PCR test for COVID-19. We imaged them two weeks after hospital discharge after converting to be PCR negative. One expectation is that changes in brain tissue structure in COVID survivors can still cause changes in compartmental volumes that remain shortly after hospital discharge. Specifically, we hypothesized that these surviving COVID-negative patients would demonstrate gray matter volume (GMV) differences with the HC group and show significant correlation of altered GMV with self-reported fatigue scores. T1-weighted MRI images are sensitive to such changes and can be used to estimate GMV differences between two groups using voxel-based morphometry (VBM) [17].

## Materials and Methods

**Participants:** 47 COVID-negative patients and 35 HCs were recruited from the Indian Institute of Technology (IIT), Delhi, India where they were imaged following all Institutional Review Board (IRB) guidelines. Four subjects (1 COVID and 3 HC) were removed during quality control assessment. Effectively, T1-weighted images from 46 (31 males) COVID and 32 (25 males) HCs were included in the study with mean age 32.91 years  $\pm$ 9.71[SD] years (HC) and 34.63 years  $\pm$ 11.54[SD] years (COVID). Please see *Table 1* for more details on demographics.

**Clinical Assessment:** The most commonly reported symptoms from the participants during hospitalization were - fever, cough, body ache, chills, difficulty breathing, bowel irritation, nausea, loss of sense of smell and loss of consciousness. We also assessed if they were having any ongoing/new symptoms from day of discharge to the day of scan – fatigue, anxiety, lack of attention, body ache, headache, memory loss, delayed recovery of sense of taste and/or smell, bowel irritation and interestingly, hair loss were commonly reported. Particularly, since we were interested in fatigue related correlates of GMV, a subset of COVID patients (n = 30), successfully reported their fatigue levels on a scale of 0 to 5, with 0 representing no fatigue and 5 representing the highest fatigue levels observed during work. The average fatigue score in this sub-set of

COVID participants was  $2.7/5 \pm 1.32$  [SD].

**Imaging:** High-resolution structural images were acquired using a 3T GE scanner with a 32-channel head coil in 3D imaging mode with a fast BRAVO sequence. The imaging parameters were TI = 450 ms; 244 x 200 matrix; Flip angle = 12 and FOV = 256 mm, number of slices = 152 (sagittal), slice thickness = 1.00 mm and spatial resolution of 1.0 mm x 1.0 mm x 1.0 mm.

**Data Pre-Processing:** We performed pre-processing using SPM12

(<http://www.fil.ion.ucl.ac.uk/spm/>) within the MATLAB environment (Mathworks Inc, Massachusetts, USA). All anatomical images were visually inspected for artifacts, re-centered and reoriented to the anterior-posterior commissure (ac-pc) line. Each brain compartment was segmented into specific tissue classes mainly - gray matter (GM), white matter (WM), and cerebro-spinal fluid (CSF). A study-specific template was first generated using the fast diffeomorphic image registration algorithm (DARTEL) [18] which is representative of the average across all the participants included in the study [19, 20]. Using the deformation fields from the segmentation stage, subject level maps were warped to this reference template for relatively higher specificity and accuracy [20]. Finally, each map was normalized to the Montreal Neurological Institute (MNI) space using affine transformation and resampled to an isotropic voxel dimension of 1.5 mm \* 1.5 mm \* 1.5 mm. Modulated images were obtained for each subject, which account for contractions and expansions from non-linear spatial transformations. The normalized modulated images were then spatially smoothed with a gaussian kernel of 8 mm.

**VBM Analysis:** VBM is a volumetric computational method that can quantify voxel-wise changes in tissue volume in the gray matter (GM)[17]. It is a useful method to report group level differences in tissue volume between patients and healthy controls (HCs), using T1-weighted anatomical images. It has been repeatedly used to demonstrate structural differences in patient cohorts with earliest reports for Schizophrenia [21, 22], autism [23], chronic depression [24] and epilepsy [25]

among several others [26-28] (check more recent reviews for: Schizophrenia [29], Autism Spectrum Disorder [30], Epilepsy [31] and Alzheimer's disease [32]). VBM can be estimated from gray matter probability maps obtained from the segmentation stage. Each value in a tissue specific probability map represents the likelihood of the voxel belonging to a brain compartment and tissue volumes can be estimated by summing over the product of each voxel's dimension and the corresponding probabilities [33]. Total Intracranial Volume (TIV) is the sum of volumes from each major compartment in the brain – GM, WM, and CSF, with  $TIV = GMV + WMV + CSFV$ ; where GMV = Gray Matter Volume, WMV = White Matter Volume and CSFV = Cerebro-Spinal Fluid Volume. Besides tissue specific volume measures, we also quantified each tissue's proportional concentration as a percentage of the total intracranial volume (TIV) - %GM, %WM and %CSF. These quantities were used to assess central tendency measures in each group. Subsequently, each subject's TIV was used as a covariate of no interest during statistical modeling to account for the individual variations in brain sizes. To visualize the sample distributions and group average compartmental and total brain volumes, we customized and adopted a script in RStudio [34] to generate a 'raincloud' figure, as depicted in a recent publication [35].

**Statistical Analysis:** To assess differences in participant demographics, we performed two sample t-test on age, GMV, WMV, CSFV and TIV and chi-squared test for sex differences between the two groups. To determine group level differences in GMV, we performed a two-sample t-test using the smoothed, modulated, and normalized GM tissue maps from the two groups. TIV of each subject was group-mean centered and added as a covariate along with age and sex to account for confounding effects. An implicit mask with absolute threshold of 20% above the group mean was set to exclude unwanted voxel quantities from the smoothed GM maps. Regions with significant difference in GMV between the two groups were identified using cluster-based thresholding at height threshold  $p_{unc} < 0.005$  and *family wise error (FWE)* corrected at  $p < 0.05$ , for multiple comparisons. The *cluster extent threshold* ( $k_E$ ) from *FWE* correction was used to generate



thresholded statistical maps for the contrast with significant effect.

To evaluate the relationship between altered GMV and fatigue in the sub-set of COVID participants, we performed a multiple linear regression analysis, with voxel-wise GMV as the response variable and the fatigue score as the covariate of interest, while, age, sex and TIV were included as covariates of no interest. Regions with significant correlation between GMV and fatigue score were identified using cluster-based thresholding at height threshold  $p_{unc} < 0.001$  and *FWE* corrected at  $p < 0.05$ , for multiple comparisons. In order to visualize any significant linear relationship between the two variables, the average GMV within the significant cluster was obtained from each subject. These average GMV values were then linearly regressed against the fatigue scores and visualized within a scatter plot and a line of best fit with 95% confidence interval. Age, sex and TIV of each participant were regressed out during the linear regression step. The correlation analysis and the graphical plotting was done using 'inhouse' scripts prepared in RStudio [34].

## Results

We assessed group level differences in demographics (age and sex), as well as in overall compartmental volumes (GMV, WMV, CSFV) and the total volume (TIV). We observed no significant differences between the two groups in any of the measures ( $p > 0.05$ ). All statistical results and the central tendency measures have been listed in *Table 1* for reference.

Surviving COVID-negative patients demonstrated significantly higher GMV compared to HCs. The significant cluster (Figure1) comprised of the *Left – Hippocampus (Hc)*, *Ventral Diencephalon (VDC)*, *Putamen (Pu)*, *Pallidum (Pd)*, *Amygdala (Am)*, *Planum Polare (PP)*, *Anterior Insula (AIns)*, *Posterior Insula (PIns)* and *Thalamus Proper (ThP)* (see Figure2 for a multi-slice view of these regions). We also assessed the central tendency measures from each group for each of the brain compartmental volumes and the overall TIV (see Figure3 for a visual assessment

of group-wise distributions). The ‘raincloud’ [35] plot in Figure3, illustrates the mean and inter-quartile range of each measure using a box plot (under the violin plot in each subplot). The dot plots (jittered for visual aesthetics) represent the subject-wise volumes corresponding to each issue type.

For the correlation analysis using self-reported fatigue scores, the subset ( $n = 30$ ) of COVID participants demonstrated significantly positive correlation with GMV in regions from the *ventral basal ganglia (BG)* and frontal gyrus, particularly, the *ventromedial prefrontal cortex (vmPFC)*. The cluster (Figure4, top left) showing significant correlation comprised of *Right – Subcallosal Area (ScA), Accumbens Area (AcA), Mid-orbital Gyrus (MOG), Anterior Cingulate Gyrus (ACG), Medial Frontal Cortex (MFC), Gyrus Rectus (GRe), Caudate (Cd), Putamen (Pu) and Bilateral – Ventral Diencephalon (VDC) and Right – Basal Forebrain (BsF), Amygdala (Amg), Entorhinal Area (EnA) and Parahippocampal Gyrus (PHG)* (see Figure4 bottom row, for a multi-slice view of some of these regions). The scatter plot (Figure4, top right) demonstrates the linear relationship ( $r = 0.65$ ,  $p = 0.0001$ ) between fatigue scores and the average GMV of each subject within the cluster. The linear plot (red) represents the least squares regression line (best fit), and the shaded gray area represents the 95% confidence interval.

## Discussion

The results support our hypothesis that COVID survivors, now PCR negative, demonstrate altered GMV compared to HCs even 2 weeks after hospital discharge. Our results also support the hypothesis that altered GMV in COVID survivors correlate to self-reported fatigue. For the single case reports in the literature – hyperintensity in FLAIR images can arise from several sources including ischemia, micro-hemorrhages, and damage to vasculature, commonly observed in acute COVID patients and these neurological disturbances can modulate tissue volumes. We observed higher GMV in the *left Hc* and *Amg* at the group level, which aligns with a case report of

hyperintensities in the *left Hc* and *Amg* from FLAIR images in an older patient (Male, 56 years) [3]. Recent neuroimaging studies have also reported higher GMV among COVID cohorts, in the *bilateral Hc* after 3 month-follow-up [12], as well as, in *bilateral Hc* and *Amg* in another follow-up study (3 and 6 months) [13]. Interestingly, Tu et al., 2021 also report significant correlation of the *left Hc* and *Amg* with PCL-5 scores, demonstrating stress related structural changes in these regions. On the contrary, cortical thickness was reported to be reduced in the *left Hc* after a 3 month-follow-up study [10] and in the *Amg* after infection with COVID-19 in a longitudinal study [11].

We also observed higher GMV in *AI*ns and *PI*ns regions indicating GMV alterations in *insular* lobes, which were reported to be hyperintense in specific patients [7]. Similarly, higher GMV was also observed at the group level in the *bilateral Ins* [12], while, on the other hand, others reported reduced cortical thickness in *insular* lobes [10, 11]. Early reports from severely acute hospitalized patients also mention hyperintense lesions in the *brain stem* and *basal ganglia* [8]. Our results also show higher GMV in *VDC*, *Pu*, and *Pd* which constitute major parts of the *basal ganglia* and *sub-cortical* system. Moreover, the same study also reported from FLAIR imaging that the *thalamus (Th)* of some COVID-positive individuals was hyperintense. We observed higher GMV in *ThP* which also aligns with this finding. Therefore, the group level estimates from our VBM analysis converge with acutely ill ‘individual’ COVID patient findings and maintain consistency with current neuroimaging reports from moderate to large samples of recovering COVID ‘groups’.

In addition, we have also assessed central tendency measures for group specific VBM quantities by averaging over subject-specific brain compartment volumes. Although not statistically significant ( $p = 0.17$ ), the mean CSFV tended to be higher in the COVID group compared to the HCs (see *Table1* and Figure3). This seems to align with the recent UK-Biobank longitudinal study (n = 401), who reported increased CSFV after COVID infection [11]. Our data indicates more variation in brain volumes among the COVID patients, with higher standard deviation (SD) in GMV,

WMV and TIV (see *Table 1*). This might arise from varying levels of tissue swelling due to acute infection among surviving patients. However, the underlying neurophysiology that elicit such changes is still unclear. Highly prevalent acute stage neurological damage from CNS viral or vascular pathologies can cause local changes in tissue concentration. Transient reduction in cerebral blood flow (CBF) can also cause gray matter concentration to increase due to change in hydration levels[36]. Overall, continued brain swelling from neuro-vascular injuries may explain why we observed locally higher GMV in the COVID group even 2 weeks after testing negative.

A rising concern with recovering patients has been the manifestation of a sequelae of symptoms that persist several months along the recovery timeline [14-16]. Fatigue, lack of attention, delayed recovery of loss of sense of smell and taste are some of the commonly reported symptoms. We asked the surviving patients, what level of fatigue is disrupting their daily work during the 2-week-recovery phase. Based on their reported score, we observed significant positive correlation of these scores with higher GMV in brain regions that are part of the *cholinergic output (BsF, AcA)* from the *ventral BG* and *orbitofrontal cortex (MOG, GrE)*, *ACG* and *MFC* from the *vmPFC*. The study from Duan K. and colleagues [9] had shown reduced GMV association with disability scores in the frontal gyri using CT scan images. However, we show a positive association of higher GMV with fatigue in the frontal gyrus (*vmPFC* in particular). Interestingly, the *BG* and *vmPFC* regions have also been shown to be functionally associated with fatigue [37-42].

In conclusion, our results highlight group level effects in surviving COVID-negative patients that match with single patient case studies, as well as several neuroimaging studies from surviving COVID-19 cohorts. We have shown significant GMV alterations in multiple brain regions from the *limbic system* and *basal ganglia* and further showed positive associations of regional volume increases with self-reported fatigue at work. More importantly, these regions can also be modulated by neuronal damage and characterized from functional neuroimaging relating to fatigue, pain, emotion, attention, and somatosensory processing [43-46].

## **Limitations and Future Directions**

Despite our emphasis on group level analysis, we understand that in a clinical setting, it may have little transferability, owing to idiosyncrasies associated with each patient. A possible approach to address this issue would be to compare patient specific VBM against a sufficiently sized control sub-group randomly selected from a larger cohort [47]. However, it may not be very practical in a clinical setting unless a well-designed control dataset is available for a clinician. Nevertheless, our group level results from a single site seem to match single patient findings quite well, especially when they were collected from several centers across different countries [48]. Moreover, currently, we only have 46 COVID subjects. While we do observe significant effects, we still need a larger sample size to verify the main effects more conclusively. Another concern we have is the reversibility or transient nature of some effects. These patients were scanned two weeks after hospital discharge. It is possible some critical effects may have already disappeared through recovery or reversible neurological processes. Therefore, a better approach could be to scan the patients at onset, during and after recovery along with behavioral parameters to assess any possible trends unique to the neurological pathology in COVID patients.

## **CRedit author Statement**

**Rakibul Hafiz:** Methodology, Software, Formal Analysis, Data Curation, Writing – Original Draft, Review and Editing.

**Tapan K. Gandhi:** Conceptualization, Investigation, Resources, Supervision, Writing – Review and Editing.

**Sapna Mishra:** Investigation, Resources, Data Curation, Writing – Review and Editing.

**Alok Prasad:** Writing – Review and Editing.

**Vidur Mahajan:** Writing – Review and Editing.

**Xin Di:** Methodology, Writing – Review and Editing.

**Benjamin H. Natelson:** Writing – Review and Editing.

**Bharat Biswal:** Conceptualization, Resources, Project Administration, Supervision, Writing – Review and Editing.

### **Acknowledgements**

This study was supported by an NIH grant (R01AT009829).

## References

1. National Center for Immunization and Respiratory Diseases (NCIRD) DoVD. Symptoms of Coronavirus: Centers for Disease Control and Prevention (CDC); 2020 [updated December 22, 2020; cited 2021 02/02/2021]. Available from: <https://www.cdc.gov/coronavirus/2019-ncov/symptoms-testing/symptoms.html>.
2. (WHO) WHO. WHO Coronavirus Disease (COVID-19) Dashboard 2020 [updated 10/21/2021, 4:46pm CET10/21/2021]. Available from: <https://covid19.who.int/table>.
3. Kremer S, Lersy F, Anheim M, Merdji H, Schenck M, Oesterlé H, Bolognini F, Messie J, Khalil A, Gaudemer A, Carré S, Alleg M, Lecocq C, Schmitt E, Anxionnat R, Zhu F, Jager L, Nesser P, Mba YT, Hmeydia G, Benzakoun J, Oppenheim C, Ferré JC, Maamar A, Carsin-Nicol B, Comby PO, Ricolfi F, Thouant P, Boutet C, Fabre X, Forestier G, de Beaurepaire I, Bornet G, Desal H, Boulouis G, Berge J, Kazémi A, Pyatigorskaya N, Lecler A, Saleme S, Edjlali-Goujon M, Kerleroux B, Constans JM, Zorn PE, Mathieu M, Baloglu S, Ardellier FD, Willaume T, Brisset JC, Caillard S, Collange O, Mertes PM, Schneider F, Fafi-Kremer S, Ohana M, Meziani F, Meyer N, Helms J, Cotton F. Neurologic and neuroimaging findings in patients with COVID-19: A retrospective multicenter study. *Neurology*. 2020;95(13):e1868-e82. Epub 2020/07/19. doi: 10.1212/wnl.0000000000010112. PubMed PMID: 32680942.
4. Keller E, Brandi G, Winklhofer S, Imbach LL, Kirschenbaum D, Frontzek K, Steiger P, Dietler S, Haeblerlin M, Willms J, Porta F, Waeckerlin A, Huber M, Abela IA, Lutterotti A, Stippich C, Globas C, Varga Z, Jelcic I. Large and Small Cerebral Vessel Involvement in Severe COVID-19: Detailed Clinical Workup of a Case Series. *Stroke*. 2020;51(12):3719-22. Epub 2020/10/16. doi: 10.1161/strokeaha.120.031224. PubMed PMID: 33054673; PMCID: PMC7678671.
5. Nicholson P, Alshafai L, Krings T. Neuroimaging Findings in Patients with COVID-19. *American Journal of Neuroradiology*. 2020;41(8):1380-3. doi: 10.3174/ajnr.A6630.
6. Radmanesh A, Derman A, Lui YW, Raz E, Loh JP, Hagiwara M, Borja MJ, Zan E, Fatterpekar GM. COVID-19-associated Diffuse Leukoencephalopathy and Microhemorrhages. *Radiology*. 2020;297(1):E223-E7. Epub 2020/05/21. doi: 10.1148/radiol.2020202040. PubMed PMID: 32437314.
7. Kandemirli SG, Dogan L, Sarikaya ZT, Kara S, Akinci C, Kaya D, Kaya Y, Yildirim D, Tuzuner F, Yildirim MS, Ozluk E, Gucyetmez B, Karaarslan E, Koyluoglu I, Demirel Kaya HS, Mammadov O, Kisa Ozdemir I, Afsar N, Citci Yalcinkaya B, Rasimoglu S, Guduk DE, Kedir Jima A, Ilksoz A, Ersoz V, Yonca Eren M, Celtik N, Arslan S, Korkmazer B, Dincer SS, Gulek E, Dikmen I, Yazici M, Unsal S, Ljama T, Demirel I, Ayyildiz A, Kesimci I, Bolsoy Deveci S, Tutuncu M, Kizilkilic O, Telci L, Zengin R, Dincer A, Akinci IO, Kocer N. Brain MRI Findings in Patients in the Intensive Care Unit with COVID-19 Infection. *Radiology*. 2020;297(1):E232-e5. Epub 2020/05/10. doi: 10.1148/radiol.2020201697. PubMed PMID: 32384020; PMCID: PMC7507997.
8. Paterson RW, Brown RL, Benjamin L, Nortley R, Wiethoff S, Bharucha T, Jayaseelan DL, Kumar G, Raftopoulos RE, Zambreanu L, Vivekanandam V, Khoo A, Geraldine R, Chinthapalli K, Boyd E, Tuzlali H, Price G, Christofi G, Morrow J, McNamara P, McLoughlin B, Lim ST, Mehta PR, Levee V, Keddie S, Yong W, Trip SA, Foulkes AJM, Hotton G, Miller TD, Everitt AD, Carswell C, Davies NWS, Yoong M, Attwell D, Sreedharan J, Silber E, Schott JM, Chandratheva A, Perry RJ, Simister R, Checkley A, Longley N, Farmer SF, Carletti F, Houlihan C, Thom M, Lunn MP, Spillane J, Howard R, Vincent A, Werring DJ, Hoskote C, Jäger HR, Manji H, Zandi MS. The emerging spectrum of COVID-19 neurology: clinical, radiological and laboratory findings. *Brain*. 2020;143(10):3104-20. Epub 2020/07/09. doi:



10.1093/brain/awaa240. PubMed PMID: 32637987; PMCID: PMC7454352.

9. Duan K, Premi E, Pilotto A, Cristillo V, Benussi A, Libri I, Giunta M, Bockholt HJ, Liu J, Campora R, Pezzini A, Gasparotti R, Magoni M, Padovani A, Calhoun VD. Alterations of frontal-temporal gray matter volume associate with clinical measures of older adults with COVID-19. *Neurobiol Stress*. 2021;14:100326. Epub 20210413. doi: 10.1016/j.ynstr.2021.100326. PubMed PMID: 33869679; PMCID: PMC8041745.

10. Qin Y, Wu J, Chen T, Li J, Zhang G, Wu D, Zhou Y, Zheng N, Cai A, Ning Q, Manyande A, Xu F, Wang J, Zhu W. Long-term microstructure and cerebral blood flow changes in patients recovered from COVID-19 without neurological manifestations. *J Clin Invest*. 2021;131(8). doi: 10.1172/jci147329. PubMed PMID: 33630760; PMCID: PMC8262559.

11. Douaud G, Lee S, Alfaro-Almagro F, Arthofer C, Wang C, Lange F, Andersson JLR, Griffanti L, Duff E, Jbabdi S, Taschler B, Winkler A, Nichols TE, Collins R, Matthews PM, Allen N, Miller KL, Smith SM. Brain imaging before and after COVID-19 in UK Biobank. *medRxiv*. 2021. Epub 20210620. doi: 10.1101/2021.06.11.21258690. PubMed PMID: 34189535; PMCID: PMC8240690.

12. Lu Y, Li X, Geng D, Mei N, Wu P-Y, Huang C-C, Jia T, Zhao Y, Wang D, Xiao A, Yin B. Cerebral Micro-Structural Changes in COVID-19 Patients &#x2013; An MRI-based 3-month Follow-up Study. *EClinicalMedicine*. 2020;25. doi: 10.1016/j.eclinm.2020.100484. PubMed PMID: 100484.

13. Tu Y, Zhang Y, Li Y, Zhao Q, Bi Y, Lu X, Kong Y, Wang L, Lu Z, Hu L. Post-traumatic stress symptoms in COVID-19 survivors: a self-report and brain imaging follow-up study. *Molecular Psychiatry*. 2021. doi: 10.1038/s41380-021-01223-w.

14. Logue JK, Franko NM, McCulloch DJ, McDonald D, Magedson A, Wolf CR, Chu HY. Sequelae in Adults at 6 Months After COVID-19 Infection. *JAMA Netw Open*. 2021;4(2):e210830. Epub 2021/02/20. doi: 10.1001/jamanetworkopen.2021.0830. PubMed PMID: 33606031; PMCID: PMC7896197 Merck, Ellume, the Bill and Melinda Gates Foundation, GlaxoSmithKline, and Pfizer; receiving grants from Sanofi-Pasteur; and receiving reagents from Cepheid Research outside the submitted work. No other disclosures were reported.

15. Tabacof L, Tosto-Mancuso J, Wood J, Cortes M, Kontorovich A, McCarthy D, Rizk D, Mohammadi N, Breyman E, Nasr L, Kellner C, Putrino D. Post-acute COVID-19 syndrome negatively impacts health and wellbeing despite less severe acute infection. *medRxiv*. 2020:2020.11.04.20226126. doi: 10.1101/2020.11.04.20226126.

16. Peluso MJ, Kelly JD, Lu S, Goldberg SA, Davidson MC, Mathur S, Durstenfeld MS, Spinelli MA, Hoh R, Tai V, Fehrman EA, Torres L, Hernandez Y, Williams MC, Arreguin MI, Bautista JA, Ngo LH, Deswal M, Munter SE, Martinez EO, Anglin KA, Romero MD, Tavs J, Rugart PR, Chen JY, Sans HM, Murray VW, Ellis PK, Donohue KC, Massachi JA, Weiss JO, Mehdi I, Pineda-Ramirez J, Tang AF, Wegner M, Assenzio M, Yuan Y, Krone M, Rutishauser RL, Rodriguez-Barraquer I, Greenhouse B, Saucedo JA, Gandhi M, Hsue P, Henrich TJ, Deeks SG, Martin JN. Rapid implementation of a cohort for the study of post-acute sequelae of SARS-CoV-2 infection/COVID-19. *medRxiv*. 2021:2021.03.11.21252311. doi: 10.1101/2021.03.11.21252311.

17. Ashburner J, Friston KJ. Voxel-Based Morphometry—The Methods. *NeuroImage*. 2000;11(6):805-21. doi: <https://doi.org/10.1006/nimg.2000.0582>.



18. Ashburner J. A fast diffeomorphic image registration algorithm. *NeuroImage*. 2007;38(1):95-113. doi: <https://doi.org/10.1016/j.neuroimage.2007.07.007>.
19. Ashburner J, Friston KJ. Computing average shaped tissue probability templates. *NeuroImage*. 2009;45(2):333-41. Epub 2009/01/17. doi: 10.1016/j.neuroimage.2008.12.008. PubMed PMID: 19146961.
20. Yassa MA, Stark CE. A quantitative evaluation of cross-participant registration techniques for MRI studies of the medial temporal lobe. *NeuroImage*. 2009;44(2):319-27. Epub 2008/10/22. doi: 10.1016/j.neuroimage.2008.09.016. PubMed PMID: 18929669.
21. Wright IC, Ellison ZR, Sharma T, Friston KJ, Murray RM, McGuire PK. Mapping of grey matter changes in schizophrenia. This work was presented, in part, at the VIth International Congress on Schizophrenia Research, Colorado Springs, Colorado, USA, April 1997. *Schizophrenia Research*. 1999;35(1):1-14. doi: [https://doi.org/10.1016/S0920-9964\(98\)00094-2](https://doi.org/10.1016/S0920-9964(98)00094-2).
22. Wright IC, McGuire PK, Poline JB, Travere JM, Murray RM, Frith CD, Frackowiak RSJ, Friston KJ. A Voxel-Based Method for the Statistical Analysis of Gray and White Matter Density Applied to Schizophrenia. *NeuroImage*. 1995;2(4):244-52. doi: <https://doi.org/10.1006/nimg.1995.1032>.
23. Abell F, Krams M, Ashburner J, Passingham R, Friston K, Frackowiak R, Happé F, Frith C, Frith U. The neuroanatomy of autism: a voxel-based whole brain analysis of structural scans. *Neuroreport*. 1999;10(8), [https://journals.lww.com/neuroreport/Fulltext/1999/06030/The\\_neuroanatomy\\_of\\_autism\\_a\\_voxel\\_based\\_whole.5.aspx](https://journals.lww.com/neuroreport/Fulltext/1999/06030/The_neuroanatomy_of_autism_a_voxel_based_whole.5.aspx).
24. Shah PJ, Ebmeier KP, Glabus MF, Goodwin GM. Cortical grey matter reductions associated with treatment-resistant chronic unipolar depression: Controlled magnetic resonance imaging study. *British Journal of Psychiatry*. 1998;172(6):527-32. Epub 2018/01/03. doi: 10.1192/bjp.172.6.527.
25. Woermann FG, Free SL, Koepp MJ, Ashburner J, Duncan JS. Voxel-by-Voxel Comparison of Automatically Segmented Cerebral Gray Matter—A Rater-Independent Comparison of Structural MRI in Patients with Epilepsy. *NeuroImage*. 1999;10(4):373-84. doi: <https://doi.org/10.1006/nimg.1999.0481>.
26. Krams M, Quinton R, Ashburner J, Friston KJ, Frackowiak RSJ, Bouloux P-MG, Passingham RE. Kallmann's syndrome. Mirror movements associated with bilateral corticospinal tract hypertrophy. *NeuroImage*. 1999;52(4):816-. doi: 10.1212/wnl.52.4.816.
27. May A, Ashburner J, Büchel C, McGonigle DJ, Friston KJ, Frackowiak RSJ, Goadsby PJ. Correlation between structural and functional changes in brain in an idiopathic headache syndrome. *Nature Medicine*. 1999;5(7):836-8. doi: 10.1038/10561.
28. Vargha-Khadem F, Watkins KE, Price CJ, Ashburner J, Alcock KJ, Connelly A, Frackowiak RSJ, Friston KJ, Pembrey ME, Mishkin M, Gadian DG, Passingham RE. Neural basis of an inherited speech and language disorder. *Proceedings of the National Academy of Sciences*. 1998;95(21):12695-700. doi: 10.1073/pnas.95.21.12695.
29. Nemoto K. [Voxel-Based Morphometry for Schizophrenia: A Review]. *Brain Nerve*. 2017;69(5):513-8. Epub 2017/05/10. doi: 10.11477/mf.1416200777. PubMed PMID: 28479528.
30. Yamasue H. [Voxel-Based Morphometry in Autism Spectrum Disorder]. *Brain Nerve*.

2017;69(5):529-38. Epub 2017/05/10. doi: 10.11477/mf.1416200779. PubMed PMID: 28479530.

31. Yasuda CL, Betting LE, Cendes F. Voxel-based morphometry and epilepsy. *Expert Rev Neurother*. 2010;10(6):975-84. Epub 2010/06/04. doi: 10.1586/ern.10.63. PubMed PMID: 20518612.

32. Matsuda H. MRI morphometry in Alzheimer's disease. *Ageing Res Rev*. 2016;30:17-24. Epub 2016/01/27. doi: 10.1016/j.arr.2016.01.003. PubMed PMID: 26812213.

33. Lüders E, Steinmetz H, Jäncke L. Brain size and grey matter volume in the healthy human brain. *Neuroreport*. 2002;13(17), [https://journals.lww.com/neuroreport/Fulltext/2002/12030/Brain\\_size\\_and\\_grey\\_matter\\_volume\\_in\\_the\\_healthy.40.aspx](https://journals.lww.com/neuroreport/Fulltext/2002/12030/Brain_size_and_grey_matter_volume_in_the_healthy.40.aspx).

34. RStudio. RStudio Team (2021). RStudio: Integrated Development for R. <http://www.rstudio.com/>. RStudio, Inc. Boston, MA: RStudio; 2021

35. Allen M, Poggiali D, Whitaker K, Marshall TR, Van Langen J, Kievit RA. Raincloud plots: a multi-platform tool for robust data visualization. *Wellcome Open Research*. 2021;4:63. doi: 10.12688/wellcomeopenres.15191.2.

36. Ge Q, Peng W, Zhang J, Weng X, Zhang Y, Liu T, Zang Y-F, Wang Z. Short-term apparent brain tissue changes are contributed by cerebral blood flow alterations. *PloS one*. 2017;12(8):e0182182. doi: 10.1371/journal.pone.0182182.

37. Wylie GR, Genova H, Dobryakova E, DeLuca J, Chiaravalloti N, Falvo M, Cook D. Fatigue in Gulf War Illness is associated with tonically high activation in the executive control network. *NeuroImage Clinical*. 2019;21:101641. Epub 20181211. doi: 10.1016/j.nicl.2018.101641. PubMed PMID: 30558870; PMCID: PMC6411905.

38. Chaudhuri A, Behan PO. Fatigue and basal ganglia. *J Neurol Sci*. 2000;179(S 1-2):34-42. doi: 10.1016/s0022-510x(00)00411-1. PubMed PMID: 11054483.

39. Dobryakova E, Genova HM, DeLuca J, Wylie GR. The Dopamine Imbalance Hypothesis of Fatigue in Multiple Sclerosis and Other Neurological Disorders. *Frontiers in Neurology*. 2015;6(52). doi: 10.3389/fneur.2015.00052.

40. Wylie GR, Dobryakova E, DeLuca J, Chiaravalloti N, Essad K, Genova H. Cognitive fatigue in individuals with traumatic brain injury is associated with caudate activation. *Scientific reports*. 2017;7(1):8973. Epub 20170821. doi: 10.1038/s41598-017-08846-6. PubMed PMID: 28827779; PMCID: PMC5567054.

41. Dobryakova E, Hulst HE, Spirou A, Chiaravalloti ND, Genova HM, Wylie GR, DeLuca J. Frontostriatal network activation leads to less fatigue in multiple sclerosis. *Mult Scler*. 2018;24(9):1174-82. Epub 20170619. doi: 10.1177/1352458517717087. PubMed PMID: 28627957.

42. Dobryakova E, Genova H, Schneider V, Chiaravalloti ND, Spirou A, Wylie GR, DeLuca J. Reward presentation reduces on-task fatigue in traumatic brain injury. *Cortex*. 2020;126:16-25. Epub 20200124. doi: 10.1016/j.cortex.2020.01.003. PubMed PMID: 32062140.

43. Bornhövd K, Quante M, Glauche V, Bromm B, Weiller C, Büchel C. Painful stimuli evoke different stimulus-response functions in the amygdala, prefrontal, insula and somatosensory cortex: a single-trial

fMRI study. *Brain*. 2002;125(Pt 6):1326-36. Epub 2002/05/23. doi: 10.1093/brain/awf137. PubMed PMID: 12023321.

44. Inagaki TK, Muscatell KA, Irwin MR, Cole SW, Eisenberger NI. Inflammation selectively enhances amygdala activity to socially threatening images. *NeuroImage*. 2012;59(4):3222-6. Epub 2011/11/04. doi: 10.1016/j.neuroimage.2011.10.090. PubMed PMID: 22079507.

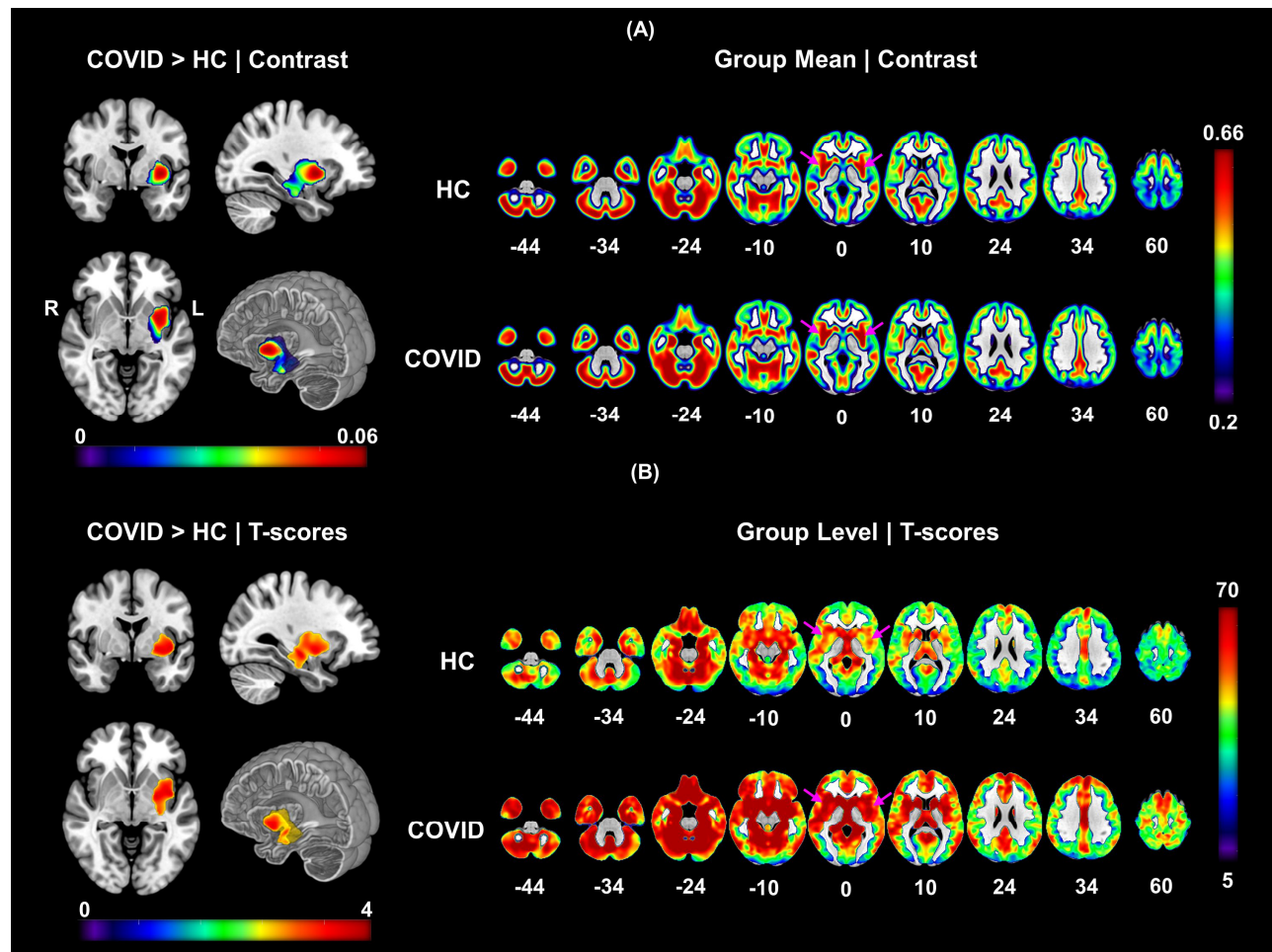
45. Sergeeva M, Rech J, Schett G, Hess A. Response to peripheral immune stimulation within the brain: magnetic resonance imaging perspective of treatment success. *Arthritis Research & Therapy*. 2015;17(1):268. doi: 10.1186/s13075-015-0783-2.

46. van Schouwenburg MR, den Ouden HE, Cools R. Selective attentional enhancement and inhibition of fronto-posterior connectivity by the basal ganglia during attention switching. *Cerebral cortex (New York, NY : 1991)*. 2015;25(6):1527-34. Epub 2013/12/18. doi: 10.1093/cercor/bht345. PubMed PMID: 24343891.

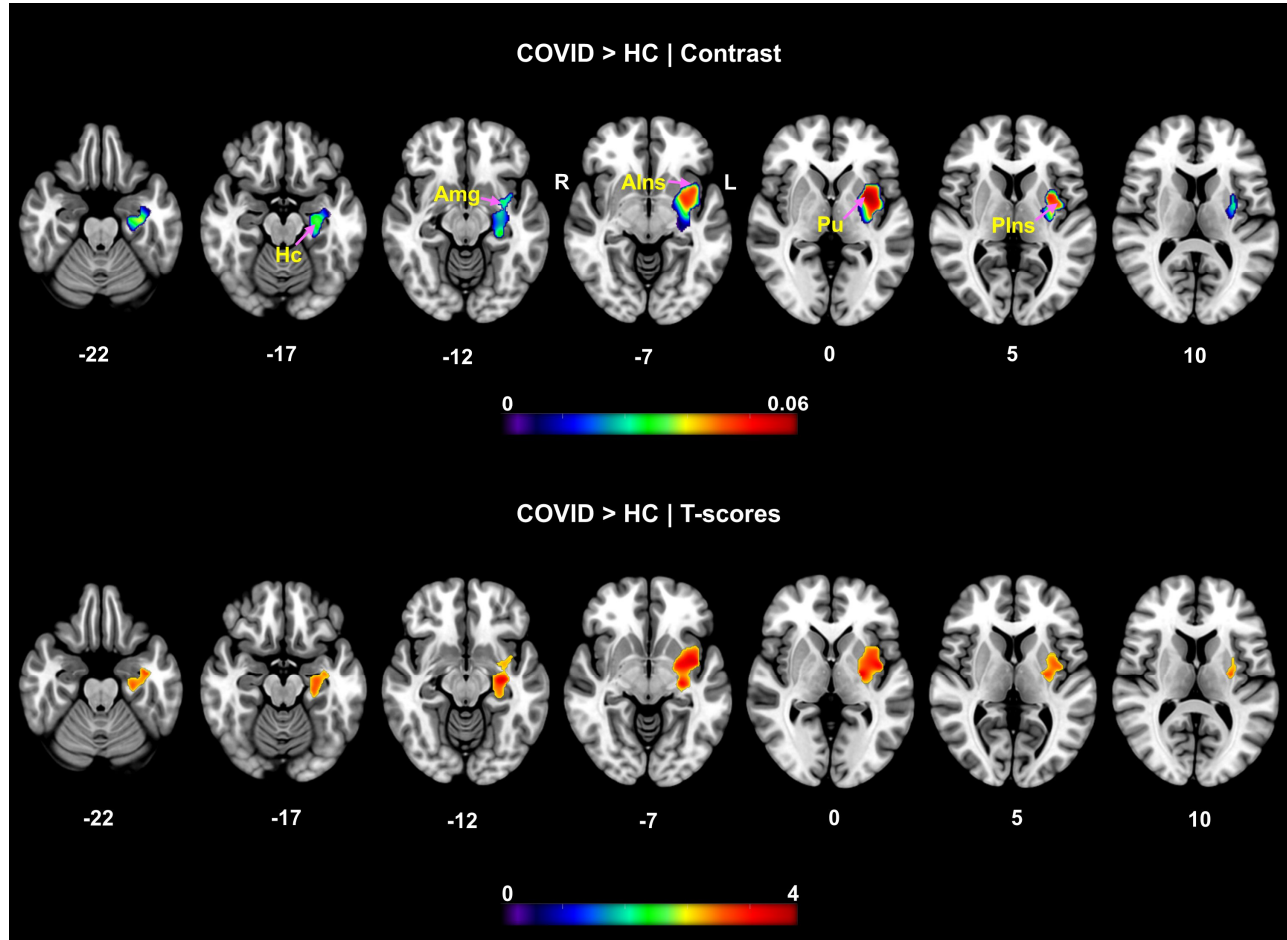
47. Scarpazza C, Nichols TE, Seramondi D, Maumet C, Sartori G, Mechelli A. When the Single Matters more than the Group (II): Addressing the Problem of High False Positive Rates in Single Case Voxel Based Morphometry Using Non-parametric Statistics. *Frontiers in neuroscience*. 2016;10:6-. doi: 10.3389/fnins.2016.00006. PubMed PMID: 26834533.

48. Gulko E, Oleksk ML, Gomes W, Ali S, Mehta H, Overby P, Al-Mufti F, Rozenshtein A. MRI Brain Findings in 126 Patients with COVID-19: Initial Observations from a Descriptive Literature Review. *American Journal of Neuroradiology*. 2020. doi: 10.3174/ajnr.A6805.

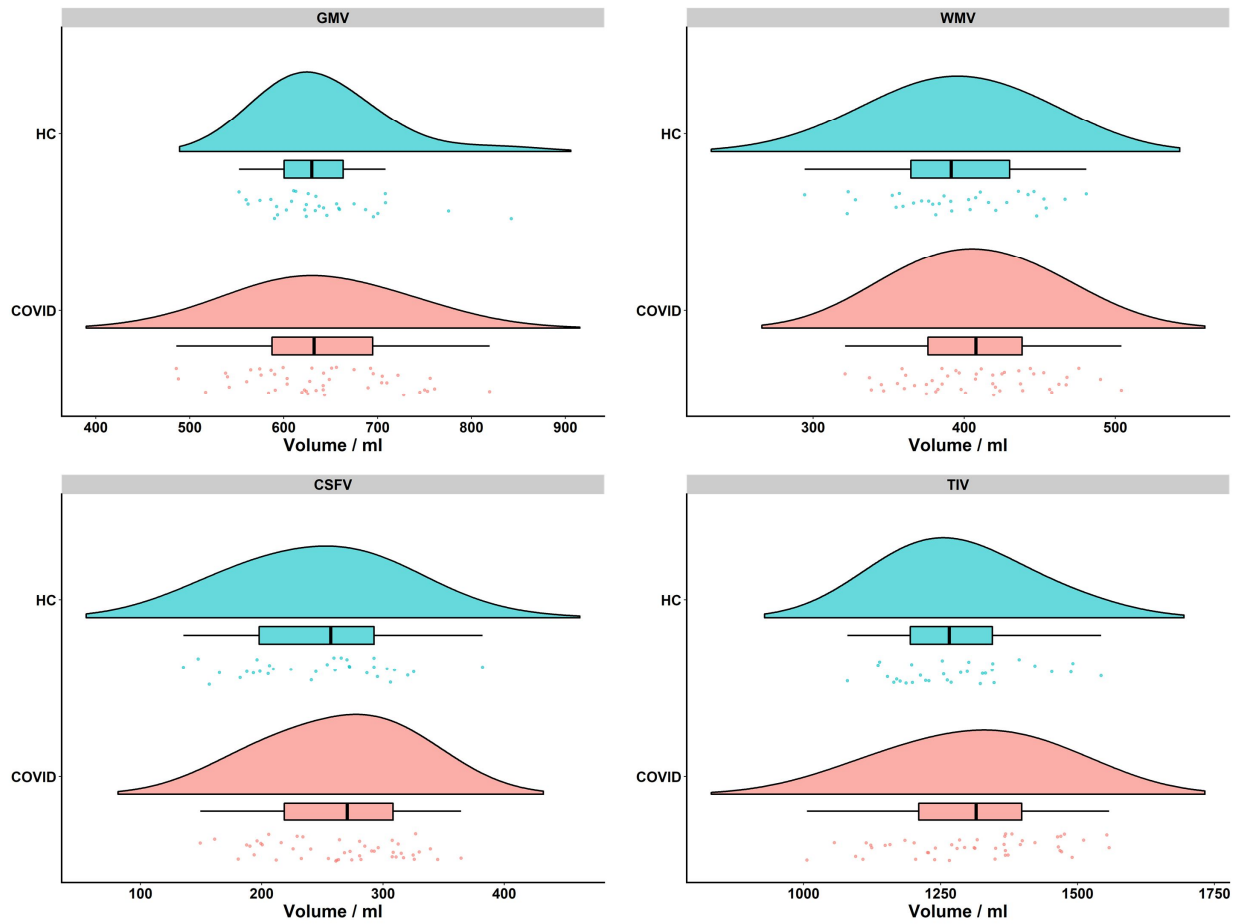
## Figures



**Figure 1. VBM demonstrating significantly higher gray matter volume in COVID-19 subjects compared to HC.** The significant cluster comprised of several deep brain structures: *Left – Hc, VDC, Pu, Pd, Am, PP, Plns, AIns, Plns, ThP*. The clusters surviving *FWE* correction for  $k_E = 3280$ , consisted of 3280 voxels, with peak t-score of 3.83 and exact corrected p-value of  $p = 0.007$  at MNI coordinates:  $[-28 -16 -10]$ . **(A)** The contrast maps from two sample t-test (left) and group-wise one sample t-test analysis (right). The orthogonal slices on the left show the difference maps along with a cut-to-depth volume rendered image to better visualize the spatial extent of the anatomical locations comprising the cluster. **(B)** The corresponding t-score maps for the contrasts shown in **(A)**. The purple arrows help locate anatomical regions where the difference in effects can be visually observed between the two groups.

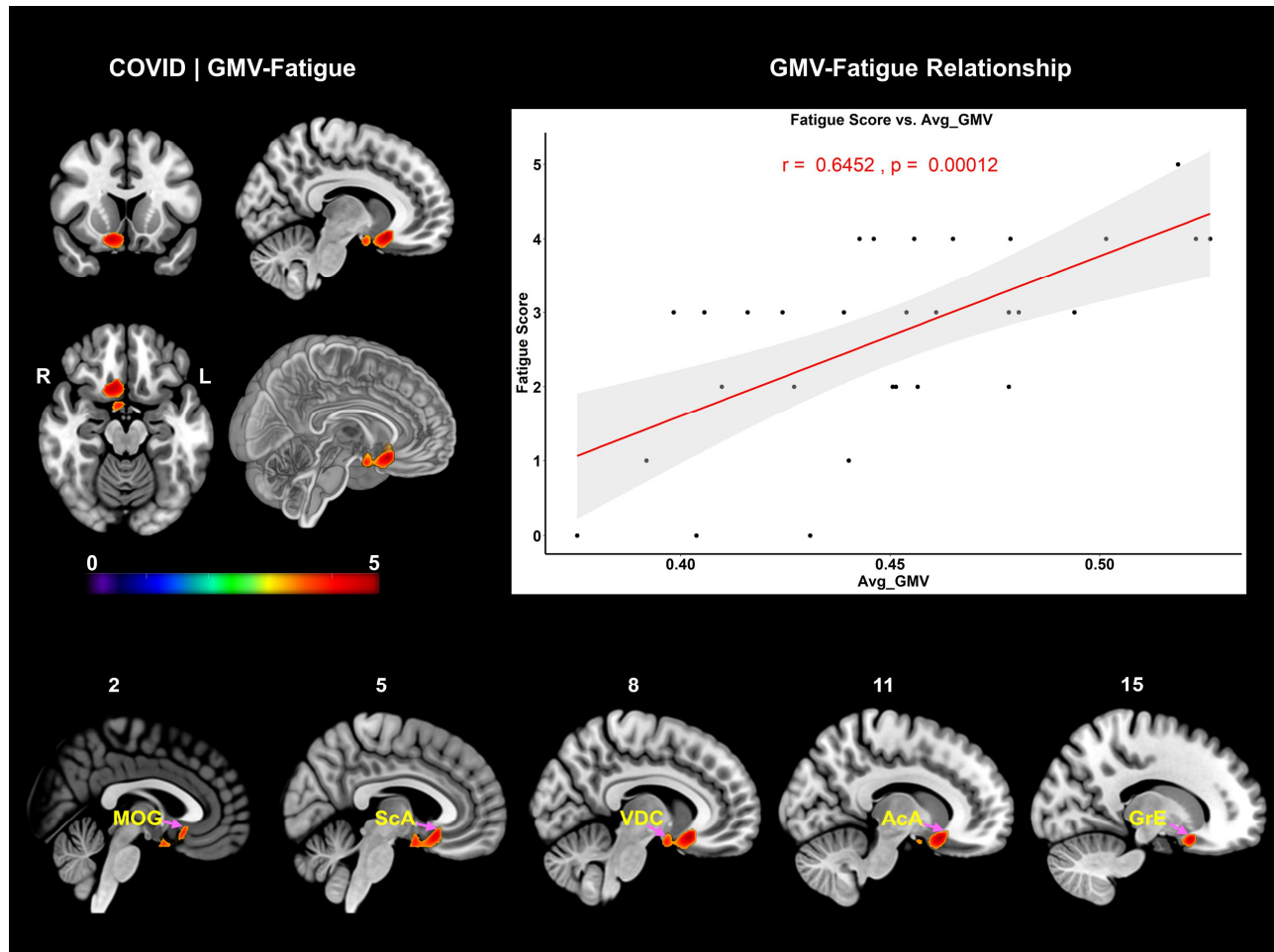


**Figure 2. Multi-slice view of the contrast and t-score difference maps.** The purpose of this figure is to use finer slices (Z-slice gap  $\geq 5$ ) to highlight and assess the structural regions with significantly higher GMV for the cluster shown in Figure 1. The axial slices on the top row show the contrast map for COVID > HC contrast and the bottom row shows the corresponding t-score map in the same spatial locations. The cluster extends from inferior to superior Z-slices spanning from *Hc* to *Alns*, *Pu*, and *Plns* regions, respectively.



**Figure 3. 'Raincloud' plots of compartmental and total intracranial volume distribution and central tendency measures from each group.** The figure shows the flat violin, box and dot plots all within the same frame for each group to assess the central tendency measures, such as the mean, standard deviation and inter-quartile range of compartmental volumes (top row and bottom left), as well as the TIV (bottom right) in each group. The cyan color represents the HC group, and the light pink color represents the COVID group in each plot. The box plot shows the tendency of higher group averaged WMV, CSFV and TIV in the COVID group and marginally lower GMV compared to the HC group. The individual volume values that drive this distribution can be assessed from the dot plot and the slight shift of the light-pink violin distribution plot to the right. GMV = Gray Matter Volume, WMV = White Matter Volume, CSFV = Cerebrospinal Fluid Volume, TIV = Total Intracranial Volume





**Figure 4. VBM demonstrating significantly positive correlation with fatigue scores in COVID-19 subjects.** The significant cluster comprised of: *Right – ScA, AcA, MOG, ACG, MFC, GRe, Cd, Pu, BsF, Amg, EnA, PHG* and *Bilateral – VDC*. The clusters surviving *FWE* correction for  $k_E = 746$ , consisted of 746 voxels, with peak *t*-score of 4.98 and exact corrected *p*-value of  $p_{FWE} = 0.04$  at MNI coordinates:  $[9\ 18\ -14]$ . The sagittal slices at the bottom show the spatial extent of the cluster over finer slices. The scatter plot with the linear regression line shows strong positive correlation ( $r = 0.65$ ,  $p = 0.0001$ ,  $r^2 = 0.42$ ) of averaged cluster GMV with self-reported fatigue score.

## Tables

Measures	<i>p</i>	<i>stat</i>	HC, mean (SD)	COVID, mean (SD)
Age (years)	0.49	-0.69 ( <i>t</i> )	32.91 (9.71)	34.63 (11.54)
Sex	0.30	1.07 ( $\chi^2$ )	25M, 7F	31M, 15F
GMV (ml)	0.88	0.15 ( <i>t</i> )	640.80 (62.00)	638.30 (76.39)
WMV (ml)	0.22	-1.24 ( <i>t</i> )	394.90 (45.78)	407.64 (43.93)
CSFV (ml)	0.17	-1.37 ( <i>t</i> )	245.750 (59.34)	263.48 (54.02)
TIV (ml)	0.35	-0.94 ( <i>t</i> )	1281.46 (117.72)	1309.42 (139.03)

**Table 1: Group level statistics on participant demographics and average volume of each tissue type in HC and COVID group.** GMV = Gray Matter Volume, WMV = White Matter Volume, CSFV= Cerebrospinal Fluid Volume, TIV = Total Intracranial Volume, *p* = *p*-value, *t* = two-sample *t*-test statistic,  $\chi^2$ = Chi-Squared statistic, ml = milliliter, M = Male, F = Female.