

## **Analysis of Corticosteroids in Immune Checkpoint Inhibitors (ICE) Induced Myocarditis – A Systematic Review of 352 Screened Articles**

### **Authors:**

Mona Sheikh\*, MD1,2; Saumil Patel 1, MD; Shavy Nagpal\*\* MD, Zeynep Yulkselen, MD 3; Samina Zahid, MD 1; Vivek Jha, MBBS 1; Diana F Sánchez-Velazco, MS4 4

\*\* The Research Institute of St. Joe's Hamilton, ON, Canada

Corresponding [shav.nagpal@gmail.com](mailto:shav.nagpal@gmail.com)

[\\*arztinmona@gmail.com](mailto:arztinmona@gmail.com)

### **Acknowledgement:**

Mohammed Stohy, MBBCh and Madiha Zaidi, MBBS: participated in article screening and data extraction.

### **Affiliation:**

1. Division of Clinical and Translational Research, Larkin Community Hospital, South Miami, Florida.
2. University of North Texas Health Science Center, School of Public Health, Fort Worth, Texas
3. University Of Massachusetts, Massachusetts
4. Cayetano Heredia Peruvian University, Lima, Perú

### **Conflict of interest:**

All authors declare no conflict of interest

### **Key words:**

ICI-induced myocarditis, ICI, treatment, diagnosis, corticosteroid

## ABSTRACT

**Introduction:** Immune Checkpoint Inhibitors (ICI) are used as a single agent or as a combination therapies for early or late-stage malignancies. The common malignancies that ICI targets include the following: melanoma, lung cancer, renal cell carcinoma, and hematological malignancies such as Hodgkin's lymphoma. ICI use is associated with many immune-related adverse events, and ICI-induced myocarditis is one of the rare and most severe AE with a high mortality rate. There are no consensus evidence-based treatment guideline; the expert recommendation is to use high-dose steroids. We aim in this review to assess the effectiveness of steroids in treating ICI-induced myocarditis.

**Methods:** We searched the following database Pubmed, Scopus, Cinhale, and Google Scholar, using the following keywords: ICI-induced myocarditis, treatment, steroid. We included articles in the English language, case reports, case series, and published in the last five years.

**Results:** 352 articles were screened using PRISMA guidelines. After excluding the articles that were duplicate, irrelevant, and did not meet inclusion criteria, 35 articles with a total number of 50 patients were included. All patients treated with ICI either as a single or combination regimen. The onset of symptoms post initiation varied from one day to a year. 46 out of the 50 cases received high doses of Intravenous steroids as a loading dose followed by an oral or intravenous maintenance dose. Out of 50 patients 14 patients (28 %) died but 34 (68 %) patients survived, and 2 (4 %) patients data were not available. The mean age of the patients was  $66.31 \pm 14.071$  (range 23-88 years), 29 were male (58%), 21 were female (42%). Most of the cases were from the USA (42%), followed by Australia (20 %), Japan (14%), Germany, France, and China (4%), Switzerland, Canada, and Spain (2%), and for (6%) cases. A total of 23 patients had cardiovascular comorbidities (46%), which were HTN (14 patients, 60.87%), hyperlipidemia (5 patients, 21.73%), and less than 1 % of patients had myocardial ischemia, congestive

heart failure, atrial fibrillation, and peripheral vascular disease. While 26 patients (52%) had normal basal cardiac status.

**Conclusion:** Our results showed that high doses of steroids were effective in controlling cardiac myocyte inflammation and mortality by 28%. Race was not included in the analysis as it was not reported. More in – depth studies are needed to provide a broader representation of steroids in myocarditis.

## **Introduction:**

### *Understanding Immune checkpoint inhibitors*

Immune Checkpoint inhibitors are monoclonal antibodies (IgG), which are produced by using hybridoma cells. [1] The monoclonal antibody binds to the regulatory receptor on T-cell lymphocyte named programmed cell death receptor 1 (PD-1), programmed cell death ligand 1 (PD-L1), and cytotoxic T-lymphocyte-associated protein 4 (CTLA-4). [2] The normal non-neoplastic cell expresses ligands that bind to these regulatory receptors and prevent them from attacking the normally functioning cell. The tumor cells overexpress PDL-1 which helps them to escape destruction by the immune cells. [2]

The monoclonal antibody binds to the regulatory receptors PD-1 (Nivolumab, Pembrolizumab, Cemiplimab), PD-L1 (Avelumab, Durvalumab, Atezolizumab), and CTLA-4 (Ipilimumab), the binding enables the immune system to attack and kill the cancer cells. [3] ICIs were reported to induce many immune-related adverse events (irAE) including, myositis, hepatitis, myasthenia gravis, and myocarditis. [4] Treatment with ICIs does not only affect the tumor cells but also the non-tumor cells as well. ICI use was found to cause an influx of lymphocytes and macrophages into the myocardium, which ultimately causes myocarditis. [5]

Based on the ICI mechanism of action, there is a theory that the myocardium expresses an antigen that is similar to the tumor cell antigen; therefore, it becomes a T-Lymphocyte target, and lymphocytes infiltrate the myocardium. [4] ICI-induced myocarditis is a rare irAE that presents with non-specific symptoms and is associated with a high mortality rate. [6] The clinical presentation of myocarditis varies widely, ranging from chest pain, fever, dyspnea, increased heart rate, and general body aches. [7, 8] Diagnosis confirmed with endomyocardial biopsy. [8] However, since this is an invasive test, initial investigations include cardiac labs such as Creatine kinase (CK), Troponin I (TnI), and Troponin T (TnT), echocardiogram, and cardiac MRI. [7,9] Myocarditis predominantly affects males as compared to females with individuals above the age of 40 years. [8]

There are no randomized controlled trials conducted to have evidence-based treatment guidelines for ICI-induced myocarditis treatment. The guidelines recommend discontinuation of the ICI and giving high-dose steroids, which are expert experience and agreements. We are aiming in this systematic review to evaluate the effectiveness of steroids and obtain a valid conclusion.

## **Methods:**

**Search Strategy:** This systematic review was conducted according to the Preferred Reporting Items for Systematic Reviews and Meta-Analyses (PRISMA) guidelines. An extensive literature search was performed in PubMed, Scopus, and CINAHL for case reports and case series. The following terms were used in MeSH and free-text searches: myocarditis, cancer, corticosteroid, steroid, immune checkpoint inhibitor, immune checkpoint blockade, checkpoint inhibitor, immune-related adverse events, immunotherapy, adverse effect, immunosuppressive, glucocorticoid, cyclosporine, mycophenolate mofetil, azathioprine, prednisone, methylprednisolone, infliximab, anti-thymocyte globulin, drug-induced myocarditis. The “related articles” function of PubMed was used for broadening the search. We attempted to identify additional studies by searching the reference lists of selected articles.

**Inclusion Criteria:** We included all case reports and case series that met the following criteria:

- ❑ Studies focused on myocarditis induced by Immune checkpoint inhibitors and received steroid or non-steroid as a treatment.
- ❑ Myocarditis is diagnosed by biopsy or CMRI (cardiac magnetic resonance imaging) or autopsy
- ❑ Time interval between years 2016-2020
- ❑ Articles published in English in a peer-reviewed journal
- ❑ Participants are at least 18 years old or above.

**Exclusion Criteria:** We excluded articles with the following criteria:

- ❑ patients aged < 18 years
- ❑ patients did not receive myocarditis treatment or the treatment not reported
- ❑ myocarditis is not induced by immune checkpoint inhibitors
- ❑ the diagnosis is not confirmed by biopsy or cardiac MRI
- ❑ non-English articles.

**Study Selection:** All case reports and case series studies that evaluated the efficacy of steroid or non-steroid treatment in ICI-induced myocarditis were downloaded into Covidence from search engines.

During the first step of this literature search, title and abstract screening were done by two independent reviewers using Covidence. A third independent reviewer resolved any conflict that arose. After completing the title and abstract screening, the full-text of eligible studies was screened in detail by two independent reviewers according to the inclusion and exclusion criteria set before. Any conflict was resolved by a third independent reviewer. Eventually, studies were selected for data extraction. Two independent reviewers performed the screening of each study and any type of discrepancies were resolved through discussions until they reached a consensus. [Figure 1]

**Data Extraction:** For all included studies, six review authors independently extracted data and summarized characteristics in tables. Authors mainly extracted these characteristics: author name, publication year, patient age and gender, type of cancer, stage of cancer, comorbidity, symptoms, ECG, echocardiogram, lab values, CMR, biopsy, type of myocarditis treatment (initial treatment, secondary treatment), the dose of steroid or other drugs, the outcome of initial and secondary treatment, prognosis, mortality, autopsy.

**Data Analysis:** We used IBM SPSS and Microsoft Excel software to run data analysis. Continuous variables are presented as mean  $\pm$  SD, and categorical variables are presented as absolute numbers and percentages.

**Assessment of risk of bias:** JBI critical appraisal checklists for case series were applied for quality and risk of bias assessment. There were eight questions in the checklist against which the quality of the study was evaluated. There were three possible answers to the questions, either yes, no, or unclear. Based on that, the overall appraisal of the studies was determined. [Table 1]

**Table1: Bias assessment**

	<b>First Author</b>	<b>Q1</b>	<b>Q2</b>	<b>Q3</b>	<b>Q4</b>	<b>Q5</b>	<b>Q6</b>	<b>Q7</b>	<b>Q8</b>	<b>Overall appraisal</b>
1	<b>Saibil 2019</b>	<i>yes</i>	<i>yes</i>	<i>yes</i>	<i>yes</i>	<i>yes</i>	<i>yes</i>	<i>unclear</i>	<i>yes</i>	Include
2	<b>Monge 2018</b>	<i>yes</i>	<i>Yes</i>	<i>Yes</i>	<i>Yes</i>	<i>Yes</i>	<i>Yes</i>	<i>No</i>	<i>Yes</i>	Include
3	<b>Guo 2020</b>	<i>Yes</i>	<i>Yes</i>	<i>Yes</i>	<i>Yes</i>	<i>Yes</i>	<i>Yes</i>	<i>unclear</i>	<i>Yes</i>	Include
4	<b>Padegimas 2019</b>	<i>Yes</i>	<i>Yes</i>	<i>Yes</i>	<i>Yes</i>	<i>Yes</i>	<i>Yes</i>	<i>No</i>	<i>Yes</i>	Include
5	<b>Salem 2019</b>	<i>No</i>	<i>Yes</i>	<i>Yes</i>	<i>Yes</i>	<i>Yes</i>	<i>Yes</i>	<i>No</i>	<i>Yes</i>	Include
6	<b>Liu 2020</b>	<i>Yes</i>	<i>Yes</i>	<i>Yes</i>	<i>Yes</i>	<i>Yes</i>	<i>Yes</i>	<i>unclear</i>	<i>yes</i>	Include
7	<b>Jain 2018</b>	<i>Yes</i>	<i>No</i>	<i>Yes</i>	<i>Yes</i>	<i>Yes</i>	<i>Yes</i>	<i>unclear</i>	<i>yes</i>	Include
8	<b>Semper 2016</b>	<i>Yes</i>	<i>Yes</i>	<i>Yes</i>	<i>Yes</i>	<i>Yes</i>	<i>Yes</i>	<i>unclear</i>	<i>Yes</i>	Include

9	<b>Tadokoro 2016</b>	Yes	Yes	Yes	Yes	Yes	Yes	<i>unclear</i>	Yes	Include
10	<b>Ganatra 2018</b>	Yes	Yes	Yes	Yes	Yes	Yes	No	Yes	Include
11	<b>Frigeri 2018</b>	Yes	Yes	Yes	Yes	Yes	Yes	<i>unclear</i>	Yes	Include
12	<b>Heinzerling 2016</b>	Yes	Yes	Yes	Yes	Yes	Yes	<i>unclear</i>	Yes	Include
13	<b>Gallegos 2019</b>	Yes	Yes	Yes	Yes	Yes	No	No	Yes	Include
14	<b>Johnson 2016</b>	Yes	Yes	Yes	Yes	Yes	Yes	No	Yes	Include
15	<b>Matsui 2020</b>	Yes	Yes	Yes	Yes	Yes	Yes	No	Yes	Include
16	<b>Edahiro 2020</b>	Yes	Yes	Yes	Yes	Yes	Yes	No	Yes	Include
17	<b>Imai 2019</b>	Yes	Yes	Yes	Yes	Yes	Yes		Yes	Include\
18	<b>Norwood 2017</b>	Yes	Yes	Yes	Yes	Yes	Yes	No	Yes	Include
19	<b>Leaver 2020</b>	Yes	Yes	Yes	Yes	Yes	Yes	No	Yes	Include
20	<b>LoongTan 2020</b>	Yes	Yes	Yes	Yes	Yes	Yes	No	Yes	Include
21	<b>Matsuo 2019</b>	Yes	Yes	Yes	Yes	Yes	Yes	No	Yes	Include
22	<b>Chang 2018</b>	Yes	Yes	Yes	Yes	Yes	Yes	No	Yes	Include
23	<b>Martin Huertas 2019</b>	Yes	No	Yes	Yes	Yes	Yes	No	Yes	Include
24	<b>Tay 2017</b>	Yes	No	Yes	Yes	Yes	Yes	No	Yes	Include
25	<b>Lee 2020</b>	Yes	Yes	Yes	Yes	Yes	Yes	No	Yes	Include
26	<b>Hardy 2020</b>	Yes	Yes	Yes	Yes	Yes	Yes	No	Yes	Include
27	<b>Tan 2020</b>	Yes	Yes	Yes	Yes	Yes	Yes	No	Yes	Include
28	<b>Mahmood 2018</b>	Yes	Yes	Yes	Yes	Yes	Yes	No	Yes	Include
29	<b>Lie 2020</b>	Yes	Yes	Yes	Yes	Yes	Yes	No	Yes	Include
30	<b>Mehta 2016</b>	Yes	Yes	Yes	Yes	Yes	Yes	No	Yes	Include
31	<b>Ansari-Gllani 2020</b>	Yes	Yes	Yes	Yes	Yes	Yes	No	Yes	Include

---

32	<b>Fukasawa</b>	Yes	Yes	Yes	Yes	Yes	Yes	Unclear	Yes	Include
33	<b>Yamaguchi</b>	Yes	Yes	Yes	Yes	Yes	Yes	Unclear	Yes	Include
34	<b>Tajmir-Riahi</b>	Yes	Yes	Yes	Yes	Yes	Yes	Unclear	Yes	Include
35	<b>Arangalage</b>	Yes	Yes	Yes	Yes	Yes	Yes	No	Yes	Include

---

*Bias assessment answer: Yes/No/Unclear/ Not Applicable*

*Overall appraisal: included/excluded/seek further information*

Q1: Were the patient's demographic characteristics clearly described?

Q2: Was the patient's history clearly described and presented as a timeline?

Q3: Was the current clinical condition of the patient on presentation clearly described?

Q4: Were diagnostic tests or assessment methods and the results clearly described?

Q5: Was the intervention(s) or treatment procedure(s) clearly described?

Q6: Was the post-intervention clinical condition clearly described?

Q7: Were adverse events (harms) or unanticipated events identified and described?

Q8: Does the case report provide takeaway lessons?

## **Results:**

We identified 352 articles through our search from PubMed, Scopus, and CINAHL. From the 35 articles we selected, a total of 50 patients met our inclusion criteria and were analyzed.

Of 50 patients, 26 had malignant melanoma (53%), 8 had carcinoma of the lung (16%), 4 had renal cell carcinoma (8%), 1 had bladder cell carcinoma (2%), other carcinomas account for less than 2% in remaining individuals. [Table 3] Regarding the cancer stage, 35 patients (70%) were in Stage IV cancer, 7 (14%) were in stage III and remained in the lower stage or undetermined.



42 out of 50 patients (84 %) were symptomatic, major presenting cardiovascular symptoms were dyspnea (22 patients, 41.50%), chest pain (9 patients, 18 %), and chest tightness and edema (4 patients, 8 %). On the other hand, 8 out of 50 patients (16 %) were asymptomatic.

All 50 patients who received immune check inhibitors have developed myocarditis. [Table 4] Among them, 32 patients (64 %) received nivolumab, 19 patients (38 %) received Ipilimumab, 2 patients (4 %) received vemurafenib and Atezolizumab, the patients received Pembrolizumab, Temozolomide, durvalumab, tremelimumab as a combination of about drugs. 17 out of the 50 reviewed cases were on a combination regimen of either Nivolumab and Ipilimumab (15 cases, 30%), durvalumab, and tremelimumab (1 case, 2%), and Nivolumab and Pembrolizumab (1 case, 2%). [Table 4]

Out of 50, 47 patients had been diagnosed with either cardiac MRI or cardiac biopsy, and the remaining 3 patients were diagnosed with autopsy reports. The time of the onset of symptoms after initiation of immune check inhibitors ranges from 1st day after initiation of the treatment to 1 year (from 1st dose to the 13th dose). Those who were on combination ICI had earlier symptoms compared to patients on one ICI, 10 out of 17 patients who were on combination regimen presented with their symptoms after the first dose. [13, 18, 18, 24, 27, 25, 36, 37]

Out of 50 patients, 23 patients (46%) had elevated CK, 13 (26 %) patients had elevated CK-MB, 37 (74 %) patients had increased troponin I/T, 13 (26 %) patients had increased BNP level, 7 (14 %) patients had increased other test including AST, ALT, ANA titer, CRP, LDH, interleukin, myoglobin levels. The mean of ejection fraction was  $39.56 \% \pm 17.72 \%$  (13%-73%).

46 out of the 50 cases received high doses of Intravenous steroids as a loading dose followed by an oral or intravenous maintenance dose. Out of 50 patients 14 patients (28 %) died but 34 (68 %) patients

survived, and 2 (4 %) patients' data was not available. In terms of steroid effectiveness, 47.16% of patients improved while 52.83% did not improve completely and needed adding additional regimen, the added treatment infliximab, IgG, mycophenolate, Tacrolimus, plasma exchange, and plasmapheresis.

The causes of death in the 14th mortality were as following myocardial infarction (MI) [4, 18, 23, 33], multiple organ failure (MOF) [18, 36], complete heart block (CHB) [19, 36], ventricular tachycardia (VT) [18, 4], congestive heart failure (CHF) [19, 30], PE/bacteremia [31], hypotension/diaphragmatic paralysis [37], and progressive lung cancer [11]. The follow-up time ranged from 3 days to 26 months. 3 out of the 4 MI deaths occurred within 7 days of hospital admission, VT also within the first couple days of admission, lastly, the 2 deaths of CHB were on the third and 17th days.

#### **Discussion:**

Immune checkpoint inhibitors are a cutting-edge, promising therapy for many malignancies. The FDA approved several ICI in the last decade; initial approval for Ipilimumab, nivolumab, Pembrolizumab, Cemiplimab, Avelumab, Durvalumab, and Atezolizumab was on 28 March 2011, 22 December 2014, 4 September 2014, 28 September 2018, 18 November 2015, 17 February 2016, and 18 May 2016, respectively. [2] They were approved as a single agent or as a combination regimen for advanced or early stages of the following tumor melanoma, renal cell carcinoma (RCC), squamous non-small-cell lung cancer (NSCLC), urothelial cancer such bladder urothelial cancer, colorectal cancer, hepatocellular carcinoma (HCC), head and neck squamous cell carcinoma (HNSCC), cutaneous squamous cell carcinoma (CSCC), Hodgkin's lymphoma, Merkel Cell carcinoma (MCC), cervical and breast cancer. [2]

[Table 2]

ICI-induced myocarditis is one of the rare and severe forms of irAE of ICI with a high mortality rate. The myocarditis was underestimated during the ICI clinical trials due to the low incidence and vague clinical presentation. For example, in the Nivolumab clinical trial, the most common adverse events were fatigue (33%), nausea (14%), and pruritus (14%); and no cardiac adverse event or death was reported due to the drug toxicity. [4]

Our result showed 81.13% of the patients with ICI-induced myocarditis had cardiovascular symptoms, which were dyspnea (41.50%), chest pain (16.98%), and chest tightness and edema (7.54%). Also, the common general presenting symptoms were fatigue, myalgia, general discomfort, or nausea, which are similar to what is reported in other studies.[7, 8] In addition to the non-specificity of clinical presentation which poses a challenge in the diagnosis, the median reporting time varies which adds another hurdle to diagnose a case of ICI-induced myocarditis. Our results showed the median time onset of symptoms after initiation of the therapy was 79.50 days, 16 days reported by Matznel et al, and 6 months reported in Dolldile et al cohort retrospective study and a year in Gallegos et al. [10, 17, 44] Hence, clinicians should have a high index of suspicion when managing patients on an ICI treatment regimen even if the treatment was initiated over 6 months or a year ago and should be aware of the ICI cardiac adverse events and the need for prolonged cardiac monitoring.

The diagnosis of ICI Induced-myocarditis is predictive of abnormal values in cardiac enzymes such as troponin, ECG, and echocardiogram. The confirmatory tests are cardiac MRI (CMRI) and endomyocardial biopsy. [42, 43] Endomyocardial biopsy is the gold standard test to diagnose ICI-induced myocarditis, however, it is an invasive procedure with high false negative probability due to patchy distribution of the inflammatory lesions and probability of missing to sample the inflamed region of the heart. The microscopic findings are commonly T-cell lymphocyte predominant infiltration and fibrosis which are

similar to graft rejection. [18] Cardiac MRI, a noninvasive, detects the macroscopic changes in the heart with late gadolinium enhancement that reflects the edema in the myocyte secondary to inflammation. Cardiac MRI also is used to monitor the progression of the disease and response to therapy. [42] ECG abnormalities vary and are non-specific, including tachycardia, bradyarrhythmia, heart block, atrial and ventricular tachyarrhythmia. We found complete heart block and ventricular tachyarrhythmia among the leading causes of death in patients taking ICI. [43, 19, 36, 40]

The recommended treatment for ICI-induced myocarditis is high-dose corticosteroids such as methylprednisolone. Steroid use is based on its anti-inflammatory action and decreasing inflammation size. In addition to corticosteroid, immunosuppressive agents as infliximab [15, 17, 18, 31, 37, 38], intravenous immunoglobulin (IVG) [11, 13, 22, 24, 37, 38, 41], antithymocyte [35], and plasma exchange [19, 24, 33], and plasmapheresis [36, 38] are used as a secondary treatment after corticosteroid trial. [11] Also, myco-phenolate mofetil (MMF) [27, 28, 30] and tacrolimus [11, 20, 24, 41], tofacitinib [41], and abatacept [32] were used and they helped in the management and controlling the inflammation. The rationale for using infliximab and anti-TNF drug based on IC-induced myocarditis microscopic finding, these drugs decrease T-lymphocyte activity and have been considered for the treatment of myocarditis related to autoimmune or infectious disease, therefore, it is recommended to be used in IC-induced myocarditis.[4]

The current guideline for ICI-induced myocarditis treatment is based on expert consensus, not on clinical trial evidence-based, the recommendations state discontinuation of ICI, immunosuppressive with use of high dose steroid and heart failure treatment or arrhythmia treatment. [uptodate] We aim to assess the effectiveness of steroids in ICI-induced myocarditis and our results showed, with the use of steroids, the fatality in the 50 reviewed cases was 28%, and 64.15% of patients survived. In terms of steroid

effectiveness 47.16% of patients improved while 52.83% did not improve completely and needed adding additional regimen, the commonly used added treatment infliximab, IgG, mycophenolate, Tacrolimus, plasma exchange, and plasmapheresis. Our reported fatality rate is about half what Matzen et al observed 48%. [10] The difference could be explained by the difference in inclusion and exclusion criteria between our reviews, we included only cases whose diagnoses were confirmed either by biopsy, CMRI or autopsy to minimize any confoundings. [Table 2] While Matzen et al did not specify that, therefore, it can't be certain that all fatality cases were a result of ICI cardiac adverse events.

The causes of death in the 14th mortality were as following myocardial infarction (MI) [4, 18, 23, 33], multiple organ failure (MOF) [18, 36], complete heart block (CHB) [19, 36], ventricular tachycardia (VT) [18, 40], congestive heart failure (CHF) [19, 30], PE/bacteremia [31], hypotension/diaphragmatic paralysis [37], and progressive lung cancer. [11] The follow-up time ranged from 3 days to 26 months. 3 out of the 4 MI deaths occurred within 7 days of hospital admission, VT also within the first couple days of admission, lastly, the 2 deaths of CHB were on the third and 17th days. This should prompt the clinicians to be highly vigilant for acute deterioration of myocarditis cases and fatal complications that are associated with. One of the cases had myocarditis resolved and was discharged and died from MI in the 26 months from myocarditis diagnosis. One out of the 14 deceased did not receive steroids [40], 3 had infliximab [17, 18, 37] as an additional treatment, 2 IVG [11, 37], and 2 plasma exchange/plasmapheresis [19, 36]. Mehta et al concluded that myocarditis induced by ICI is a fatal complication of irAE steroid, alemtuzumab or abatacept are all possible treatments for IC-induced myocarditis, while infliximab is associated with increased risk of death from cardiovascular causes and should be avoided. [26] Dolladille et al argued against the current recommendation which states discontinuation of ICI therapy in life-threatening situations but Dolladille et al prefer management should be individualized or personalized cases by case based on the patient's cancer status and toxicity

progression and recommended both cardiological and oncological care approach. [44] Also, Huerta et recommended multidisciplinary teamwork including an oncologist, cardiologist, radiologist, and pathologist in the care of ICI patients to optimally manage and reduce mortality [4]

### **Conclusion:**

Immune checkpoint inhibitors (ICI) are the therapy used against malignant neoplasms with or without combined drugs, so we are focusing on an adverse effect, myocarditis. This study shows that corticosteroids achieve a low mortality rate in patients with ICI-induced myocarditis, which, although it is a rare presentation, is serious. But the effectiveness of steroids was not high, the majority of patients needed another supplementary handling.

### **References:**

1. al-Rubeai, M., & Emery, A. N. (1990). Mechanisms and kinetics of monoclonal antibody synthesis and secretion in synchronous and asynchronous hybridoma cell cultures. *Journal of biotechnology*, 16(1-2), 67–85. [https://doi.org/10.1016/0168-1656\(90\)90066-k](https://doi.org/10.1016/0168-1656(90)90066-k)
2. Hino, R., Kabashima, K., Kato, Y., Yagi, H., Nakamura, M., Honjo, T., Okazaki, T., & Tokura, Y. (2010). Tumor cell expression of programmed cell death-1 ligand 1 is a prognostic factor for malignant melanoma. *Cancer*, 116(7), 1757–1766. <https://doi.org/10.1002/cncr.24899>
3. Vaddepally, R. K., Kharel, P., Pandey, R., Garje, R., & Chandra, A. B. (2020). Review of Indications of FDA-Approved Immune Checkpoint Inhibitors per NCCN Guidelines with the Level of Evidence. *Cancers*, 12(3), 738. <https://doi.org/10.3390/cancers12030738>
4. Martin Huertas, R., Saavedra Serrano, C., Perna, C., Ferrer Gómez, A., & Alonso Gordo, T. (2019). Cardiac toxicity of immune-checkpoint inhibitors: a clinical case of nivolumab-induced myocarditis and review of the evidence and new challenges. *Cancer management and research*, 11, 4541–4548. <https://doi.org/10.2147/CMAR.S185202>

5. Xia, W., Zou, C., Chen, H., Xie, C., & Hou, M. (2020). Immune checkpoint inhibitor induces cardiac injury through polarizing macrophages via modulating microRNA-34a/Kruppel-like factor 4 signaling. *Cell death & disease*, 11(7), 575. <https://doi.org/10.1038/s41419-020-02778-2>
6. Salem, J. E., Manouchehri, A., Moey, M., Lebrun-Vignes, B., Bastarache, L., Pariente, A., Gobert, A., Spano, J. P., Balko, J. M., Bonaca, M. P., Roden, D. M., Johnson, D. B., & Moslehi, J. J. (2018). Cardiovascular toxicities associated with immune checkpoint inhibitors: an observational, retrospective, pharmacovigilance study. *The Lancet. Oncology*, 19(12), 1579–1589. [https://doi.org/10.1016/S1470-2045\(18\)30608-9](https://doi.org/10.1016/S1470-2045(18)30608-9)
7. Chang, A., Nasti, T. H., Khan, M. K., Parashar, S., Kaufman, J. L., Boise, L. H., Lonial, S., Ahmed, R., & Nooka, A. K. (2018). Myocarditis With Radiotherapy and Immunotherapy in Multiple Myeloma. *Journal of oncology practice*, 14(9), 561–564. <https://doi.org/10.1200/JOP.18.00208>
8. Ganatra, S., & Neilan, T. G. (2018). Immune Checkpoint Inhibitor-Associated Myocarditis. *The oncologist*, 23(8), 879–886. <https://doi.org/10.1634/theoncologist.2018-0130>
9. Shirai, T., Kiniwa, Y., Sato, R., Sano, T., Nakamura, K., Mikoshiba, Y., Ohashi, N., Sekijima, Y., & Okuyama, R. (2019). Presence of antibodies to striated muscle and acetylcholine receptor in association with occurrence of myasthenia gravis with myositis and myocarditis in a patient with melanoma treated with an anti-programmed death 1 antibody. *European journal of cancer (Oxford, England : 1990)*, 106, 193–195. <https://doi.org/10.1016/j.ejca.2018.10.025>
10. Matzen, E., Bartels, L. E., Løgstrup, B., Horskær, S., Stilling, C., & Donskov, F. (2021). Immune checkpoint inhibitor-induced myocarditis in cancer patients: a case report and review of reported cases. *Cardio-oncology (London, England)*, 7(1), 27. <https://doi.org/10.1186/s40959-021-00114-x>
11. Imai, R., Ono, M., Nishimura, N., Suzuki, K., Komiyama, N., & Tamura, T. (2019). Fulminant Myocarditis Caused by an Immune Checkpoint Inhibitor: A Case Report With Pathologic Findings. *Journal of thoracic oncology : official publication of the International Association for the Study of Lung Cancer*, 14(2), e36–e38. <https://doi.org/10.1016/j.jtho.2018.10.156>
12. Norwood, T. G., Westbrook, B. C., Johnson, D. B., Litovsky, S. H., Terry, N. L., McKee, S. B., Gertler, A. S., Moslehi, J. J., & Conry, R. M. (2017). Smoldering myocarditis following immune checkpoint blockade. *Journal for immunotherapy of cancer*, 5(1), 91. <https://doi.org/10.1186/s40425-017-0296-4>

13. Leaver, P. J., Jang, H. S., Vernon, S. T., & Fernando, S. L. (2020). Immune checkpoint inhibitor-mediated myasthenia gravis with focal subclinical myocarditis progressing to symptomatic cardiac disease. *BMJ case reports*, 13(5), e232920. <https://doi.org/10.1136/bcr-2019-232920>
14. Matsuo, K., Ishiguro, T., Najama, T., Shimizu, Y., Kobayashi, Y., & Mutou, M. (2019). Nivolumab-induced Myocarditis Successfully Treated with Corticosteroid Therapy: A Case Report and Review of the Literature. *Internal medicine (Tokyo, Japan)*, 58(16), 2367–2372. <https://doi.org/10.2169/internalmedicine.2596-18>
15. Tay, R. Y., Blackley, E., McLean, C., Moore, M., Bergin, P., Gill, S., & Haydon, A. (2017). Successful use of equine anti-thymocyte globulin (ATGAM) for fulminant myocarditis secondary to nivolumab therapy. *British journal of cancer*, 117(7), 921–924. <https://doi.org/10.1038/bjc.2017.253>
16. Lee, D. H., Armanious, M., Huang, J., Jeong, D., Druta, M., & Fradley, M. G. (2020). Case of pembrolizumab-induced myocarditis presenting as torsades de pointes with safe re-challenge. *Journal of oncology pharmacy practice : official publication of the International Society of Oncology Pharmacy Practitioners*, 26(6), 1544–1548. <https://doi.org/10.1177/1078155220904152>
17. Gallegos, C., Rottmann, D., Nguyen, V. Q., & Baldassarre, L. A. (2019). Myocarditis with checkpoint inhibitor immunotherapy: case report of late gadolinium enhancement on cardiac magnetic resonance with pathology correlate. *European heart journal. Case reports*, 3(1), yty149. <https://doi.org/10.1093/ehjcr/yty149>
18. Johnson, D. B., Balko, J. M., Compton, M. L., Chalkias, S., Gorham, J., Xu, Y., Hicks, M., Puzanov, I., Alexander, M. R., Bloomer, T. L., Becker, J. R., Slosky, D. A., Phillips, E. J., Pilkinton, M. A., Craig-Owens, L., Kola, N., Plautz, G., Reshef, D. S., Deutsch, J. S., ... Moslehi, J. J. (2016).



- Fulminant myocarditis with combination immune checkpoint blockade. *New England Journal of Medicine*, 375(18), 1749-1755. <https://doi.org/10.1056/NEJMoa1609214>
19. Matsui, H., Kawai, T., Sato, Y., Ishida, J., Kadowaki, H., Akiyama, Y., Yamada, Y., Nakamura, M., Yamada, D., Akazawa, H., Suzuki, M., Komuro, I., & Kume, H. (2020). A Fatal Case of Myocarditis Following Myositis Induced by Pembrolizumab Treatment for Metastatic Upper Urinary Tract Urothelial Carcinoma. *International heart journal*, 61(5), 1070–1074.  
<https://doi.org/10.1536/ihj.20-162>
20. Edahiro
21. Fukasawa, Y., Sasaki, K., Natsume, M., Nakashima, M., Ota, S., Watanabe, K., Takahashi, Y., Kondo, F., Kozuma, K., & Seki, N. (2017). Nivolumab-Induced myocarditis concomitant with myasthenia gravis. *Case Reports in Oncology*, 10(3), 809–812.  
<https://doi.org/10.1159/000479958>
22. Yamaguchi, S., Morimoto, R., Okumura, T., Yamashita, Y., Haga, T., Kuwayama, T., Yokoi, T., Hiraiwa, H., Kondo, T., Sugiura, Y., Watanabe, N., Kano, N., Kohno, K., Fukaya, K., Sawamura, A., Yokota, K., Ishii, H., Nakaguro, M., Akiyama, M., & Murohara, T. (2018). Late-Onset Fulminant Myocarditis With Immune Checkpoint Inhibitor Nivolumab. *The Canadian journal of cardiology*, 34(6), 812.e1–812.e3. <https://doi.org/10.1016/j.cjca.2018.03.007>
23. Tajmir-Riahi, A., Bergmann, T., Schmid, M., Agaimy, A., Schuler, G., & Heinzerling, L. (2018). Life-threatening Autoimmune Cardiomyopathy Reproducibly Induced in a Patient by Checkpoint Inhibitor Therapy. *Journal of immunotherapy (Hagerstown, Md. : 1997)*, 41(1), 35–38.  
<https://doi.org/10.1097/CJI.0000000000000190>
24. Arangalage, D., Delyon, J., Lermuzeaux, M., Ekpe, K., Ederhy, S., Pages, C., & Lebbé, C. (2017). Survival After Fulminant Myocarditis Induced by Immune-Checkpoint Inhibitors. *Annals of internal medicine*, 167(9), 683–684. <https://doi.org/10.7326/L17-0396>

25. Tan, J. L., Mugwagwa, A. N., Cieslik, L., & Joshi, R. (2019). Nivolumab-induced myocarditis complicated by complete atrioventricular block in a patient with metastatic non-small cell lung cancer. *BMJ case reports*, 12(7), e229963. <https://doi.org/10.1136/bcr-2019-229963>
26. Mehta, A., Gupta, A., Hannallah, F., Koshy, T., & Reimold, S. (2016). Myocarditis as an immune-related adverse event with ipilimumab/nivolumab combination therapy for metastatic melanoma. *Melanoma research*, 26(3), 319–320. <https://doi.org/10.1097/CMR.0000000000000251>
27. Mahmood, S. S., Chen, C. L., Shapnik, N., Krishnan, U., Singh, H. S., & Makker, V. (2018). Myocarditis with tremelimumab plus durvalumab combination therapy for endometrial cancer: A case report. *Gynecologic oncology reports*, 25, 74–77. <https://doi.org/10.1016/j.gore.2018.05.014>
28. Lie, G., Weickhardt, A., Kearney, L., Lam, Q., John, T., Liew, D., & Arulananda, S. (2020). Nivolumab resulting in persistently elevated troponin levels despite clinical remission of myocarditis and myositis in a patient with malignant pleural mesothelioma: case report. *Translational lung cancer research*, 9(2), 360–365. <https://doi.org/10.21037/tlcr.2020.02.05>
29. Monge, C., Maeng, H., Brofferio, A., Apolo, A. B., Sathya, B., Arai, A. E., Gulley, J. L., & Bilusic, M. (2018). Myocarditis in a patient treated with Nivolumab and PROSTVAC: a case report. *Journal for immunotherapy of cancer*, 6(1), 150. <https://doi.org/10.1186/s40425-018-0473-0>
30. Guo, C. W., Alexander, M., Dib, Y., Lau, P., Wepler, A. M., Au-Yeung, G., Lee, B., Khoo, C., Mooney, D., Joshi, S. B., Creati, L., & Sandhu, S. (2020). A closer look at immune-mediated myocarditis in the era of combined checkpoint blockade and targeted therapies. *European journal of cancer (Oxford, England : 1990)*, 124, 15–24. <https://doi.org/10.1016/j.ejca.2019.09.009>

31. Padegimas, A., Agarwal, P., Fleitman, J., Carver, J., Rao, S., Mather, P., Domenico, C., Nazarian, S., Riley, M., & O'Quinn, R. (2019). Case series of ventricular tachycardia AND Myocarditis from Programmed CELL-DEATH Protein-1 INHIBITOR treated With INFLIXIMAB. *JACC: Clinical Electrophysiology*, 5(8), 989–992. <https://doi.org/10.1016/j.jacep.2019.05.001>
32. Salem, J. E., Allenbach, Y., Vozy, A., Brechot, N., Johnson, D. B., Moslehi, J. J., & Kerneis, M. (2019). Abatacept for Severe Immune Checkpoint Inhibitor-Associated Myocarditis. *The New England journal of medicine*, 380(24), 2377–2379. <https://doi.org/10.1056/NEJMc1901677>
33. Ansari-Gilani, K., Tirumani, S. H., Smith, D. A., Nelson, A., Alahmadi, A., Hoimes, C. J., & Ramaiya, N. H. (2020). Myocarditis associated with immune checkpoint inhibitor therapy: a case report of three patients. *Emergency radiology*, 27(4), 455–460. <https://doi.org/10.1007/s10140-020-01765-6>
34. Semper, H., Muehlberg, F., Schulz-Menger, J., Allewelt, M., & Grohé, C. (2016). Drug-induced myocarditis after nivolumab treatment in a patient with pdl1- negative squamous cell carcinoma of the lung. *Lung Cancer*, 99, 117–119. <https://doi.org/10.1016/j.lungcan.2016.06.025>
35. Jain, V., Mohebtash, M., Rodrigo, M. E., Ruiz, G., Atkins, M. B., & Barac, A. (2018). Autoimmune Myocarditis Caused by Immune Checkpoint Inhibitors Treated With Antithymocyte Globulin. *Journal of immunotherapy (Hagerstown, Md. : 1997)*, 41(7), 332–335. <https://doi.org/10.1097/CJI.0000000000000239>
36. Hardy, T., Yin, M., Chavez, J. A., Ivanov, I., Chen, W., Nadasdy, T., & Brodsky, S. V. (2020). Acute fatal myocarditis after a single dose of anti-PD-1 immunotherapy, autopsy findings: a case report. *Cardiovascular pathology : the official journal of the Society for Cardiovascular Pathology*, 46, 107202. <https://doi.org/10.1016/j.carpath.2020.107202>

37. Saibil, S. D., Bonilla, L., Majeed, H., Sotov, V., Hogg, D., Chappell, M. A., Cybulsky, M., & Butler, M. O. (2019). Fatal myocarditis and rhabdomyositis in a patient with stage IV melanoma treated with combined ipilimumab and nivolumab. *Current oncology (Toronto, Ont.)*, 26(3), e418–e421. <https://doi.org/10.3747/co.26.4381>
38. Frigeri, M., Meyer, P., Banfi, C., Giraud, R., Hachulla, A. L., Spoerl, D., Friedlaender, A., Pugliesi-Rinaldi, A., & Dietrich, P. Y. (2018). Immune Checkpoint Inhibitor-Associated Myocarditis: A New Challenge for Cardiologists. *The Canadian journal of cardiology*, 34(1), 92.e1–92.e3. <https://doi.org/10.1016/j.cjca.2017.09.025>
39. Tadokoro, T., Keshino, E., Makiyama, A., Sasaguri, T., Ohshima, K., Katano, H., & Mohri, M. (2016). Acute Lymphocytic Myocarditis With Anti-PD-1 Antibody Nivolumab. *Circulation. Heart failure*, 9(10), e003514. <https://doi.org/10.1161/CIRCHEARTFAILURE.116.003514>
40. Heinzerling, L., Ott, P. A., Hodi, F. S., Husain, A. N., Tajmir-Riahi, A., Tawbi, H., Pauschinger, M., Gajewski, T. F., Lipson, E. J., & Luke, J. J. (2016). Cardiotoxicity associated with CTLA4 and PD1 blocking immunotherapy. *Journal for immunotherapy of cancer*, 4, 50. <https://doi.org/10.1186/s40425-016-0152-y>
41. Liu, Y., & Jiang, L. (2020). Tofacitinib for treatment in immune-mediated myocarditis: The first reported cases. *Journal of oncology pharmacy practice : official publication of the International Society of Oncology Pharmacy Practitioners*, 1078155220947141. Advance online publication. <https://doi.org/10.1177/1078155220947141>
42. Mahrholdt, H., Goedecke, C., Wagner, A., Meinhardt, G., Athanasiadis, A., Vogelsberg, H., Fritz, P., Klingel, K., Kandolf, R., & Sechtem, U. (2004). Cardiovascular magnetic resonance assessment of human myocarditis: a comparison to histology and molecular pathology. *Circulation*, 109(10), 1250–1258. <https://doi.org/10.1161/01.CIR.0000118493.13323.81>

43. Nakashima, H., Honda, Y., & Katayama, T. (1994). Serial electrocardiographic findings in acute myocarditis. *Internal medicine (Tokyo, Japan)*, *33*(11), 659–666.  
<https://doi.org/10.2169/internalmedicine.33.659>
44. Dolladille, C., Ederhy, S., Allouche, S., Dupas, Q., Gervais, R., Madelaine, J., Sassier, M., Plane, A. F., Comoz, F., Cohen, A. A., Thuny, F. R., Cautela, J., & Alexandre, J. (2020). Late cardiac adverse events in patients with cancer treated with immune checkpoint inhibitors. *Journal for immunotherapy of cancer*, *8*(1), e000261. <https://doi.org/10.1136/jitc-2019-000261>

**Table 2: ICI mechanism of action, targeted cancer and date of approval**

<b>Immune Checkpoint Inhibitor</b>	<b>Mechanism of Action</b>	<b>Targeted Cancer</b>	<b>Date of Initial Approval</b>
Ipilimumab (Yervoy)	T-lymphocyte antigen 4 (CTLA-4) blocking antibody	Melanoma, RCC	03/28/2011
Nivolumab (Opdivo)	Human IgG4 monoclonal antibody against PD-1	Melanoma, NSCLC, RCC, Hodgkin’s lymphoma, SCCHN, urothelial cancer, CRC, HCC	12/22/2014
Pembrolizumab (Keytruda)	Human IgG4 monoclonal antibody against PD-1	Melanoma, NSCLC, Hodgkin’s lymphoma, HNSCC, urothelial cancer, solid tumor, G/GEJ adeno; cervical cancer, PMBCL, HCC, MCC, RCC	09/04/2014
Cemiplimab (Libtayo)	Human monoclonal antibody against Programed Death -1 (Pd-1)	Cutaneous squamous cell carcinoma	09/28/2018
Avelumab (Bavencio)	Programmed Death-Ligand 1 (PD-L-1) blocking antibody	MCC, RCC, urothelial carcinoma	11/18/2015
Duravalumab (Imfinzi)	Human monoclonal antibody directed against PD-L-1	Urothelial carcinoma, NSCLC	02/17/2016
Atezolizumab (Tecentriq)	Human monoclonal antibody directed against PD-L-1	Urothelial carcinoma, NSCLC, Breast cancer	05/18/2016

RCC: Renal Cell Carcinoma; NSCLC: squamous non-small-cell lung cancer; SCCHN: squamous cell cancer of head and neck; CRC: colorectal cancer; HCC: hepatocellular carcinoma; HNSCC: head and neck squamous cell cancer; G/GEJ adeno.: gastric/gastroesophageal junction (GEJ) adenocarcinoma; PMBCL: primary mediastinal large B-cell lymphoma ; MCC: Merkel cell carcinoma.

**Figure 1: Prisma chart for study acquisition**

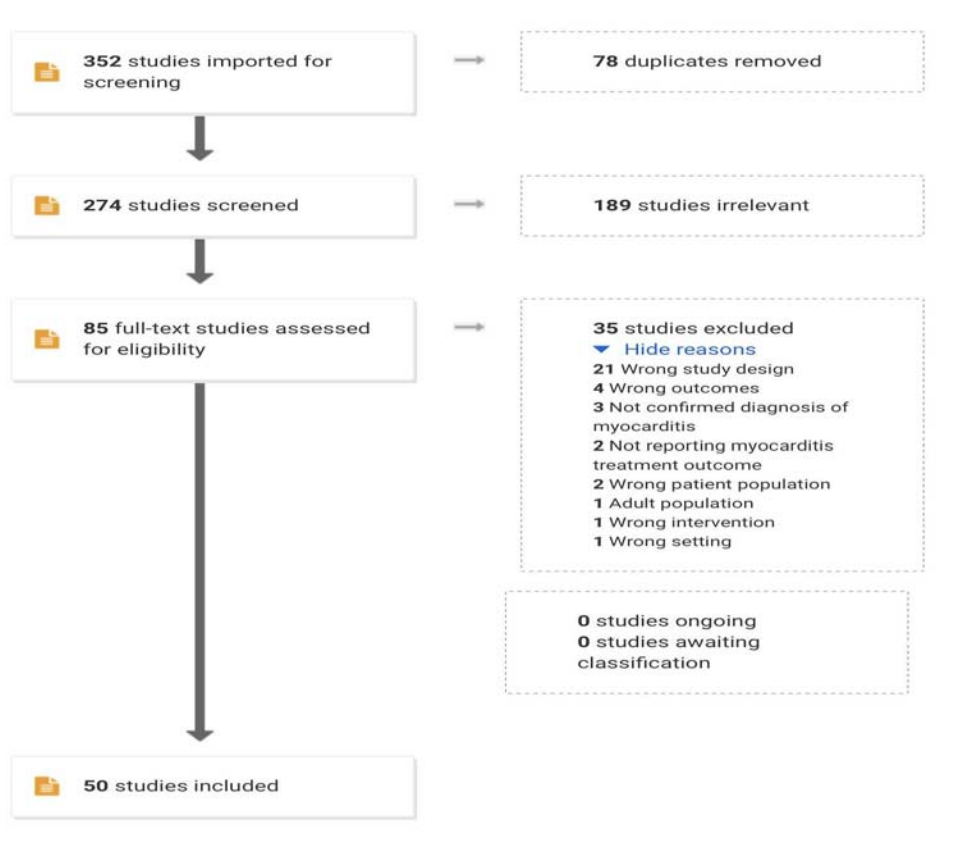


Table 3: Study details and demographic

Author, year	Study name	Country	Age	gender	Diagnosed malignancy	Stage	comorbidity	Baseline cardiac status	Presenting symptoms	cardiovascular symptoms
Saibil et al. 2019	Fatal myocarditis and rhabdomyolysis in a patient with stage IV melanoma treated with combined ipilimumab and nivolumab	Canada	67	Male	BRAF wild type metastatic Melanoma	III	HLD, HTN	N/A	Fatigue, weakness, dyspnea	Dyspnea
Monge et al. 2018	Myocarditis in a patient treated with Nivolumab and PROSTVAC: a case report	USA	79	Male	metastatic castration-resistant prostate cancer (mCRPC)	IV	afib.	Afib	blurred vision, stiffness in the back	N/A
Guo et al. 2020	A closer look at immune-mediated myocarditis in the era of combined checkpoint blockade and targeted therapies	Australia	74	Male	Metastatic Melanoma	IV	HTN, obesity	left axis deviation	fatigue, fever, chills, anorexia, diarrhea, acneiform rash	Fatigue
			60	Female	metastatic melanoma	IV	N/A	N/A	Nausea, Vomiting, diarrhea, mucositis	N/A
			75	Male	Metastatic melanoma	IV	UC, HTN, HLD, PE, Hyperthyroidism, obesity	N/A	fatigue, weight loss, back/neck pain, truncal/girdle	Fatigue

									weakness	
			74	Female	Metastatic melanoma	IV	CHF, DM2, HTN, non ST MI, CKD3, BMI 29	CHF	proximal limb girdle weakness, exertional dyspnea	Dyspnea
			88	Male	Metastatic Melanoma	IV	HTN, HLD, TIA, CKD2, Hypothyroidism, CHF, obesity	N/A	exertional dyspnea	Dyspnea
			61	Male	Melanoma	IV	BMI 26	LBBB	diarrhea, exertional dyspnea	Dyspnea
Padegimas et al. 2019	Case Series of Ventricular Tachycardia and Myocarditis From Programmed Cell-Death Protein-1 Inhibitor Treated With Infliximab	N/A	53	Female	Metastatic ovarian adenocarcinoma	IV	N/A	N/A	exertion chest pressure	N/A
		N/A	62	Female	metastatic renal cell carcinoma	IV	N/A	N/A	N/A	Dyspnea, chest tightness
Salem et al. 2019	Abatacept for Severe Immune Checkpoint Inhibitor-Associated Myocarditis	France	66	Female	metastatic lung cancer	IV	N/A	N/A	ptosis, diplopia, and subacute, painful paresis affecting the proximal muscles	Chest pain
Chang et al. 2018	Myocarditis with Radiotherapy and Immunotherapy in Multiple Myeloma	USA	47	Female	Multiple Myeloma	IV	plasmacytoma of the lumbosacra	N/A	fever, hypoxia	chest pain



							l spine			
Ganatra et al. 2018	Immune Checkpoint Inhibitor-Associated Myocarditis	USA	41	Female	metastatic melanoma	IV	Hashimoto's thyroiditis	N/A	N/A	Dyspnea, tachycardia
Huertas et al. 2019	Cardiac toxicity of immune-checkpoint inhibitors: A clinical case of nivolumab-induced myocarditis and review of the evidence and new challenges	Spain	80	Male	advanced clear cell kidney cancer	IV	HTN	N/A	Asthenia, poor pain control	N/A
Tay et al. 2017	Successful use of equine anti-thymocyte globulin (ATGAM) for fulminant myocarditis secondary to nivolumab therapy	Australia	64	Female	right temporo-parietal glioblastoma IDH-WT	IV	N/A	N/A	N/A	N/A
Lee et al. 2020	Case of pembrolizumab-induced myocarditis presenting as torsades de pointes with safe re-challenge.	USA	37	Female	alveolar soft part sarcoma, metastatic to the lung and brain	IV	N/A	Mild myocarditis	cough	Dyspnea, chest tightness
Hardy et al. 2020	Acute fatal myocarditis after a single dose of anti-PD-1 immunotherapy, autopsy findings: a case report	USA	81	Male	recurrent renal cell carcinoma (RCC)	III	carcinoid tumor (T1aN0) of the lung	N/A	fatigue, decreased appetite, and weight loss	N/A
Fukasawa et al. 2017	Nivolumab-Induced Myocarditis Concomitant with Myasthenia Gravis	Japan	69	Female	Advanced adenocarcinoma of the lung	IV	N/A	N/A	general malaise and double vision.	N/A

Yamagushi et al. 2018	Late-Onset Fulminant Myocarditis With Immune Checkpoint Inhibitor Nivolumab	Japan	60	Male	Melanoma	IV	N/A	N/A	fatigue and fever	Dyspnea, chest pain
Tajmir-Fiahi et al. 2018	Life-threatening Autoimmune Cardiomyopathy Reproducibly Induced in a Patient by Checkpoint Inhibitor Therapy	Germany	72	Male	Melanoma	II	DM, HTN, PAD, Hyperuricemia	N/A	loss of appetite	Dyspnea, pedal edema
Arangala et al. 2017	Survival after fulminant myocarditis induced by immune-checkpoint inhibitors	France	35	Female	Melanoma	III	N/A	N/A	N/A	N/A
Tan et al. 2019	Nivolumab-induced myocarditis complicated by complete atrioventricular block in a patient with metastatic non-small cell lung cancer	Australia	74	Male	non-small cell lung cancer	IV	COPD, depression	N/A	N/A	Dyspnoea, chest discomfort, palpitation, orthopnoea
Liu et al. 2020	Tofacitinib for treatment in immune-mediated myocarditis: The first reported cases	China	68	Female	breast cancer and Hodgkin's lymphoma	IV	No	N/A	fatigue	Dyspnea
		China	46	Female	Unknown primary or metastatic supraclavicular lymph node	N/A	N/A	N/A	N/A	Dyspnea, palpitation

Jain et al. 2018	Autoimmune Myocarditis Caused by Immune Checkpoint Inhibitors Treated With Antithymocyte Globulin	USA	67	Male	melanoma	IV	DJD	N/A	Skin rash	Dyspnea
Semper et al. 2016	Drug-induced myocarditis after nivolumab treatment in a patient with PDL1-negative squamous cell carcinoma of the lung	Germany	75	Male	squamous cell carcinoma of the lung	IV	No	N/A	N/A	Dyspnea, chest pain
Tadokoro et al. 2016	Acute Lymphocytic Myocarditis With Anti-PD-1 Antibody Nivolumab	Japan	69	Female	choroidal malignant melanoma with liver and bone metastases	IV	No	N/A	general malaise	palpitation
Frigeri et al. 2018	Immune Checkpoint Inhibitor-Associated Myocarditis: A New Challenge for Cardiologists	Switzerland	76	Female	recurrent metastatic pulmonary adenocarcinoma	IV	N/A	N/A	N/A	Dyspnea, pedal edema, pulmonary edema
Heinzerling et al. 2016	Cardiotoxicity associated with CTLA4 and PD1 blocking immunotherapy	USA and Germany	72	Male	primary melanoma and low-grade non-Hodgkin's lymphoma	IV	MI, DM2, HTN, PAD, hyperuricemia, hypothyroidism.	N/A	edema, ascites, pleural effusion, dyspnea	Dyspnea, pedal edema
			68	Male	metastatic BRAF wild-type	N/A	Dilated cardiomyopathy,	N/A	edema	Dyspnea, pedal edema

					melanoma			alcohol abuse.		
			61	Male	melanoma	III		no	N/A	N/A
			81	Male	metastatic BRAF wild-type melanoma	III		afib, MI, VT	N/A	subacute shortness of breath
			23	Male	BRAF V600E mutant melanoma	N/A		uveitis	N/A	and cough
			64	Male	melanoma	III		N/A.	N/A	fatigue, seizures, abdominal pain.
			88	Male	metastatic melanoma	IV		PVD	N/A	pain in the shoulder
			87	Male	primary melanoma was diagnosed with low-grade non-Hodgkin's lymphoma	II		autoimmune hepatitis.	N/A	N/A
Mahmood et al. 2018	Myocarditis with tremelimumab plus durvalumab combination therapy for endometrial cancer: A case report	N/A	75	Female	Advanced endometrial cancer	III		N/A	N/A	Neck protraction, imbalance
										Dyspnea, edema, arrhythmias.
										Dyspnea

Lie et al. 2020	Nivolumab resulting in persistently elevated troponin levels despite clinical remission of myocarditis and myositis in a patient with malignant pleural mesothelioma: case report	Australia	79	Male	Right-sided PD-L1 negative epithelioid Malignant Pleural Mesothelioma	N/A	HTN, HLD	High sensitivity troponin T of 1,072 ng/L	severe proximal limb, truncal weakness and generalized fatigue	Dyspnea
Mehta et al. 2016	Myocarditis as an immune-related adverse event with ipilimumab/nivolumab combination therapy for metastatic melanoma	<u>USA</u>	68	Female	metastatic melanoma	IV	N/A	N/A	left arm pain, fever, malaise	chest pain
Ansari-Gllani et al. 2020	Myocarditis associated with immune checkpoint inhibitor therapy: a case report of three patients	USA	83	Male	Renal cell carcinoma	IV	HTN, hypothyroidism	N/A	abdominal pain, right-sided facial drop, and diffuse weakness	chest pain
			78	Female	metastatic melanoma	IV	HLD, depression, anxiety	N/A	blurry vision, malaise, and dysphagia	chest pain,
			81	Male	metastatic melanoma	IV	HTN, COPD, afib	N/A	watery diarrhea, chest pain, and frequent	chest pain, PVC
Gallegos et al. 2019	Myocarditis with checkpoint inhibitor immunotherapy: case report of late gadolinium enhancement on cardiac magnetic resonance with	USA	47	Female	Metastatic melanoma	IV	carotid artery dissection, acute HF	carotid artery dissection, acute heart	tachypnoeic, with pulmonary oedema, jugular venous distension,	Hypotension, tachycardic, pedal edema.

	pathology correlate							failure	ascites	
Johnson et al. 2016	Fulminant Myocarditis with Combination Immune Checkpoint Blockade	USA	65	Female	Metastatic melanoma	IV	HTN	N/A	atypical chest pain, dyspnea, and fatigue	Dyspnea, chest pain
		USA	63	Male	Metastatic melanoma	IV	HTN	N/A	fatigue and myalgias.	N/A
Matsui et al. 2020	A Fatal Case of Myocarditis Following Myositis Induced by Pembrolizumab Treatment for Metastatic Upper Urinary Tract Urothelial Carcinoma	Japan	69	Male	Urothelial Carcinoma	IV	HTN	N/A	severe fatigue and an abnormal gait. bilateral diplopia, bilateral ptosis, and decreased tendon reflexes. Dysesthesia In extremities	N/A
Edahiro et al. 2020	Severe myocarditis with slight lymphocytic infiltration after nivolumab treatment	Japan	73	Male	squamous cell lung cancer	N/A	N/A	N/A	Acute shortness of breath and chest discomfort.	dyspnea, chest discomfort
Imai et al. 2019	Fulminant Myocarditis Caused by an Immune Checkpoint Inhibitor: A Case Report With Pathologic Findings	Japan	70	Male	Squamous cell carcinoma of the right lung	IV	THN	N/A	Fever, faintness, muscle weakness, hypotension 99/63 mm Hg, tender lower	Syncope, Hypotension

										extremities.	
Norwood et al. 2017	Smoldering myocarditis following immune checkpoint blockade	USA	49	Female	cutaneous melanoma	IV	HLD	N/A	Nausea	N/A	
Leaver et al. 2020	Immune checkpoint inhibitor-mediated myasthenia gravis with focal subclinical myocarditis progressing to symptomatic cardiac disease	Australia	55	Male	melanoma	IV	HTN	N/A	blurred vision, mild bilateral ptosis and fatigable left arm abduction.	N/A	
LoongTan et al. 2020	Concomitant myopericarditis and takotsubo syndrome following immune checkpoint inhibitor therapy.	USA	62	Male	metastatic hepatocellular carcinoma		chronic hepatitis C with cirrhosis	N/A	12hours of midsternal chest pain following 3days of nausea and vomiting.	chest pain	
Matsuo et al. 2019	Nivolumab-induced myocarditis successfully treated with corticosteroid therapy: A case report and review of the literature	Japan	62	Male	unresectable lung adenocarcinoma	IV	hypothyroidism	N/A	back pain, chest discomfort, general fatigue, and dyspnea.	Dyspnea, chest tightness	

**Table 4 Statistical analysis**

Group 1	
Mean	5.57098E+58
Standard Error	7.87855E+57

Median	15
Mode	
Standard Deviation	5.62641E+58
Sample Variance	3.1656E+117
Kurtosis	-2
Skewness	-1
Range	1981
Minimum	
Maximum	1981
Sum	2.8412E+60
Count	51
Largest(1)	8
Smallest(1)	
Confidence Level	78.02777694

---