medRxiv preprint doi: https://doi.org/10.1101/2021.11.04.21265815; this version posted November 5, 2021. The copyright holder for this preprint (which was not certified by peer review) is the author/funder, who has granted medRxiv a license to display the preprint in perpetuity. It is made available under a CC-BY 4.0 International license .

Predicting Clinical Course from Subcortical Shape in Provisional Tic Disorder

Authors

Tiffanie Che [1], Soyoung Kim [2], Deanna J. Greene [3], Ashley Heywood [4], Jimin Ding [5], Bradley L. Schlaggar [6], Kevin J. Black [7], Lei Wang [1,4]

Institutions

[1] Department of Psychiatry and Behavioral Health, Ohio State University Wexner Medical Center, Columbus, OH; tiffanieche2019@u.northwestern.edu; Lei.Wang@osumc.edu
[2] Departments of Psychiatry and Radiology, Washington University in St. Louis School of Medicine, St. Louis, MO; soyoung@brainkim.com
[3] Department of Cognitive Science, University of California San Diego, La Jolla, CA; deannagreene@ucsd.edu
[4] Department of Psychiatry and Behavioral Sciences, Northwestern University Feinberg School of Medicine, Chicago, IL; ashley.heywood@northwestern.edu
[5] Department of Mathematics and Statistics; Department of Medicine, Washington University in St. Louis, St. Louis, MO; jmding@wustl.edu
[6] Kennedy Krieger Institute, Baltimore, MD; Departments of Neurology and Pediatrics, Johns Hopkins University School of Medicine, Baltimore, MD; schlaggar@kennedykrieger.org
[7] Departments of Psychiatry, Neurology, Radiology and Neuroscience, Washington University in St. Louis School of Medicine, St. Louis, MO; kevin@wustl.edu

Abstract

The ongoing NewTics study examines children who have had tics for less than 9 months (NT group) - a population on which little research exists. Here, we further investigate relationships between subcortical shape and tic symptom outcomes. 138 children were assessed at baseline and a 12-month follow-up: 79 with NT, 27 tic-free healthy controls (HC), and 32 with chronic tic disorder or Tourette syndrome (TS), using T1-weighted MRI and total tic scores (TTS) from the Yale Global Tic Severity Scale to evaluate symptom change. Subcortical surface maps were generated using FreeSurfer-initialized large deformation diffeomorphic metric mapping, and linear regression models were constructed to correlate structural shapes with TTS while accounting for covariates, with relationships mapped onto structure surfaces. When compared to healthy controls, smaller mean volumes were found in the TS group for the caudate, nucleus accumbens, pallidum, and thalamus. NT had smaller mean volumes than controls in the caudate, pallidum, and thalamus. Surface maps illustrate distinct patterns of inward deformation (localized volume loss) in the TS group compared to NT children. In the NT group, a larger hippocampus at baseline significantly correlated with the worsening of tic symptoms at 12 months. Outward deformation in the hippocampus and inward deformation in the accumbens at baseline are also related to worsening tic symptoms at follow-up. Since the NT group has had tics only for a few months, we can rule out the possibility that these subcortical volume differences are caused by living with tics for years; they are more likely related to the cause of

NOTE: This preprint reports new research that has not been certified by peer review and should not be used to guide clinical practice.

medRxiv preprint doi: https://doi.org/10.1101/2021.11.04.21265815; this version posted November 5, 2021. The copyright holder for this preprint (which was not certified by peer review) is the author/funder, who has granted medRxiv a license to display the preprint in perpetuity. It is made available under a CC-BY 4.0 International license .

tics. These observations constitute some of the first prognostic biomarkers for tic disorders and suggest localized circuitry that may be associated with outcome of tic disorders.

Introduction

Chronic tic disorders (CTD) were once thought to be rare, but are now known to be much more common than previously thought [1]. Tics are sudden, repetitive, nonrhythmic movements or vocalizations such as blinks or grunting [2]. Transient tics affect at least 20% of children, though only about 3% of all children have tics for a full year- the requirement to diagnose a chronic tic disorder or Tourette syndrome (TS) [3, 4]. When tics are present less than a year since onset, Provisional Tic Disorder is diagnosed [1]. Efforts to identify biomarkers for tics and study the pathophysiology behind tic disorders have recently been increasing, although our understanding is still limited [5, 6].

Studies exploring differences in subcortical structure and function have often been contradictory, with some finding no significant differences in basal ganglia volumes or shape between children with TS and matched control children [6]. Two groups have found increased putamen volume in TS compared to HC, but a larger study found decreased volume [7-9]. A large study of basal ganglia volume *in vivo* found the caudate to be 4.9% smaller in the TS group [10]. Smaller studies found lower caudate volume [11, 12], and another large study identified no change [13].

Previous such studies have also primarily focused only on TS and control samples. A potential confounding variable that arises here is that we cannot determine whether the identified differences reflect an underlying cause of tics or secondary changes due to prolonged tic presence. Examining participants at the onset of tic symptoms will more likely lead to identifying biomarkers related to the primary cause of tics.

Thus, the ongoing NewTics study examines children who have had tics for less than 9 months (new tics, or NT) [14]. Little research exists on this population, and there are even fewer results on predictive outcome analyses, which have also been contradictory [4]. The NewTics study aims to see whether features including subcortical structures measured shortly after tic onset can predict symptom severity at 12 months after tic onset. A previous volumetric MRI analysis using data from 65 children with NT found that striatal volumes did not predict outcome, but a larger hippocampus at baseline predicted worse severity at follow-up [15].

In the present study, we further investigated neurobiological characteristics in tic disorders by examining relationships between subcortical shape and tic symptom outcomes. Three-dimensional surface analysis can detect subtler or more localized volumetric changes that are not revealed in whole-structure, scalar volumetric analysis [16]. Using whole-structure volume estimates alone may yield false negative findings by overlooking local deformities in shape. Previously, diffeomorphic mapping of structural magnetic resonance imaging (MRI) has successfully mapped pathological biomarker patterns onto surface-based representations of anatomical structures [17].

medRxiv preprint doi: https://doi.org/10.1101/2021.11.04.21265815; this version posted November 5, 2021. The copyright holder for this preprint (which was not certified by peer review) is the author/funder, who has granted medRxiv a license to display the preprint in perpetuity. It is made available under a CC-BY 4.0 International license .

We predicted that baseline volumes would differ across NT, TS, and control groups, and that subcortical shape would demonstrate distinct patterns of shape deformation in tic disorders. We further predicted that we would find distinct regions of shape deformation in subcortical structures at baseline that predict clinical outcome in terms of tic severity changes after one year. We also tested whether shape deformation analyses would confirm previous findings of hippocampal structure predicting symptom severity outcome using a 3D method in an expanded sample.

Methods

The following protocol was approved by the Washington University Human Research Protection Office (IRB; 201109157 and 201707059). Participants assented and guardians provided informed consent, and likewise control data from other projects was collected after informed consent.

Subjects and data collection

Subjects. The sample consisted of 138 children across 3 groups: children examined within 9 months after tic onset (median 3.5 months; new tic, or NT), tic-free children with no parental or sibling history of tics (healthy controls, HC), and children who at the time of screening already have TS/CTD (TS) [14]. NT subjects returned at the best-estimate 1-year anniversary of tic onset for clinical evaluation. Since TS and HC subjects have no tic onset date from which to calculate the 12 months, their follow-up visit occurred at the same time after screening as it does in a matched NT subject, based on age, sex, and handedness.

Enrollment criteria. Subjects were limited to ages 5-10 at enrollment to reduce sample variance. For NT children, we accepted children who currently exhibit tic symptoms, with the first tic less than 9 months before enrollment. Exclusion criteria are detailed elsewhere [14]. In the TS group, we accepted children who meet DSM-5 criteria for TS/CTD at enrollment, matched to the NT group based on age, sex, handedness, and ADHD status. The exclusion criteria used reflects that of the NT group. For HC, we accepted children who do not exhibit tic symptoms and are matched with NT subjects.

Clinical data collection. For participants exhibiting tic symptoms, a best estimated date of onset was taken. Total tic scores from the Yale Global Tic Severity Scale (YGTSS) were determined during a neurological and psychiatric examination performed by Dr. Black for NT and TS subjects, as an evaluation of tic symptom severity. Additional assessments were done at the time of screening [14]. The YGTSS is a tool used to quantify the severity of tic symptoms in children and adolescents. The Total Tic Severity Score (TTS) comprises half of the YGTSS score and has a range of 0-50; a higher score indicates more severe tic symptoms [18].

medRxiv preprint doi: https://doi.org/10.1101/2021.11.04.21265815; this version posted November 5, 2021. The copyright holder for this preprint (which was not certified by peer review) is the author/funder, who has granted medRxiv a license to display the preprint in perpetuity. It is made available under a CC-BY 4.0 International license .

Imaging data collection. All subjects at entry were assessed through 1 mm^3 T1-weighted magnetization prepared rapid gradient echo (MPRAGE) images and T2-weighted images using three different scanners across the data acquisition period. Details of scan parameters are given in Kim et al (2020) [15]. About half of the scans (the newer ones) were acquired with a prospective motion correction sequence (vNavs) [19].

Additional measures were taken prior to scanning in order to reduce motion effects on images, including the use of a mock scanner, as well as an informational video and game for children to practice holding still during scanning adapted from a previous study on Type I diabetes [20].

Data processing / Image processing

Data processing began with the use of the FreeSurfer (version 6.0.0) software's probabilistic voxel-based classification, which provided initial subcortical segmentations [21]. Surfaces of the hippocampus, amygdala, basal ganglia (caudate, putamen, pallidum, and nucleus accumbens), and thalamus were automatically generated for each participant using multi-atlas FreeSurfer-initialized large deformation diffeomorphic metric mapping (FS+LDDMM), which utilizes automated brain segmentations based on multiple template images and allows for image alignment and intensity normalization to produce smooth transformations for each region of interest [21, 22]. Combining maps from multiple atlases that best match an individual's scan features has shown improved segmentation accuracy and reduced biases [23]. An expert rater (the first author) inspected the final surfaces and made minor manual edits on the initial segmentation on poor surface maps of 6 subjects. The edited segmentations were then re-processed via LDDMM to yield accurate maps to be included in subsequent surface analyses.

Local shape variation for each participant was calculated from the population average of all participants by quantifying the vertex-to-vertex perpendicular change between surfaces, which were assigned a positive (outward variation from the population average) or negative (inward variation from the population average) value [21]. Subcortical volumes for each participant were determined using the volume enclosed within the surfaces. FreeSurfer also reported estimated total intracranial volume (TIV) to be used as a covariate in surface analyses, as TIV estimated by FreeSurfer segmentation has been shown to influence subcortical volumes [22].

Statistical analysis.

TTS: Paired T-tests were conducted to determine significance of TTS changes from baseline to 12-months within each group, as well as between groups. The raw change variable was created by subtracting each subjects' baseline TTS from their 12-month TTS.

TIV: We first conducted a one-way ANOVA to determine group effects with post hoc Tukey HSD tests for pairwise differences, with and without age and sex as covariates.

medRxiv preprint doi: https://doi.org/10.1101/2021.11.04.21265815; this version posted November 5, 2021. The copyright holder for this preprint (which was not certified by peer review) is the author/funder, who has granted medRxiv a license to display the preprint in perpetuity. It is made available under a CC-BY 4.0 International license .

The tests showed significant group effects (see results); therefore, TIV was used as an additional covariate in all subsequent analyses.

Scanner type: We first conducted a chi-square test that determined that scanner types did not differ between groups. Additionally, we conducted a one-way ANOVA with a post hoc Tukey HSD test to determine the effects of scanner type on structural volumes. We found that the subcortical structures did not differ in volume based on the scanner type used, though the TIV did differ significantly, with the difference existing between the Trio and Prisma scanners. However, a subsequent ANCOVA found that group differences in TIV between NT / TS and healthy controls still occur after controlling for the scanner type. Thus, we did not use scanner type as a covariate in subsequent analyses.

Subcortical volumes: ANCOVA and post hoc tests were then conducted to compare group differences of baseline structural volumes. All structures were examined by combining left and right subcortical structures, since we did not have a lateralized hypothesis. If groups were found to differ significantly for a specific structure, further analyses were conducted to examine left and right structures separately. Analyses done in R used version 4.0.5, with *psych* and *ggplot2* packages [24, 25].

We then performed a partial correlation analysis using baseline structural volume in the NT group to predict 12-month TTS while controlling for baseline TTS and total intracranial volume.

Shape: For group comparisons, ANCOVAs were conducted to compare pairwise group differences of baseline surface shape (i.e., NT vs. HC, TS vs. HC, and TS vs. NT). All models included covariates for age, sex, and TIV. Surface comparisons with TTS were conducted using SurfStat implemented in MATLAB [26]. Random field theory (RFT) was applied using SurfStat to identify significant clusters of vertices at the family-wise error rate (FWER) of $p<0.05$ within each subcortical structure to account for the multiple comparisons inherent in surface maps [27]. Group differences were visualized onto the surface of the structure as a color map on the overall average surface [21].

To correlate the shape of each subcortical structure with symptom change scores, multiple linear regression models were constructed using SurfStat. Morphometric values were regressed onto 12-month TTSs while accounting for age, sex, baseline TIV and baseline TTS. RFT was applied to identify significant clusters of vertices at FWER of $p<0.05$ within each subcortical structure to account for multiple comparisons [21, 27]. Significant associations were visualized onto the surface of the structure as a color map on the overall average surface.

medRxiv preprint doi: https://doi.org/10.1101/2021.11.04.21265815; this version posted November 5, 2021. The copyright holder for this preprint (which was not certified by peer review) is the author/funder, who has granted medRxiv a license to display the preprint in perpetuity. It is made available under a CC-BY 4.0 International license .

Results

Subject demographics and clinical features

In total, we analyzed 138 participants - 27 HC (21M / 6F), 79 NT (57M / 22F), and 32 TS (22M / 10F). The mean age at baseline did not differ significantly between groups, and these were all near 8 years old. The TS group had a slightly higher mean TTS at baseline compared to the NT group, though this difference was not statistically significant. The TS group had a higher mean TTS at 12 months (p=.07).

Sample Characteristic	HC	NT	TS	Statistics
Total N (M / F)	27 (21M / 6F)	79 (57M / 22F)	32 (22M / 10F)	X^2 = 0.61, *p =0.74*
Mean age (SD) at baseline (years)	8.1 ± 1.8	7.8 ± 2.0	8.3 ± 1.7	F=1.10, *p=0.34*
Scanner Type*	9 Trio / 18 Prisma	26 Trio / 52 Prisma	6 Trio / 26 Prisma	X^2 = 2.49, *p = 0.29*
Race/ethnicity*	11 White / 5 More than one race	65 White / 5 Black or African American / 6 More than one race / 1 Asian / 2 Unknown or not reported	19 White / 6 More than one race / 1 Asian	X^2 = 12.47, *p = 0.13*
Mean TTS at baseline	N/A	17.15 ± 5.82; *n=71*	20.05 ± 8.40; *n=22*	t=-1.51, df=28, *p=0.14*
Mean TTS at 12 months	N/A	13.92 ± 7.01; *n=71*	18.91 ± 11.71; *n=22*	t=-1.90, df= 25, *p=0.07*

Table 1. Participant characteristics at baseline or 12-months *(as specified under "Sample Characteristic"). Values indicate number or mean ± SD unless indicated otherwise.*
** Indicates that partial data was used, as some subjects were missing this information.*

Baseline total intracranial volume

Both patient groups had smaller average total intracranial volumes at baseline (NT 1490 ± 157 cm^3, TS 1508 ± 143 cm^3, HC 1596 ± 141 cm^3; see Fig. 1).

A one-way ANOVA with age and sex as covariates revealed significant group differences [F(2,134)=6.241, p=0.0026; see Fig. 1]. Post hoc Tukey HSD tests revealed that both the NT and TS groups had smaller TIV compared to the HC group (p = 0.002 and p = 0.037, respectively). Since TIV differed significantly among groups, we henceforth used TIV as a covariate in subsequent analyses.

medRxiv preprint doi: https://doi.org/10.1101/2021.11.04.21265815; this version posted November 5, 2021. The copyright holder for this preprint (which was not certified by peer review) is the author/funder, who has granted medRxiv a license to display the preprint in perpetuity. It is made available under a CC-BY 4.0 International license .

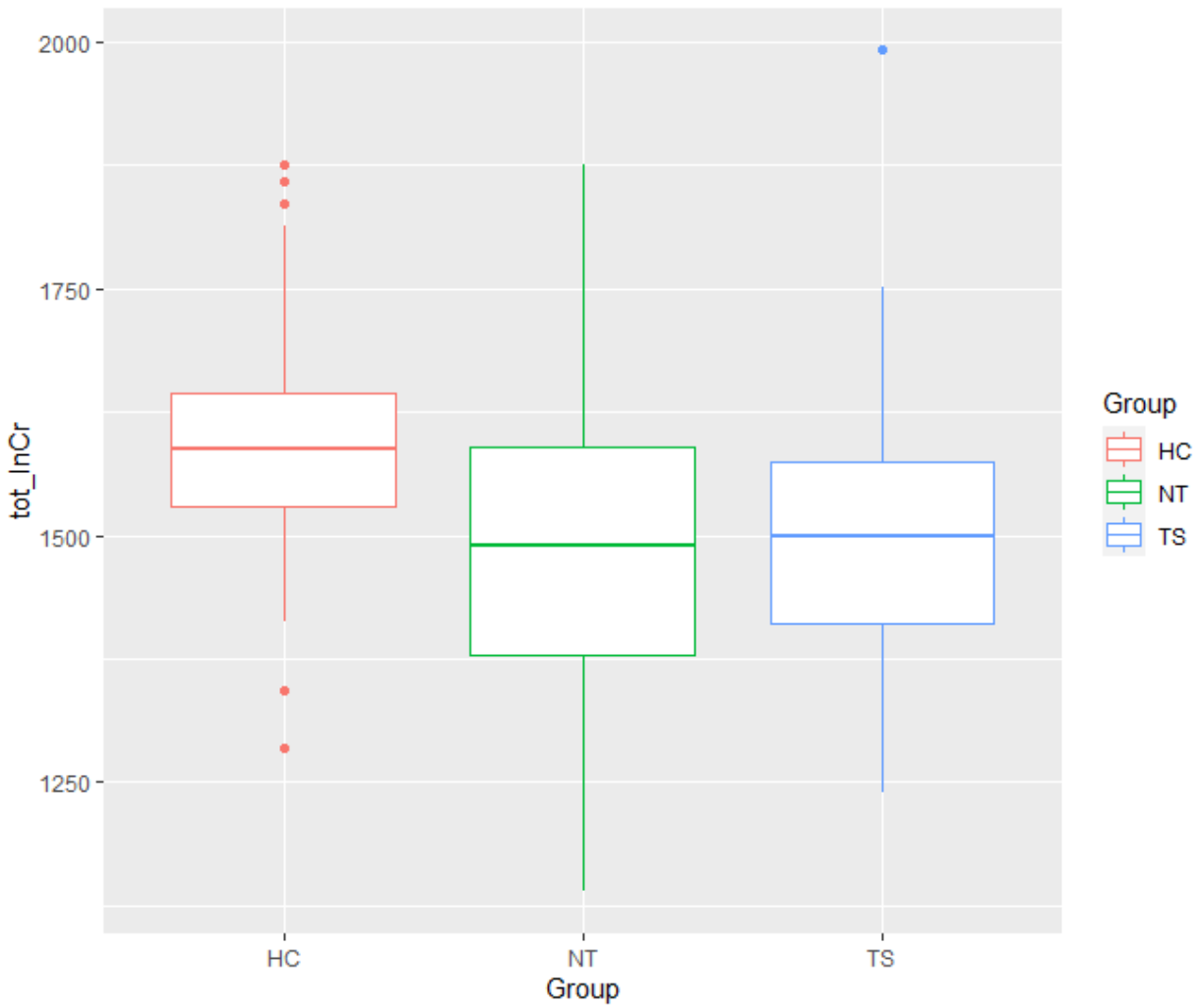

Figure 1. Group comparisons of total intracranial volume measured at baseline. *Healthy controls had the highest average, followed by TS and NT. ANCOVA analyses found an overall group effect [F(2,134)=6.241, p=0.00257], with differences between both NT and TS compared to healthy controls (p=0.0017 and p=0.0369, respectively).*

Scanner type

The subcortical structures did not differ in volume based on the scanner used. The TIV did differ significantly (F(2,135)= 15.9, p=6.55e-07), with the difference existing between the Trio and Prisma scanners. Group differences in TIV between NT / TS and healthy controls remained significant after controlling for the scanner type (p=0.0003 and p=0.0151, respectively). Scanner used did not differ between groups (X^2 = 3.25, p = 0.52).

medRxiv preprint doi: https://doi.org/10.1101/2021.11.04.21265815; this version posted November 5, 2021. The copyright holder for this preprint (which was not certified by peer review) is the author/funder, who has granted medRxiv a license to display the preprint in perpetuity. It is made available under a CC-BY 4.0 International license .

Baseline group comparisons of subcortical structural volumes

Subcortical Structural Volumes (Left + Right Average) (in mm³) *n=138*				
Group	**HC**	**NT**	**TS**	**Statistics**
Hippocampus	5209 ± 533	5149 ± 571	5050 ± 582	F(2,134)=1.262, p=0.29
Amygdala	2646 ± 297	2632 ± 300	2549 ± 303	F(2,134)=2.153, p=0.12
Caudate	**7645 ± 542**	**7190 ± 780**	**6990 ± 842**	[1] **F(2,134)=9.350, p=0.0002**
Accumbens	**850 ± 76**	**834 ± 83**	**805 ± 93**	[2] **F(2,134)=3.417, p=0.04**
Putamen	10422 ± 936	10107 ± 1004	9987± 910	F(2,134)=2.685, p=0.07
Pallidum	**3651 ± 381**	**3433 ± 370**	**3426 ± 356**	[3] **F(2,134)=8.710, p=0.0003**
Thalamus	**14334 ± 1025**	**13720 ± 1020**	**13684 ± 1139**	[4] **F(2,134)=7.915, p=0.0006**

Table 2. Subcortical Structural Volumes (Left + Right Average)*. Significant group differences were found in the caudate, accumbens, pallidum, and thalamus using a one-way ANCOVA while controlling for total intracranial volume, age, and sex. Post hoc Tukey HSD tests further revealed specific group differences:*
[1] NT and TS had smaller caudate volumes than the HC group (p = 0.0023 and p=0.0001, respectively).
[2] TS had a smaller accumbens volume than the HC group (p=0.034).
[3] NT and TS had smaller pallidal volumes than the HC group (p = 0.0003 and p=0.0018, respectively).
[4] NT and TS had smaller thalamic volumes than the HC group (p = 0.00074 and p=0.0026, respectively).
Values indicate mean ± SD unless indicated otherwise.
For differences within each hemisphere for these structures, see text.

Table 2 summarizes the means and standard deviations of the subcortical volume for each group, as well as statistical comparisons for each group. Here, we describe the results for each structure in detail.

Hippocampus. There were no statistically significant differences between groups.

Amygdala. There were no statistically significant differences between groups.

Caudate. Patients in NT and TS had a smaller caudate by an average of 455 mm^3 and 655 mm^3, respectively, compared to those in the HC group. There was a significant difference between both the NT and TS groups compared to the HC group.

medRxiv preprint doi: https://doi.org/10.1101/2021.11.04.21265815; this version posted November 5, 2021. The copyright holder for this preprint (which was not certified by peer review) is the author/funder, who has granted medRxiv a license to display the preprint in perpetuity. It is made available under a CC-BY 4.0 International license .

Differences were additionally found when examining the left and right caudate separately. On the left, there were statistically significant differences between groups. Both NT and TS groups differed significantly from the HC group ($p = 0.0190$ and $p=0.0003$, respectively). In the right caudate, there were statistically significant differences between groups [$F(2,134)=10.32$, $p=0.00007$]. Both NT and TS groups differed significantly from the HC group ($p = 0.0003$ and $p=0.0001$, respectively).

Nucleus Accumbens. Patients in TS had a smaller nucleus accumbens by an average of 45.45 mm^3 compared to healthy controls.

When examining the left and right accumbens separately, we found no significant differences between group means on the left [$F(2,134)=1.250$, $p=0.290$]. Right accumbens volume differed significantly between groups [$F(2,134)=5.557$, $p=0.005$]. TS groups differed from both the HC and NT groups ($p = 0.004$ and $p=0.034$, respectively).

Putamen. There were no statistically significant differences between groups.

Pallidum. Patients in NT and TS had a smaller pallidum by an average of 218.12 mm^3 and 225.49 mm^3 compared to healthy controls, respectively.

These differences were seen in both hemispheres. In the left pallidum [$F(2,134)=8.423$, $p=0.0004$], both NT and TS groups differed significantly from the HC group ($p = 0.0003$ and $p=0.0037$, respectively). In the right pallidum [$F(2,134)=8.333$, $p=0.0004$], both NT and TS groups once again differed significantly from the HC group ($p=0.0007$ and $p=0.0014$, respectively).

Thalamus. Patients in NT and TS had a smaller thalamus by an average of 613.84 mm^3 and 650.17 mm^3, respectively, compared to those in the HC group.

These differences were seen in both hemispheres. In the left thalamus [$F(2,134)=8.375$, $p=0.0004$], both NT and TS groups differed significantly from the HC group ($p = 0.0008$ and $p=0.0010$, respectively). In the right thalamus [$F(2,134)=7.129$, $p=0.0012$], both NT and TS groups once again differed significantly from the HC group ($p = 0.001$ and $p=0.008$, respectively).

Baseline group comparisons of subcortical structural shape

Shape comparisons did not yield significant differences between either tic group and healthy controls. When comparing the TS group to NT children, however, six structures were found to have significant regions of inward deformation. In other words, areas of inward deformation described below illustrate localized volume loss in the specified regions.

Hippocampus. No group differences were found between any groups.

medRxiv preprint doi: https://doi.org/10.1101/2021.11.04.21265815; this version posted November 5, 2021. The copyright holder for this preprint (which was not certified by peer review) is the author/funder, who has granted medRxiv a license to display the preprint in perpetuity. It is made available under a CC-BY 4.0 International license .

Amygdala. (Figure 2 Panel A). We found regions of inwards deformation in both the superior and inferior surfaces of the right amygdala. In the top view, there was a significant region of inward deformation closer to the lateral-posterior parts of the right amygdala. On the bottom view, more inward deformities are concentrated around the medial-posterior areas of the right amygdala.

Caudate. (Figure 2 Panel B). From the top view, there are regions of inward deformation concentrated towards the lateral-anterior parts of both the left and right caudate.

Accumbens. (Figure 2 Panel C). From both the top and bottom views, substantial inward deformation is visible in the right nucleus accumbens. When looking from the top, we can see multiple regions of inward deformation that are concentrated towards the medial-posterior and lateral-anterior parts of the right accumbens. From the bottom view, a large region of deformation is observed near the posterior part of the right accumbens.

Putamen. (Figure 2 Panel D). Small regions of inward deformation are seen in the putamen in both the right and left hemispheres. From the bottom, we found inward deformation in the medial-anterior parts of the right putamen, and another small area closer to the posterior side of the left putamen.

Pallidum. (Figure 2 Panel E). We observed significant inward deformation towards the anterior side of the right pallidum when viewed from the top.

Thalamus. (Figure 2 Panel F). We found a region of inward deformation in the medial parts of the right thalamus from the bottom view.

medRxiv preprint doi: https://doi.org/10.1101/2021.11.04.21265815; this version posted November 5, 2021. The copyright holder for this preprint (which was not certified by peer review) is the author/funder, who has granted medRxiv a license to display the preprint in perpetuity. It is made available under a CC-BY 4.0 International license .

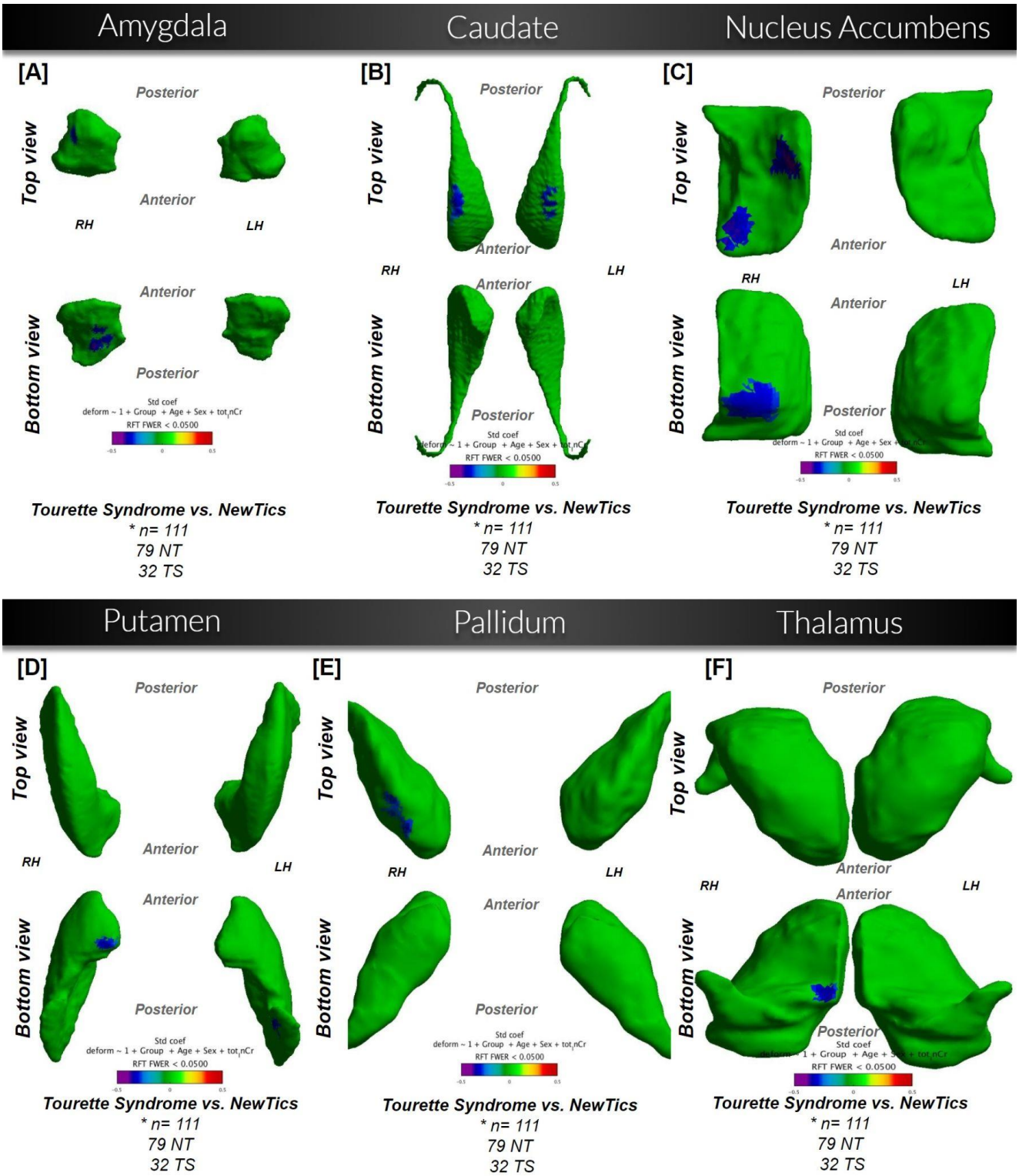

Figure 2. Shape comparison between specified groups, *while controlling for the effects of age, sex, and total intracranial volume. Cooler shades represent a greater inward deformation of the first group relative to the second, whereas warmer shades represent greater outward deformation. RFT = comparisons that passed the random field theory threshold.*

medRxiv preprint doi: https://doi.org/10.1101/2021.11.04.21265815; this version posted November 5, 2021. The copyright holder for this preprint (which was not certified by peer review) is the author/funder, who has granted medRxiv a license to display the preprint in perpetuity. It is made available under a CC-BY 4.0 International license .

Prediction of 12-month TTS with baseline structural volume and shape

Longitudinal TTS analyses included 71 NT and 22 TS subjects. Over the course of the 12 months between the baseline and second visits, the NT group average total tic scores decreased from 17.15 ± 5.82 to 13.92 ± 7.01 (t = 3.00, df = 135, p-value = 0.003). The TS group average total tic scores decreased non-significantly from 20.05 ± 8.40 to 18.91 ± 11.71 (t = 0.37, df = 38, p-value = 0.71). TTS changes between the two groups from baseline to 12 months did not differ significantly (t=-1.07, df=28, p=0.29).

Baseline hippocampal volumes predicted 12-month total tic scores in the NT group. A larger hippocampus significantly correlated with worsening of symptoms (r=0.28, p=0.02).

Additionally, regression analyses illustrated that the shape of the hippocampus and accumbens at baseline significantly correlated with TTS increase from baseline to 12 months (worsening of symptoms) when controlled for age, sex, TIV, and screen TTS (Figure 3).

> Hippocampus. From the top, we can see that an increase in TTS from baseline to 12-months was positively associated with a cluster of outward local shape deformation in the lateral-posterior region of the right hippocampus (tail).
>
> Accumbens. Inferiorly, an increase in TTS from baseline to 12-months was negatively associated with a cluster of inward local shape deformation in the medial-anterior region of the left accumbens at baseline.

medRxiv preprint doi: https://doi.org/10.1101/2021.11.04.21265815; this version posted November 5, 2021. The copyright holder for this preprint (which was not certified by peer review) is the author/funder, who has granted medRxiv a license to display the preprint in perpetuity. It is made available under a CC-BY 4.0 International license .

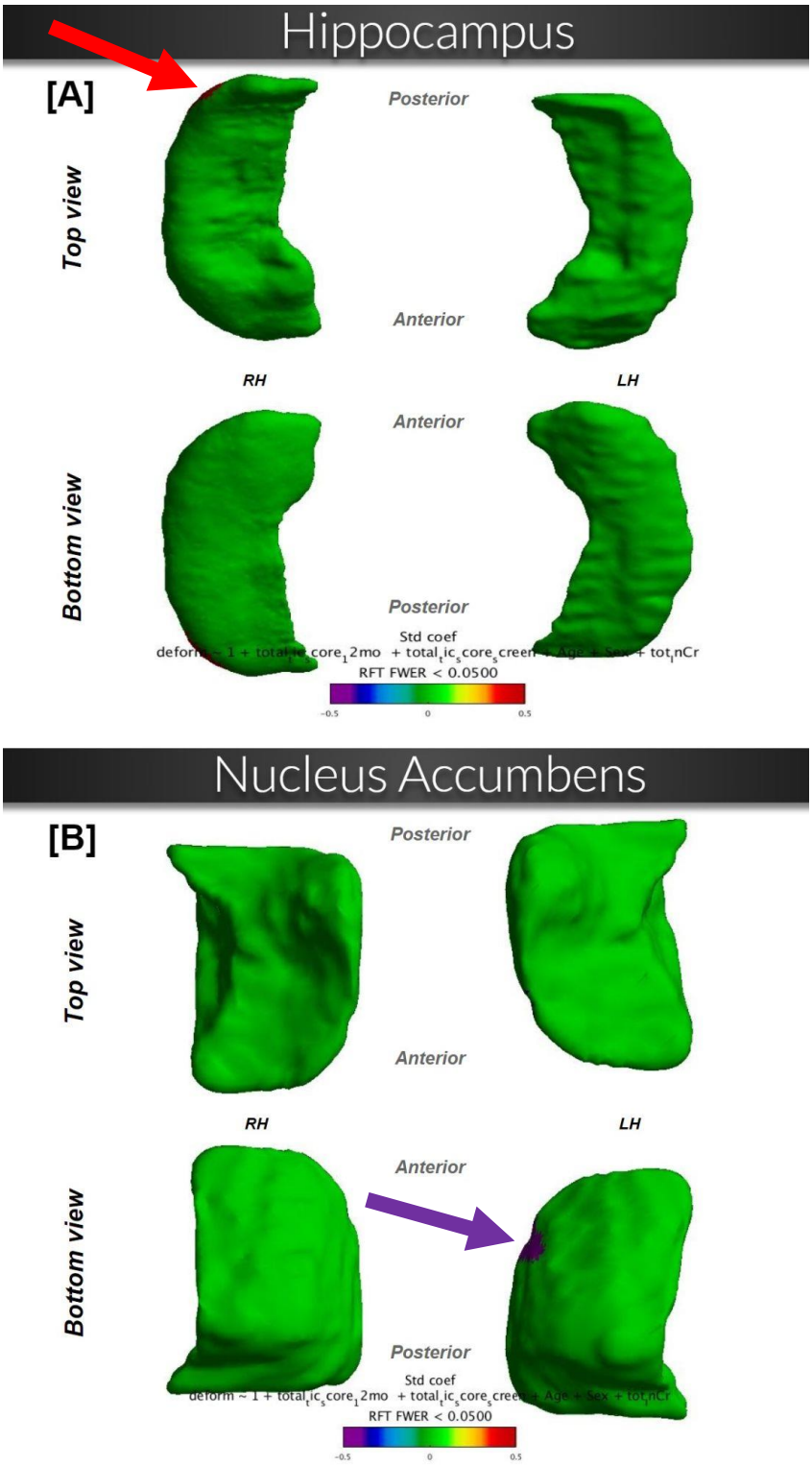

Figure 3. Subcortical local shape deformation and total tic score symptom changes. *Cooler shades represent a significant negative association between deformation from the mean and increase of TTS (worsening of symptoms) (increased TTS is related to more inward deformation), while warmer shades represent where an increase in TTS is positively associated with local shape deformation (increased TTS is related to more outward deformation). Regions in green do not have significant associations with TTS. Models are controlled for the effects of age, sex, screen TTS, and TIV. N=93*

medRxiv preprint doi: https://doi.org/10.1101/2021.11.04.21265815; this version posted November 5, 2021. The copyright holder for this preprint (which was not certified by peer review) is the author/funder, who has granted medRxiv a license to display the preprint in perpetuity. It is made available under a CC-BY 4.0 International license .

Discussion

In this study, we focus on the first year of tic development and how and why tics typically improve during this period. We have identified several subcortical volume and shape characteristics related to tic symptoms, including some that predict clinical tic outcome at 12 months. Baseline volume and surface analyses demonstrate distinct patterns of subcortical surface deformation in the amygdala, caudate, nucleus accumbens, putamen, pallidum, and thalamus. These structures exhibited significant regions of inward deformation (i.e., localized volume loss) in TS children compared to NT children. Shape analyses support volume group differences, with TS consistently having smaller volume than NT children, as well as localized inward deformation above and beyond TIV.

Functional implications

Hippocampus. Larger hippocampal volume and local outward shape deformation in the right hippocampus tail was found to be associated with the worsening of tic symptoms after 12 months. The hippocampus plays a role in memory consolidation, in both the cognitive and motor domains [28]. Specifically, the hippocampal tail supports visuospatial ability and memory. In a study on patients with amnestic mild cognitive impairment, a larger right hippocampal tail was significantly associated with higher visuospatial memory scores on the Rey's complex figure test, which measures visuospatial ability and memory) [29]. Furthermore, in a study on the effects of traumatic brain injury in the hippocampus, damage to the right hippocampal tail had a tendency to correlate with lower memory scores on the Rey's complex figure test [30]. Our conjecture is that damage to this area impairs visuospatial ability and memory, and abnormal enlargement may conversely lead to abnormal preservation of visuospatial memory. There is evidence that in children with TS, those with more persistent motor memory show more severe tics, as they were found to take longer to unlearn a previously learned motor pattern [31]. As we saw that worsening of tic symptoms after 12 months was associated with outward deformation in the right hippocampal tail, perhaps this region may be implicated in tic development and/or persistence.

Amygdala. In the amygdala, TS children were found to exhibit localized volume loss compared to NT children. The amygdala has been previously shown to be involved in motor inhibition processes, as well as the modulation of brain circuits involved in motor control [32]. Consequently, this idea is consistent with our findings that the amygdala would be implicated in tic symptoms.

Basal Ganglia (accumbens, pallidum, putamen, and caudate). The basal ganglia is a collection of subcortical nuclei that, along with its associated connections, has been a large focus of TS/CTD research. It is known to be involved in motor control in other movement disorders such as Parkinson's and Huntington's disease. Cortico-striatal-thalamo-cortical (CSTC) circuits related to the basal ganglia have been found to be involved in inhibitory control and habit formation, both to which TS relate [33, 34]. This

medRxiv preprint doi: https://doi.org/10.1101/2021.11.04.21265815; this version posted November 5, 2021. The copyright holder for this preprint (which was not certified by peer review) is the author/funder, who has granted medRxiv a license to display the preprint in perpetuity. It is made available under a CC-BY 4.0 International license .

understanding may relate to the volume and shape differences we found in basal ganglia structures.

Thalamus. In the thalamus, both TS and NT groups were found to have significantly smaller volume than the HC group. Additionally, the thalamus displayed localized volume loss when comparing TS to NT children. The thalamus's strategic location between motor areas of the cerebral cortex and other motor-related subcortical structures lends itself to its involvement in motor control [35]. Our findings support the theory of the thalamus' implication in TS.

In the NT group, a larger hippocampus at baseline significantly correlated with the worsening of tic symptoms at 12 months. In a prior analysis of a smaller subset of the present sample using different methods, a larger hippocampus at baseline similarly predicted worse severity at follow-up [15]. Since the NT group has had tics for only a few months, the subcortical volume differences in this group are especially meaningful as they are more likely to be related to the cause of tics rather than a result of chronic tics.

Shape analysis further illustrated this trend, as we found patterns of outwards deformation in the hippocampus surface at baseline that significantly correlated with TTS increase from baseline to 12 months (worsening of symptoms) when controlled for age, sex, and total intracranial volume. Additionally, we found a region of inward deformation in the medial-anterior part of the left accumbens associated with increasing TTS from baseline to 12 months. Localized shape deformation can be a more sensitive antecedent marker of clinical progression than whole-structure volume.

A meta-analysis on task-based fMRI studies involving patients with TS found focal regional differences [36]. In the thalamus, there is a clear overlap of all the conditions involving various aspects of voluntary motor execution, response inhibition, and tic generation. The right pallidum and thalamus were both found to be regions that show a more consistent activation in free-to-tic conditions. This is consistent with our findings of inward deformation present in the right pallidum and thalamus of the TS group compared to the NT group. It seems that these regions are implicated in tic severity and persistence. The meta-analysis also identified a positive correlation between the YGTSS score and the activity of the right thalamus and putamen bilaterally, relating higher TTS to higher task-induced BOLD signal in these regions [36]. Similarly, we found that the TS group showed inward deformation in the right thalamus and putamen when compared to the NT group. Perhaps these regions hyperactivate over time to compensate for focal indentations in the surfaces or volume loss.

The primary limitation of this project is sample size, especially our healthy controls, as we have 27 HC compared to 79 NT and 32 TS. Future studies shall include longitudinal and within-subject analyses using both baseline and 12-month scans, in combination with clinical scores.

These new findings have potential clinical relevance, and continuing to investigate neuroanatomical characteristics in TS/CTD may further provide insight into prognostic

medRxiv preprint doi: https://doi.org/10.1101/2021.11.04.21265815; this version posted November 5, 2021. The copyright holder for this preprint (which was not certified by peer review) is the author/funder, who has granted medRxiv a license to display the preprint in perpetuity. It is made available under a CC-BY 4.0 International license .

biomarkers. In many children with Provisional Tic Disorder, tics improve within the first year, often to the point of clinical insignificance. Understanding the mechanisms related to these outcomes may provide clinical insight into the pathophysiological traits in tic disorders and thus potentially lead to improved treatment approaches. In a previous memory study on the hippocampus, multiple-session stimulation increased functional connectivity among cortical-hippocampal network regions and simultaneously improved associative memory performance [37]. With a deeper understanding of neural networks related to tic symptoms, we may be able to similarly provide targets that could be manipulated to prevent worsening of tic symptoms.

Funding

Research reported in this publication was supported by the National Institutes of Health: National Institute of Mental Health under award number K24MH087913 to K.J.B.; K01MH104592 to D.J.G.; R01MH104030 to K.J.B. and B.L.S.; National institute of Neurological Disorders and Stroke R21NS091635 to B.L.S. and K.J.B.; the Washington University Institute of Clinical and Translational Sciences grants UL1RR024992 and UL1TR000448; the Eunice Kennedy Shriver National Institute of Child Health and Human Development of the National Institutes of Health under Award Number U54HD087011 to the Intellectual and Developmental Disabilities Research Center at Washington University, and K23DC006638 to J.E.C. Lieu; the Mallinckrodt Institute of Radiology MIR-IDDRC Pilot Study Fund; the National Institute of Biomedical Imaging and Bioengineering grant R01 EB020062 to L.W.; the National Science Foundation grants 1734853 and 1636893 to L.W. The studies presented in this work were carried out in part in the East Building MR Facility of the Washington University Medical Center. The content is solely the responsibility of the authors and does not necessarily represent the official views of the National Institutes of Health or of the MIR.

medRxiv preprint doi: https://doi.org/10.1101/2021.11.04.21265815; this version posted November 5, 2021. The copyright holder for this preprint (which was not certified by peer review) is the author/funder, who has granted medRxiv a license to display the preprint in perpetuity. It is made available under a CC-BY 4.0 International license .

References

1. American Psychiatric Association, *Diagnostic and statistical manual of mental disorders: DSM-5.* United States, 2013.
2. Black, K.J., *Tics*, in ***Encyclopedia of Movement Disorders***, K. Kompoliti, et al., Editors. 2010, Elsevier (Academic Press): Oxford. p. 231-236.
3. Scahill, L., M. Specht, and C. Page, *The prevalence of tic disorders and clinical characteristics in children.* Journal of obsessive-compulsive and related disorders, 2014. **3**(4): p. 394-400.
4. Black, K.J., et al., *Provisional Tic Disorder: What to tell parents when their child first starts ticcing [version 1].* F1000Res, 2016. **5**: p. 696.
5. Leckman, J.F., et al., *Neurobiological substrates of Tourette's disorder.* Journal of child and adolescent psychopharmacology, 2010. **20**(4): p. 237-247.
6. Greene, D.J., K.J. Black, and B.L. Schlaggar, *Neurobiology and functional anatomy of tic disorders*. 2013: Oxford University Press: Oxford.
7. Williams, A.C., et al., *A pilot study of basal ganglia and thalamus structure by high dimensional mapping in children with Tourette syndrome.* F1000Research, 2013. **2**.
8. Ludolph, A.G., et al., *Grey-matter abnormalities in boys with Tourette syndrome: magnetic resonance imaging study using optimised voxel-based morphometry.* The British Journal of Psychiatry, 2006. **188**(5): p. 484-485.
9. Roessner, V., et al., *Increased putamen and callosal motor subregion in treatment-naïve boys with Tourette syndrome indicates changes in the bihemispheric motor network.* Journal of Child Psychology and Psychiatry, 2011. **52**(3): p. 306-314.
10. Peterson, B.S., et al., *Basal ganglia volumes in patients with Gilles de la Tourette syndrome.* Archives of general psychiatry, 2003. **60**(4): p. 415-424.
11. Peterson, B., et al., *Reduced basal ganglia volumes in Tourette's syndrome using three-dimensional reconstruction techniques from magnetic resonance images.* Neurology, 1993. **43**(5): p. 941-941.
12. Makki, M.I., et al., *Altered fronto-striato-thalamic connectivity in children with Tourette syndrome assessed with diffusion tensor MRI and probabilistic fiber tracking.* Journal of Child Neurology, 2009. **24**(6): p. 669-678.
13. Greene, D.J., et al., *Brain structure in pediatric Tourette syndrome.* Molecular psychiatry, 2017. **22**(7): p. 972-980.
14. Black, K.J., et al., *The New Tics study: A novel approach to pathophysiology and cause of tic disorders.* Journal of Psychiatry and Brain Science, 2020. **5**(3): p. e200012.
15. Kim, S., et al., *Hippocampal volume in Provisional Tic Disorder predicts tic severity at 12-month follow-up.* Journal of Clinical Medicine, 2020. **9**(6): p. 1715.
16. Group, B.D.C., *Total and regional brain volumes in a population-based normative sample from 4 to 18 years: the NIH MRI Study of Normal Brain Development.* Cerebral Cortex, 2012. **22**(1): p. 1-12.
17. Wang, L., et al., *Large deformation diffeomorphism and momentum based hippocampal shape discrimination in dementia of the Alzheimer type.* IEEE transactions on medical imaging, 2007. **26**(4): p. 462-470.
18. Leckman, J.F., et al., *The Yale Global Tic Severity Scale: initial testing of a clinician-rated scale of tic severity.* Journal of the American Academy of Child & Adolescent Psychiatry, 1989. **28**(4): p. 566-573.
19. Tisdall, M.D., et al., *Volumetric navigators for prospective motion correction and selective reacquisition in neuroanatomical MRI.* Magn Reson Med, 2012. **68**(2): p. 389-99.

medRxiv preprint doi: https://doi.org/10.1101/2021.11.04.21265815; this version posted November 5, 2021. The copyright holder for this preprint (which was not certified by peer review) is the author/funder, who has granted medRxiv a license to display the preprint in perpetuity. It is made available under a CC-BY 4.0 International license .

20. Barnea-Goraly, N., et al., *High success rates of sedation-free brain MRI scanning in young children using simple subject preparation protocols with and without a commercial mock scanner–the Diabetes Research in Children Network (DirecNet) experience.* Pediatric radiology, 2014. **44**(2): p. 181-186.
21. Jenkins, L.M., et al., *Subcortical structural variations associated with low socioeconomic status in adolescents.* Human brain mapping, 2020. **41**(1): p. 162-171.
22. Wang, L., et al., *Fully-automated, multi-stage hippocampus mapping in very mild Alzheimer disease.* Hippocampus, 2009. **19**(6): p. 541-548.
23. Christensen, A., et al., *Hippocampal subfield surface deformity in nonsemantic primary progressive aphasia.* Alzheimer's & Dementia: Diagnosis, Assessment & Disease Monitoring, 2015. **1**(1): p. 14-23.
24. Revelle W (2021). psych: Procedures for Psychological, Psychometric, and Personality Research. Northwestern University, Evanston, Illinois. R package version 2.1.9, https://CRAN.R-project.org/package=psych.
25. Wickham, Hadley (2009). ggplot2: Elegant Graphics for Data Analysis (Use R!). New York: Springer. ISBN 978-0387981406
26. Worsley, K., et al., *SurfStat: A Matlab toolbox for the statistical analysis of univariate andmultivariate surface and volumetric data using linear mixed effects modelsand random field theory.* Human Brain Mapping, 2009.
27. Taylor, J.E. and K.J. Worsley, *Detecting sparse signals in random fields, with an application to brain mapping.* Journal of the American Statistical Association, 2007. **102**(479): p. 913-928.
28. Schapiro, A.C., et al., *The hippocampus is necessary for the consolidation of a task that does not require the hippocampus for initial learning.* Hippocampus, 2019. **29**(11): p. 1091-1100.
29. Peter, J., et al., *Real-world navigation in amnestic mild cognitive impairment: the relation to visuospatial memory and volume of hippocampal subregions.* Neuropsychologia, 2018. **109**: p. 86-94.
30. Ariza, M., et al., *Hippocampal head atrophy after traumatic brain injury.* Neuropsychologia, 2006. **44**(10): p. 1956-1961.
31. Kim, S., et al., *Visuomotor learning and unlearning in children and adolescents with tourette syndrome.* Cortex, 2018. **109**: p. 50-59.
32. Sagaspe, P., S. Schwartz, and P. Vuilleumier, *Fear and stop: a role for the amygdala in motor inhibition by emotional signals.* Neuroimage, 2011. **55**(4): p. 1825-1835.
33. Aron, A.R., *The neural basis of inhibition in cognitive control.* The neuroscientist, 2007. **13**(3): p. 214-228.
34. Graybiel, A.M., *Habits, rituals, and the evaluative brain.* Annu. Rev. Neurosci., 2008. **31**: p. 359-387.
35. Bosch-Bouju, C., B.I. Hyland, and L.C. Parr-Brownlie, *Motor thalamus integration of cortical, cerebellar and basal ganglia information: implications for normal and parkinsonian conditions.* Frontiers in computational neuroscience, 2013. **7**: p. 163.
36. Zapparoli, L., M. Porta, and E. Paulesu, *The anarchic brain in action: the contribution of task-based fMRI studies to the understanding of Gilles de la Tourette syndrome.* Current opinion in neurology, 2015. **28**(6): p. 604-611.
37. Wang, J.X., et al., *Targeted enhancement of cortical-hippocampal brain networks and associative memory.* Science, 2014. **345**(6200): p. 1054-1057.

medRxiv preprint doi: https://doi.org/10.1101/2021.11.04.21265815; this version posted November 5, 2021. The copyright holder for this preprint (which was not certified by peer review) is the author/funder, who has granted medRxiv a license to display the preprint in perpetuity. It is made available under a CC-BY 4.0 International license .

Keywords

Tic disorders, subcortical structure, structural MRI, surface analysis, surface deformation, FreeSurfer, Provisional Tic Disorder, Tourette syndrome, hippocampus, nucleus accumbens, caudate, putamen, amygdala, globus pallidus, thalamus