NOTE: This preprint reports new research that has not been certified by peer review and should not be used to guide clinical practice.

medRxiv preprint doi: https://doi.org/10.1101/2021.10.18.21265102; this version posted October 19, 2021. The copyright holder for this preprint (which was not certified by peer review) is the author/funder, who has granted medRxiv a license to display the preprint in perpetuity. All rights reserved. No reuse allowed without permission.

The Diagnostic Value of Genetic Mutation Analysis and Mutation Profiling of cfDNA in Intraocular Fluid for VRL

Running title: Genetic Mutation of IOF for VRL Diagnosis

Xiaoqing Chen MD, PHD[1*], Yunwei Hu PHD[1*], Wenru Su MD, PHD[1*], Shizhao Yang PHD[1], Xiaoxiao Wang MD[2], Xiaoyu Hong MD[4], Chuqiao Liang MD[4], Zhuyun Qian MD[5], Ziqiang Li PHD[5], Yong Tao MD[3#], Huiqiang Huang MD[2#], Dan Liang MD, PHD[1#]

[1]State Key Laboratory of Ophthalmology, Zhongshan Ophthalmic Center, Sun Yat-sen University, Guangzhou, China;

[2]Department of Medical Oncology, Sun Yat-sen University Cancer Center, Guangzhou, China

[3]Department of Ophthalmology, Beijing Chaoyang Hospital, Capital Medical University, Beijing, China.

[4]Nanjing Geneseeq Technology Inc., Nanjing, Jiangsu, China

[5]Beijing GIANTMED medical diagnostics Lab.Beijing, China

[*] Those authors contributed equally

[#] **Correspondence:**

Dan Liang, MD, PhD

State Key Laboratory of Ophthalmology

Zhongshan Ophthalmic Center, Sun Yat-sen University, Guangzhou, China

Email: liangdan@gzzoc.com

Phone: +86-20-87330341;

Fax: +86-20-87330341.

Huiqiang Huang, MD

Department of Medical Oncology, Sun Yat-sen University Cancer Center,

651 Dongfeng East Road, Guangzhou, Guangdong, China, 510060

Email: huanghq_sysucc@163.com

Phone:86 20 87343350

Yong Tao, MD

Department of Ophthalmology, Beijing Chaoyang Hospital, Capital Medical University; No.8, South Road of Worker's Stadium, Chaoyang District, Beijing 100020, China.

Email: taoyong@bjcyh.com

medRxiv preprint doi: https://doi.org/10.1101/2021.10.18.21265102; this version posted October 19, 2021. The copyright holder for this preprint (which was not certified by peer review) is the author/funder, who has granted medRxiv a license to display the preprint in perpetuity. All rights reserved. No reuse allowed without permission.

Phone: +86-10-85231718.

Fax: +86-10-85231405.

This work was supported by grants from the National Science Foundation of China (8187040615, Guangzhou, Guangdong, China);

Abstract word count: 249

Text word count: 4493

Tables: 4

Figures: 6

medRxiv preprint doi: https://doi.org/10.1101/2021.10.18.21265102; this version posted October 19, 2021. The copyright holder for this preprint (which was not certified by peer review) is the author/funder, who has granted medRxiv a license to display the preprint in perpetuity. All rights reserved. No reuse allowed without permission.

Abstract

Vitreoretinal lymphoma (VRL) is a rare but aggressive masquerade syndrome, which would be easily confused with uveitis. The diagnostic gold standard remains the pathologic examination of ocular specimen with invasiveness and low sensitivity. To improve the safety and accuracy of VRL diagnosis, alternative techniques using intraocular fluid (IOF) samples are emerging. In this study, we aimed to test the diagnostic value of genetic mutation analysis of circulating cell-free DNA (cfDNA) in IOF for VRL and exhibit the mutation profile for revealing the molecular characteristics of VRL. Twenty-three suspected VRL patients were selected as the training group, who had genetic mutation analysis using a panel containing 446 tumor-related genes. Another external cohort including 5 VRL patients and 5 uveitis patients was selected for further validation. In training group, all of VRL patients had obtained 23 (IQR 13.5, 36.0) cfDNA mutations in IOF (sensitivity 100%), and 2 out of 6 uveitis patients had one and four mutations respectively (specificity 67%). The latter were identified as clonal hematopoiesis mutations. In validation group, all of VRL patients were positive and all of uveitis patients were negative for mutation analysis (sensitivity and specificity 100%). VRL patients from the two groups were characterized by the high mutation frequencies of PIM1 (21/22, 90.91%), MYD88 (17/22, 77.27%), CD79B (11/22, 50.00%), ETV6 (11/22, 50.00%) and IRF4 (11/22, 50.00%), and 77.27% were MCD subtype with PI3K-Akt signaling pathway alternation. In conclusion, it demonstrated a new mini-invasive and feasible method for VRL diagnosis using a panel of 466

medRxiv preprint doi: https://doi.org/10.1101/2021.10.18.21265102; this version posted October 19, 2021. The copyright holder for this preprint (which was not certified by peer review) is the author/funder, who has granted medRxiv a license to display the preprint in perpetuity. All rights reserved. No reuse allowed without permission.

tumor-related genes.

Key words: Vitreoretinal lymphoma, uveitis, diagnosis, circulating cell-free DNA, intraocular fluid, mutation profiling

medRxiv preprint doi: https://doi.org/10.1101/2021.10.18.21265102; this version posted October 19, 2021. The copyright holder for this preprint (which was not certified by peer review) is the author/funder, who has granted medRxiv a license to display the preprint in perpetuity. All rights reserved. No reuse allowed without permission.

Introduction

Vitreoretinal lymphoma (VRL) is a rare intraocular malignant lymphoma affecting the vitreous and/or the retina that can occur as a primary lymphoma or as a secondary manifestation of a primary central nervous system (CNS) lymphoma[1]. The vast majority of cases are histopathologically classified as diffuse large B-cell lymphoma (DLBCL)[2].

Clinically, VRL masquerades posterior and pan- uveitis, and is highly aggressive and associated with an elevated mortality rate. It is challenging to distinguish VRL from uveitis because both of them present vitreous opacity and yellow subretinal lesions[3, 4]. However, delaying diagnosis, and therefore the start of treatment, may have vision- and lifethreatening consequences. The gold standard for the definite diagnosis of VRL is commonly based on the clinical presentation along with histopathologic or cytologic examinations of the ocular specimen including retinal tissue biopsy and vitreous fluid (VF), which demonstrate the malignant B lymphocytes and characterize lymphocyte type by immunohistochemistry[5, 6]. However, the limited cellular yield, the cell lysis due to the fragile nature of lymphoma cells and lack of experience of cytopathologist contribute to the difficulty in cytologic diagnosis[7]. Meanwhile, retinal tissue biopsies are even more invasive and trickier, owing to the inherent risks associated with retinal surgery[8].

To improve the safety and accuracy of VRL diagnosis, the alternative techniques are emerging, for example the detection of IGH gene rearrangements of lymphoma cells by polymerase chain reaction (PCR), the measurement of interleukin-10 (IL-10) and interleukin-6 (IL-6) cytokine by flow cytometry using intraocular fluid (IOF) samples. However, the sensitivity and specificity of IGH gene rearrangements and

medRxiv preprint doi: https://doi.org/10.1101/2021.10.18.21265102; this version posted October 19, 2021. The copyright holder for this preprint (which was not certified by peer review) is the author/funder, who has granted medRxiv a license to display the preprint in perpetuity. All rights reserved. No reuse allowed without permission.

IL-10/IL-6 ratio in different studies ranges from 60% to 90%, which are largely affected by the quality of sample, the choice of primers set and the treatment of corticosteroids[9-11]. Ocular inflammatory conditions can also induce oligoclonal expansion of B lymphocytes and lead to false positive diagnosis, especially in cases with low yield of collected cells[11]. Thus, a detection method using IOF samples with high sensitivity and specificity for the diagnosis of VRL needs to be explored.

The circulating cell-free DNA (cfDNA) is the endogenous DNA secreted by or derived from cells which can be detected in the circulation of body fluids or blood. The circulating tumor DNA (ctDNA) harbors the tumor-derived genetic alterations, having been recognized as a tumor-specific biomarker and showing encouraging results in cancer diagnosis, prognosis and treatment of multiple solid cancers [12-14]. Recently, there is a growing interest in the genetic mutations of cfDNA in plasma, cerebrospinal fluid (CSF) for their potential utility in the diagnosis and management of CNS lymphoma patients[15, 16]. In 2018 Laura S.et al. reported that the anterior humor (AH)-based $MYD88^{L265P}$ mutation analysis would provide an additional liquid biopsy tool to diagnose and monitor patients with VRL[17]. However, MYD88 mutation could only be found in about 70% VRL patients[18, 19], and more various mutations of lymphoma cells should be identified for better diagnosis. Currently many genomic sequencing studies have revealed that genetic mutations are associated with overall survival and differential response to chemotherapy in systemic DLBCL. However, few studies focus on the genetic mutations profile of VRL. Therefore, the genetic mutation profile of VRL remains to be established, which may be used to reveal molecular characteristics and guide molecular targeted therapy of VRL in future.

medRxiv preprint doi: https://doi.org/10.1101/2021.10.18.21265102; this version posted October 19, 2021. The copyright holder for this preprint (which was not certified by peer review) is the author/funder, who has granted medRxiv a license to display the preprint in perpetuity. All rights reserved. No reuse allowed without permission.

Next-generation sequencing (NGS) technology has emerged as a promising approach for cfDNA mutational profiling characterized with high-throughput, high sensitivity and specificity. Here, we used a panel of 446 hematopoietic tumor-related genes on NGS. In this study, the 446-gene panel was used to detect cfDNA mutations in IOF samples from a training group of diagnosed VRL and chronic uveitis patients, and validated in IOF samples from another group. The clinical records were analyzed retrospectively, aiming to explore the clinical utility of the NGS detection in IOF for VRL diagnosis.

Method

Patients selection, samples collection, treatment and follow-up in the training group.

Patients who were suspected as VRL and had cfDNA mutation analysis performed at Zhongshan Ophthalmic Center (ZOC) of the Sun Yat-Sen University, Guangzhou, China, between April 1st 2018 and March 1st 2021, were selected as the training group. Written informed consent was collected from each patient and the study design was approved by the Ethics Committee of Zhongshan Ophthalmic Center, Sun Yat-sen University (NO.2021KYPJ190). All procedures were performed in compliance with the principles of the Helsinki Declaration.

These patients who presented the manifestations of severe vitreous opacity or diffuse subretinal yellow lesions or both were suspected as VRL by two experienced ophthalmologists (D. Liang and WR. Su) at the initial stage. Routine eye examination of slit lamp, fundus photography, fundus fluorescein angiography (FFA), indocyanine green angiography (ICGA), optical coherence tomography (OCT) and B-ultrasound examination had been taken. To clarify the diagnosis the laboratory investigations for autoimmune disease or other etiology of uveitis including

medRxiv preprint doi: https://doi.org/10.1101/2021.10.18.21265102; this version posted October 19, 2021. The copyright holder for this preprint (which was not certified by peer review) is the author/funder, who has granted medRxiv a license to display the preprint in perpetuity. All rights reserved. No reuse allowed without permission.

tests for syphilis, mycobacterium tuberculosis, and antiviral antibodies; chest CT, urinalysis, kidney, and liver function were routinely checked. Some patients also had brain magnetic resonance imaging (MRI) or cytologic examination of CSF to exclude CNS lymphoma.

IL-10/IL-6 ratio, as well as cfDNA genetic mutation analysis of the IOF (either AH or VF, or both) samples were also tested in all patients to assist in diagnosis. IGH gene rearrangements were tested in a part of patients. The anterior chamber paracentesis was performed with a 31-gauge insulin syringe and the diagnostic vitrectomy was performed with a standard three-port approach[20]. The undiluted samples were taken immediately to the cytopathologist, and prepared onto glass slides. One slide was stained with May-Grünwald-Giemsa, and the rest were used for the immunostainings[21, 22]. No patient underwent retinal biopsies due to high risks of retinal and visual damage.

The therapeutic strategies of all patients were also determined by the two ophthalmologists (D Liang and WR Su). Patients presenting typically clinical features of VRL with the positive findings of histopathologic examination or IGH gene rearrangements, or IL-10/IL-6 ratio greater than 1 would be treated with vitreous injection of Methotrexate (MTX, 400 mg/0.1 ml). The oncologist (HQ. Huang) of cerebral lymphoma was invited to give systemic evaluation and treatment in need. With less evidence for VRL, patients were treated with local or systemic corticosteroids combined with/without immunosuppressive therapy or anti-infective treatments according to the patient's conditions and examinations. The therapeutic strategies were adjusted and the diagnoses were identified after careful evaluation of treatment effects in follow-up.

The diagnostic criteria of VRL and uveitis

medRxiv preprint doi: https://doi.org/10.1101/2021.10.18.21265102; this version posted October 19, 2021. The copyright holder for this preprint (which was not certified by peer review) is the author/funder, who has granted medRxiv a license to display the preprint in perpetuity. All rights reserved. No reuse allowed without permission.

Combined ocular manifestations with the results of pathology, IL-10/IL-6 ratio, IGH gene rearrangements and patients' response to treatments, patients were divided into three groups: definitive diagnosed VRL, clinically diagnosed VRL and chronic uveitis. The diagnosis was given by two experienced specialists (D Liang and WR Su) independently. Any disagreements on diagnosis and treatment were resolved by discussion and, if required, referred to a third specialist (XQ Chen).

The diagnostic criteria were as follows:

Definitive diagnosis of VRL: It was established by pathological examinations of ocular specimens with/without the elevation of IL-10/IL-6 ratio or IGH gene rearrangements in IOF; or pathologic proven systemic lymphoma with ocular involvements.

Clinical diagnosis of VRL: Presenting clinical features suggestive for VRL but without positive finding in histopathology and cytomorphology, the patients show a positive response to MTX therapy during the follow-up, with/without the elevation of IL-10/IL-6 ratio or positive of IGH gene rearrangements in IOF.

Diagnosis of uveitis: Even if characterized as clinical features of presumed VRL, the patients had no positive results of laboratory investigations including pathological examinations, IL-10/IL-6 ratio or IGH gene rearrangements to support the diagnosis of lymphoma, also show: positive laboratory investigations for autoimmune disease and positive responses to corticosteroids with/without immunosuppressive therapy; or positive laboratory investigations for infectious uveitis and positive responses to the anti-infective treatment.

Meanwhile, we classified the VRL lesions as previous reported[23]: (1) the vitreous opacity type, vitreous opacity of 2+ or higher without retinal

medRxiv preprint doi: https://doi.org/10.1101/2021.10.18.21265102; this version posted October 19, 2021. The copyright holder for this preprint (which was not certified by peer review) is the author/funder, who has granted medRxiv a license to display the preprint in perpetuity. All rights reserved. No reuse allowed without permission.

lesions, (2) the retina type, vitreous opacity of 1+ or less with retinal lesions only, or (3) the concomitant type, with both.

The diagnostic value of cfDNA genetic mutations analysis for VRL

The diagnostic value including sensitivity, specificity, positive and negative predictive values, and test efficiency of genetic mutation analysis in diagnosing VRL were analyzed as previous described[24]. Patients in both the definitively and clinically diagnosed VRL were considered as patients with VRL for diagnosis value analysis. The detection of targeted genetic mutations was considered as positive and recorded as circulating tumor DNA, ctDNA (+).

Verification of the diagnostic value of cfDNA mutations

Furthermore, a validation group of patients including definite diagnosis of VRL, clinical diagnosis of VRL and chronic uveitis with different etiology from the ophthalmic unite in Beijing Chaoyang Hospital, Beijing, China, was selected to validate the diagnostic value of cfDNA genetic mutation analysis in the diagnosis of VRL. The same diagnostic criteria as described above were used. The diagnosis was made by two experienced ophthalmologists (Yong.Tao and Zhuyun Qian) independently. Any disagreements were resolved by discussion and, if required, referred to a third specialist. IOF samples from validation patients were sent for cfDNA mutation detection. All the patients signed an informed consent and institutional review board approval was obtained. The study was performed in accordance with the tenets of the Declaration of Helsinki.

medRxiv preprint doi: https://doi.org/10.1101/2021.10.18.21265102; this version posted October 19, 2021. The copyright holder for this preprint (which was not certified by peer review) is the author/funder, who has granted medRxiv a license to display the preprint in perpetuity. All rights reserved. No reuse allowed without permission.

Mutation Analysis by NextGeneration Sequencing of cfDNA

cfDNA extraction

Samples were collected and shipped to the central testing laboratory (Nanjing Geneseeq Technology Inc.) within 48 hours. cfDNA was extracted using the QIAamp Circulating Nucleic Acid Kit (QIAGEN). Genomic DNA of the whole blood sample was prepared by DNeasy Blood & Tissue kit (QIAGEN) as control for germline mutations. DNA was quantified by dsDNA HS Assay Kit (Life Technologies, Eugene, OR, USA) according to the manufacturer's recommendations.

Library Preparation

Sequencing libraries were prepared using the KAPA Hyper Prep kit (KAPA Biosystems,Cape Town,South Africa) with an optimized manufacturer's protocol. In brief, 50ng - 1 μg of genomic DNA was sheared into 350 bp fragments using the Bioruptor Pico, and then underwent end-repairing, A-tailing and ligation with indexed adapters sequentially, followed by size selection using Agencourt AMPure XP beads. Finally, libraries were amplified by PCR and purified for target enrichment.

Hybridization Capture and Sequencing

Different libraries with unique indices were pooled together in desirable ratios for up to 2 μg of total library input. Human cot-1 DNA (Life Technologies,Carlsbad,CA,USA) and xGen Universal blocking oligos (Integrated DNA Technologies,Coralville,IA,USA) targeting 446 lyphoma-related genes were used for hybridization enrichment. The capture reaction was performed with the NimbleGen SeqCap EZ Hybridization and Wash Kit (Roche,Madison,WI,USA) and Dynabeads M-270 (Life Technologies,Vilnius,Lithuania) with optimized manufacturers' protocols. Captured libraries were on-beads amplified with Illumina p5 and p7 primers in KAPA HiFi HotStart ReadyMix (KAPA

medRxiv preprint doi: https://doi.org/10.1101/2021.10.18.21265102; this version posted October 19, 2021. The copyright holder for this preprint (which was not certified by peer review) is the author/funder, who has granted medRxiv a license to display the preprint in perpetuity. All rights reserved. No reuse allowed without permission.

Biosystems, Cape Town, South Africa). The post-capture amplified library was purified by Agencourt AMPure XP beads and quantified by qPCR using the KAPA Library Quantification kit (KAPA Biosystems, Cape Town, South Africa). Library fragment size was determined by the Agilent Technologies 2100 Bioanalyzer (Agilent, Santa Clara, CA, USA). Enriched libraries were sequenced on Hiseq 4000 NGS platforms (Illumina) to targeted mean coverage depths of at least 100x for whole blood control samples, and 5000x for cfDNAs.

Sequence Data Processing

Trimmomatic was used for FASTQ file quality control (QC). Reads from each sample were mapped to the reference sequence hg19 (Human Genome version 19) using Burrows-Wheeler Aligner (BWA-mem, v0.7.12). VarScan2 was employed for detection of somatic mutations. Annotation was performed using ANNOVAR on hg19 reference genome and 2014 versions of standard databases and functional prediction programs. Genomic fusions were identified by FACTERA with default parameters. Copy number variations (CNVs) were detected using ADTEx (http://adtex.sourceforge.net) with default parameters. An IOF or a plasma sample was defined as ctDNA-positive if any somatic mutations detected in the 446 gene panel. All mutations were confirmed by the Integrative Genomics Viewer (IGV v2.3). The CNVs of each gene in the 446 gene panel were estimated from the calculation of CNVs by Control-FREEC. The KEGG signal analysis were analyzed by KOBAS 3.0 (http://kobas.cbi.pku.edu.cn).

Statistical analyses

Comparisons of the cfDNA concentration and mutations were analyzed by Student's t-test for normally distributed data, and Mann Whitney test for non-normally distributed data. Data were presented as the median (IQR, 25% percentile, 75% percentile). An alpha value of $p<0.05$ was

medRxiv preprint doi: https://doi.org/10.1101/2021.10.18.21265102; this version posted October 19, 2021. The copyright holder for this preprint (which was not certified by peer review) is the author/funder, who has granted medRxiv a license to display the preprint in perpetuity. All rights reserved. No reuse allowed without permission.

considered statistically significant. The statistical analyses were performed using the Statistical Package for the Social Sciences (SPSS, version 19.0).

Results

Demographic, Clinical and Laboratory Data of Patients in Training Group

A total of 23 presumed VRL patients had been tested for genetic mutation analysis in ZOC from April 1st 2018 to March 1st 2021. These patients including 17 VRL patients and 6 uveitis patients, who got clear diagnosis after clinical examination and follow-up treatment, were enrolled as a training group and analyzed retrospectively. The demographic, clinical and laboratory data of patients in the training group were summarized in Table 1.

The IOF samples from the one checked eye of every patient in the training group were collected before treatment and sent for diagnostic tests. At the diagnostic stage, 7 paired AH and VF samples for diagnostic analysis from 7 patients were simultaneously collected by anterior chamber puncture and vitrectomy. Unpaired samples included those samples of which only VF or AH was available for analysis. Sixteen unpaired samples, 10 AH samples and 6 VF samples were collected from 16 patients respectively. At the same time, 22 blood samples and 9 CSF samples from the 23 patients were also collected.

A total of 17 patients (17/23, 73.91%) were diagnosed as VRL: 5 (21.74%) were pathologically diagnosed, and 12 (52.17%) were clinically

medRxiv preprint doi: https://doi.org/10.1101/2021.10.18.21265102; this version posted October 19, 2021. The copyright holder for this preprint (which was not certified by peer review) is the author/funder, who has granted medRxiv a license to display the preprint in perpetuity. All rights reserved. No reuse allowed without permission.

diagnosed. Of the 12 clinical VRL patients, 10 (83.33%) had IL-10/IL-6 ratio ≥1 and responded well to systemic and/or local anti-tumor therapy; 2 had symptoms alleviated after MTX intravitreal injection, although the IL-10/ IL-6 ratio was < 1. Among these 17 VRL patients, 5 had gene rearrangements test and 4 out of them (sensitivity 80%) turned out to be positive. Meanwhile, 6 patients (6/23, 26.09%) were proven to be chronic uveitis with different etiology, including autoimmune uveitis, virus uveitis and diffuse uveal melanocytic proliferation. One of uveitis patients diagnosed as uveitis was negative for cfDNA mutation analysis but had a very high concentration of IL-10 in IOF. The elevated IL-10 made the diagnosis confused, but the patient had symptoms alleviated after the anti-virus and glucocorticoids treatment for 6 months and got remission at present. Among these 23 patients, the sensitivity and specificity of IL-10/IL-6 ratio were 88.24% and 83.33% respectively.

Intraocular cfDNA genetic mutation analysis exhibited high sensitivity and specificity for VRL diagnosis in training group

The cfDNA of AH and VF samples from the 23 patients were performed with genetic mutation analysis by NGS and the results were analyzed. Among all the 23 enrolled patients, 19 patients got ctDNA positive, while 4 patients were ctDNA negative. All of the 17 VRL cases were ctDNA positive comparing with that 2 of 6 uveitis cases were ctDNA positive (Figure 1).

The cfDNA concentration of AH [0.48 (IQR 0.37, 0.60) ng/μl] and VH [1.5 (IQR 0.93, 4.02) ng/μl] in VRL group (including definitively and clinically diagnosed VRL cases) had no significant difference with those in uveitis patients [0.38 (IQR 0.15, 0.47), 0.24 (IQR 0.20, 0.28) ng/μl, respectively]. However, the ctDNA concentration (hGE/ml), the mean of MAF and the number of somatic mutations of VRL patients were significantly higher than uveitis group (Table 2, Figure 2).

medRxiv preprint doi: https://doi.org/10.1101/2021.10.18.21265102; this version posted October 19, 2021. The copyright holder for this preprint (which was not certified by peer review) is the author/funder, who has granted medRxiv a license to display the preprint in perpetuity. All rights reserved. No reuse allowed without permission.

Two of 6 uveitis patients (patient 18 and patient 20) were ctDNA positive. Patient 18 was presented with severe vitreous opacity in left eye in October 2020. He had a history of ankylosing spondylitis and uveitis for 20 years. His vision fluctuated due to irregular immune suppressive treatment. The condition improved after vitrectomy surgery and achieved remission with Adalimumab treatment for 1 year. The mutation of IKZF3 at a MAF of 39.6% was detected in his AH sample, with a ctDNA concentration of 57062 hGE/ml. And the IL-10/IL-6 ratio was less than 1. Patient 20 was diagnosed as autoimmune uveitis, he alleviated after immune suppressive agent treatment, and drugs had been discontinued since one year ago. Four mutations at a mean MAF of 8.1% were detected in his AH sample, including ASXL1, CHEK2, POT1 and FLT4. The ctDNA concentration (7292 hGE/ml) was relatively lower than the ctDNA concentration of VRL patients [56040 (IQR 50682, 79880) hGE/ml in AH]. Elevated IL-10 was not detected in his AH sample. Remarkably, all of these 5 mutations found in uveitis patients were not common in B-cell lymphomas.

The diagnostic values including sensitivity, specificity, positive and negative predictive value, and test efficiency were presented in Table 3. cfDNA genetic mutation analysis of IOF samples exhibited high diagnostic potential and efficiency for VRL.

Validation of cfDNA genetic mutation analysis as a diagnostic method for VRL

To consolidate our findings, 5 cases of VRL (3 pathological diagnosed VRL and 2 clinically diagnosed VRL) and 5 cases of uveitis were selected

medRxiv preprint doi: https://doi.org/10.1101/2021.10.18.21265102; this version posted October 19, 2021. The copyright holder for this preprint (which was not certified by peer review) is the author/funder, who has granted medRxiv a license to display the preprint in perpetuity. All rights reserved. No reuse allowed without permission.

as a validation cohort from Ophthalmic center in Beijing Chaoyang Hospital, China, to validate the value of genetic mutation analysis of IOF for VRL diagnosis. A total of 10 VF samples from these patients were send for cfDNA mutation test, for it's relatively more sufficient for mutation analysis than AH in sample bank of Chaoyang Hospital. It turned out that all of the 5 VRL patients were ctDNA positive, while 5 uveitis samples were ctDNA negative (Figure 1). The results shown that both the sensitivity and specificity of the test for VRL diagnosis were 100%.

The cfDNA concentrations, the ctDNA concentration, the mean of MAF and the number of somatic mutation of all validation samples were statistically analyzed (Table 4 and Figure 3). Thought it shows no difference in the cfDNA concentration between VRL and uveitis samples (P=0.310), all of the VRL IOF samples were ctDNA positive, with a significantly higher ctDNA concentration [192530 (IQR 110371, 1114886) hGE/ml), P=0.008], mean of MAF [31.7% (IQR 27.8% , 39.9%), P=0.008], and number of somatic mutations [19 (IQR 7.5, 23.0), P=0.008] by comparing with uveitis samples.

Both AH and VF samples show the same value in cfDNA genetic mutation analysis

Furthermore, we compared the genetic mutations of cfDNA in AH and VF samples of VRL patients, to evaluate the diagnostic value of different IOF samples. By comparing with AH, the concentration of cfDNA (ng/μl) and the concentration of ctDNA (hGE/ml) were significantly higher (P=0.002 and 0.002) in VF samples, while the mean of MAF and the number of genetic mutations show no difference (Figure 4A). Meanwhile, the types and frequencies of the top 12 high-frequency mutations were similar in paired samples of VRL patients (Figure 4B). Among the 7 paired IOF samples, the ctDNA detection rate of AH and VF sample were the same, showing the similar potential value for VRL diagnosis.

medRxiv preprint doi: https://doi.org/10.1101/2021.10.18.21265102; this version posted October 19, 2021. The copyright holder for this preprint (which was not certified by peer review) is the author/funder, who has granted medRxiv a license to display the preprint in perpetuity. All rights reserved. No reuse allowed without permission.

Genomic profiling of mutations in IOF from the 22 VRL patients of the study

All the samples undergone the 446-genes panel sequencing to identify the somatic mutations in IOF samples. The mutation profile of the 22 VRL patients (17 from training group and 5 from validation group) were illustrated by the bubble plot in Figure 5A. PIM1(21/22, 90.91%), MYD88 (17/22, 77.27%), CD79B (11/22, 50.00%), ETV6 (11/22, 50.00%) and IRF4 (11/22, 50.00%) were the five most frequently mutated genes found in these VRL patients.

Among these 22 VRL patients, 7 patients presented as retina type, 10 were vitreous opacity type and 5 were concomitant type. The comparison of mutations among different subtypes were analyzed and presented in Figure 5B. It shown that the mutation frequency of BTG2 gene was significantly higher in vitreous opacity type than in retinal type (P=0.0099). The gene of MYC was only detected in vitreous opacity type, yet the genes of CREBBP, FAT4 and MED12 were not detected in vitreous opacity type. Meanwhile the genes of ACTB, PRDM1, GADD45B and ALX were not detected in VRL of retinal type either.

Genetic Subtypes and lymphocyte differentiation pathways of genetic mutations of VRL patients

The genetic subtypes involved in different mutations of lymphocyte differentiation pathway, have distinct clinical outcomes. COO (Cell of origin) classification of DLBCL has been the most commonly use subtyping method for prognostic. In this study, we first classified the VRL patients into germinal-center B-cell-like (GCB) and non-GCB by applying the classifier described by Scherer et al[25]. It was found that 95.5% (21/22) of

medRxiv preprint doi: https://doi.org/10.1101/2021.10.18.21265102; this version posted October 19, 2021. The copyright holder for this preprint (which was not certified by peer review) is the author/funder, who has granted medRxiv a license to display the preprint in perpetuity. All rights reserved. No reuse allowed without permission.

the VRL patients were non-GCB subtype, except patient 17 was unclassified (Figure 6A). Recently, George et al.[26] established a LymphGen probabilistic algorithm which facilitate the application of DLBCL genetic subtyping, which was associated with the response to chemotherapy. By applying it, we next determined the subtype of each VRL patient. The nosology covered 86.36% (19/22) of VRL patients, including 17 (77.27%) were MCD, and 2 (9.09%) were BN2 (Figure 6B). Patient 17, who was unclassified by COO classification, classified as BN2 subtype in LymphGen algorithm with 0.76 confidence.

At the same time, we divided the genetic mutations of VRL into specific pathways that associated with B-cells differentiation. It was demonstrated that the VRL patients in our study were mostly characterized by mutations in PI3K-Akt signaling pathway, followed by MAPK, Transcriptional misregulation in cancer, Ras, JAK-STAT and NF-kappa B signaling pathway (Figure 6C).

Discussion

VRL, a non-Hodgkin lymphoma of DLBCL, is an aggressive cancer with high mortality[1]. The pathogenesis of VRL is largely unknown and diagnose of VRL remains a challenge for clinicians. Liquid biopsy, such as the detection and analysis of ctDNA has been emerged to be a valuable diagnostic method recently[14, 15]. In our study, we explored the diagnostic value of genetic mutation analysis in IOF with mini-invasion by NGS using a panel containing 466 tumor-related genes for VRL diagnosis. In training group, all of the VRL patients were positive for mutation detection in IOF (sensitivity 100%), and 2 out of 6 uveitis patients were positive (specificity 67%). However, the mutations detected in uveitis patients were identified as clonal hematopoiesis mutations. In validation group, both the sensitivity and specificity of cfDNA genetic

medRxiv preprint doi: https://doi.org/10.1101/2021.10.18.21265102; this version posted October 19, 2021. The copyright holder for this preprint (which was not certified by peer review) is the author/funder, who has granted medRxiv a license to display the preprint in perpetuity. All rights reserved. No reuse allowed without permission.

mutation analysis for VRL diagnosis were 100%. Meanwhile, it was found that both the AH and VF samples shown the same value in mutation detection for VRL diagnosis. Beside above, we also found that the top five mutated genes in VRL patients were PIM1 (21/22, 90.91%), MYD88 (77.27%), CD79B (50.00%), ETV6 (50.00%) and IRF4 (50.00%) with PI3K-Akt signaling pathway alternation. Among 22 VRL patients, 21 patients (95.45%) were classified as non-GCB while 1 patient was unclassified subtype. Using the LymphGen probabilistic algorithm, 77.27% of VRL patients were classified as MCD subtype, and 2 patients (9.1%) were BN2 subtype.

All VRL patients, including the patients of training group and validation group, were detected with abundant genetic mutations in cfDNA of IOF, which indicated a huge possibility of the presence of tumor cells (100% sensitivity). Previous studies had presented additional liquid biopsy tools to detect mutations to support the VRL diagnosis. Unfortunately, the sensitivity was not satisfied because the types of mutations they tested were limited. The panel of 466 tumor-related genes we applied had an advantage of tracking novel or rare mutations in VRL, thus it was comprehensive enough for VRL diagnosis with 100% sensitivity. In addition, in this study the diagnostic value of genetic mutations of AH and VF samples were compared. We found that although the concentration of cfDNA and ctDNA were significantly higher (P=0.002 and 0.002) in VF samples, the mean of MAF, the number of genetic mutations, the types and frequencies of the top 12 high-frequency mutations were similar. In consideration of safety and simplicity of anterior chamber paracentesis, it is suggested that genetic mutation analysis using a targeted panel sequencing in AH was a feasible method for VRL diagnosis clinically.

It was noticed that two AH samples from 6 uveitis patients of training group were positive for genetic mutation analysis. However, the detected

medRxiv preprint doi: https://doi.org/10.1101/2021.10.18.21265102; this version posted October 19, 2021. The copyright holder for this preprint (which was not certified by peer review) is the author/funder, who has granted medRxiv a license to display the preprint in perpetuity. All rights reserved. No reuse allowed without permission.

mutant genes (IKZF3, ASXL1, CHEK2, POT1, FLT4) were not common in B-cell lymphoma, yet were considered to be the clonal hematopoiesis mutations[27-29]. The clonal hematopoiesis was a common aging-associated process that involved the leukemia-associated mutations accumulation in the hematopoietic stem cells[30]. Thus, it was crucial to make a comprehensive analysis of the clinical characteristics, the allele frequencies the of mutations and the specificity of the detected mutated genes when getting a positive result. The detection of abundant high-frequency mutations, especially the reported genes derived from VRL patients, made a greater possibility of VRL diagnosis. In regard of these, we needed more cases to optimize and establish a more specific panel of VRL-related genes for VRL diagnosis. Meanwhile, because it was the first diagnostic accuracy study using this tumor-related gene panel for mutation analysis in VRL patients, we set the cut-off of mutations number as zero which contributed to the false positives in training group. A perspective study to explore an optimal cut-off for VRL diagnosis would be urgently needed.

In training group, IL-10/IL-6 ratio of IOF samples were checked in all 23 patients, while IGH gene rearrangements were tested in 5 VRL patients. The results showed that the sensitivity and specificity of IL-10/IL-6 ratio were 88.24% (15/17) and 83.33% (1/6) respectively, while the sensitivity IGH gene rearrangements were 80% (4/5), which were consistent with literature reports[9-11]. The sensitivity of IL-10/IL-6 ratio and IGH gene rearrangements were lower than the genetic mutation analysis in our study.

Pathological features and molecular classification had shown the potential clinical utility on lymphoma treatment and prognosis. In our study the VRL patients were characterized by the high mutation frequencies of PIM1, MYD88, CD79B, ETV6 and IRF4. Based on their genomic

medRxiv preprint doi: https://doi.org/10.1101/2021.10.18.21265102; this version posted October 19, 2021. The copyright holder for this preprint (which was not certified by peer review) is the author/funder, who has granted medRxiv a license to display the preprint in perpetuity. All rights reserved. No reuse allowed without permission.

abnormalities, 21 patients (95.45%) were classified as non-GCB subtype, which was consistent with the previous findings that, the non-GCB subtype accounted for the main proportion of CNS lymphoma[31, 32]. In 2018, Schmitz et al. extended the DLBCL into MCD, BN2, N1 and EZB subtypes, which had been proved to be associated with the response to chemotherapy[33, 34]. Using the LymphGen probabilistic algorithm[26], 77.27% of VRL patients were classified as MCD subtype, and 2 patients (9.1%) were BN2 subtype. It was reported that the viability of MCD cells was likely sustained by BCL2, thus the treatment targeting BCL2 may be effective against MCD. And BN2 had favorable survival comparing with MCD in DLBCL[26]. However, there was lack of study on the genetic molecular classification and signaling pathway of VRL. In our study, we presented the genetic mutation profile and revealed the molecular characteristics of VRL, which might provide great value for the investigation of the pathogenesis and treatment strategy of VRL in the future.

In conclusion, it was proved that the genetic mutation analysis of cfDNA in IOF using a 466-gene-panel was a minimally-invasive and feasible testing for VRL diagnosis. These 466 genes contained in our panel were comprehensive enough for VRL diagnosis with 100% sensitivity. However, the huge set of genes contained some unspecific genes for VRL contributing to the specificity of 67%, which called for more cases to optimize and establish a more specific panel for VRL. Meanwhile, the analysis was informative enough to track genetic profile for VRL, which could reveal genetic heterogeneity and molecular characteristics of VRL. It may contribute to targeted treatment in future.

medRxiv preprint doi: https://doi.org/10.1101/2021.10.18.21265102; this version posted October 19, 2021. The copyright holder for this preprint (which was not certified by peer review) is the author/funder, who has granted medRxiv a license to display the preprint in perpetuity. All rights reserved. No reuse allowed without permission.

Authorship Contributions

YH, XC and DL were responsible for the conception and design of the study, data collection, data analysis, and manuscript writing. XC, WS, SY, ZQ, HH, YT and DL contributed to the patients' follow-up and clinical data collection. WS, HH and YT provided guide of study. XH, CL, HH and YT helped in the experiment design. XH, CL, ZQ and ZL were helpful in data analysis and manuscript writing. XC, HH, YT and DL were responsible for conception and design, revision of the manuscript, and final manuscript approval. All authors contributed to the article and approved the submitted version.

Disclosure of Conflicts of Interest

There is no conflict of financial interests in relation to the work described to declare.

medRxiv preprint doi: https://doi.org/10.1101/2021.10.18.21265102; this version posted October 19, 2021. The copyright holder for this preprint (which was not certified by peer review) is the author/funder, who has granted medRxiv a license to display the preprint in perpetuity. All rights reserved. No reuse allowed without permission.

medRxiv preprint doi: https://doi.org/10.1101/2021.10.18.21265102; this version posted October 19, 2021. The copyright holder for this preprint (which was not certified by peer review) is the author/funder, who has granted medRxiv a license to display the preprint in perpetuity. All rights reserved. No reuse allowed without permission.

References

1. Chan CC, Rubenstein JL, Coupland SE, Davis JL, Harbour JW, Johnston PB, et al. Primary vitreoretinal lymphoma: a report from an International Primary Central Nervous System Lymphoma Collaborative Group symposium. *Oncologist.* 2011;16(11):1589-1599.
2. Bataille B, Delwail V, Menet E, Vandermarcq P, Ingrand P, Wager M, et al. Primary intracerebral malignant lymphoma: report of 248 cases. *J Neurosurg.* 2000;92(2):261-266.
3. Rothova A, Ooijman F, Kerkhoff F, Van Der Lelij A, and Lokhorst HM. Uveitis masquerade syndromes. *Ophthalmology.* 2001;108(2):386-399.
4. Sen HN, Bodaghi B, Hoang PL, and Nussenblatt R. Primary intraocular lymphoma: diagnosis and differential diagnosis. *Ocul Immunol Inflamm.* 2009;17(3):133-141.
5. Davis JL. Diagnosis of intraocular lymphoma. *Ocul Immunol Inflamm.* 2004;12(1):7-16.
6. Wittenberg LA, Maberley DA, Ma PE, Wade NK, Gill H, and White VA. Contribution of vitreous cytology to final clinical diagnosis fifteen-year review of vitreous cytology specimens from one institution. *Ophthalmology.* 2008;115(11):1944-1950.
7. Kase S, Namba K, Iwata D, Mizuuchi K, Kitaichi N, Tagawa Y, et al. Diagnostic efficacy of cell block method for vitreoretinal lymphoma. *Diagn Pathol.* 2016;11:29.
8. Gupta OP, Weichel ED, Regillo CD, Fineman MS, Kaiser RS, Ho AC, et al. Postoperative complications associated with 25-gauge pars plana vitrectomy. *Ophthalmic Surg Lasers Imaging.* 2007;38(4):270-275.
9. Kimura K, Usui Y, Goto H, and Japanese Intraocular Lymphoma Study G. Clinical features and diagnostic significance of the intraocular fluid of 217 patients with intraocular lymphoma. *Jpn J Ophthalmol.* 2012;56(4):383-389.
10. Coupland SE, Hummel M, Muller HH, and Stein H. Molecular analysis of immunoglobulin genes in primary intraocular lymphoma. *Invest Ophthalmol Vis Sci.* 2005;46(10):3507-3514.
11. Wang Y, Shen D, Wang VM, Sen HN, and Chan CC. Molecular biomarkers for the diagnosis of primary vitreoretinal lymphoma. *Int J Mol Sci.* 2011;12(9):5684-5697.
12. Dawson SJ, Tsui DW, Murtaza M, Biggs H, Rueda OM, Chin SF, et al. Analysis of circulating tumor DNA to monitor metastatic breast cancer. *N Engl J Med.* 2013;368(13):1199-1209.
13. Murtaza M, Dawson SJ, Tsui DW, Gale D, Forshew T, Piskorz AM, et al. Non-invasive analysis of acquired resistance to cancer therapy by sequencing of plasma DNA. *Nature.* 2013;497(7447):108-112.
14. Leung F, Kulasingam V, Diamandis EP, Hoon DS, Kinzler K, Pantel K, et al. Circulating Tumor DNA as a Cancer Biomarker: Fact or Fiction? *Clin Chem.* 2016;62(8):1054-1060.
15. Roschewski M, Dunleavy K, Pittaluga S, Moorhead M, Pepin F, Kong K, et al. Circulating tumour DNA and CT monitoring in patients with untreated diffuse large B-cell lymphoma: a correlative biomarker study. *Lancet Oncol.* 2015;16(5):541-549.

medRxiv preprint doi: https://doi.org/10.1101/2021.10.18.21265102; this version posted October 19, 2021. The copyright holder for this preprint (which was not certified by peer review) is the author/funder, who has granted medRxiv a license to display the preprint in perpetuity. All rights reserved. No reuse allowed without permission.

16. Kurtz DM, Scherer F, Jin MC, Soo J, Craig AFM, Esfahani MS, et al. Circulating Tumor DNA Measurements As Early Outcome Predictors in Diffuse Large B-Cell Lymphoma. *J Clin Oncol.* 2018;36(28):2845-2853.
17. Hiemcke-Jiwa LS, Ten Dam-van Loon NH, Leguit RJ, Nierkens S, Ossewaarde-van Norel J, de Boer JH, et al. Potential Diagnosis of Vitreoretinal Lymphoma by Detection of MYD88 Mutation in Aqueous Humor With Ultrasensitive Droplet Digital Polymerase Chain Reaction. *JAMA Ophthalmol.* 2018;136(10):1098-1104.
18. Bonzheim I, Giese S, Deuter C, Susskind D, Zierhut M, Waizel M, et al. High frequency of MYD88 mutations in vitreoretinal B-cell lymphoma: a valuable tool to improve diagnostic yield of vitreous aspirates. *Blood.* 2015;126(1):76-79.
19. Miserocchi E, Ferreri AJM, Giuffre C, Cangi MG, Francaviglia I, Calimeri T, et al. Myd88 L265p Mutation Detection in the Aqueous Humor of Patients with Vitreoretinal Lymphoma. *Retina.* 2019;39(4):679-684.
20. Davis JL, Miller DM, and Ruiz P. Diagnostic testing of vitrectomy specimens. *Am J Ophthalmol.* 2005;140(5):822-829.
21. Chan CC. Molecular pathology of primary intraocular lymphoma. *Trans Am Ophthalmol Soc.* 2003;101:275-292.
22. Davis JL, Solomon D, Nussenblatt RB, Palestine AG, and Chan CC. Immunocytochemical staining of vitreous cells. Indications, techniques, and results. *Ophthalmology.* 1992;99(2):250-256.
23. Hashida N, Nakai K, Saitoh N, and Nishida K. Association between ocular findings and preventive therapy with onset of central nervous system involvement in patients with primary vitreoretinal lymphoma. *Graefes Arch Clin Exp Ophthalmol.* 2014;252(4):687-693.
24. Akobeng AK. Understanding diagnostic tests 1: sensitivity, specificity and predictive values. *Acta Paediatr.* 2007;96(3):338-341.
25. Scherer F, Kurtz DM, Newman AM, Stehr H, Craig AF, Esfahani MS, et al. Distinct biological subtypes and patterns of genome evolution in lymphoma revealed by circulating tumor DNA. *Sci Transl Med.* 2016;8(364):364ra155.
26. Wright GW, Huang DW, Phelan JD, Coulibaly ZA, Roulland S, Young RM, et al. A Probabilistic Classification Tool for Genetic Subtypes of Diffuse Large B Cell Lymphoma with Therapeutic Implications. *Cancer Cell.* 2020;37(4):551-568 e514.
27. Asada S, Fujino T, Goyama S, and Kitamura T. The role of ASXL1 in hematopoiesis and myeloid malignancies. *Cell Mol Life Sci.* 2019;76(13):2511-2523.
28. Bolton KL, Ptashkin RN, Gao T, Braunstein L, Devlin SM, Kelly D, et al. Cancer therapy shapes the fitness landscape of clonal hematopoiesis. *Nat Genet.* 2020;52(11):1219-1226.
29. Stengel A, Baer C, Walter W, Meggendorfer M, Kern W, Haferlach T, et al. Mutational patterns and their correlation to CHIP-related mutations and age in hematological malignancies. *Blood Adv.* 2021.
30. Li Z, Huang W, Yin JC, Na C, Wu X, Shao Y, et al. Comprehensive next-generation profiling of clonal hematopoiesis in cancer patients using paired tumor-blood sequencing for guiding personalized therapies. *Clin Transl Med.* 2020;10(7):e222.

medRxiv preprint doi: https://doi.org/10.1101/2021.10.18.21265102; this version posted October 19, 2021. The copyright holder for this preprint (which was not certified by peer review) is the author/funder, who has granted medRxiv a license to display the preprint in perpetuity. All rights reserved. No reuse allowed without permission.

31. Camilleri-Broet S, Criniere E, Broet P, Delwail V, Mokhtari K, Moreau A, et al. A uniform activated B-cell-like immunophenotype might explain the poor prognosis of primary central nervous system lymphomas: analysis of 83 cases. *Blood.* 2006;107(1):190-196.

32. Preusser M, Woehrer A, Koperek O, Rottenfusser A, Dieckmann K, Gatterbauer B, et al. Primary central nervous system lymphoma: a clinicopathological study of 75 cases. *Pathology.* 2010;42(6):547-552.

33. Schmitz R, Wright GW, Huang DW, Johnson CA, Phelan JD, Wang JQ, et al. Genetics and Pathogenesis of Diffuse Large B-Cell Lymphoma. *N Engl J Med.* 2018;378(15):1396-1407.

34. Shechter R, London A, and Schwartz M. Orchestrated leukocyte recruitment to immune-privileged sites: absolute barriers versus educational gates. *Nat Rev Immunol.* 2013;13(3):206-218.

Table 1. Demographic, Clinical and Laboratory Data of Patients Included in Training Group

Characteristics	VRL	Uveitis
Total, No. (%)	17(73.91)	6(26.01)
Age, y, mean±SD	58.06 ± 2.42	54.17 ± 3.73
Sex, No. (%)		
Male	9(52.94)	4(66.67)
Female	8(47.06)	2(33.33)
Clinical typing, No.		
Vitreous opacity type	8	-
Retina type	5	-
Concomitant type	4	-
Brain involvement, No.	6	0
Follow-up time, months, median (min, max)	15 (7, 40)	11.5 (7, 24)
Samples for mutation analysis, No.		
Aqueous humor	12	5
Vitreous fluid	11	2
Paired samples	6	1
Ocular Pathology		
positive No. (total No.)	5(11)	0(2)
IL-10/IL-6		
positive No. (total No.)	15(17)	1(6)
Gene rearrangements		
positive No. (total No.)	4(5)	0(0)
cfDNA genetic mutation analysis		
positive No. (total No.)	17(17)	2(6)

medRxiv preprint doi: https://doi.org/10.1101/2021.10.18.21265102; this version posted October 19, 2021. The copyright holder for this preprint (which was not certified by peer review) is the author/funder, who has granted medRxiv a license to display the preprint in perpetuity. All rights reserved. No reuse allowed without permission.

VRL: vitreoretinal lymphoma; No.: number; IL-10: interleukin-10 cytokines; IL-6: interleukin-6 cytokines;

medRxiv preprint doi: https://doi.org/10.1101/2021.10.18.21265102; this version posted October 19, 2021. The copyright holder for this preprint (which was not certified by peer review) is the author/funder, who has granted medRxiv a license to display the preprint in perpetuity. All rights reserved. No reuse allowed without permission.

Table 2. The Description and Comparison of Genetic Mutation Analysis Results Between VRL and Uveitis Patients in Training Group

	Anterior Humor				Vitreous Fluid			
	cfDNA concentration (ng/μl)	**ctDNA concentration (hGE/ml)**	**mean MAF**	**number of somatic mutation**	**cfDNA concentration (ng/μl)**	**ctDNA concentration (hGE/ml)**	**mean MAF**	**number of somatic mutation**
VRL	0.475 (0.3650, 0.6000)	56040 (50682, 79880)	45.5% (35%, 49%)	23 (13.5, 36.0)	1.5 (0.9300, 4.020)	164217 (108941, 336531)	39.2% (33%, 41%)	18 (12.0, 24.0)
Uveitis	0.38 (0.1490, 0.4740)	0 (0, 32177)	0.0% (0, 8.1%)	0 (0, 1)	0.239 (0.1980, 0.2800)	0 (0, 0)	0 (0, 0)	0 (0, 0)
P value	0.1367	0.0092	0.0039	0.0003	0.1026	0.0256	0.0256	0.0256

Data are presented as the median (IQR, 25% percentile，75% percentile).

medRxiv preprint doi: https://doi.org/10.1101/2021.10.18.21265102; this version posted October 19, 2021. The copyright holder for this preprint (which was not certified by peer review) is the author/funder, who has granted medRxiv a license to display the preprint in perpetuity. All rights reserved. No reuse allowed without permission.

Table 3. The Diagnosis Value of cfDNA Genetic Mutation Analysis for VRL Diagnosis in Training Group

Genetic mutations in cfDNA	Patients with VRL	Patients with uveitis
Positive; ctDNA(+)	17	2
Negative; ctDNA(-)	0	4
Sensitivity	1	
Specificity	0.67	
Positive predictive value	0.89	
Negative predictive value	1	
Test efficency	0.91	

ctDNA: circulating tumor DNA. The detection of genetic mutations was considered as a positive result and recorded as ctDNA (+).

medRxiv preprint doi: https://doi.org/10.1101/2021.10.18.21265102; this version posted October 19, 2021. The copyright holder for this preprint (which was not certified by peer review) is the author/funder, who has granted medRxiv a license to display the preprint in perpetuity. All rights reserved. No reuse allowed without permission.

Table 4. The Description and Comparison of Genetic Mutation Analysis Results Between VRL and Uveitis Patients in Validation Group

	Vitreous Fluid			
	cfDNA concentration (ng/μl)	**ctDNA concentration (hGE/ml)**	**mean MAF**	**number of somatic mutation**
VRL	1.92 (1.106, 9.620)	192530 (110371, 1114886)	31.7% (26%, 40%)	19 (7.5, 23.0)
Uveitis	1.11 (0.337, 13.480)	0 (0, 0)	0.0% (0, 0)	0 (0, 0)
P value	0.3095	0.0079	0.0079	0.0079

Data are presented as the median (IQR, 25% percentile , 75% percentile).

medRxiv preprint doi: https://doi.org/10.1101/2021.10.18.21265102; this version posted October 19, 2021. The copyright holder for this preprint (which was not certified by peer review) is the author/funder, who has granted medRxiv a license to display the preprint in perpetuity. All rights reserved. No reuse allowed without permission.

Fig. 1. The work flow chart of patients inclusion and results of genetic mutation analysis.

Fig. 2. The comparison of genetic mutations in anterior humor and vitreous fluid samples between VRL and uveitis patients in training group. (A, B) There was no significant difference of the cfDNA concentration between VRL and uveitis patients. However, the ctDNA concentration, the mean MAF and the number of somatic mutations of both anterior humor and vitreous fluid samples were greatly higher in VRL patients than those in uveitis patients.

Fig. 3. The comparison of genetic mutations in vitreous fluid samples between VRL and uveitis patients in validation group. There was no significant difference of the cfDNA concentration between VRL and uveitis patients. However, the ctDNA concentration, the mean of MAF and the number of somatic mutations was greatly higher in VRL patients.

Fig. 4. The genetic mutations in anterior humor and vitreous fluid samples show equal value in diagnosis of VRL. (A) The cfDNA concentration and the ctDNA concentration in VF samples were significantly higher than those in AH samples, while the mean of MAF and the number of genetic mutations show no difference. **(B, C)** For the paired IOF samples, the frequencies of the top 12 high-frequency mutations and the types of mutations were similar in both AH and VF samples.

Fig. 5. Genomic prolifing of targeted mutations in 22 VRL patients of the study. (A) Bubble plot represented all detectable gene mutations identified in each patient. The bubble size represents the mutation allele frequency (MAF). **(B)** The bar graph illustrated the distribution of some high-frequency mutations among the VRL of the vitreous opacity type, the concomitant type and the retina type.

Fig. 6. Subtypes prediction and lymphocyte differentiation pathways of genetic mutations among these VRL patients. (A, B) The subtypes of VRL patient based on CCO (cell of origin) classification. The majority of VRL patients (95.45%) in our study were non-GCB type. Further classification using the LymphGen probabilistic algorithm, 17 VRL patients were MCD subtype, and 2 patients were BN2 subtype. **(C)** The genetic mutations of VRL patients were divided into specific pathways that associated with B-cells differentiation. The signaling pathways which were involved and prevalent in VRL patients were illustrated.

medRxiv preprint doi: https://doi.org/10.1101/2021.10.18.21265102; this version posted October 19, 2021. The copyright holder for this preprint (which was not certified by peer review) is the author/funder, who has granted medRxiv a license to display the preprint in perpetuity. All rights reserved. No reuse allowed without permission.

Figure 1

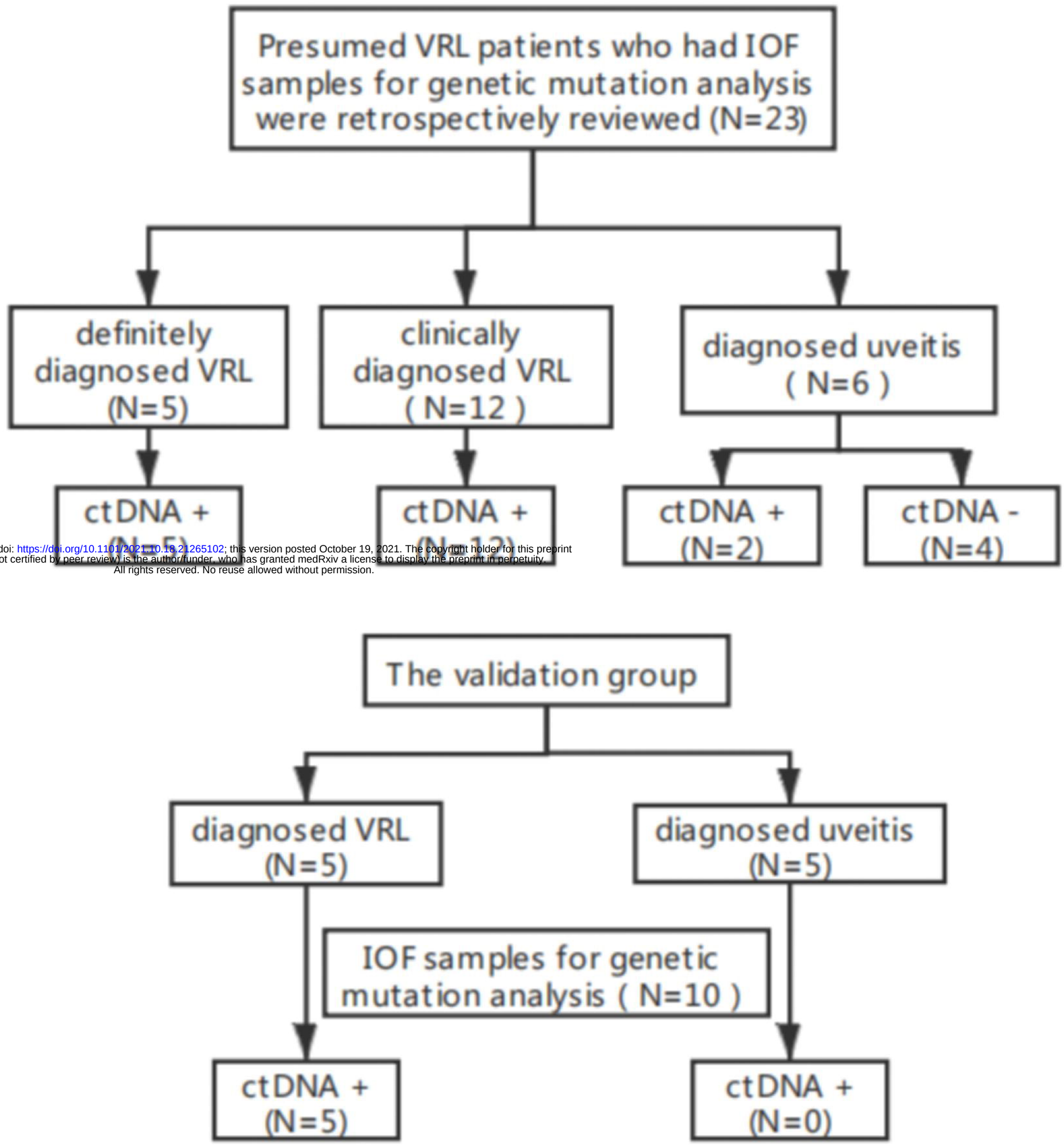

medRxiv preprint doi: https://doi.org/10.1101/2021.10.18.21265102; this version posted October 19, 2021. The copyright holder for this preprint (which was not certified by peer review) is the author/funder, who has granted medRxiv a license to display the preprint in perpetuity. All rights reserved. No reuse allowed without permission.

Figure 2

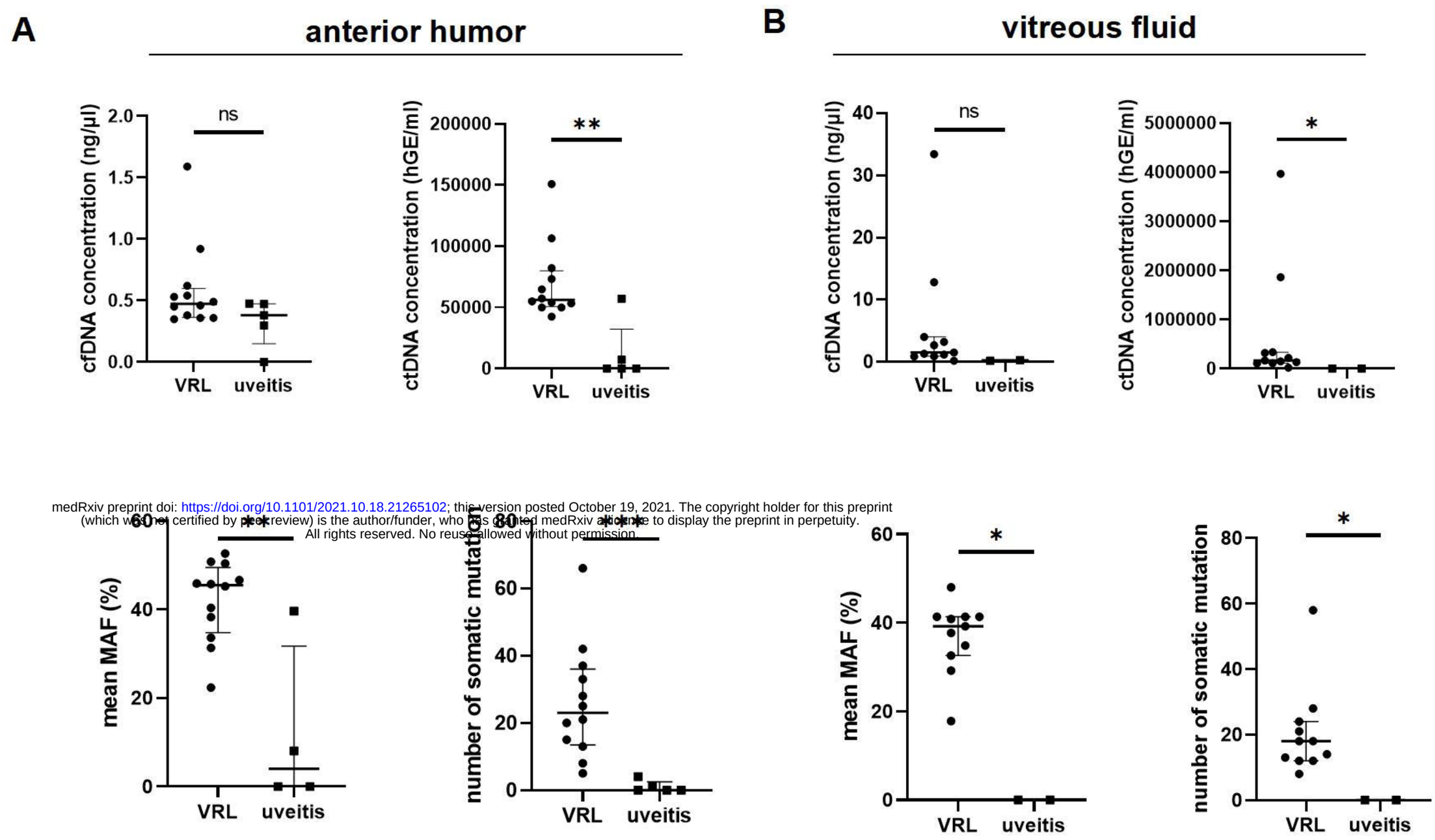

medRxiv preprint doi: https://doi.org/10.1101/2021.10.18.21265102; this version posted October 19, 2021. The copyright holder for this preprint (which was not certified by peer review) is the author/funder, who has granted medRxiv a license to display the preprint in perpetuity. All rights reserved. No reuse allowed without permission.

Figure 3

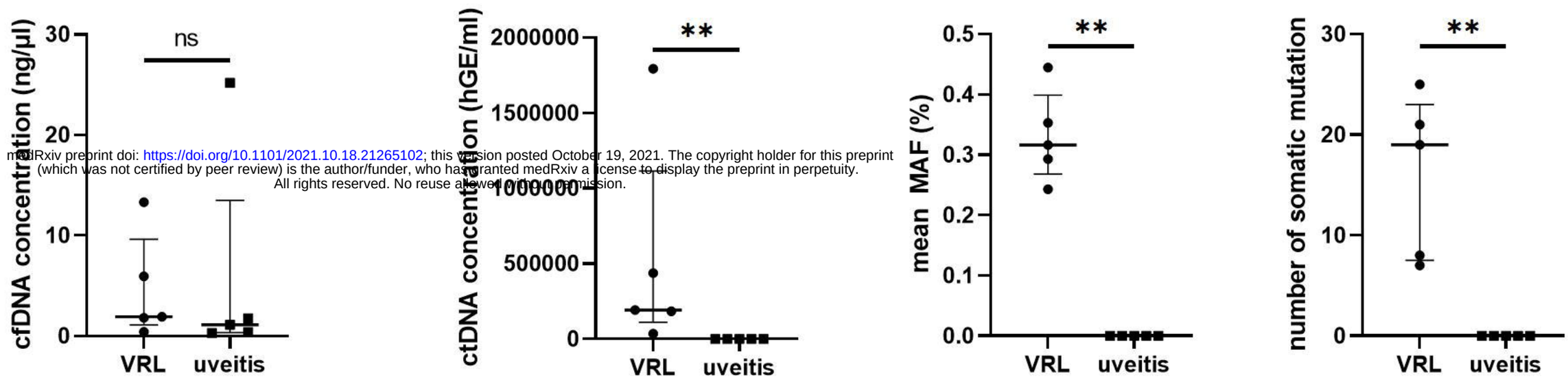

medRxiv preprint doi: https://doi.org/10.1101/2021.10.18.21265102; this version posted October 19, 2021. The copyright holder for this preprint (which was not certified by peer review) is the author/funder, who has granted medRxiv a license to display the preprint in perpetuity. All rights reserved. No reuse allowed without permission.

Figure 4

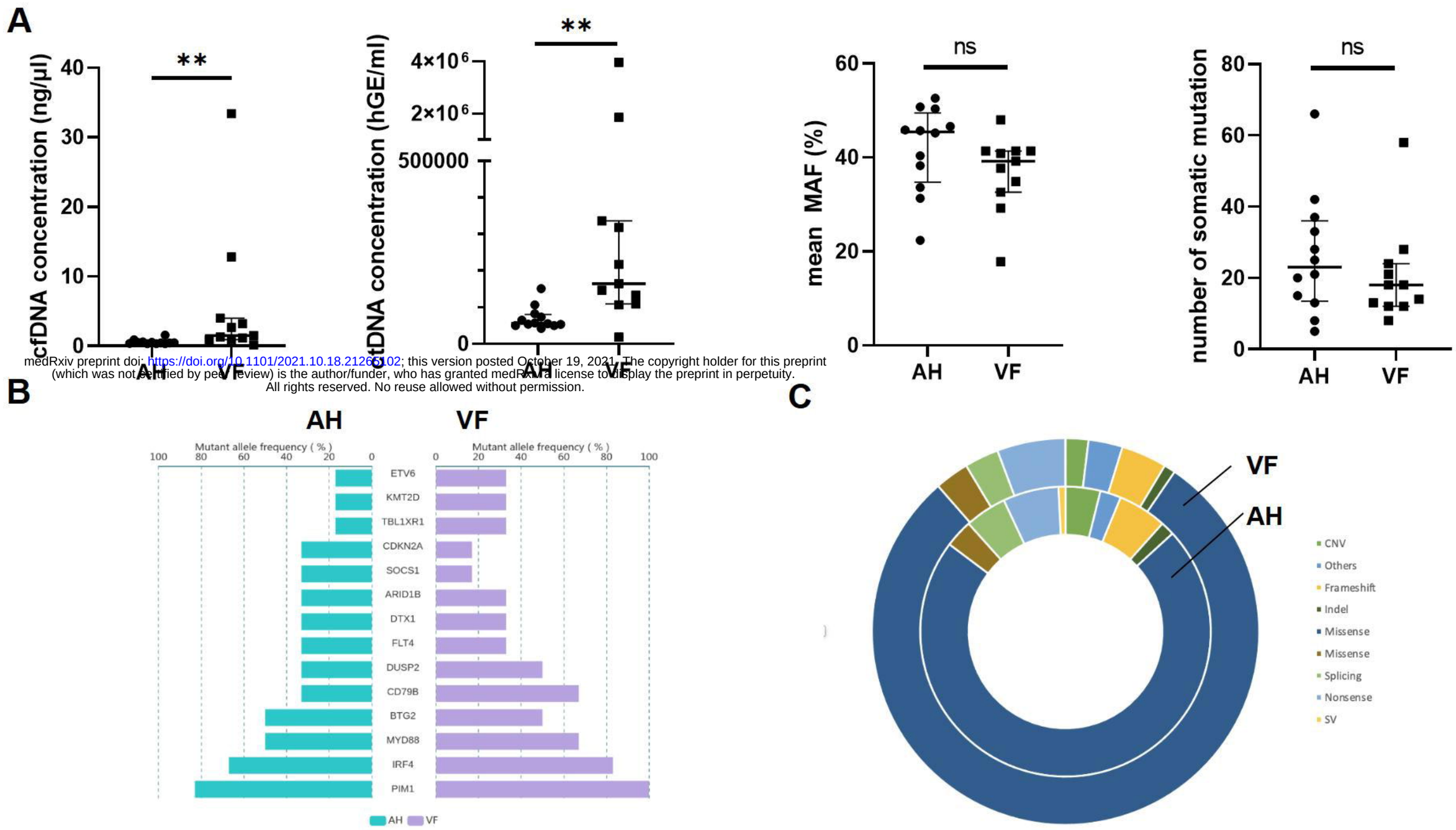

medRxiv preprint doi: https://doi.org/10.1101/2021.10.18.21265102; this version posted October 19, 2021. The copyright holder for this preprint (which was not certified by peer review) is the author/funder, who has granted medRxiv a license to display the preprint in perpetuity. All rights reserved. No reuse allowed without permission.

Figure 5

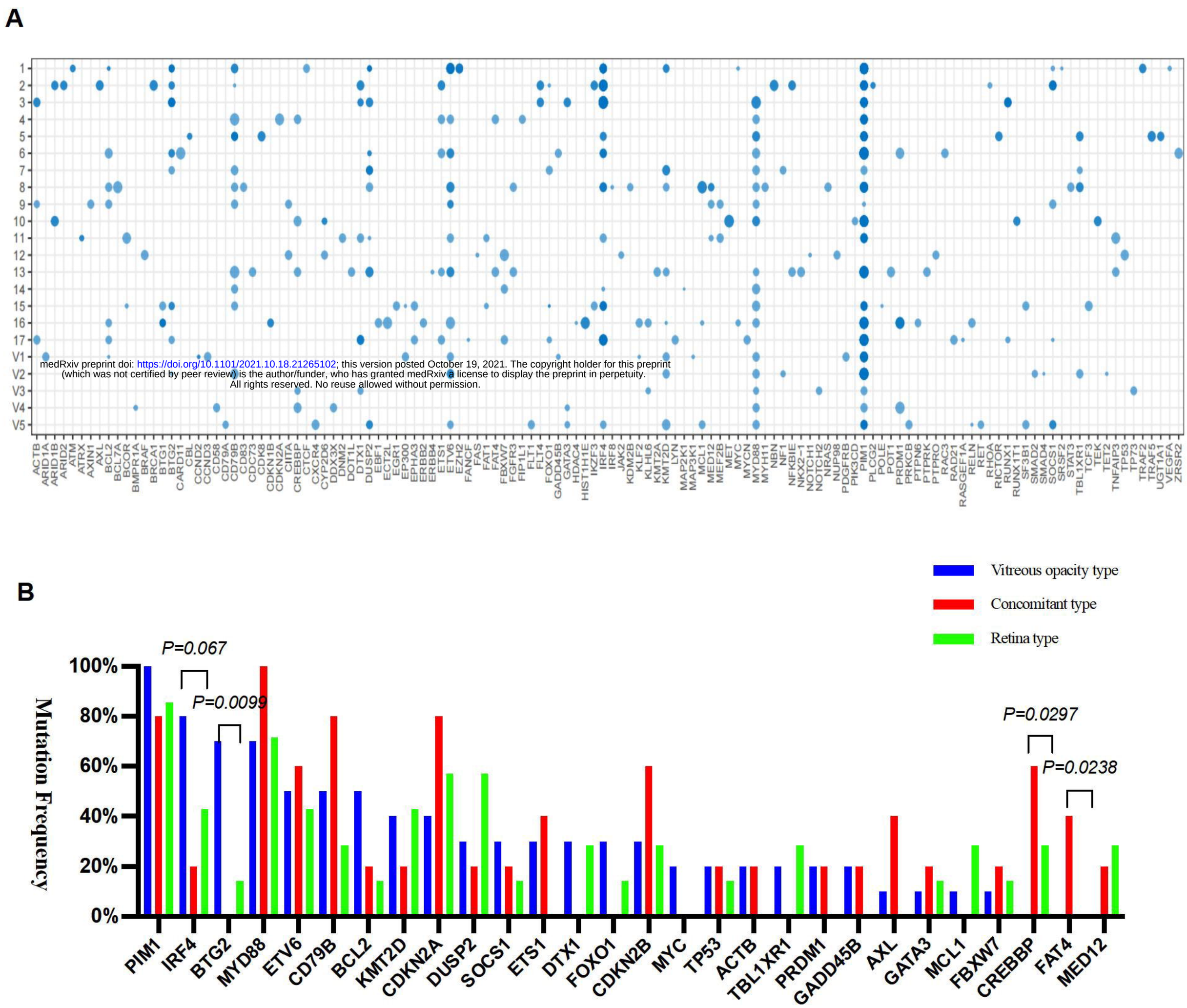

medRxiv preprint doi: https://doi.org/10.1101/2021.10.18.21265102; this version posted October 19, 2021. The copyright holder for this preprint (which was not certified by peer review) is the author/funder, who has granted medRxiv a license to display the preprint in perpetuity. All rights reserved. No reuse allowed without permission.

Figure 6

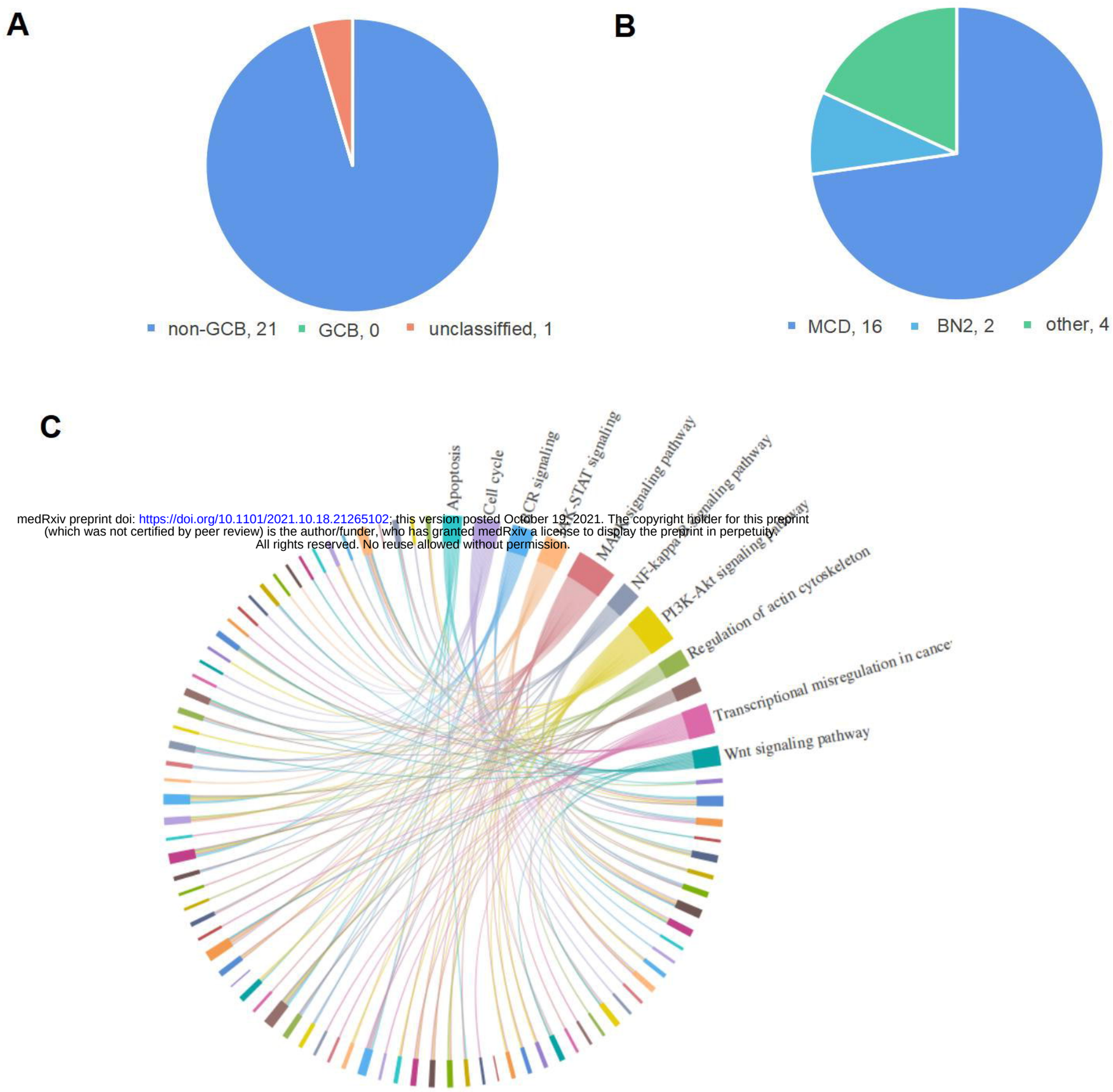

medRxiv preprint doi: https://doi.org/10.1101/2021.10.18.21265102; this version posted October 19, 2021. The copyright holder for this preprint (which was not certified by peer review) is the author/funder, who has granted medRxiv a license to display the preprint in perpetuity. All rights reserved. No reuse allowed without permission.