Coronary collaterals not visible by invasive angiography can provide more than half of normal resting perfusion in patients with coronary artery disease

Brandon Harris[a], Stafford Warren MD[b], Eva Persson MD PhD[c], Ravinay Bhindi MBBS PhD[a], Michael Ringborn MD PhD[d], Martin Ugander MD PhD[a§], Usaid Allahwala MBBS, PhD[a§]

(a) Kolling Institute, Department of Cardiology, Royal North Shore Hospital, and University of Sydney, Sydney, Australia

(b) Anne Arundel Medical Center, Department of Medicine, Cardiology Division, Annapolis, MD, USA

(c) Clinical Sciences, Department of Clinical Physiology, Skane University Hospital, Lund, Sweden

(d) Thoracic Center, Blekinge County Hospital, Karlskrona, Sweden

§ Denotes equal contribution as senior authors.

Correspondence to: Usaid Allahwala, MBBS, PhD
Department of Cardiology
Royal North Shore Hospital
Reserve Rd, St. Leonards
Sydney, Australia, 2065
Telephone +61 2 9463 2506
Fax +61 2 9463 2053
Email usaid.allahwala@sydney.edu.au

Short Title: Coronary collaterals provide >50% of normal perfusion in patients with CAD

Abstract

Background: There is sufficient collateral flow to prevent myocardial ischemia during balloon occlusion in approximately one in five patients. However, the magnitude of myocardial perfusion provided by the coronary collateral circulation during occlusion is unknown. Therefore, the aim of this study was to quantify collateral myocardial perfusion during balloon occlusion in patients with coronary artery disease (CAD). **Methods:** Patients without angiographically visible collaterals undergoing elective percutaneous transluminal coronary angioplasty (PTCA) to a single epicardial vessel underwent two scans with ^{99m}Tc-sestamibi myocardial perfusion single-photon emission computed tomography (SPECT). All subjects underwent at least three minutes of angiographically verified complete balloon occlusion, at which time an intravenous injection of the radiotracer was administered, followed by SPECT imaging. A second radiotracer injection followed by SPECT imaging was performed 24 hours after PTCA. **Results:** The study included 21 patients (median [interquartile range] age 70 [56-74] years, 48% female). The diameter stenosis ranged from 60-99%, with successful PTCA performed with a mean 5-minute balloon occlusion. The perfusion defect extent was 16 [8-30]% of the LV. The collateral perfusion at rest was 64 [58-68]% of normal perfusion. Collateral perfusion was negatively correlated with perfusion defect size (R^2=0.85, $p<0.001$), and did not differ by sex ($p=0.27$) or age ($p=0.58$). **Conclusions:** This is the first study to describe the magnitude of coronary microvascular collateral perfusion in patients with CAD. On average, despite coronary occlusion and an absence of angiographically visible collateral vessels, collaterals provide approximately 60% of the perfusion that reaches the jeopardized myocardium during coronary occlusion.

Introduction

The coronary collateral circulation is a preformed network of anastomotic connections between primitive vessels, linking one epicardial artery with another, acting as a "natural bypass" mechanism. The presence of robust coronary collateral circulation is known to be associated with improved survival and left ventricular function in the setting of ST-elevation myocardial infarction [1]. Whilst the prevalence of collaterals varies between species, approximately 25% of patients have angiographically visible robust collaterals at the time of ST elevation myocardial infarction [2]. In a previous study in patients with non-obstructive coronary artery disease (CAD), collateral flow during one minute of balloon occlusion was sufficient to prevent electrocardiographic evidence of ischemia in 17% of patients, and to prevent anginal symptoms in 26% of patients [3]. However, while the presence of collaterals is associated with improved outcomes, the magnitude of myocardial perfusion which can be provided by the collateral circulation remains uncertain. Importantly, collateral vessels smaller than approximately 100 μm are not visibly detectable by invasive angiography [4]. However, relative myocardial perfusion regardless of vessel size can be quantified by ^{99m}Tc-sestamibi single-photon emission computed tomography (SPECT). ^{99m}Tc-sestamibi uptake is linearly proportional to myocardial perfusion [5], and it exhibits minimal redistribution after initial uptake [6]. Therefore, the aim of the study was to quantify collateral myocardial perfusion during experimental coronary balloon occlusion in patients with CAD using ^{99m}Tc-sestamibi SPECT.

Methods

Study design

The current study was a retrospective substudy of a previously published larger cohort [7]. Patients without prior infarction, bypass surgery, or angiographically visible collaterals undergoing elective percutaneous transluminal coronary angioplasty (PTCA) to a single epicardial vessel, were prospectively selected to undergo two myocardial perfusion single-photon emission computed tomography (SPECT) scans between September 1995 and April 1996. The study was undertaken at Charleston Area Medical Center, Charleston, West Virginia, USA, approved by the local Investigational Review Board, and all subjects provided written informed consent.

SPECT Imaging

For each patient, when the angioplasty balloon was angiographically verified as being fully inflated during PTCA, with absence of anterograde blood flow, 1100 MBq (30 mCi) ^{99m}Tc-sestamibi was injected intravenously. The intracoronary balloon inflation lasted for at least three minutes in all patients, in order to maximize clearance of.^{99m}Tc-sestamibi from the bloodstream. Immediately following PTCA, the interventional cardiologist performing the procedure recorded the location of balloon occlusion, their observation of whether angiographically visible collateral circulation was considered to be present, and the duration of balloon inflation. Within three hours following angioplasty, the patient was brought to the nuclear medicine laboratory to acquire SPECT imaging data (Occlusion study). On the day following PTCA, a second intravenous injection with 1100 MBq of ^{99m}Tc-sestamibi was administered intravenously, followed by SPECT imaging within three hours (Control study). Each patient in the study was clinically stable throughout both processes.

SPECT imaging was performed using a single head gamma camera (Elscint, Haifa, Israel) that was set to peak with a 20% window. The images were acquired using a high-resolution collimator in a 64x64 matrix, 6.9 mm pixel size, using 30 projections (25 seconds/projection) over 180° from 45° right anterior oblique to 45° left posterior oblique. A filtered back projection with a Butterworth filter (order 5, cut-off 0.25 cycles/pixel) and without attenuation correction was used to reconstruct axial slices. The same gamma camera and image acquisition procedures were used for the occlusion and control studies.

Image Analysis

Short-axis images were reconstructed using the Cedars and Emory quantitative analysis (CEqual) program, and were used to build a volume-weighted bull's eye plots [8,9]. The quantification of collateral perfusion was performed by comparing the Occlusion study to the Control study for each patient. The Control study was first corrected by taking the decay of ^{99m}Tc into account. Following this process, the Occlusion study was scaled so that its average value, in the region above 90% of its maximum, was made equal to the average value of the control study in the same region of the heart. This normalization was necessary to achieve uniformity for the Control and Occlusion studies in regions not impacted by inflation-induced hypoperfusion.

The amount of residual perfusion downstream of the balloon-occluded artery, presumably due to coronary collateral flow, was quantified within the region of hypoperfusion in the following manner. First, the ratio of perfusion between the occlusion study and the control study was calculated. Secondly, the extent of the perfusion defect was identified in an extent map, and the region where the ratio of Occlusion-to-Control counts was less than 75% of maximum tracer

uptake was delineated, as previously validated [7]. Residual collateral perfusion was defined as Occlusion counts divided by Control counts, expressed in percent. A representative case is illustrated in Figure 1.

Statistical Analysis

All statistical analysis was performed using the software R (version 4.0.4, R Core Team, R Foundation for Statistical Computing, Vienna, Austria). Non-normally distributed data are presented as median [interquartile range]. Differences between groups were tested using the Wilcoxon test. Linear correlations were described using Pearson's correlation coefficient and expressed as its square (R^2). A p-value less than 0.05 was considered statistically significant.

Results

The study included 21 patients (age 70 [56-74] years, 10 (48%) female). The degree of diameter stenosis of treated vessels ranged from 60-99%, with successful PTCA performed with a mean balloon occlusion time of 5 minutes (range 3-7 minutes), resulting in ≤20% residual stenosis in all cases. Ten patients underwent stent implantation as part of the procedure. The vessels undergoing PTCA were 6 (28%) in the left anterior descending artery (LAD) [4 proximal, 2 distal], 5 (24%) in the left circumflex coronary artery [4 proximal, 1 distal] and 10 (48%) in the right coronary artery [8 proximal, 2 distal].

For the entire cohort, the size of the perfusion defect was 16 [8-30] % of the left ventricle, and the collateral perfusion at rest within the perfusion defect was 64 [58-68] % of normal (Control) perfusion within that region [Figure 2]. Collateral perfusion was negatively correlated with

perfusion defect size (R^2=0.85, p<0.001), but did not differ by sex (males 63 [55-67] vs females 65 [61-70] %, p=0.27) or age (R^2=0.01, p=0.58).

Discussion

The main finding of the study was that on average, despite coronary occlusion and an absence of angiographically visible collateral vessels, collaterals provide approximately 60% of the perfusion that reaches the jeopardized myocardium during coronary occlusion. This is the first study to describe the magnitude of microvascular collateral perfusion in CAD.

This magnitude of collateral perfusion is far greater than previously speculated. A previous study in young healthy dogs found that collateral-dependent myocardial perfusion in the setting of an occluded vessel was 6% of normal as quantified by fluorescent microspheres [10]. By comparison, the current study found roughly ten times greater collateral perfusion in patients with CAD, thus highlighting the large differences in collateral perfusion between different species, likely due to a combination of biological differences between species, age, and the presence of CAD. This surprising finding highlights the impressive magnitude of perfusion provided by collaterals in CAD in humans, despite not being visible at angiography.

The current study has shown that there is a strong negative correlation between perfusion defect size and the magnitude of collateral perfusion. In other words, smaller perfusion defects had greater collateral perfusion than larger perfusion defects. These results suggest that there is a limit to the distance over which collaterals can effectively perfuse into the core of a perfusion defect, and related to the extent of the perfusion defect.

The current study did not identify any differences in collateral perfusion due to sex or age. Healthy young females have been shown to have higher myocardial perfusion than males at rest and during hyperemic stress [11]. The exact cause of this sex difference in myocardial perfusion is not known, but it may be the consequence of either hormonally mediated vasomotor, and/or structural differences in capillary density between the sexes. However, the results of the current study show that these sex differences in myocardial perfusion in young healthy subjects do not translate to differences in collateral perfusion in patients with CAD that on average are in their sixth decade of life. This could potentially be explained by factors related to the pathophysiological changes inherent to CAD having a far stronger influence upon collateral perfusion than the mechanisms of normal biology that differ between the sexes. The current study further showed that collateral perfusion did not differ according to age. While it is known that the risk of CAD increases with age [12], the results of the current study suggests that these known age differences in presentation of CAD do not translate to differences in collateral perfusion. It may be that, similarly to the lack of sex differences in collateral perfusion, the differences induced by CAD dominate over any age-related difference.

While the magnitude of collateral perfusion has not previously been known, having robust coronary collateral circulation as visualized by invasive angiography has been associated with clinical benefits, since robust collaterals allow oxygenated blood to reach the jeopardized myocardium [1]. Patients with robust collaterals presenting with ST elevation myocardial infarction have a lower mortality in both the short and long term, and have a higher left ventricular ejection fraction [1]. Furthermore, patients with robust collaterals are more likely to

have successful percutaneous coronary intervention to treat chronic total occlusion [13]. Future studies on coronary collateral circulation could incorporate quantification of the myocardial perfusion contributed by collaterals using perfusion imaging methods such those used in the current study. This would be particularly applicable in chronic total occlusion, where perfusion imaging could quantify coronary collateral perfusion without the need for balloon inflation to reveal the magnitude of contribution that collaterals provide to myocardial perfusion.

Limitations

The study included 21 subjects, and this may be deemed a relatively small sample size that could potentially be seen as a limitation. However, the sample size was adequate to provide reliable data for a point estimate and variability for myocardial perfusion supplied to myocardium subtended by an occluded coronary artery. Uptake of ^{99m}Tc-sestamibi following balloon deflation could potentially falsely increase the estimation of collateral perfusion. However, it is known that approximately 8% of ^{99m}Tc-sestamibi remains in the blood stream at 5 minutes after intravenous injection [14]. The mean balloon injection time in our study was 5 minutes. Thus, when the balloon was deflated, residual ^{99m}Tc-sestamibi in the bloodstream could falsely increase our measured perfusion results by at most 8 percentage points. Taking this into account, this would mean that our results could reflect a true perfusion that was on average at least 56% of normal perfusion (64% minus 8%). Furthermore, contralateral vessel angiography was not performed during balloon inflation in this study. Thus, it is only known that collateral vessels could not be visualized prior to balloon occlusion, but it is not known if collateral vessels could be angiographically visualized during balloon occlusion, which otherwise would be the case for example in the assessment of chronic total coronary occlusion. Regardless, the angiographic

visualization of collateral vessels was performed under clinical conditions, and the current results highlight that angiographic visualization under clinical conditions does not visualize a sizable portion of perfusion that can reach myocardium subtended by a given artery should it become occluded.

In conclusion, this is the first study to describe the magnitude of microvascular collateral perfusion in CAD. On average, despite coronary occlusion and an absence of angiographically visible collateral vessels, collaterals provide approximately 60% of the perfusion that reaches the jeopardized myocardium during coronary occlusion. Future research on diagnosis and therapy in CAD should consider quantification of collateral perfusion beyond angiographic visualization.

References

1. Allahwala UK, Nour D, Alsanjari O, et al. Prognostic implications of the rapid recruitment of coronary collaterals during ST elevation myocardial infarction (STEMI): a meta-analysis of over 14,000 patients. J Thromb Thrombolysis. 2021;51(4):1005-1016.
2. Allahwala UK, Weaver JC, Nelson GI, et al. Effect of Recruitment of Acute Coronary Collaterals on In-Hospital Mortality and on Left Ventricular Function in Patients Presenting With ST Elevation Myocardial Infarction. Am J Cardiol. 2020 May 15;125(10):1455-1460.
3. Wustmann K, Zbinden S, Windecker S, et al. Is there functional collateral flow during vascular occlusion in angiographically normal coronary arteries? Circulation. 2003 May 6;107(17):2213-20.

4. Gensini GG, Bruto da Costa BC. The coronary collateral circulation in living man. *Am J Cardiol*. 1969;24(3):393-400.
5. Sinusas AJ, Trautman KA, Bergin JD, et al. Quantification of area at risk during coronary occlusion and degree of myocardial salvage after reperfusion with technetium-99m methoxyisobutyl isonitrile. *Circulation*. 1990;82(4):1424-1437.
6. Haronian HL, Remetz MS, Sinusas AJ, et al. Myocardial risk area defined by technetium-99m sestamibi imaging during percutaneous transluminal coronary angioplasty: comparison with coronary angiography. *J Am Coll Cardiol*. 1993;22(4):1033-1043.
7. Persson E, Palmer J, Pettersson J, et al. Quantification of myocardial hypoperfusion with 99m Tc-sestamibi in patients undergoing prolonged coronary artery balloon occlusion. Nucl Med Commun. 2002 Mar;23(3):219-28.
8. DePuey EG, Berman DS, Garcia EV. Cardiac SPECT imaging. New York: Raven Press, 1995: 63-74.
9. Garcia EV, Cooke CD, Van Train KF, et al. Technical aspects of myocardial SPECT imaging with technetium-99m sestamibi. *Am J Cardiol* 1990; 66: 23E-31E.
10. Ugander M, Bagi PS, Oki AJ, et al. Myocardial edema as detected by pre-contrast T1 and T2 CMR delineates area at risk associated with acute myocardial infarction. JACC Cardiovasc Imaging. 2012 Jun;5(6):596-603.
11. Nickander J, Themudo R, Sigfridsson A, et al. Females have higher myocardial perfusion, blood volume and extracellular volume compared to males - an adenosine stress cardiovascular magnetic resonance study. *Sci Rep*. 2020;10(1):10380.

12. Jousilahti P, Vartiainen E, Tuomilehto J, et al. Sex, age, cardiovascular risk factors, and coronary heart disease: a prospective follow-up study of 14 786 middle-aged men and women in Finland. *Circulation*. 1999;99(9):1165-1172.

13. Allahwala UK, Nour D, Bhatia K, et al. Prognostic impact of collaterals in patients with a coronary chronic total occlusion: A meta-analysis of over 3,000 patients. *Catheter Cardiovasc Interv*. 2021;97(6):E771-E777.

14. Cardiolite information sheet, retrieved on 8 July 2021. https://www.lantheus.com//assets/Cardiolite-US-PI-513121-0619mktg.pdf

Figures

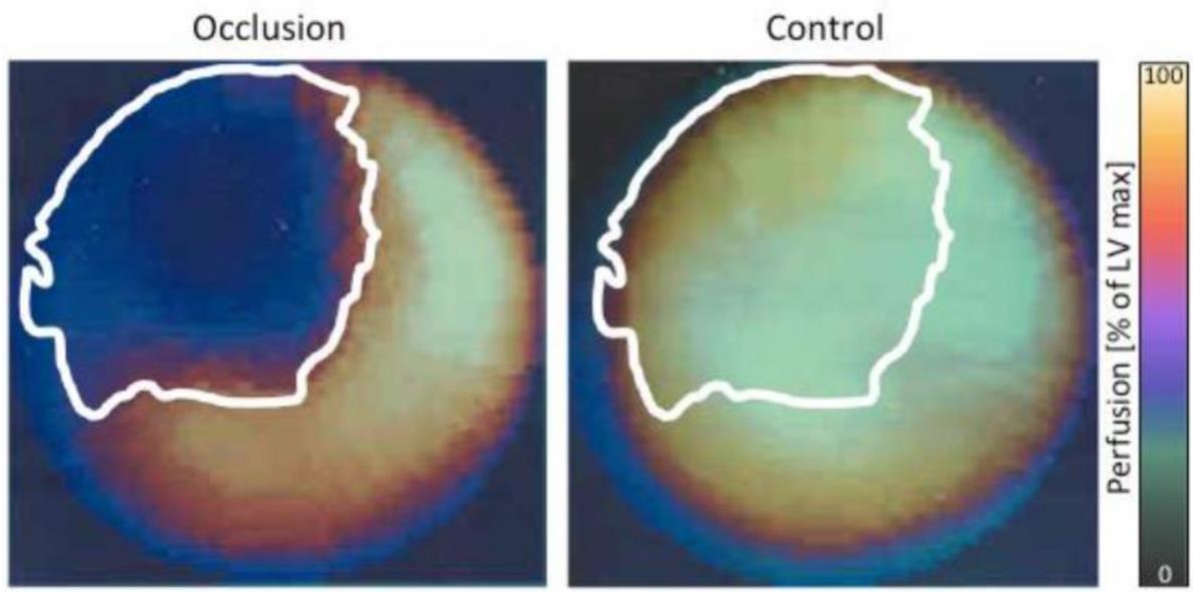

Figure 1. Collateral perfusion to myocardium during elective PTCA in patients with CAD. Bull's eye plots show left ventricular (LV) myocardial perfusion by ^{99m}Tc-sestamibi SPECT in a representative patient with a balloon-occluded left anterior descending artery (Occlusion) and 24 hours later at rest (Control). The size of the perfusion defect (white delineation) was defined as the region where the Occlusion/Control ratio was less than 75% as previously validated [4]. Collateral perfusion within the perfusion defect was quantified as Occlusion counts divided by Control counts, expressed in percent.

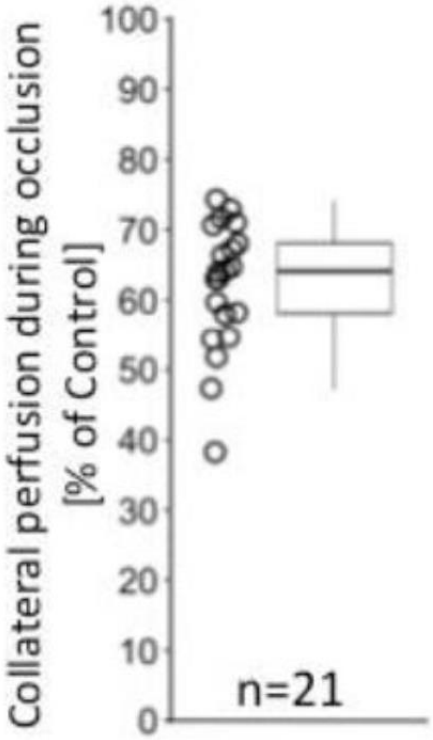

Figure 2. Box and whisker plot shows the collateral perfusion in all patients (n=21, median [interquartile range], 64 [58-68] %).