Vascular complexity and severity of diabetic retinopathy by using swept-source optical coherence tomographic angiography

Running title: Retinal geometry and DR severity

Authors: Jiahui Liu, MD, PhD[1#]*, Xia Gong, MD[2#], Xiong Kun, MD[2], Wei Wang, MD[2], Yuting Li, MPH[2], Xiaolin Liang, MD, PhD[2], Minyu Chen, MD, PhD[1], Wenyong Huang, MD, PhD[2]*

Affiliation and institute

1. Ophthalmology department, Affiliated Dongguan People's Hospital, Southern Medical University, Dongguan, China.
2. Zhongshan Ophthalmic Center, State Key Laboratory of Ophthalmology, Sun Yat-Sen University, Guangzhou, People's Republic of China.

#Co-first authors

Corresponding authors:

Wenyong Huang, MD&PhD, Zhongshan Ophthalmic Center, State Key Laboratory of Ophthalmology, Sun Yat-sen University, 54S.Xianlie Road, Guangzhou, China, Email: huangwenyong@gzzoc.com

Minyu Chen, MD&PhD, Ophthalmology department, Affiliated Dongguan People's Hospital, Southern Medical University, Dongguan, China, Email: chenminyu99@tom.com

Word count: 2450

Table: 4

Figure: 2

Abstract

Objectives: To evaluate the associations of retinal vascular complexity features with the severity of diabetic retinopathy (DR) by using non-invasive optical coherence tomographic angiography (OCTA).

Methods: This prospective cross-sectional study recruited ocular-treatment-naïve patients with type 2 diabetes mellitus registered in the community of Guangzhou, China. The OCTA was used to obtain the measurements of fractal dimension (FD) and blood vessel tortuosity (BVT) in superficial capillary plexus (SCP) and the deep capillary plexus (DCP). The univariate and multivariate linear regression was used to analyze the correlation of FD and BVT in different layers with DR severity.

Results: A total of 1282 patients (1282 eyes) were included, with a mean age of 64.2±7.8 years, 60.81% of male. The FD in DCP decreased and BVT in DCP increased in DR patients compared to non-DR patients, even after adjusting for confounding factors ($P< 0.05$). Trend analysis showed a significant decrease in FD values as DR progresses, while the BVT progressively increased with worsening DR severity ($P< 0.01$).

Conclusion: The FD and BVT determined using OCTA might be useful parameters for objectively distinguishing DR from non-DR, and indicating the DR progression.

Key words: fractal dimension; blood vessel tortuosity; diabetic retinopathy; OCTA

Introduction

The diabetic retinopathy (DR) is the leading causes of blindness in the working-age population around the world [1,2]. Patients with diabetes mellitus (DM) are usually symptomless until the advanced stages of DR, leading to a poor visual prognosis after treatment. Thus, early detection and prompt treatment of DR play a pivotal role in protecting from vision impairment. Although the exact pathogenesis of DR remains unclear, it is universally acknowledged that damage of retinal microvasculature, especially in the macula, might contribute to the occurrence and development of DR [3,4]. The capillary drop-out has been reported to precede proliferative disease [5]. However, there are no available clinically quantitative parameters to identity the degree of microvascular damage, especially in the early stage of DR.

As optical coherence tomography angiography (OCTA) become more widely available, detailed microvascular networks can now be quantified conveniently and noninvasively with high resolution. With OCTA, some abnormal changes of the retinal capillary network in DM patient without DR have been recognized, demonstrating that OCTA metrics could be early indicators of subtle, subclinical alterations in DM before the first clinically observable signs of DR [6-8]. Fractal dimension (FD) and blood vessel tortuosity (BVT) have been used for evaluation of overall structural and geometric complexity of retinal vasculatures. Recent studies revealed that FD and BVT were altered in DR and therefore as DR biomarker candidates [2,9-11]. The objective of this study was to assess the FD and BVT to identify localized complexity distortions across various stages of DR by using OCTA in a large sample of Chinese patients with DM.

Method

Participants

This prospective cross-sectional study was performed in the Zhongshan Ophthalmic Centre, which is affiliated with Sun Yat-sen University, Guangzhou, China. The Medical Ethics Committee of the Zhongshan Ophthalmic Centre approved the study

(2017KYPJ094). All research conducted adhered to the tenets of the Declaration of Helsinki. Written informed consent was obtained from all subjects.

Subjects in the study were enrolled from November 01, 2017 to December 30, 2020 in the community of Guangzhou, China. Patients aged 35–80 years with type 2 diabetes and without any history of eye treatments or surgeries (including retinal laser, intraocular injection, vitrectomy, cataract extraction, scleral buckle, and glaucoma surgery) were included in this study. Eyes with other significant ocular pathology (including hypertensive retinopathy, retinal vascular occlusions, and uveitis) were excluded from the study. Other exclusion criteria included history of systemic diseases, except for diabetes, such as malignant tumors, ischemic heart disease, stroke, cancer, or kidney disease; a history of heart bypass, thrombolysis, or kidney transplantation; cognitive impairments or mental illnesses that made them unable to complete questionnaires or cooperate with examiner. They were also excluded if they had spherical equivalent (SE) < − 9.0 D, astigmatism > + 4.0 D, axial length (AL) > 26.0 mm, or a best corrected visual acuity (BCVA) of less than 20/200.

General and laboratory parameters

The demographic and systemic information, including age, gender, duration of diabetes, and medical history, were obtained using standardised questionnaires and the information was confirmed after further inspection of outpatient history. The height, weight, systolic blood pressure (SBP), and diastolic blood pressure (DBP) were measured using standardised processes. The haemoglobin A1c (HbA1c), total cholesterol and triglyceride were determined in a laboratory certified by the Chinese government.

Ocular examination

Each participant underwent a full clinical examination including slit-lamp bioscopy, ophthalmoscopy, intraocular pressure (IOP), visual acuity, refraction, ocular biometry, retinal photography, and OCTA imaging. Ocular biometric parameters were measured

with a Lenstar LS900 (Haag-Streit AG, Koeniz, Switzerland), including AL, corneal curvature, lens thickness and anterior chamber depth. Pupil dilation was performed with instillation of 0.5% tropicamide plus 0.5% phenylephrine in eye drops. Once pupils were fully dilated, standardised 7-field colour retinal photographs adhering to Early Treatment of Diabetic Retinopathy Study (ETDRS) protocol were taken, using a digital fundus camera (Canon CR-2, Tokyo, Japan). The clinician retinopathy severity grading guided the recruitment goals, but a masked grading of the color photographs assigned eyes into no retinopathy, mild, moderate, and severe DR groups for final analysis by two trained ophthalmologists and further confirmed by a senior retina specialist if there is disagreement about the grade [12].

OCTA imaging and measurements

A commercial swept-source OCTA instrument (DRI OCT-2 Triton; Topcon, Tokyo, Japan) was used for retinal microvasculature imaging, which had a central wavelength of 1050 nm with an axial resolution of 8 µm, a transverse resolution of 20 µm, and a speed of 100,000 A-scans per second. We used 3mm X 3mm scans that provided a more detailed description of the fovea and its contour. Automated segmentation and image exportation generated an SS-OCTA image of the superficial capillary plexus (SCP) and the deep capillary plexus (DCP). One eye from each patient were included. All OCTA images were acquired by a well-trained examiner with no knowledge of the study protocol. Image quality of each scan was automatically graded by the built-in software, with a quality index ranging from 0 to 100 [13].

We measured two complexity quantitative features, FD and BVT through OCTA images. OCTA images were standardized, cropped, and binarized using Fiji (free downloadable software, https://fiji.sc) [14]. Before measuring the OCTA features, a binary vessel map and skeleton map were extracted from the input images. FD can quantify the degree of branching complexity (i.e., blood vessels). In our study, the box counting technique was used to measure the FD values in both SCP and DCP. The FD analysis procedure has been described in a previous study [15]. The average BVT

was measured as the ratio of sum of actual branch lengths to sum of straight lengths between branch nodes [16]. The FD and BVT were measured using segmented branches within the skeleton map in the SCP and DCP (Figure 1). As FD and BVT value is too small, we enlarge their value by 1000 times for statistical analysis.

Figure 1. Illustration of FD and BVT measurements in superficial capillary plexus (SCP) and deep capillary plexus (DCP) by OCTA. Column 1: OCTA image. Column 2: Segmented blood vessel map including large blood vessels and small capillaries. Column 3: Skeletonized blood vessel map. Column 4: Image from column 3 magnified by a thousand times.

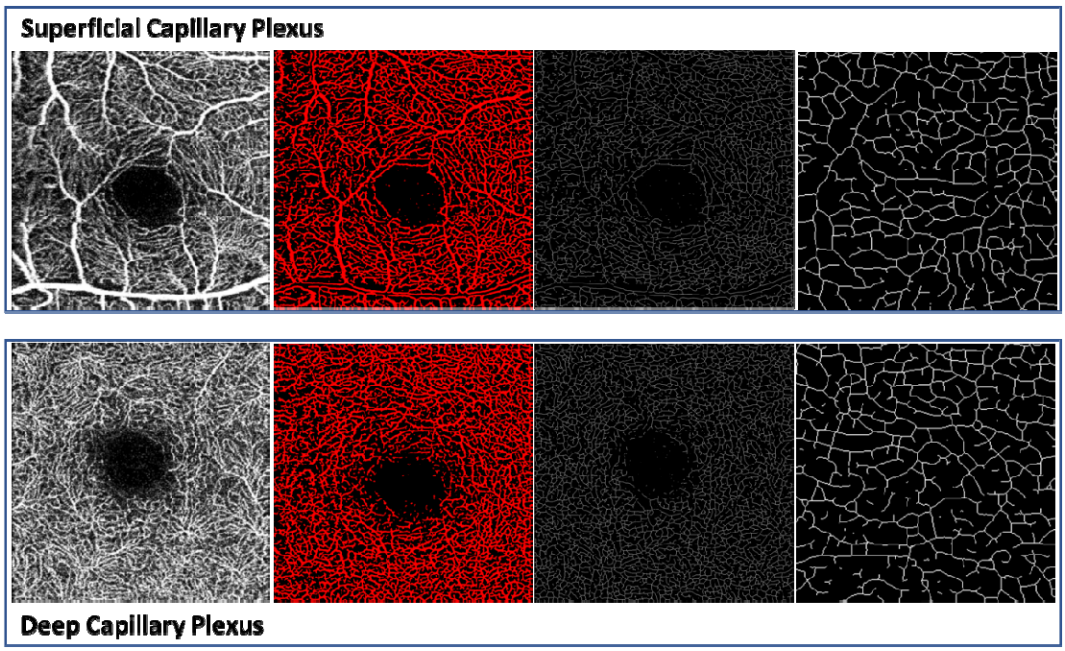

Statistical analysis

The Shapiro-Wilk test was used to verify the normal distribution, and analysis of variance was performed to compare differences in demographic, systemic, and ocular parameters among groups with different stages of DR. The categorical variables were analyzed by $\chi 2$. Univariate and multivariate linear regressions were used to compare FD and BVT in both SCP and DCP between the control group and various stages of DR group. Model 1 of the multivariable linear regression was

adjusted for age, gender and OCTA signal strength intensity. Model 2 was performed by adjusting for more confounding factors including age, gender, systolic blood pressure, diastolic blood pressure, HbA1c, serum creatinine, blood cholesterol, triglycerides, axial length, and OCTA signal strength intensity. All analyses were performed using Stata Version 16.0 (Stata Corporation, College Station, TX, USA). A P-value < 0.05 was considered statistically significant.

Results

Characteristics of Included Participants

A total of 1282 eyes from 1282 subjects were included in the study. Demographic and clinical characteristics of study participants are shown in Table 1. Among them, 756 (58.97%) patients were male, with a mean age of 64.2 ± 7.8 years. Of the 1059 patients without DR, 644(60.81%) were male, with a mean age of 64.3 ± 7.5 years. Of the 54 patients with mild DR, 30(55.56%) were male, with a mean age of 62.8 ± 6.9 years. Of the 133 patients with moderate DR, 64(48.12%) were male, with a mean age of 63.8 ± 9.3 years. Of the 36 patients with severe DR, 18(50%) were male, with a mean age of 62.1 ± 8.8 years. The parameters relating to the gender, SBP, HbA1c, Serum creatinine and OCTA macular signal strength intensity differed among the groups (P < 0.05). No statistically significant differences were present with respect to the other parameters.

Table 1. Demographics and clinical characteristics of study patients

Characteristics	ALL	Non- DR	Mild DR	Moderate DR	Severe DR	p Value
No. of subjects	1282	1059	54	133	36	
Male (%)	756(58.97%)	644(60.81%)	30(55.56%)	64(48.12%)	18(50%)	0.024
Mean age, year	64.2± 7.8	64.3± 7.5	62.8± 6.9	63.8± 9.3	62.1± 8.8	0.1822
Systolic blood pressure, mm Hg	135.5± 19.0	134.9± 18.8	133.3± 16.0	138.8± 19.3	145.3± 24.2	0.0015
Diastolic blood pressure, mm Hg	70.9± 10.3	71.1± 10.1	70.9± 12.0	69.0± 10.1	70.8± 12.7	0.1614
HbA1c, %	7.0± 1.5	6.8± 1.3	7.9± 1.9	7.9± 1.7	8.6± 1.8	< 0.001
Triglycerides, mmol/L	2.3± 1.6	2.3± 1.6	2.2± 1.6	2.3± 1.9	2.2± 1.3	0.9185
Total cholesterol, mmol/L	4.8± 1.0	4.9± 1.0	4.8± 1.1	4.8± 1.1	4.9± 1.1	0.6906
Serum creatinine, μmol/L	70.9± 21.1	69.3± 19.1	72.6± 23.7	79.4± 28.9	82.3± 28.0	< 0.001
Axial length, mm	23.4± 0.9	23.4± 0.9	23.2± 0.9	23.2± 0.8	23.2± 0.9	0.1356
OCTA signal strength intensity	59.2± 11.5	60.0± 11.1	59.5± 12.3	55.7± 12.3	49.5± 14.1	< 0.001

Distribution of FD and BVT by DR severity

A summary of the average and detailed univariate analysis of FD and BVT in SCP and DCP among control group and different stages of the DR groups is showed in Table 2 and Figure 2.

Figure 2. Boxplots showing the distribution of FD and BVT in superficial retinal layer (SRL) and the deep retinal layer (DRL) by swept-source optical coherence tomographic angiography stratified by various stage of DR.

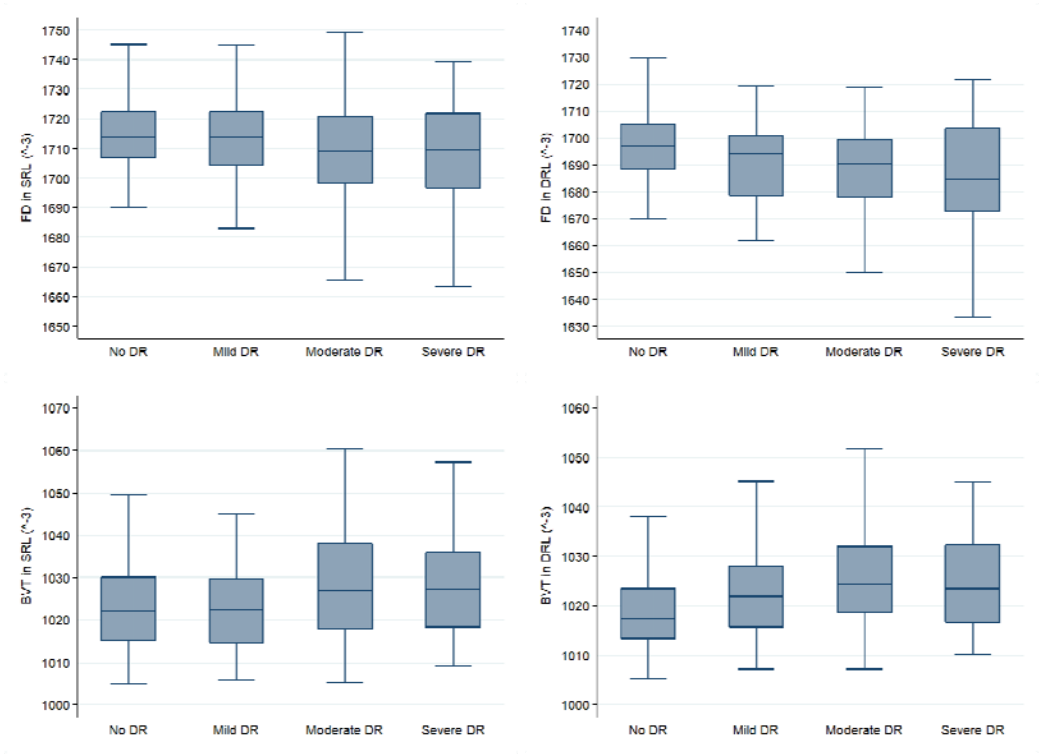

A post-hoc study after the ANOVA showed that all the features were able to distinguish controls versus moderate DR patients ($P< 0.001$) and controls versus severe DR patients ($P< 0.05$), none of the features showed statistically significant differences between moderate DR eyes and severe DR eyes. Comparison of FD and BVT in DCP between Non-DR patients and mild DR patients showed significant difference ($P< 0.05$). Furthermore, there was a significant rise in BVT both in SCP and in DCP of mild DR eyes compared with moderate DR eyes ($P \leq 0.01$). Only FD in SCP

were able to distinguish between mild DR group and severe DR group (P=0.038). The FD in DCP was higher in non-DR eyes compared with each stage of DR eyes (P ≤ 0.001), but it showed no significant difference among different stages of DR. Consequently, we considered that FD in DCP was an important feature to differentiate DR and Non-DR.

Table 2. Comparisons of FD and BVT in different stages of diabetic retinopathy.

Features	Non- DR (I)	Mild DR (II)	Moderate DR (III)	Severe DR (IV)	I vs. II	I vs. III	I vs. IV	II vs. III	II vs. IV	III vs. IV	ANOVA
FD(SCP)	1714.98±1.97	1714.24±15.00	1709.50±18.59	1706.33±24.30	1	< 0.001	0.001	0.179	0.038	1	< 0.001
FD(DCP)	1697.15±12.37	1689.91±20.28	1687.09±17.89	1682.73±25.76	0.001	< 0.001	< 0.001	1	0.102	0.582	< 0.001
BVT(SCP)	1023.32±10.08	1022.52±10.24	1028.14±13.82	1028.46±13.71	1	< 0.001	0.027	0.007	0.06	1	< 0.001
BVT(DCP)	1018.94±7.27	1022.27±8.81	1026.33±11.06	1026.25±12.71	0.017	< 0.001	< 0.001	0.01	0.126	1	< 0.001

Association between Vascular Complexity and Diabetic Retinopathy

A univariate linear regression analysis was performed to observe relationship between FD in DCP and other OCTA features (Table 3). FD in DCP had a statistically significant positive correlation with FD in SCP and a negative correlation with BVT in SCP and BVT in DCP in all of the participants, Non-DR group, moderate DR group and severe DR group (P< 0.01). Only BVT in DCP showed a negative trend with FD in DCP in mild DR eyes (P< 0.001).

Table 3. Univariate linear regression analysis of the relationship between features of vascular complexity and FD in DCP.

Features	ALL		Non- DR (I)		Mild DR (II)		Moderate DR (III)		Severe DR (IV)	
	Coefficient (95%CI)	P value	Coefficient (95%CI)	P value	Coefficient (95%CI)	P value	Coefficient (95%CI)	P value	Coefficient (95%CI)	P value
FD(SCP)	0.359 (0.312, 0.406)	< 0.001	0.314 (0.259, 0.370)	< 0.001	0.173(-0.276, 0.373)	0.089	0.382 (0.215, 0.549)	< 0.001	0.673 (0.442, 0.903)	< 0.001
BVT(SCP)	-0.156 (-0.196, -0.116)	< 0.001	-0.117 (-0.166, -0.682)	< 0.001	-0.005 (-0.146, 0.136)	0.941	-0.239 (-0.366, -0.112)	0.0003	-0.239 (-0.405, -0.730)	0.006
BVT(DCP)	-0.281 (-0.308, -0.252)	< 0.001	-0.244 (-0.276, -0.212)	< 0.001	-0.278 (-0.371, -0.186)	< 0.001	-0.273 (-0.372, -0.174)	< 0.001	-0.255 (-0.402, -0.109)	0.001

To reduce the factors known to be relevant to OCTA features, we performed two multivariate linear regression analysis to compare FD and BVT in both SCP and DCP between the control group and various stages of DR group, which was adjusted for confounding factors. Both results of the two models were consistent with the univariate analysis in table 2, but nearly all the differences between groups were more significant.

Table 4. Multivariable linear regression of OCTA parameters in non-DR eyes compared with various stages of DR eyes after adjusting confounding factors. Model 1 was adjusted for age, gender and OCTA signal strength intensity. Model 2 was further adjusted for confounding factors including age, gender, systolic blood pressure, diastolic blood pressure, HbA1c, serum creatinine, blood cholesterol, triglycerides, axial length, and OCTA signal strength intensity.

Features	Non- DR vs. Mild DR		Non- DR vs. Moderate DR		Non- DR vs. Severe DR	
	Coefficient (95%CI)	P value	Coefficient (95%CI)	P value	Coefficient (95%CI)	P value
Model 1						
FD(SCP)	- 0.43(- 3.59, 3.09)	0.81	- 6.72(- 9.05, - 4.40)	< 0.001	- 13.63(- 17.98, - 9.27)	< 0.001
FD(DCP)	- 7.96(- 11.91, - 4.01)	< 0.001	- 10.19(- 12.79, - 7.59)	< 0.001	- 16.26(- 21.15, - 11.37)	< 0.001
BVT(SCP)	- 1.01(- 4.04, 2.03)	0.516	4.65(2.65, 6.64)	< 0.001	6.48(2.72, 10.24)	0.001
BVT(DCP)	3.58(1.29, 5.86)	0.002	7.06(5.55, 8.57)	< 0.001	7.90(5.08, 10.73)	< 0.001
Model 2						
FD(SCP)	- 0.89(- 4.49, 2.72)	0.63	- 6.72(- 9.15, - 4.28)	< 0.001	- 13.74(- 18.31, - 9.17)	< 0.001
FD(DCP)	- 6.75(- 10.72, - 2.78)	0.001	- 8.93(- 11.62, - 6.25)	< 0.001	- 13.37(- 18.40, - 8.34)	< 0.001
BVT(SCP)	- 0.61(- 3.71, 2.49)	0.7	4.62(2.53, 6.72)	< 0.001	6.63(2.70, 10.55)	0.001
BVT(DCP)	3.55(1.23, 5.87)	0.003	6.66(5.09, 8.23)	< 0.001	7.43(4.49, 10.37)	< 0.001

Discussion

This OCTA study based on a large sample demonstrated that FD in DCP decreased and BVT in DCP increased in various grades of DR patients compared to non-DR, the differences are more significant especially adjusting for potential confounding factors. In addition, our results showed that FD in DCP positively correlated with FD in SCP and negatively correlated with BVT in SCP and BVT in DCP in all groups except mild DR group. The findings confirmed a close relationship between the alterations of retinal microcirculation particularly in DCP and the pathophysiology of DR. To the best of our knowledge, this study is the first to use SS-OCTA to investigate association of vascular complexity features and different stages of DR in patients with diabetes from communities in China.

Fractal analysis has been employed as a useful tool to study the retinal vascular pattern and measuring the complexity of retinal vasculature branching. As DR develops, the high rate of vascular dropouts results in lower vessel density, which represented by a lower average number of FD values [9]. Chen et al reported that the value of FD in the four quadrant sectors of the deep retinal capillary layer were lower

in diabetic patients with minimal DR compared to those with no DR and FD in the deep retinal capillary layer were extremely lower in DM eyes without DR compared with the nondiabetic control subjects [17]. Suruchi et al showed FD both in the superficial and deep capillary plexus for diabetic eyes was significantly lower than in control eyes [10]. Consistent with previous studies, our findings illustrated that retinal vascular FD in both SCP and DCP showed a significant reduction in DR patients. Moreover, the superiority of our research was that we adjusted for a large number of confounding factors associated with vascular complexity. However, no statistically significant changes were appreciated in FD at both superficial and deep vascular networks among different stages of DR, apart from FD at SCP in severe DR group compared with moderate DR group. These results suggested that FD in DCP, could be an important indicator that distinguishes DR from Non-DR, indicating that the early changes of retinal capillaries associated with DR may first occur in the deep retinal capillary layer before the superficial plexus.

There was no significant difference in FD of the superficial capillary plexus when comparing mild DR and non-DR, suggesting that the superficial capillary plexus may be damaged until DR progresses to a greater degree. This is further supported by our analysis of BVT which did not yield a significant difference in the superficial capillary plexus between control eyes and mild DR eyes. Similar to the FD in DCP, the BVT in DCP in non-DR was lowest than any other stages of DR even by adjusting for all known covariates. This result is consistent with a previous study by Minhaj et al [9]. Consequently, BVT in DCP could be used for non-DR vs. DR classification. Retinal vessel tortuosity has been considered as a characteristic of hemodynamic changes and grading of DR [18-20]. Dysfunction of endothelium and pericytes induces unstable vessel wall, which could easily become tortuous [21,22]. The neovascularization often occurred in DR patients also lead to increase of BVT [20]. However, both FD and BVT in DCP does not distinguish between different severity of DR, which was inconsistent with Suruchi's [10] and Hyungwoo's research [16]. It may due to the small sample size of the enrolled DR populations or heterogenous study

populations.

As FD in DCP plays a vital role in diagnosis and risk assessment of DR, we performed univariate linear regression analysis between FD in DCP with other OCTA features. Few studies have analysed the association between FD and BVT. It was shown in our correlation analysis that the negative associations of FD in DCP with both BVT in SCP and DCP are plausible, because all these parameters are related to the abnormal vascular architecture with DR progression. With DR progresses, avascular regions are assigned with small FD values and interrupted blood flow results in short branches. The short capillaries are prone to become tortuous rather than long branches. The cerebral microvascular meshwork demonstrated that vessels nearer to the capillary network have higher tortuosity and more curvature [23], which supporting our deduction. Further studies are needed to estimate the cause of high tortuosity by short branch.

The advantage of our study is all participants were treatment-naïve patients with type 2 DM from a single Chinese community, consisting a homogenous and large-scale cohort. In addition, several potential confounding factors were put into consideration for adjustment to make our results more accurate and reliable. There are also some limitations in this study. Firstly, our observation is only in very small areas of the retina because the 3 × 3 mm area showed more clearly demarcated vessels, ensuring the more precise binarization of vessels, and subsequently, the more accurate quantification of parameters. Larger scan area would be performed to quantity OCTA features in more region of retina. Secondly, projection and motion artifacts in OCTA and blood flow velocity below the threshold value can affect quantitative feature analysis. We strictly control the image quality by a quality index. Thirdly, we did not have enough patients of each stage of DR, due to the participants in our study recruited from communities. Further work is warranted on a larger sample size of DR patients. Finally, this study as a cross-sectional study, cannot illustrate the cause-effect relationship between vascular alterations and DR

occurrence and development. Longitudinal studies are required in the future.

Conclusions

In summary, we found that FD and BVT in DCP by OCTA imaging may be new quantitative biomarkers in the diagnosis and risk assessment of DR. Future studies are necessary to determine whether intensive investigations of retinal vascular geometry can benefit patients and improve clinical decision-making in the risk evaluation and management of DR.

Acknowledgements/Disclosures

A. Funding / Support: This research was supported by the National Natural Science Foundation of China (82000901), the Fundamental Research Funds of the State Key Laboratory of Ophthalmology (303060202400362).

B. Financial Disclosures: None.

C. Contributions to Authors in each of these areas: Design and conduct of the study (MC, WH); Collection, management, analysis and interpretation of the data (all authors); Preparation of the manuscript (JL,XG, WH); Review and final approval of the manuscript (all authors).

D. Other Acknowledgements: The authors thank all the participants and staff in the ZOC preventive department.

References:

[1] Wong TY, Cheung CM, Larsen M et al (2016) Diabetic retinopathy. Nat Rev Dis Primers 2:16012

[2] Alam M, Zhang Y, Lim JI, et al. Quantitative optical coherence tomography angiography features for objective classification and staging of diabetic retinopathy. Retina 2020;40:322–332

[3] Stitt AW, Curtis TM, Chen M et al (2016) The progress in understanding and treatment of diabetic retinopathy. Prog Retin Eye Res 51:156–186

[4] Cheung CY, Ikram MK, Klein Ret al. (2015) The clinical implications of recent studies on the structure and function of the retinal microvasculature in diabetes. Diabetologia 58(5):871–885

[5] Golubovic-Arsovska M. Correlation of diabetic maculopathy and level of diabetic retinopathy. Prilozi 2006;27: 139–150.

[6] Hwang TS, Zhang M, Bhavsar K, et al. Visualization of 3 distinct retinal plexuses by Projection-Resolved optical coherence tomography angiography in diabetic retinopathy. JAMA Ophthalmol 2016;134:1411–9.

[7] Hwang TS, Gao SS, Liu L, et al. Automated quantification of capillary nonperfusion using optical coherence tomography angiography in diabetic retinopathy. JAMA Ophthalmol 2016;134:367–73.

[8] Rosen RB, Andrade Romo JS, Krawitz BD, et al. Earliest evidence of preclinical diabetic retinopathy revealed using optical coherence tomography angiography perfused capillary density. Am J Ophthalmol 2019; 203:103–15.

[9] Alam M, Le D, Lim JI, Yao X. VASCULAR COMPLEXITY ANALYSIS IN OPTICAL COHERENCE TOMOGRAPHY ANGIOGRAPHY OF DIABETIC RETINOPATHY. Retina. 2021 Mar 1;41(3):538-545.

[10] Bhardwaj S, Tsui E, Zahid S, Young E, Mehta N, Agemy S, Garcia P, Rosen RB, Young JA. Value of fractal analysis of optical coherence tomography angiography in various stages of diabetic retinopathy. Retina. 2018 Sep;38(9):1816-1823.

[11] Ting DSW, Tan GSW, Agrawal R, et al. Optical coherence tomographic angiography in type 2 diabetes and diabetic retinopathy. JAMA Ophthalmol.

2017; 135:306–312.

[12] Wilkinson CP, Ferris FL, Klein RE, et al. Proposed International clinical diabetic retinopathy and diabetic macular edema disease severity scales. Ophthalmology 2003; 110:1677–82.

[13] Tang F, Sun Z, Wong R, et al. Relationship of intercapillary area with visual acuity in diabetes mellitus: an optical coherence tomography angiography study. Br J Ophthalmol 2018. doi:10.1136/bjophthalmol-2018-312010. [Epub ahead of print: 04 Jun 2018].

[14] Schindelin J, Arganda-Carreras I, Frise E, et al. Fiji: an opensource platform for biological-image analysis. Nat Methods 2012; 9:676–682

[15] Alam M, Thapa D, Lim JI, et al. Quantitative characteristics of sickle cell retinopathy in optical coherence tomography angiography. Biomed Opt Express 2017; 8:1741–1753.

[16] Lee H, Lee M, Chung H, Kim HC. Quantification of retinal vessel tortuosity in diabetic retinopathy using optical coherence tomography angiography. Retina. 2018 May;38(5):976-985.

[17] Chen Q, Ma Q, Wu C, Tan F, Chen F, Wu Q, Zhou R, Zhuang X, Lu F, Qu J, Shen M. Macular Vascular Fractal Dimension in the Deep Capillary Layer as an Early Indicator of Microvascular Loss for Retinopathy in Type 2 Diabetic Patients. Invest Ophthalmol Vis Sci. 2017 Jul 1;58(9):3785-3794.

[18] Kristinsson JK, Gottfredsdottir MS, Stefansson E. Retinal vessel dilatation and elongation precedes diabetic macular oedema. Br J Ophthalmol 1997; 81:274–278

[19] Witt N, Wong TY, Hughes AD, et al. Abnormalities of retinal microvascular structure and risk of mortality from ischemic heart disease and stroke. Hypertension 2006; 47:975–981

[20] Hartnett ME, Martiniuk D, Byfield G, et al. Neutralizing VEGF decreases tortuosity and alters endothelial cell division orientation in arterioles and veins in a rat model of ROP: relevance to plus disease. Invest Ophthalmol Vis Sci 2008; 49:3107–3114.

[21] Curtis TM, Gardiner TA, Stitt AW. Microvascular lesions of diabetic retinopathy: clues towards understanding pathogenesis? Eye (Lond) 2009; 23:1496–1508

[22] Dobrin PB, Schwarcz TH, Baker WH. Mechanisms of arterial and aneurysmal tortuosity. Surgery 1988; 104:568–571

[23] Lorthois S, Lauwers F, Cassot F. Tortuosity and other vessel attributes for arterioles and venules of the human cerebral cortex. Microvasc Res 2014; 91:99–109.