medRxiv preprint doi: https://doi.org/10.1101/2021.07.23.21260716; this version posted September 21, 2021. The copyright holder for this preprint (which was not certified by peer review) is the author/funder, who has granted medRxiv a license to display the preprint in perpetuity.

It is made available under a CC-BY-ND 4.0 International license .

COVID-19 Associated Hepatitis in Children (CAH-C) during the second wave of SARS-CoV-2 infections in Central India: Is it a complication or transient phenomenon.

Sumit Kumar Rawat MD[1*], Ajit Anand Asati MD[1], Ashish Jain MD[1], Dr Nitu Mishra MDS[1], R K Ratho MD[2]

1. Bundelkhand Govt. Medical College Sagar, Madhya Pradesh, India.
2. Post Graduate Institute of Medical Education and Research, Chandigarh, India

Grant support: NA

Key words: Hepatitis, COVID-19, SARS-CoV-2, Pediatric, MIS-C.

Abstract

Background: While pediatric population has largely remained free of severe COVID-19 disease with most infected children being asymptomatic or presenting with mild symptoms, in some cases SARS-CoV-2 infection has been associated with Multiple Inflammatory Syndrome in children (MIS-C). We mention another unique presentation observed in children subsequent to asymptomatic infection of SARS-CoV-2, a transient form of hepatitis during the second wave of COVID-19 and designated as COVID-19 Associated Hepatitis in Children (CAH-C). The clinical presentations, temporal association and viral parameters of the cases of CAH-C contrasting to MIS-C hepatitis are presented here. **Methods**: As a retrospective and follow-up observational study we reviewed all pediatric patients presenting to our hospital with acute hepatitis. There were increased number of cases of hepatitis in pediatric age group during the second wave of SARS CoV-2 infections, where children or adolescents developing sudden onset acute hepatitis with temporal relation to SAR-CoV-2 infection and without prior liver disease or familiar etiology of acute hepatitis are being described. **Results**: Among 47 pediatric patients presented with hepatitis, 37 patients had features of CAH-C, they had symptoms of hepatitis only, with majority having unelevated inflammatory markers and uneventful recovery following supportive treatment. Whereas remaining 10 MIS-C hepatitis were observed with protracted illness, multiple system involvement, required

NOTE: This preprint reports new research that has not been certified by peer review and should not be used to guide clinical practice.

medRxiv preprint doi: https://doi.org/10.1101/2021.07.23.21260716; this version posted September 21, 2021. The copyright holder for this preprint (which was not certified by peer review) is the author/funder, who has granted medRxiv a license to display the preprint in perpetuity.

It is made available under a CC-BY-ND 4.0 International license .

admission to critical care, and had mortality of 3/10 (30%). **Conclusion:** With the emergence of newer variants of concern (VOC) including the Delta variant which has now spread to more than 60 countries and was responsible for the massive wave of COVID-19 across India, with changing presentations, CAH-C might be one of them. Such new entities need to be identified and differentiated from other emerging syndromes in children for a timely and appropriate management.

Introduction:

Severe acute respiratory syndrome coronavirus 2 (SARS-CoV-2), the begetter of ongoing pandemic, was first identified in China in December 2019, with its subsequent epicenters being recognized in Western countries, thereafter reaching India during the first wave (1). Initial reports of SARS-CoV-2 infection interestingly indicated that young children were disproportionately spared from severe illness, with predominance of asymptomatic or mild cases without a need for hospital admission (2). Later a novel "multisystem inflammatory syndrome in children" (MIS-C) linked to SARS-CoV-2 infection surfaced out (3).

First reports of MIS-C were observed in children and adolescents in April 2020, in UK (4) with features of (5); "Serious illness leading to hospitalization, an age of less than 21 years, fever (body temperature, >38.0°C) or report of subjective fever lasting at least 24 hours, laboratory evidence of inflammation, multi organ involvement (i.e., at least two systems), and laboratory-confirmed SARS-CoV-2 infection (positive SARS-CoV-2 real-time reverse-transcriptase polymerase chain reaction [RT-PCR] or antibody test during hospitalization) or an epidemiologic link with a COVID-19" patient according to the Centers for Disease Control and Prevention (CDC) (6).
The first wave of the SARS-CoV-2 pandemic persisted till November 2020 causing a large number of infections across India, sparing serious disease in children, similar to the observation from west (8). However, in April 2021 the massive second wave of COVID-19 in India with an unimagined size and consequences, there were cases involving children with severe illnesses (9). Newer variants of concern (VOC) including the delta (B.1.617.2) variant which spread to more than 60 countries, was largely

medRxiv preprint doi: https://doi.org/10.1101/2021.07.23.21260716; this version posted September 21, 2021. The copyright holder for this preprint (which was not certified by peer review) is the author/funder, who has granted medRxiv a license to display the preprint in perpetuity.

It is made available under a CC-BY-ND 4.0 International license .

responsible for this massive upsurge in COVID-19 cases in India (10). Because of these newer variants, disease presentations varied from respiratory system to newer entities like MIS-C, encephalitis, and hepatitis in children (11, 12). Although initial reports did not mention much about hepatitis as a one of the features of MIS-C, it was recognized in the later part of the year 2020. It has been observed in a subset of obese children with MIS-C, that severe disease and adverse outcomes were associated with co-existing hepatitis, similar to the findings observed among adults with COVID-19. However, about 60% of children with MIS-C presented with hepatitis in contrast to only 20-30% adult cases following COVID 19 (13).

These findings indicate that age-related differences might exist in cases of hepatitis associated with COVID-19, potentiating the need for age-specific management. If we look at patterns of liver injury in children, two patterns have been observed with SARS-CoV-2 infection till date. The former, milder disease phenotype is seen during active COVID-19 infection without admission requirements and the latter with more severity seen in cases with MIS-C often associated with shock, respiratory distress, chances of multi-organ failure and prolonged need for hospital admission (14). At least four different mechanisms of liver injury occurring in cases of COVID-19 have been reported with many possible different presenting phenotypes (15). In the current context of emerging VOC like the delta variant, the effects of liver injury and the dominant hepatic phenotype on outcomes in children with COVID-19. There is a strong possibility that different hepatic phenotypes of liver injury and the associated complications might be caused by differences in the circulating variant causing COVID-19 and its interplay with host immune responses. Such differences also dictate varying management strategies, preventing overburden on resources thus improving outcomes and preventing adversities(14).

During the ongoing second wave of SARS-CoV-2 infections along with a small proportion of children presenting with MIS-C, other presentations like respiratory distress, shock, encephalitis-like features and sudden rise in cases of hepatitis among children was noticed. These features of hepatitis were typically found among previously asymptomatic children beyond 2-weeks post-COVID-19, noticeably their numbers were far more than the cases classified as MIS-C and interestingly the majority of such

medRxiv preprint doi: https://doi.org/10.1101/2021.07.23.21260716; this version posted September 21, 2021. The copyright holder for this preprint (which was not certified by peer review) is the author/funder, who has granted medRxiv a license to display the preprint in perpetuity.

It is made available under a CC-BY-ND 4.0 International license .

hepatitis cases were lacking the hallmarks of inflammation seen in MIS-C. Since these unique cases far outnumbered any other presentations of hepatitis seen in children during this period, the study was planned to correctly identify the cases, find out its temporal relation with COVID-19 infections and differentiate it from the other entities like MIS-C in children.

To our knowledge, none of the published studies and reports took a detailed account of such incidences of post-COVID-19 hepatitis in pediatric or adolescent age group, as in CAH-C which was unique, different from both the known liver injury phenotypes described earlier in children and has been observed during the second wave of SARS-CoV-2 infections.

Methods

Patients and Study Design: It was a retrospective and follow-up observational study of children presented with acute hepatitis during April 2021 to July 2021 at a tertiary care public hospital and Medical College in Sagar, a district in central India, which is a dedicated COVID-19 (500 beds) center for the entire region as *shown in figure 1*. During the study period a total of 475 children of age of 14 years or below tested COVID-19 positive by Indian Council of Medical research (ICMR) recommended RT-PCR assay As per the existing protocols, all the positive cases, their family members and contacts were monitored through central control command telemedicine center from the Sagar smart city control room (16). Children presented with serious symptoms including hepatitis, during post-COVID-19 illness were admitted to the hospital. A record review for all such patients was performed and follow-up information was collected from the control command center and from the hospital helpdesk center. The outline of the procedures is shown in *figure 2*.

Inclusion criteria: Children presented with clinical features and laboratory findings (elevated transaminases) suggestive of acute hepatitis during post-COVID-19 were enrolled in the study for further evaluation. Based on temporal association in relation to COVID-19, disease severity (admission to intensive care), inflammatory markers and presence or absence of multi-system involvement we could differentiate these hepatitis patients into two different entities.

medRxiv preprint doi: https://doi.org/10.1101/2021.07.23.21260716; this version posted September 21, 2021. The copyright holder for this preprint **(which was not certified by peer review)** is the author/funder, who has granted medRxiv a license to display the preprint in perpetuity.

It is made available under a CC-BY-ND 4.0 International license .

1) COVID-19 associated hepatitis in children (CAH-C): Those presented with "Sudden onset hepatitis in a pediatric patient with elevated transaminases, non-obstructive jaundice, without history of underlying liver disease, negative for evidence of other known causes of acute hepatitis, with a laboratory evidence of recent COVID-19 and in absence of marked inflammatory responses".
2) MIS-C associated hepatitis: Patients of MIS-C presenting with acute hepatitis i.e. elevated transaminases (17).

Exclusion criteria: Those patients who had evidence of pre-existing liver disease, drug-induced liver injury, MIS-C cases without evidence of liver injury or those who were positive for other known causes of acute hepatitis were excluded from the study.

Laboratory investigations: SARS-CoV-2 RT-PCR was done at the ICMR recognized Virology research and diagnostic laboratory (VRDL) of the hospital with the established protocols and results were recorded on the national portal. All patients presenting with hepatitis were thoroughly evaluated as per the standard protocols including complete blood counts, liver function tests, renal function tests, serum ferritin, CRP, D Dimer, LDH, myocardial enzymes, and procalcitonin in the Central clinical lab in the dedicated COVID-19 hospital of our institute. Those children with signs of acute hepatitis were further evaluated with additional tests including HbsAg, anti-hepatitis E virus (HEV) IgM, anti-hepatitis A virus (HAV) IgM, anti HCV, anti-Leptospira IgM, anti EBV IgM, anti VZV IgM, Widal test, malaria antigen, malaria antibody, antinuclear antibody (ANA), anti LKM antibody, total IgG, anti-SARS-CoV-2 IgG, dengue NS1 antigen, dengue IgM (Antibody tests were done in the department of Microbiology with ICMR recommended ELISA kits)(18), and a repeat RT-PCR for COVID-19.

Treatment: Children in the CAH-C cases (n=37) admitted in general wards were given supportive therapy consisting of anti-emetics, IV fluids, vitamins, Zinc without any use of steroids. Those with MIS-C and hepatitis (n=10) were treated as per the ICMR recommended COVID-19 regimen for children and other supportive treatment inclusive of IVIG (n=1) in child with neurologic symptoms, steroids in all, and oxygen administration (n=3) in intensive care settings, without mechanical ventilation.

medRxiv preprint doi: https://doi.org/10.1101/2021.07.23.21260716; this version posted September 21, 2021. The copyright holder for this preprint **(which was not certified by peer review)** is the author/funder, who has granted medRxiv a license to display the preprint in perpetuity.

It is made available under a CC-BY-ND 4.0 International license .

Outcomes: Survival at 4 weeks post-discharge was taken as an endpoint for the assessment of the outcomes.

Statistical analysis: The data was extracted and entered in MS excel, proportions and percentages were calculated for categorical variables. The chi-square test was performed to find possible associations between the categorical variables like association of male sex, clinical outcome with either of entities. After checking the normality of data, *t*-test was applied to compare the mean values of different baseline laboratory parameters such as age, days of hospital stay etc. For those variables not having normality Mann Whitney U test or Fischer's exact test was applied; A *p*-value of less than 0.05 was considered significant. The statistical analysis was performed using SPSS trial version 16 for windows.

Ethics approval: The follow-up and analysis work was performed after obtaining due approval of human ethics committee of the institution (Ref no. IEC/BMC/80/21).

Funding: No external funding was provided for the study; diagnosis and clinical investigations were carried out as part of the routine patient care at the hospital.

Results

Patient characteristics: During the study period from April 2021 to July 2021 among the screened population of 15873, 475 (2.99%) children with a male to female ratio of 303: 172(1.76:1) were found to be COVID-19 RT-PCR positive. The age group of these children ranged from 4 months to 14 years with mean age of 9 ± 3 years (*figure 3.a). A*mong the admitted patients, 47 presented with features of hepatitis *(Table 1)* could satisfy the inclusion criteria, 2 cases presenting with hepatitis were excluded from the study as one of them was suspected to have drug induced liver injury, other was positive for HAV (*figure 2)*. As per the above- mentioned criteria, 37 patients (Male: Female, 23:14) and 10 (Male: Female, 3:7) patients could be categorized into CAH-C and MIS-C respectively. The distribution of age groups for both entities is depicted in *figure 3.b* where majority belonged to 2-6 years' age group.

medRxiv preprint doi: https://doi.org/10.1101/2021.07.23.21260716; this version posted September 21, 2021. The copyright holder for this preprint **(which was not certified by peer review)** is the author/funder, who has granted medRxiv a license to display the preprint in perpetuity.

It is made available under a CC-BY-ND 4.0 International license .

The MIS-C cases started in mid-April 2021 and peaked around the end of May 2021, showing a decline thereafter limiting to 1 case in July first week and finally disappearing in July 3rd week, after a lag of 2 weeks when the new cases COVID-19 disappeared in June end. The cases of CAH-C started appearing in April-end and peaked in may end and then showing a decline in trend with small number of cases (3-4) still presenting after 4 weeks of disappearance of new COVID-19 cases in the district. The relative incidences of hepatitis cases in temporal relation to COVID-19 cases have been shown in *figure 4*.

Clinical and laboratory findings:

CAH-C group: Children presented with typical symptoms of hepatitis including nausea, vomiting, loss of appetite, weakness and mild fever not exceeding 100 ºF. The frequency of symptoms is shown in *figure 5 a.* Icterus was present on examination in majority (25) of cases. All these children had history of COVID-19 within past 3-6 weeks, however none of these children had experienced any serious or typical symptoms of COVID-19 or any significant finding on chest X-ray. The X-ray findings of CAH-C versus MIS-C have been shown in *figure 5 b*.

On laboratory investigation at admission for CAH-C cases, 35 had a RTPCR test negative for SARS CoV-2 by the time when admitted, majority cases (29/37) had significantly elevated transaminases>10X upper limit of normal (ULN) with median 1326.2 (range 70-5685) U/L , and serum bilirubin with median 4.05 (range 1.4-17.1) mg/dl , 25/37 had unelevated (remaining 12/37 had moderate elevation) C reactive protein (CRP), median 5.4 (range 0.70-7.9) mg/L , IL-6, median 9.7 (range 2.1-24.6.3) pg/ml (p=0.0001). many (16/37) had elevated alkaline phosphatases 2X ULN (p= 0.29), slightly elevated total IgG levels median 1245.3 (range 551.4-1640) mg/dl, 35/37 had normal platelet counts, median 2.45 (range 0.69-7.7) /mm^3X10^3 and D-Dimer could be performed in 8/37 among them 5 were within range. All 37 (100%) patients were positive for SARS-CoV-2, anti-N protein antibodies in high titers. All were ANA negative, anti- LKM antibody negative (available for 21/37), 8/37 (21.6%) had positive IgM antibodies for Dengue and in 21/37 (56.7%) a Widal titer of more than 1:160 for both O

medRxiv preprint doi: https://doi.org/10.1101/2021.07.23.21260716; this version posted September 21, 2021. The copyright holder for this preprint **(which was not certified by peer review)** is the author/funder, who has granted medRxiv a license to display the preprint in perpetuity.

It is made available under a CC-BY-ND 4.0 International license .

and H antibodies. Furthermore, anti-VZV IgM antibodies were found in 7 (19%) of these and anti EBV-IgM was found in (21.6%) of them, respectively. The mean laboratory values of the groups have been depicted in *Table 2.*

Outcomes: All patients were discharged with supportive treatment without any complications with mean hospital stay of 4 (± 1.0) days and remained uneventful at 4 weeks' follow-up. No mortality was reported in this group.

MIS-C with hepatitis: Children were presented with moderate to severe symptoms of COVID-19 and a persistent fever of >100 ºF made them to be hospitalized. Besides persistent fever, they had sub-conjunctival hemorrhages, cough, shortness of breath, with features of hepatitis such as abdominal pain, loss of appetite and weakness. In these cases, 3 (30%) developed ARDS and signs of multi-organ failure mainly hypotension, swelling and one of them developed signs of liver failure. One child presented with epidermal necrosis and toxic shock like picture, one with encephalitis and 5 (50%) children had features of pneumonia on chest X rays (*figure 5 b)*. All cases had admission in intensive care units.

On laboratory investigation MIS-C patients presented with hepatitis, majority (7/10) were RT-PCR test positive for SARS CoV-2 within the past 2-3 weeks, they had markedly raised CRP median 17.8 mg/L (p=0.0001), significantly elevated IL-6 median 134.4 pg/ml (p=0.0001) and reduced albumin levels with median 3.3 gm/dl (2.7-3.58) (p=0.116). D-Dimer was high (>1.5) in all 7 cases in which it could be measured. They had reduced platelet counts in some cases, moderately elevated transaminases (ALT 40-200 U/L), normal or borderline raised serum bilirubin, slightly raised alkaline phosphatases, and raised procalcitonin (available only for 4 cases). They had insignificant Widal titer (available for n=5 cases), negative IgM for dengue, positive ANA in 1 case and positive SARS-CoV-2 antibody test in 3 cases (test result was available for 5 cases). These 3 cases had a contact history with RT-PCR confirmed case of COVID-19 but were themselves RT-PCR negative for SARS-CoV-2.

medRxiv preprint doi: https://doi.org/10.1101/2021.07.23.21260716; this version posted September 21, 2021. The copyright holder for this preprint **(which was not certified by peer review)** is the author/funder, who has granted medRxiv a license to display the preprint in perpetuity.

It is made available under a CC-BY-ND 4.0 International license .

Outcomes: Among the MIS-C children having various multi-system involvement including lung disease, vasculitis, encephalitis, one child developed paralytic ileus which resolved on conservative treatment, however 3 (30%) out of 10 had an adverse outcome. These cases had protracted illness, the mean hospital stay in this group was 8 (± 1) days, on 4 weeks' post-discharge follow-up the remaining children recovered leading to a survival rate of 7/10 (70%).

Discussion

With the emergence of newer variants of concern and recurring waves of the COVID-19 pandemic, varied symptoms and post COVID-19 complications have been observed. While, pediatric population remained largely unaffected by the horror of COVID-19 during the initial wave of SARS-CoV-2 infection, things changed for this age group in the subsequent waves. In our study, performed on 475 pediatric COVID-19 patients during the second wave of the pandemic, we identified 37 cases with a unique presentation of acute hepatitis defined as CAH-C, whereas MIS-C could account for hepatitis in 10 cases.

The findings worth noticing are that CAH-C cases are not only asymptomatic COVID-19 course but also mild disease course. None of the CAH-C cases had any previous underlying morbidity. These cases presented after 2-6 weeks of asymptomatic COVID-19, or remaining mild symptomatic for the same period following exposure to a lab-confirmed case of COVID-19. These cases peaked following 3-4 weeks in relation to the peak of new cases of COVID-19 during the second wave of SARS-CoV-2 infections in central India. This unique feature of the children being previously asymptomatic might led to a casual attitude in these children and their parents which is contrary to the fact that all these patients required hospital admission. These cases might just be the tip of the iceberg, hence health systems and pediatric care setups across the globe need to be prepared in the light of these observations, since this is an initial and early report of such cases. There is always a possibility of such cases presenting in a few months' time in the countries to which the Delta variant has reached.

medRxiv preprint doi: https://doi.org/10.1101/2021.07.23.21260716; this version posted September 21, 2021. The copyright holder for this preprint **(which was not certified by peer review)** is the author/funder, who has granted medRxiv a license to display the preprint in perpetuity.

It is made available under a CC-BY-ND 4.0 International license .

The brighter side of the picture is that all cases of CAH-C responded within a week with the help of supportive treatment and care measures with none requiring specific anti-viral treatment. They were monitored carefully for deterioration in clinical course since these type of presentations was observed for the first time and no guidelines were available for treatment of such cases. None of them required antiviral drugs, oxygen therapy or mechanical ventilation, which was the recommended line of treatment for cases with deterioration in COVID-19 **(19)**. CAH-C cases were more commonly reported in the age group of 6-11 years and with male preponderance. Similar findings were observed in other large cohort studies conducted among MIS-C cases. Higher expression of ACE2 receptor in cholangiocytes **(20)** and TMPRSS2 receptor in hepatocytes among males might be predisposing them for the liver injury **(21)**.

Interestingly, CAH-C cases had distinct immunological imprints having antibody responses with raised anti SARS-CoV-2 titers (>50 COI) in all the cases, negative ANA, significant Widal titers (>1:160 O, H), along with positive dengue IgM, positive anti-EBV IgM was seen in 8/37 cases and anti-VZV IgM in 7/37 patients respectively. This multi-positivity for various infectious agents along with elevated total IgG levels are unusual for children of such young age. These findings point to skewed immune activation towards B cell stimulation giving rise to multiple antibody responses as a result of possible polyclonal B cell immune activation by some of the SARS-CoV-2 antigens. This role played by SARS-CoV-2 in CAH-C is in contrast to the hallmark polyclonal (Vβ 21.3+ CD4+ and CD8+) T-cell stimulation observed in cases of MIS-C **(23)**. Thus SARS-Cov-2 is a potent immune-stimulator in both these conditions with a role of possible molecular mimicry resulting in polyclonal B cell activation during post COVID-19 CAH-C with such self-limiting course seen exclusively in children.

Possibly among the known complications occurring subsequently to SARS-CoV-2 infections MIS-C is the more severe form hallmarked by polyclonal T- cell activation and CAH-C is on the milder end of disease spectrum hallmarked by polyclonal B-cell activation. As of now, these antibodies in CAH-C seem to be doing more of an evil, rather than a virtue offering any long-term or short-term protection.

medRxiv preprint doi: https://doi.org/10.1101/2021.07.23.21260716; this version posted September 21, 2021. The copyright holder for this preprint **(which was not certified by peer review)** is the author/funder, who has granted medRxiv a license to display the preprint in perpetuity.

It is made available under a CC-BY-ND 4.0 International license .

Whether such polyclonal activation is a friend or a foe is just one of the worries in the light of current knowledge, where previous studies have reported differences among the antibody responses in children versus adults. It was found that children are having a reduced breadth of spectrum against SARS-CoV-2 which may or may not be neutralizing versus a wide spectrum of neutralizing antibodies found in adults. Some studies have shown that alterations in B cells responses persist during the period of convalescence affecting long-term immunity and producing varied persistent symptoms in the among adults recovered from COVID-19 (24). Nevertheless, at this point with our limited experience at a single set-up and given the relatively short period of follow-up among the cases, it might be too early to say with certainty that CAH-C is actually a benign disease. Long-term follow-up of such cases is likely to rule out any possibility of long COVID in these cases.

Another more important concern is associated with the value of such probable biologically false positive (BFP) antibody tests in the diagnosis of other infectious diseases. It is likely to pose a diagnostic dilemma in the times of this pandemic where similar febrile illnesses such as dengue, chikungunya and enteric fever remain endemic in certain geographic areas in developing countries like India.

Prima facie, CAH-C is a different liver injury phenotype since the parameters observed here, do not resemble either those observed in MIS-C, or the hepatitis seen in cases of active COVID-19 (22). The clinical and laboratory findings in CAH-C cases are unique, noticeably lacked any markedly elevated inflammatory markers observed in MIS-C or systemic derangements associated with COVID-19, besides having markedly elevated levels of serum bilirubin and more than 10x ULN elevation of transaminases.

Cases of CAH-C had a hundred percent survival rate, at 4 weeks' post-discharge follow-up again indicating towards existence of it being a separate phenotype.

On the contrary, much is already known about the MIS-C cases with hepatitis, findings in our set of cases were quite similar. These cases having presented with fever often >100 ºF, often with respiratory distress, abdominal pain, loss of appetite, rash,

medRxiv preprint doi: https://doi.org/10.1101/2021.07.23.21260716; this version posted September 21, 2021. The copyright holder for this preprint **(which was not certified by peer review)** is the author/funder, who has granted medRxiv a license to display the preprint in perpetuity.

It is made available under a CC-BY-ND 4.0 International license .

conjunctival hemorrhages, and encephalitis-like features necessitating intensive care facility. Majority of these cases typically presented within 2-3 weeks of having moderate to severe symptoms of COVID-19. Their numbers peaked earlier in comparison to the CAH-C cases.

Their laboratory assessment showed significant association with high inflammatory markers, which were often many folds to the UNL, with borderline elevated aminotransferases, slightly altered INR, markedly raised ferritin levels in 7/10 cases, elevated D-Dimer in 8/10 cases and decreased albumin levels in all cases. Among them 5/10 had developed anti SARS-CoV-2 antibodies and 8 patients had a 2-3 weeks old history of COVID-19 RTPCR positivity.

Despite best of efforts besides having administered standard recommended therapy, including anti-viral drugs when needed, steroids in all cases, IVIG in 1 case, oxygen administration in 4 cases, and mechanical ventilation in 1 case, 3 patients succumbed to the disease.

As MIS-C is already known to be associated with higher mortality and a poor survival rate **(5)**, our findings in these cases were no different and they only had fair survival rate of 7/10 (70 %).

Conclusion

At the times when majority of children across the globe remain uncovered by vaccination, early recognition of the newly described entity of CAH-C, which is by far a transient phenomenon considering the distinct features described here, should enable the treating physician in using age and phenotype targeted approach for timely administering the supportive therapy. Furthermore, it will also help in preventing burden on resources in the times of pandemic, since the MIS-C hepatitis phenotype is more associated with disease severity and increased mortality.

medRxiv preprint doi: https://doi.org/10.1101/2021.07.23.21260716; this version posted September 21, 2021. The copyright holder for this preprint (which was not certified by peer review) is the author/funder, who has granted medRxiv a license to display the preprint in perpetuity.

It is made available under a CC-BY-ND 4.0 International license .

Acknowledgement

The authors thank and acknowledge Dr Rupesh Sahu for his support in suggesting the right statistical tools and his valuable feedback in completing the statistical analysis of the study. We are obliged by Dr Anirudh Singh and Dr Ashish K Vyas for their suggestions in improvement of the manuscript and for assistance in the plagiarism check.

References

1. Hu B, Guo H, Zhou P, Shi Z-L. Characteristics of SARS-CoV-2 and COVID-19. Nat Rev Microbiol. 2021 Mar;19(3):141–54.

2. Guan W, Ni Z, Hu Y, Liang W, Ou C, He J, et al. Clinical Characteristics of Coronavirus Disease 2019 in China. N Engl J Med [Internet]. 2020 Feb 28 [cited 2021 Jun 20]; Available from: https://www.nejm.org/doi/10.1056/NEJMoa2002032

3. Viner RM, Whittaker E. Kawasaki-like disease: emerging complication during the COVID-19 pandemic. The Lancet. 2020 Jun 6;395(10239):1741–3.

4. Riphagen S, Gomez X, Gonzalez-Martinez C, Wilkinson N, Theocharis P. Hyperinflammatory shock in children during COVID-19 pandemic. Lancet Lond Engl. 2020;395(10237):1607–8.

5. Feldstein LR, Rose EB, Horwitz SM, Collins JP, Newhams MM, Son MBF, et al. Multisystem Inflammatory Syndrome in U.S. Children and Adolescents. N Engl J Med. 2020 Jun 29;NEJMoa2021680.

6. HAN Archive - 00432 | Health Alert Network (HAN) [Internet]. 2020 [cited 2021 Aug 10]. Available from: https://emergency.cdc.gov/han/2020/han00432.asp

7. Cantor A, Miller J, Zachariah P, DaSilva B, Margolis K, Martinez M. Acute Hepatitis Is a Prominent Presentation of the Multisystem Inflammatory Syndrome in Children: A Single-Center Report. Hepatology. 2020;72(5):1522–7.

8. Singh PP, Tamang R, Shukla M, Pathak A, Srivastava A, Gupta P, et al. Estimation of real-infection and immunity against SARS-CoV-2 in Indian populations. medRxiv. 2021 Apr 11;2021.02.05.21251118.

9. Mallapaty S. India's massive COVID surge puzzles scientists. Nature. 2021 Apr 21;592(7856):667–8.

10. Dougherty K. SARS-CoV-2 B.1.617.2 (Delta) Variant COVID-19 Outbreak Associated with a Gymnastics Facility — Oklahoma, April–May 2021. MMWR Morb Mortal Wkly Rep [Internet]. 2021 [cited 2021 Jul 14];70. Available from: https://www.cdc.gov/mmwr/volumes/70/wr/mm7028e2.htm

medRxiv preprint doi: https://doi.org/10.1101/2021.07.23.21260716; this version posted September 21, 2021. The copyright holder for this preprint **(which was not certified by peer review)** is the author/funder, who has granted medRxiv a license to display the preprint in perpetuity.

It is made available under a CC-BY-ND 4.0 International license .

11. Gupta DCH S, Chopra MD N, Singh MD A, Gera R, Chellani MD H, Pandey PhD R, et al. Unusual Clinical Manifestations and Outcome of Multisystem Inflammatory Syndrome in Children (MIS-C) in a Tertiary Care Hospital of North India. J Trop Pediatr. 2021 Jan 29;67(1):fmaa127.

12. Narahari KK, Pothala R, Bathina SP, Deshmukh N, Kumar C. Cholestatic Jaundice as a Manifestation of Multisystem Inflammatory Syndrome in Children (MIS-C). Indian J Pediatr. 2021 Jul 28;1.

13. Phipps MM, Barraza LH, LaSota ED, Sobieszczyk ME, Pereira MR, Zheng EX, et al. Acute Liver Injury in COVID-19: Prevalence and Association with Clinical Outcomes in a Large U.S. Cohort. Hepatol Baltim Md. 2020 Sep;72(3):807–17.

14. Perez A, Cantor A, Rudolph B, Miller J, Kogan-Liberman D, Gao Q, et al. Liver involvement in children with SARS-COV-2 infection: Two distinct clinical phenotypes caused by the same virus. Liver Int. 2021 Apr 22;10.1111/liv.14887.

15. Nardo AD, Schneeweiss-Gleixner M, Bakail M, Dixon ED, Lax SF, Trauner M. Pathophysiological mechanisms of liver injury in COVID-19. Liver Int. 2021;41(1):20–32.

16. 45 smart city command and control centres turn into COVID-19 war rooms - The Economic Times [Internet]. [cited 2021 Jul 13]. Available from: https://economictimes.indiatimes.com/news/politics-and-nation/45-smart-city-command-and-control-centres-turn-into-COVID-19-war-rooms/articleshow/74904329.cms

17. Godfred-Cato S, Bryant B, Leung J, Oster ME, Conklin L, Abrams J, et al. COVID-19–Associated Multisystem Inflammatory Syndrome in Children — United States, March–July 2020. Morb Mortal Wkly Rep. 2020 Aug 14;69(32):1074–80.

18. ICMR_PR_IgG_Elisa_30052020.pdf [Internet]. [cited 2021 Jul 14]. Available from: https://main.icmr.nic.in/sites/default/files/press_realease_files/ICMR_PR_IgG_Elisa_30052020.pdf

19. Sanders JM, Monogue ML, Jodlowski TZ, Cutrell JB. Pharmacologic Treatments for Coronavirus Disease 2019 (COVID-19): A Review. JAMA. 2020 May 12;323(18):1824–36.

20. Salamanna F, Maglio M, Landini MP, Fini M. Body Localization of ACE-2: On the Trail of the Keyhole of SARS-CoV-2. Front Med. 2020;7:935.

21. Zhou L, Niu Z, Jiang X, Zhang Z, Zheng Y, Wang Z, et al. SARS-CoV-2 Targets by the pscRNA Profiling of ACE2, TMPRSS2 and Furin Proteases. iScience. 2020 Nov 1;23(11):101744.

22. Lv Y, Zhao X, Wang Y, Zhu J, Ma C, Feng X, et al. Abnormal Liver Function Tests Were Associated With Adverse Clinical Outcomes: An Observational Cohort Study of 2,912 Patients With COVID-19. Front Med. 2021 Jun 9;8:639855.

23. Moreews M, Gouge KL, Khaldi-Plassart S, Pescarmona R, Mathieu A-L, Malcus C, et al. Polyclonal expansion of TCR Vb 21.3+ CD4+ and CD8+ T cells is a hallmark of multisystem inflammatory syndrome in children. Sci Immunol [Internet]. 2021 May 25 [cited 2021 Aug 16];6(59). Available from: https://immunology.sciencemag.org/content/6/59/eabh1516

medRxiv preprint doi: https://doi.org/10.1101/2021.07.23.21260716; this version posted September 21, 2021. The copyright holder for this preprint **(which was not certified by peer review)** is the author/funder, who has granted medRxiv a license to display the preprint in perpetuity.

It is made available under a CC-BY-ND 4.0 International license .

24. Weisberg SP, Connors TJ, Zhu Y, Baldwin MR, Lin W-H, Wontakal S, et al. Distinct antibody responses to SARS-CoV-2 in children and adults across the COVID-19 clinical spectrum. Nat Immunol. 2021 Jan;22(1):25–31.

***Figure 1*: Geographic location of the study**

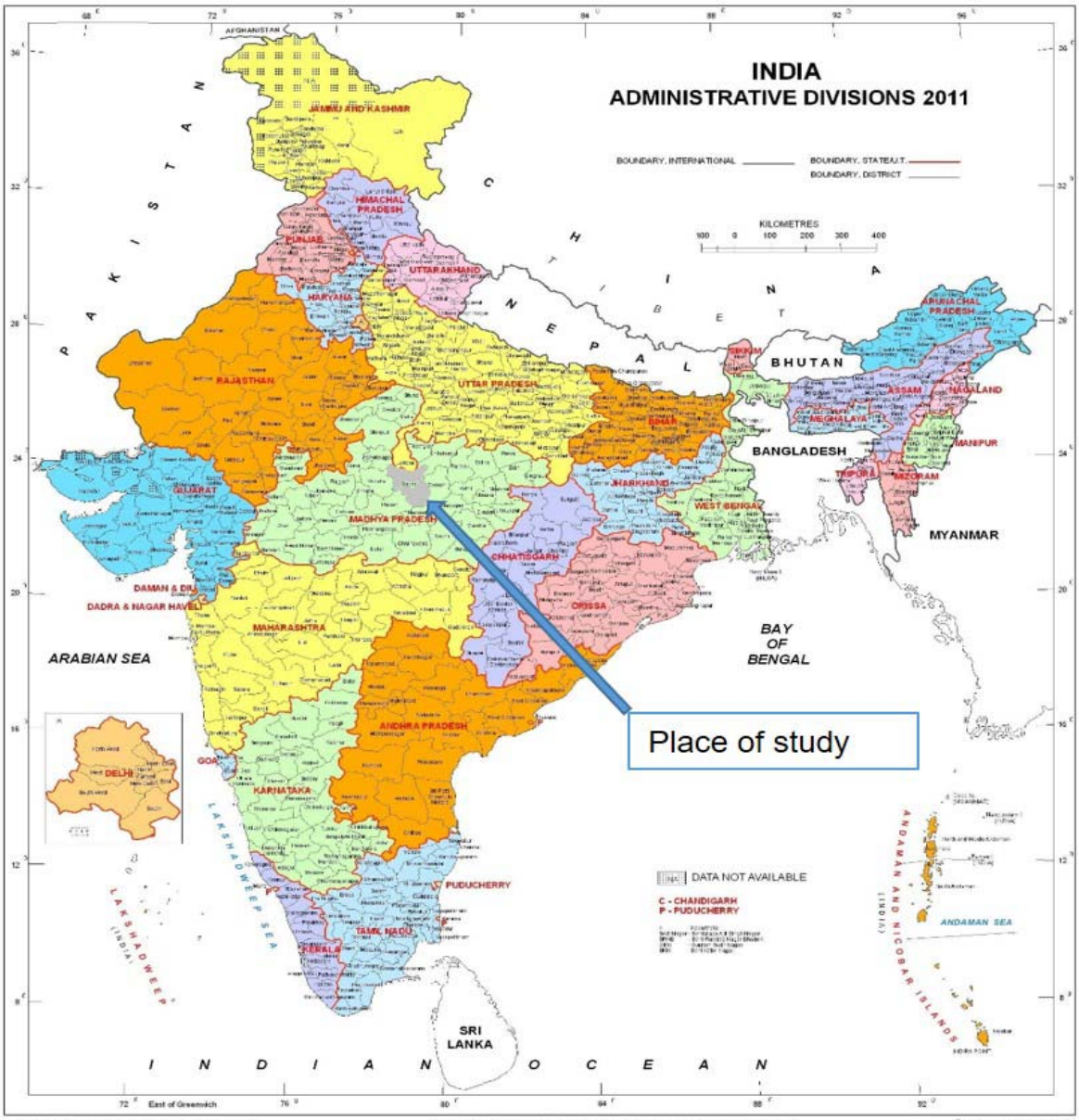

medRxiv preprint doi: https://doi.org/10.1101/2021.07.23.21260716; this version posted September 21, 2021. The copyright holder for this preprint **(which was not certified by peer review)** is the author/funder, who has granted medRxiv a license to display the preprint in perpetuity.

It is made available under a CC-BY-ND 4.0 International license .

Figure 2, Study workflow and case work-up

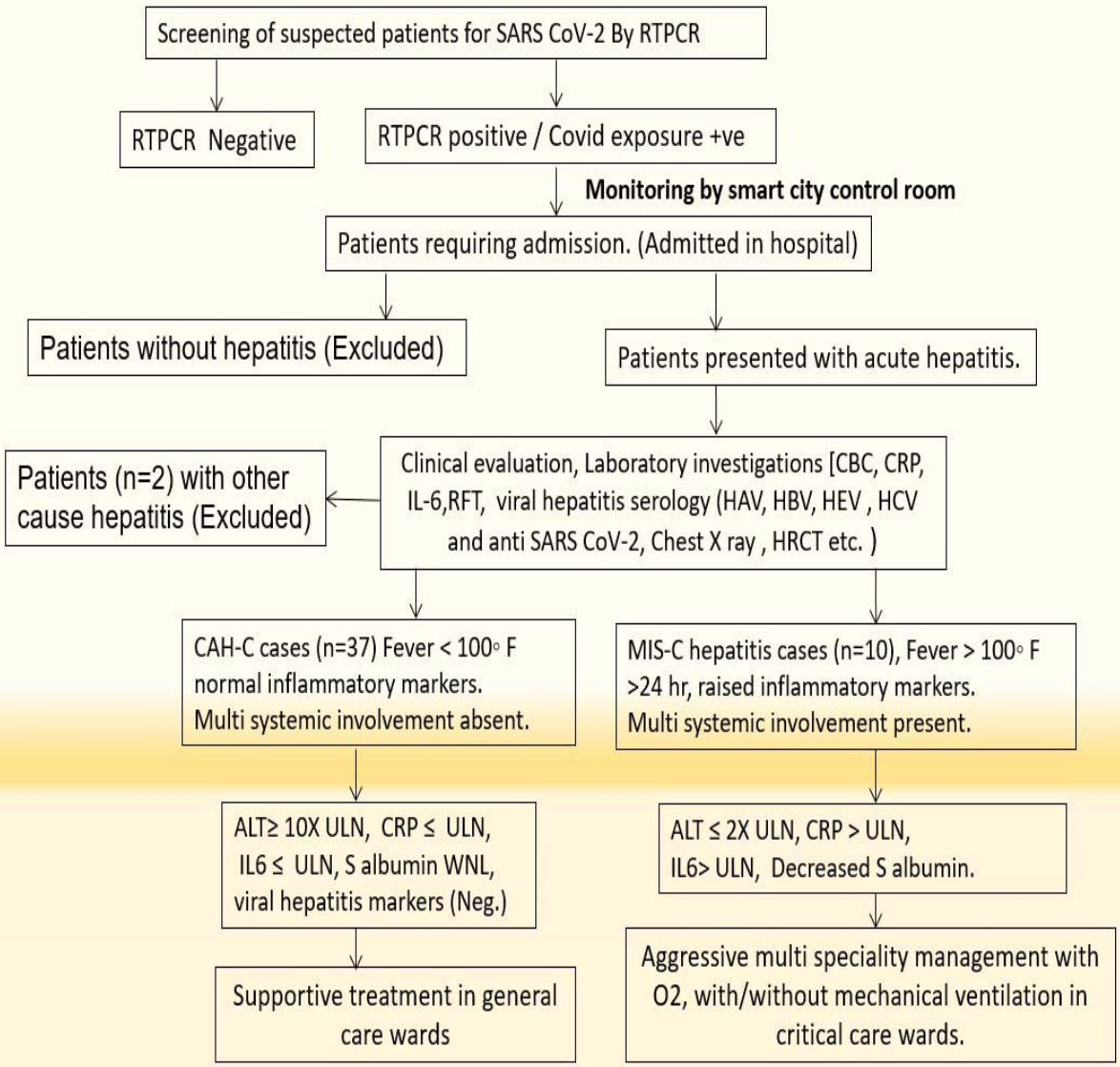

medRxiv preprint doi: https://doi.org/10.1101/2021.07.23.21260716; this version posted September 21, 2021. The copyright holder for this preprint **(which was not certified by peer review)** is the author/funder, who has granted medRxiv a license to display the preprint in perpetuity.

It is made available under a CC-BY-ND 4.0 International license .

Figure 3 a : Age group distribution of total screened population vs study population

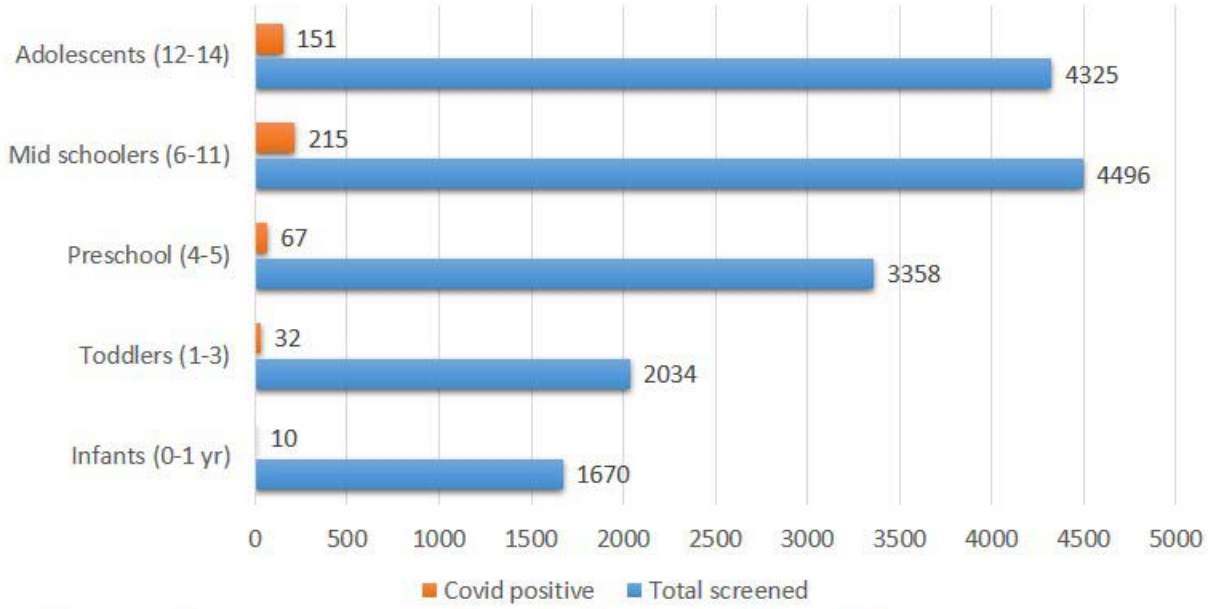

Figure 3b: Age group distribution of CAH-C Vs MIS-C cases

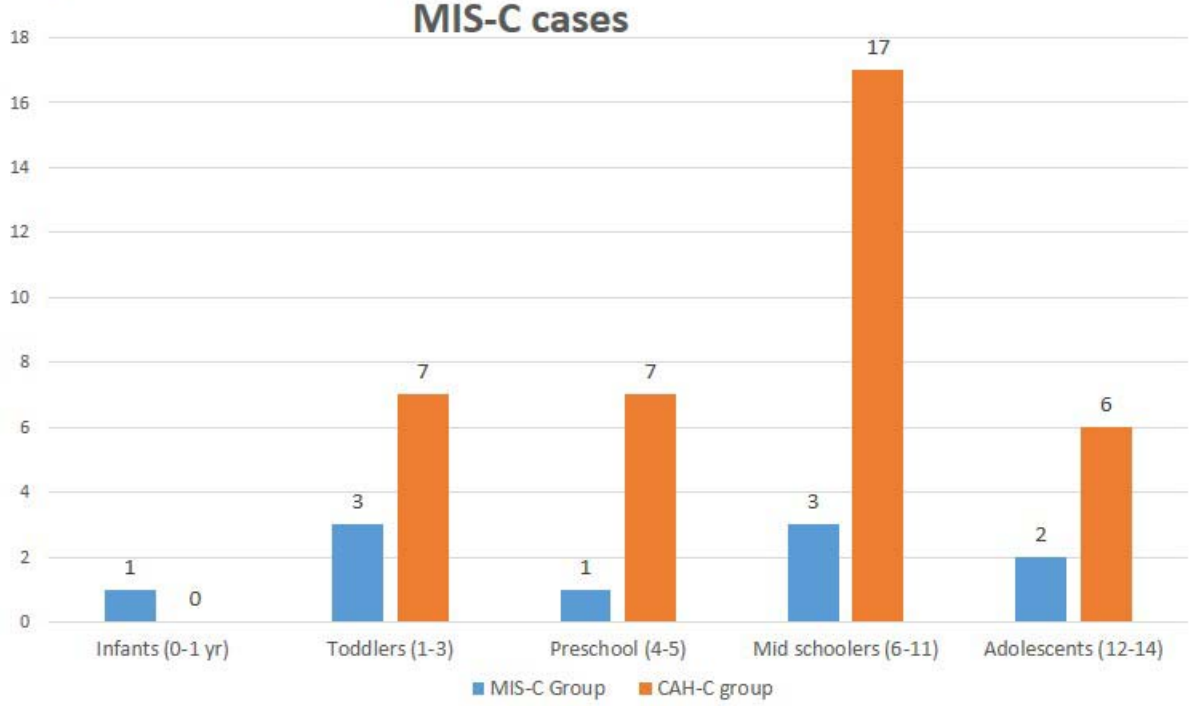

medRxiv preprint doi: https://doi.org/10.1101/2021.07.23.21260716; this version posted September 21, 2021. The copyright holder for this preprint **(which was not certified by peer review)** is the author/funder, who has granted medRxiv a license to display the preprint in perpetuity.

It is made available under a CC-BY-ND 4.0 International license .

Figure 4: Relative incidences of Covid-19 new cases Vs hepatitis cases

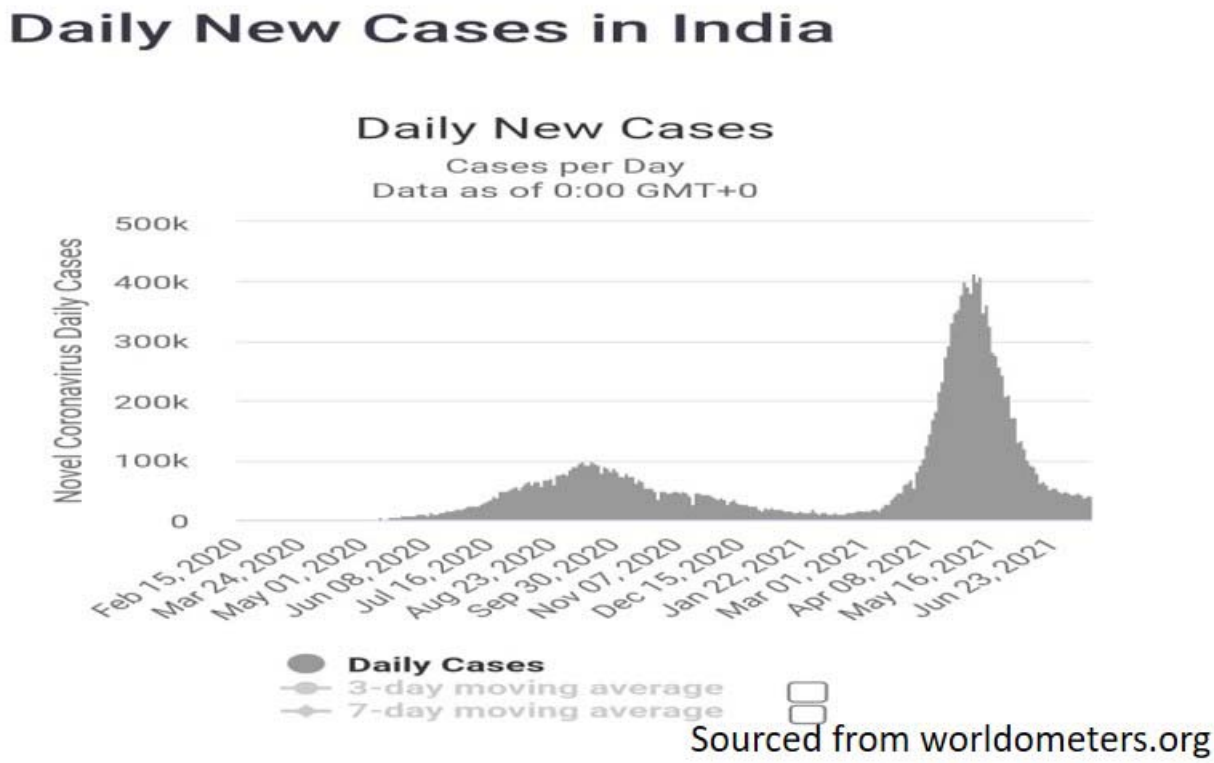

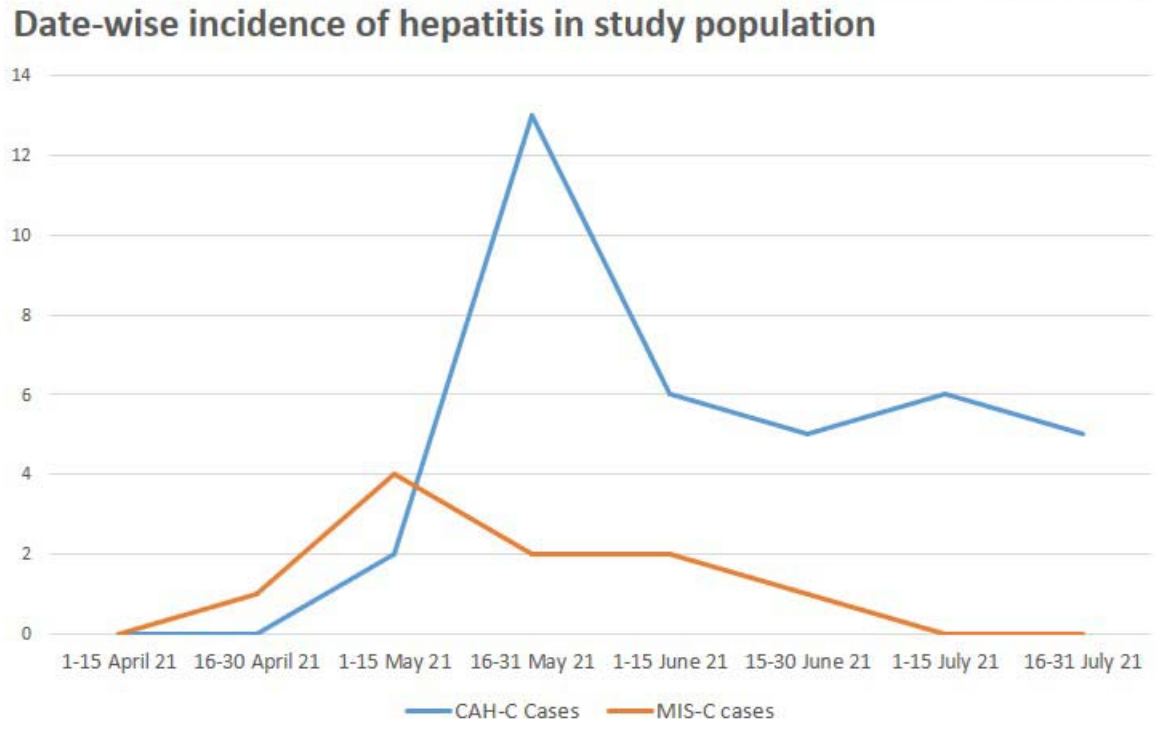

medRxiv preprint doi: https://doi.org/10.1101/2021.07.23.21260716; this version posted September 21, 2021. The copyright holder for this preprint **(which was not certified by peer review)** is the author/funder, who has granted medRxiv a license to display the preprint in perpetuity.

It is made available under a CC-BY-ND 4.0 International license .

Figure 5a: Presenting signs and symptoms in CAH-C Cases

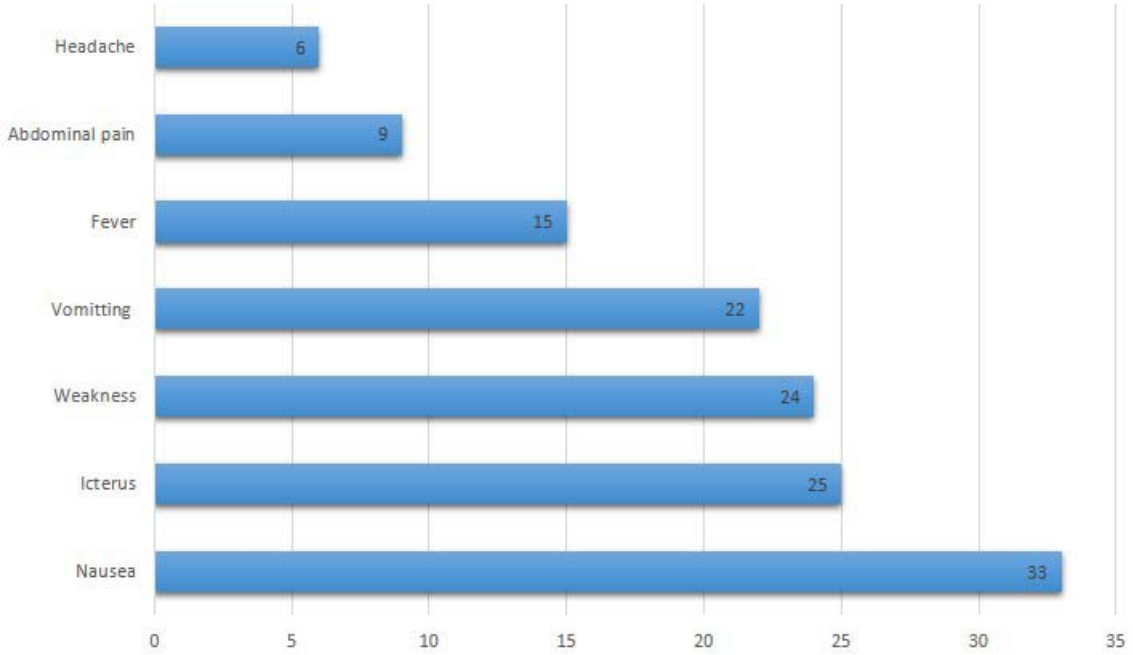

Figure 5b : X ray findings of CAH-C Vs MIS-C cases.

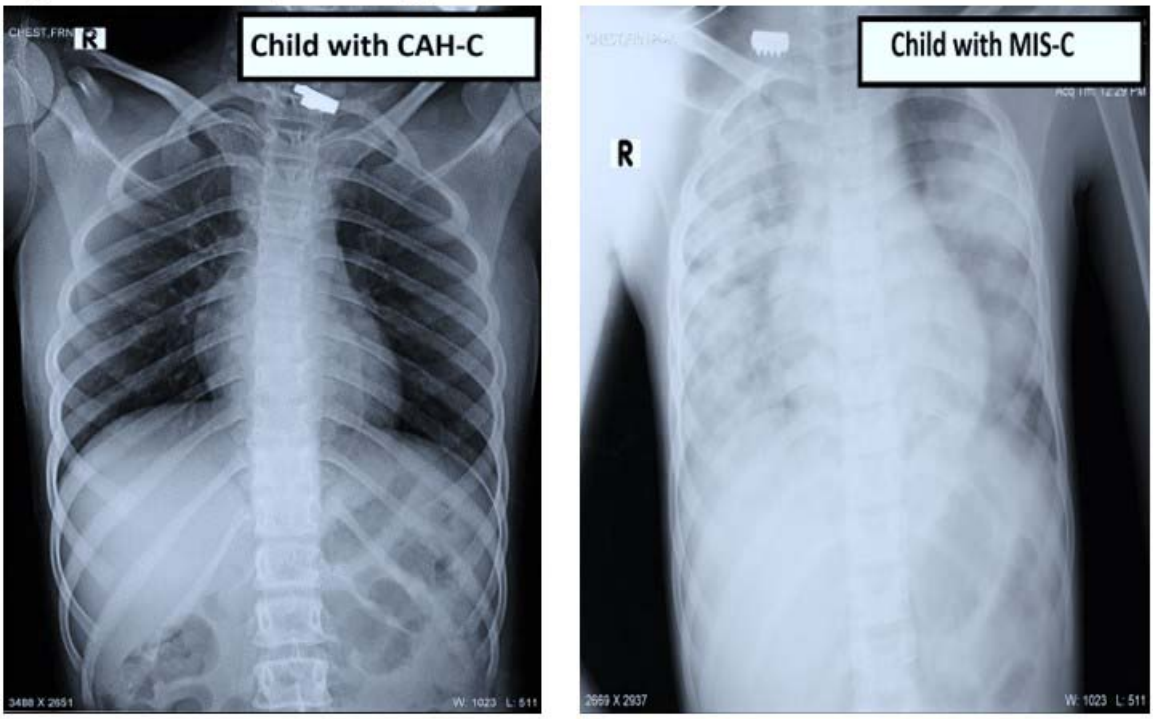

medRxiv preprint doi: https://doi.org/10.1101/2021.07.23.21260716; this version posted September 21, 2021. The copyright holder for this preprint (which was not certified by peer review) is the author/funder, who has granted medRxiv a license to display the preprint in perpetuity.

It is made available under a CC-BY-ND 4.0 International license .

Table 1: Patient characteristics of CAH-C Cases Vs MIS-C associated hepatitis cases.

Patient characteristics	**CAH-C (n=36)**	**MIS-C (n=10)**	**P-value***
Age, mean ± SD, years	6.75 (3.32)	6.2 (4.29)	-
Male sex, No. (%)	23 (63.9%)	3 (30%)	-
Total days admitted, mean ± SD	4.64 (1.37)	8.4 (1.95)	0.0001
Day from contact history, mean ± SD	23.56 (6.63)	9.7 (93.74)	0.0001
Anti SARS-CoV-2 antibody positive, n (%)	27 (73%)	5 (50%)	-
Clinical outcomes:			
Recovered, n (%)	37 (100%)	7 (70%)	-
Death, n (%)	- (-)	3 (30%)	-
***Independent samples t-test**			

Table 2: Laboratory findings of CAC-H Vs MIS-C associated hepatitis cases.

Lab values	**CAH-C (n=37)**	**MIS-C (n=10)**	P-value*
	Median (IQR)	Median (IQR)	
CRP, mg/L	4.10 (0.70, 7.90) (n=37)	17.85 (10.82, 28.42) (n=10)	0.0001
IL6, pg/ml	9.70 (4.27, 13.42) (n=37)	134.40 (34.00, 227.52) (n=10)	0.0001
Platelet, /mm^{3}X10^3	2.45 (2.10, 3.06) (n=37)	2.85 (1.35, 3.85) (n=10)	0.894
T Bil, mg/dl	5.4 (2.95, 7.15) (n=37)	0.90 (0.87, 1.37) (n=10)	0.0001
Albumin, gm/dl	3.60 (3.42, 3.67) (n=37)	3.45 (2.70, 3.77) (n=10)	0.394
AST, U/L	942.45 (301.67, 2002.05) (n=37)	85.50 (47.55, 127.90) (n=10)	0.0001
ALT, U/L	1326.25 (492.12, 2124.92) (n=37)	76.00 (44.42, 170.45) (n=10)	0.0001
Alkaline PO4, U/L	311.00 (187.40, 498.20) (n=27)	200.75 (131.12, 312.85) (n=10)	0.097
INR, ratio	1.30 (1.05, 1.52) (n=24)	1.00 (1.00, 1.39) (n=10)	0.174
	*Mann-Whitney U test		
CRP, C-reactive protein; SD, standard deviation; IL-6, interleukin-6: AST, aspartate transaminase; ALT, alanine aminotransferase; TBil, Total bilirubin; INR, international normalized ratio			