medRxiv preprint doi: https://doi.org/10.1101/2021.07.20.21260824; this version posted July 22, 2021. The copyright holder for this preprint (which was not certified by peer review) is the author/funder, who has granted medRxiv a license to display the preprint in perpetuity. All rights reserved. No reuse allowed without permission.

Association Between Ultrasonography Fetal Anomalies and Autism Spectrum Disorder

Ohad Regev[1], MD/PhD Candidate; Amnon Hadar[2,3], MD; Gal Meiri[2], MD; Hagit Flusser[2], MD; Analya Michaelovski[2], MD; Ilan Dinstein[1], PhD; Reli Hershkovitz[2], MD; and Idan Menashe[1], PhD.

[1] Ben-Gurion University of the Negev, Beer-Sheva, Israel.

[2] Soroka University Medical Center, Beer-Sheva, Israel.

[3] Clalit Health Services, Beer-Sheva, Israel.

Corresponding Author:

Idan Menashe, PhD

Department of Public Health, Faculty of Health Sciences,

Ben-Gurion University of the Negev, Beer-Sheva 8410501, Israel

Phone: +972-8-6477456

Email: idanmen@bgu.ac.il

Keywords: Autism Spectrum Disorder, Prenatal Ultrasound, Fetal Development, Fetal Organ Anomalies

NOTE: This preprint reports new research that has not been certified by peer review and should not be used to guide clinical practice.

medRxiv preprint doi: https://doi.org/10.1101/2021.07.20.21260824; this version posted July 22, 2021. The copyright holder for this preprint (which was not certified by peer review) is the author/funder, who has granted medRxiv a license to display the preprint in perpetuity. All rights reserved. No reuse allowed without permission.

Key Points

Question: Are ultrasonography fetal anomalies (UFAs) associated with autism spectrum disorder (ASD)?

Findings: In this retrospective matched case-sibling-control study, we show that fetuses developing into children with ASD have significantly higher rates of UFAs vs. both their typically developing siblings and typically developing children from the general population. UFAs in the heart, urinary system and head and brain were the anomalies most significantly associated with an ASD diagnosis and with more severe ASD symptoms.

Meaning: The association between UFAs and ASD sheds light on the multiorgan embryonic anomalies associated with ASD development and suggests potential prenatal ultrasonography biomarkers for ASD.

medRxiv preprint doi: https://doi.org/10.1101/2021.07.20.21260824; this version posted July 22, 2021. The copyright holder for this preprint (which was not certified by peer review) is the author/funder, who has granted medRxiv a license to display the preprint in perpetuity. All rights reserved. No reuse allowed without permission.

Abstract

Importance: Prenatal ultrasound is a frequently used technique to monitor fetal growth and identify fetal anomalies that may develop into congenital anomalies and diseases. Autism spectrum disorder (ASD) is a complex neurodevelopmental disorder, which is associated with a wide range of congenital anomalies. Nevertheless, to date, very little has been done to investigate organ development using prenatal ultrasound as a means to identify fetuses with an ASD susceptibility.

Objective: To investigate the association between ultrasonography fetal anomalies (UFAs) and ASD risk.

Design: A retrospective matched case-sibling-control study of singleton pregnancies between 2004-2018.

Setting: A single HMO that serves >75% of the citizens in southern Israel.

Participants: Children with ASD (n=229) were matched to two control groups: *typically developing sibling* (TDS) closest in age to the ASD child (n=201); and *typically developing population* (TDP), matched for age, sex, and ethnicity (n=229).

Exposures: UFAs detected in the fetal anatomical survey.

Main Outcomes and Measures: ASD diagnosis and symptom severity.

Results: The study cohort comprised 659 children: 229 with ASD, 201 TDS, and 229 TDP, with no significant socio-demographic case-control differences except an inherent ASD male bias compared to their TDS (77.7% vs. 56.7% respectively; p <0.001). Overall, UFAs were found in 29.3% of ASD cases vs. only 15.9% and 9.6% in the TDS and TDP groups (aOR=2.23, 95%CI=1.32-3.78, and OR=3.50, 95%CI=2.07-5.91, respectively), with 7% of the ASD cases having multiple anatomic anomalies vs. only 2% of TDS and 0.9% of TDP controls (p=0.014

medRxiv preprint doi: https://doi.org/10.1101/2021.07.20.21260824; this version posted July 22, 2021. The copyright holder for this preprint (which was not certified by peer review) is the author/funder, who has granted medRxiv a license to display the preprint in perpetuity. All rights reserved. No reuse allowed without permission.

and *p*=0.001, respectively). UFAs in the urinary system, heart, and head and brain were the anomalies most significantly associated with an ASD diagnosis ($aOR_{Urinary}$ =2.08, 95%CI=0.96-4.50 and $OR_{Urinary}$=2.90, 95%CI=1.41-5.95; aOR_{Heart}=3.72, 95%CI=1.50-9.24 and OR_{Heart}=8.67, 95%CI=2.62-28.63; and $aOR_{Head\&Brain}$=1.77, 95%CI=0.68-4.64 and $OR_{Head\&Brain}$=6.50, 95%CI=1.47-28.80; vs. TDS and TDP, respectively). ASD fetuses were also characterized by a narrower head and a relatively wider ocular distance vs. TDP fetuses (OR_{BPD}=0.81, 95%CI=0.70-0.94 and $aOR_{Ocular\ Distance}$=1.29, 95%CI=1.06-1.57). Finally, UFAs for children with ASD were associated with an earlier ASD diagnosis and more severe ASD symptoms.

Conclusions and Relevance: Our findings shed important light on the abnormal multiorgan embryonic development of ASD and suggest fetal ultrasonography biomarkers for ASD.

medRxiv preprint doi: https://doi.org/10.1101/2021.07.20.21260824; this version posted July 22, 2021. The copyright holder for this preprint (which was not certified by peer review) is the author/funder, who has granted medRxiv a license to display the preprint in perpetuity. All rights reserved. No reuse allowed without permission.

Introduction

Autism spectrum disorder (ASD) is a multifactorial, life-long neurodevelopmental disorder characterized by impaired social communication and restrictive-repetitive behaviors.[1,2] However, many people with ASD manifest additional comorbidities and congenital anatomical abnormalities that further complicate their clinical picture.[3–15] Nonetheless, today, the diagnosis of ASD is based on behavioral symptoms,[2] which are typically manifested in the second year of life.[16] A growing body of evidence suggests that the initial signs of ASD emerge during early childhood[17–19] and possibly even before birth.[20–25] Indeed, recent postnatal studies have found indications of the prenatal onset of abnormal neurodevelopment in children with ASD,[21] and some prenatal studies have provided preliminary indications for higher rates of structural anomalies both in the renal system of fetuses later developing into children with ASD and in children with specific genetic syndromes associated with ASD.[26–31] Taken together, these findings suggest that ASD may be associated with abnormal embryonic organogenesis of different body parts, which consequently leads to postnatal malformations in some children with ASD.[11,21,32,33] Accordingly, there is emerging interest in examining the prenatal organ development of fetuses later developing into children diagnosed with ASD.[20,22,25]

The tool of choice for this task is prenatal ultrasound, a commonly used pregnancy monitoring tool that allows physicians to survey fetal growth and organ development and may hence reveal anomalies suggesting genetic and developmental problems that require further testing and follow-up. In prenatal monitoring protocols, one of the primary ultrasound screenings is the fetal anatomical survey, which is considered standard of care for examining fetal organ development and detecting fetal organ anomalies. The survey involves the screening of the different organ systems and the measurement of a number of markers.[34,35] The abnormalities that

medRxiv preprint doi: https://doi.org/10.1101/2021.07.20.21260824; this version posted July 22, 2021. The copyright holder for this preprint (which was not certified by peer review) is the author/funder, who has granted medRxiv a license to display the preprint in perpetuity. All rights reserved. No reuse allowed without permission.

can be detected by the survey include structural anomalies and "soft markers" that may indicate genetic abnormalities or other non-genetic embryonic insults such as intrauterine infections, but some may be considered, in isolation, as normal variants or transient. The discovery of either structural abnormalities or "soft markers" during the fetal anatomical survey will usually prompt a thorough examination of the fetal anatomy and consideration of further diagnostic testing for chromosome abnormalities.[34–40]

Despite the emerging literature suggesting the prenatal onset of abnormal organogenesis and neurodevelopment in children with ASD and the possible genetic and environmental background of ASD, together with evidence of higher rates of congenital anomalies in ASD, very little has been done to investigate prenatal organ development in children with ASD, as reflected in prenatal ultrasound scans. For this reason, we conducted the first retrospective study of ultrasound data from the fetal anatomical survey of fetuses developing into children later diagnosed with ASD in comparison with the ultrasound data for their unaffected siblings and for typically developing children from the general population.

Methods

Study Population

All the participants in this study were born between 2004 and 2018 to mothers living in southern Israel – the Negev – which has ~700,000 inhabitants belonging to two main ethnic groups, Jews and Bedouins, that differ in their environmental exposures and genetic backgrounds. We included only fetuses from singleton pregnancies whose mothers were members of Clalit Health Services (CHS), Israel's largest health maintenance organization (HMO), serving ~75% of the Negev population. Members of CHS in this region receive most of their hospital-related health

medRxiv preprint doi: https://doi.org/10.1101/2021.07.20.21260824; this version posted July 22, 2021. The copyright holder for this preprint (which was not certified by peer review) is the author/funder, who has granted medRxiv a license to display the preprint in perpetuity. All rights reserved. No reuse allowed without permission.

services (including ASD diagnosis) at the region's only tertiary hospital, the Soroka University Medical Center, and its associated outpatient clinics.

Study design

This retrospective case-sibling-control study comprised children diagnosed with ASD (cases); their typically developing, closest-in-age siblings (TDS); and typically developing children from the [general] population (TDP), who were matched to cases by year of birth, sex (male/female) and ethnicity (Jewish/Bedouin). The case group was drawn from all children diagnosed with ASD in the Negev area, who are registered in the database of the National Autism Research Center of Israel (NARCI).[41,42] The diagnosis of ASD at the NARCI is a multidisciplinary process, which entails a comprehensive intake interview (socio-demographic and clinical factors), a behavioral evaluation with ADOS-2,[43] and a full neurocognitive assessment as described previously. [41,42] The final diagnosis of ASD is made by a pediatric psychiatrist or neurologist, according to DSM-5 criteria.[2]

Of the 704 singleton birth children with ASD in the NARCI database (database freeze, February 2020), there were 237 children (34%) for whom the relevant ultrasound scans were available in the database of the CHS prenatal ultrasound clinics. Among the 237 children, there were eight pairs of siblings with ASD (multiplex families). We randomly assigned one ASD sibling from each such multiplex family to the final study sample to reduce familial bias in our results. In addition, a sensitivity analysis using the second ASD sibling from these families was conducted. In total, the study cohort included 659 children: 229 with ASD, 201 TDS, and 229 TDP (**Figure 1**). An evaluation of socio-demographic and clinical differences between cases in the study cohort and the other children with ASD in the NARCI database showed a lower

medRxiv preprint doi: https://doi.org/10.1101/2021.07.20.21260824; this version posted July 22, 2021. The copyright holder for this preprint (which was not certified by peer review) is the author/funder, who has granted medRxiv a license to display the preprint in perpetuity. All rights reserved. No reuse allowed without permission.

proportion of Jews (vs. Bedouin Israelis), a lower parental age, and a higher ADOS score for the ASD children in the study cohort (**eTable 1**). The lower proportion of Jews in the study cases can be explained by the fact that Jewish parents tend to use private insurance to conduct a more comprehensive anatomical survey than that offered by the HMO. The ethnic differences in the study cases can also explain the differences in parental age and ADOS scores, since Bedouins tend to have children at an earlier age than Jews,[42] and the diagnosis of ASD in the Bedouin population is usually made for those with more severe symptoms of the disorder.[42,44]

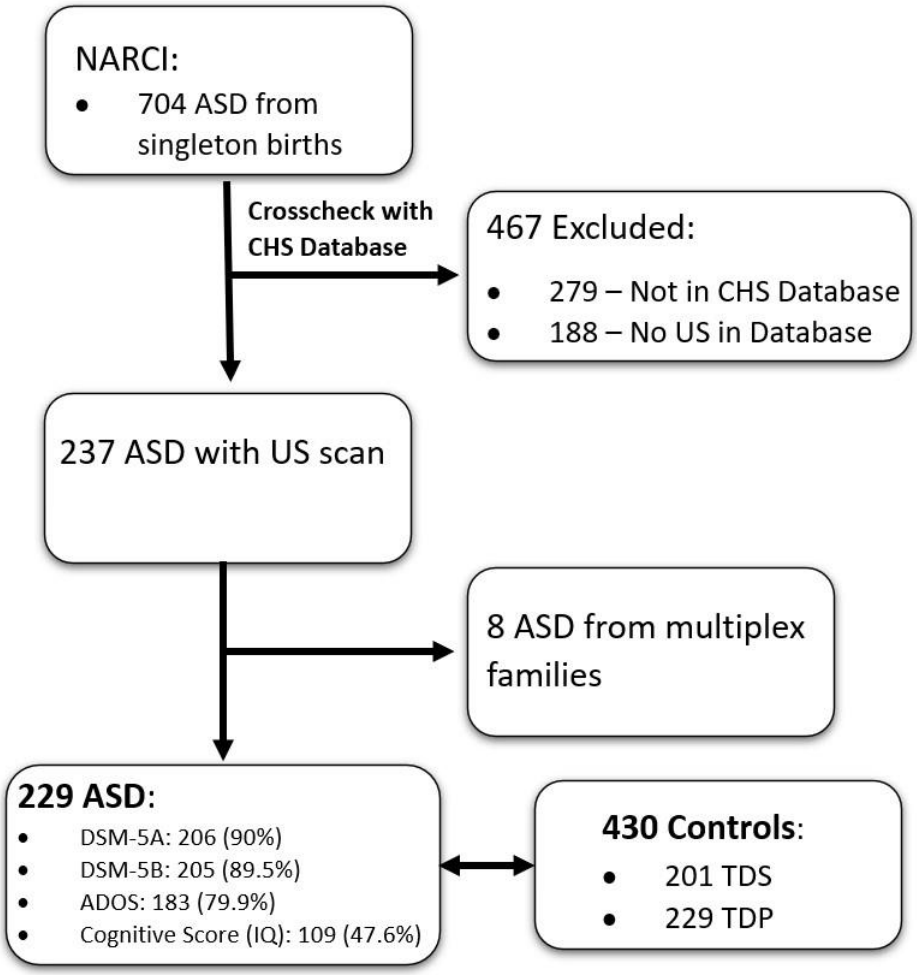

Figure 1. Flowchart of Children included in this Study.

medRxiv preprint doi: https://doi.org/10.1101/2021.07.20.21260824; this version posted July 22, 2021. The copyright holder for this preprint (which was not certified by peer review) is the author/funder, who has granted medRxiv a license to display the preprint in perpetuity. All rights reserved. No reuse allowed without permission.

Fetal Ultrasound Data

Fetal ultrasound data from the fetal anatomical survey, which is conducted during gestational weeks 20-24 in Israel, were obtained from all the prenatal ultrasound clinics of CHS in southern Israel. In these clinics, fetal anatomical surveys are performed by experienced physicians, who record fetal anomalies and biometric measures according to standard clinical guidelines. The anatomical survey includes a thorough examination of different anatomical landmarks according to the various body systems, including the head, brain, thorax, abdomen, spine, limbs, and umbilical cord. Abnormalities in each examined organ are classified as either structural anomalies or "soft markers."[34–37] In addition, the following biometric measures are recorded: head circumference (HC), biparietal diameter (BPD), abdominal circumference (AC), femur length (FL), cisterna magna size, cerebellar diameter, lateral ventricle width, and ocular distance.[34,45] The physician also assesses the fetal well-being according to a biophysical profile, which includes examination of the amniotic fluid index (AFI), breathing, movement, and tone, giving a score of 0–8.[46] For the current study, the gestational age (GA) of each fetus was calculated from the last menstrual period (LMP) and confirmed by the crown-rump length (CRL) from the ultrasound scan in the first trimester. If the date of LMP was unknown, GA was calculated based on CRL.

Statistical Analysis

We converted the basic biometric fetal measures (HC, BPD, AC, FL) to gestation-matched standardized Z-scores using the Hadlock approach,[47–49] the most widely used standardization approach in this field. In addition, the proportions of the ocular distance and of the cerebellum width out of the BPD were calculated (e.g., ocular distance * 100/ BPD) in light of the strong

medRxiv preprint doi: https://doi.org/10.1101/2021.07.20.21260824; this version posted July 22, 2021. The copyright holder for this preprint (which was not certified by peer review) is the author/funder, who has granted medRxiv a license to display the preprint in perpetuity. All rights reserved. No reuse allowed without permission.

relationships between these measures and head width. Differences in socio-demographic and clinical characteristics and in the proportion of anomalies between cases and each of the two matched control groups (TDS and TDP) were assessed using appropriate univariate statistics. Multivariable conditional regression or logistic regression models were used to assess the independent association of each ultrasound fetal measure/biomarker with ASD risk after adjusting for potential confounders. Finally, the association between clinical severity and fetal abnormalities was assessed using appropriate univariate statistics. P-values of analyses with multiple testing were adjusted using the Bonferroni correction. All analyses were conducted using SPSS Statistics V. 25 and R software. A two-sided test significance level of 0.05 was used throughout the entire study.

Results

Socio-Demographic and Clinical Characteristics

Clinical and socio-demographic characteristics of the study sample are shown in **Table 1**. The anatomic survey was performed at the gestational age of 22.85 ±1.7 weeks, with no significant differences between the groups. Similarly, there were no significant differences between the groups in all other clinical characteristics, except for the inherent male bias in the ASD group compared to their unaffected siblings (77.7% vs. 56.7%, respectively; p <0.001).

medRxiv preprint doi: https://doi.org/10.1101/2021.07.20.21260824; this version posted July 22, 2021. The copyright holder for this preprint (which was not certified by peer review) is the author/funder, who has granted medRxiv a license to display the preprint in perpetuity. All rights reserved. No reuse allowed without permission.

Table 1. Clinical and Sociodemographic Characteristics for Children included in this Study

Variable		ASD (n = 229)	TDS (n = 201)	TDP (n = 229)
Sociodemographic background				
Ethnicity (Jewish)	No. (%)	163(71.2)	141(70.1)	163(71.2)
	P[a]		1	1
Sex (male)	No. (%)	178(77.7)	114(56.7)	178(77.7)
	P[a]		**<0.001**	1
Pregnancy Details				
Mother's age (years)	Mean±SD	28.7±5.5	28.5±5.0	27.9±4.6
	P[b]		1	0164
Pregnancy number	Median (IQR)	2(1-3)	2(2-4)	2(1-3)
	P[c]		0.242	0.234
Previous abortions	Median (IQR)	0(0-1)	0(0-1)	0(0-0)
	P[c]		1	0.070
Gestational age at birth (weeks)	Mean±SD	38.8±2.5	39.1±1.9	39.2±1.6
	P[b]		0.496	0.188
C section	No. (%)	40(17.8)	27(14.4)	34(14.9)
	P[a]		0.696	0.818
Birth weight (g)	Mean±SD	3148 ±606	3163±593	3259±531
	P[b]		1	0.128
1-min low APGAR score (<7)	No. (%)	5(4.7)	5(5.6)	9(6.8)
	P[d]		1	0.966
US Details				
Gestation age assessed by last menstrual period	No. (%)	157(76.2)	130(75.6)	166(82.2)
	P[a]		1	0.276
Gestational age at US (weeks)	Mean±SD	22.9±1.9	22.7±1.8	22.9±1.5
	P[b]		0.412	1
Placenta position, No. (%)	Fundus	13(5.7)	13(6.8)	14(6.3)
	Front wall	124(54.6)	102(53.7)	109(48.7)
	Back wall	96(39.6)	74(38.9)	100(44.6)
	Placenta previa	0(0)	1(0.5)	1(0.4)
	P[a]		1	0.948
Placental grading	Median (IQR)	1(0-2)	1(0-2)	1(0-2)
	P[c]		1	0.578
Breech Presentation at US	No. (%)	74(32.9)	58(29.6)	59(26.1)
	P[a]		0.934	0.228
Normal amniotic fluid	No. (%)	222(97.4)	195(98.5)	219(97.8)
	P[d]		1	1
Weight at US (g)	Mean±SD	578±197	555±176	577±145
	P[b]		0.406	1

Note: Boldface type indicates $p<0.05$.

All p-values are Bonferroni corrected for multiple comparison (N=2).

ASD = autism spectrum disorder; TDS = typically developing siblings; TDP = typically developing population; US = ultrasound.

[a] Chi-square; [b] Two-sided t-test; [c] Mann-Whitney U test; [d] Fisher's Exact Test

medRxiv preprint doi: https://doi.org/10.1101/2021.07.20.21260824; this version posted July 22, 2021. The copyright holder for this preprint (which was not certified by peer review) is the author/funder, who has granted medRxiv a license to display the preprint in perpetuity. All rights reserved. No reuse allowed without permission.

Ultrasonography Fetal Anomalies (UFAs)

Case-control differences in UFAs are depicted in **Figure 2** and **Table 2**. Overall, UFAs were found in 67 (29.3%) of the ASD cases compared to only 32 (15.9%) and 22 (9.6%) in the TDS and TDP groups (aOR=2.23, 95%CI=1.32-3.78, and OR=3.50, 95%CI=2.07-5.91, respectively). In addition, more ASD cases had multiple anatomic anomalies than controls, with 7% of cases having multiple anatomic anomalies compared to only 2% of TDS and 0.9% of TDP controls (p=0.014 and p=0.001, respectively) (**Figure 2A**). Most UFAs in the ASD cases were seen in the urinary system and the heart (12.8% and 12.1%, respectively), followed by the head&brain (always taken together in this study; 5.7%), limbs (3.1%), blood vessels (2.7%), and gastrointestinal system (0.9%) (**Figure 2B**). Of note, cardiac UFAs were significantly associated with higher odds of an ASD diagnosis (aOR_{Heart}=3.72, 95%CI=1.50-9.24, and OR_{Heart}=8.67, 95%CI=2.62-28.63 compared to TDS and TDP, respectively). UFAs in the urinary system were also associated, although to a lesser extent, with elevated odds of an ASD diagnosis ($aOR_{Urinary}$ =2.08, 95%CI=0.96-4.50 and $OR_{Urinary}$=2.90, 95%CI=1.41–5.95 compared to TDS and TDP, respectively), with dilation of the renal pelvis (pyelectasis or hydronephrosis) being the most frequently detected anomaly. Finally, UFAs in the head&brain were significantly higher in the ASD cases compared to the TDP group but not to the TDS group ($OR_{Head\&Brain}$=6.50, 95%CI=1.47-28.80, and $aOR_{Head\&Brain}$=1.77, 95%CI=0.68-4.64, respectively). ASD cases also had higher rates of UFAs in most other organs examined in the study, although these differences did not reach statistical significance (**Table 2** and **Figure 2B**).

Common biometric measures evaluated during the ultrasound anatomic survey are presented in **eTable 2**. While ASD cases had significantly smaller (HC) and narrower (BPD) heads compared to TDP controls (OR_{HC}=0.76, 95%CI=0.62-0.93; OR_{BPD}=0.81, 95%CI=0.70-

medRxiv preprint doi: https://doi.org/10.1101/2021.07.20.21260824; this version posted July 22, 2021. The copyright holder for this preprint (which was not certified by peer review) is the author/funder, who has granted medRxiv a license to display the preprint in perpetuity. All rights reserved. No reuse allowed without permission.

0.94), their ocular distance, relative to their BPD, was significantly larger than that in TDP controls ($aOR_{Ocular\ Distance}$=1.29, 95%CI=1.06-1.57). ASD fetuses also had a lower biophysical profile than TDP fetuses (aOR=0.58, 95%CI=0.38-0.89), suggesting abnormal fetal neurodevelopment in the ASD cases. Finally, there were no significant differences in the sizes of the cisterna magna, cerebellum, or lateral ventricles between ASD fetuses and the two control groups.

Table 2. Anomalies in Different Fetal Organ Systems

Variable		Group [a]	No. (%)	Adjusted odds ratio (aOR)	95% CI	P-Value
Any fetal organ abnormality		ASD	67(29.3)	REF		
		TDS	32(15.9)	2.23	1.32-3.78	**0.006** [b]
		TDP	22(9.6)	3.50	2.07-5.91	**<0.001** [c]
Urinary system	**Total**	ASD	29(12.8)	REF		
		TDS	12(6.0)	2.08	0.96-4.50	0.126 [b]
		TDP	10(4.4)	2.90	1.41-5.95	**0.008** [c]
	Dilation of renal pelvis	ASD	26(11.5)	REF		
		TDS	12(6.0)	1.82	0.82-4.02	0.280 [b]
		TDP	10(4.4)	2.60	1.25-5.39	**0.020** [c]
	Bladder	ASD	1(0.4)	REF		
		TDS	0(0)	NA		1[d]
		TDP	0(0)	NA		0.994[d]
	Other malformation	ASD	2(0.9)	REF		
		TDS	0(0)	NA		1[d]
		TDP	0(0)	NA		0.494[d]
Heart	**Total**	ASD	27(12.1)	REF		
		TDS	7(3.5)	3.72	1.50-9.24	**0.010**[b]
		TDP	4(1.8)	8.67	2.62-28.63	**<0.001**[c]
	EIF	ASD	16(7.2)	REF		
		TDS	6(3)	3.35	1.21-9.28	**0.040** [b]
		TDP	1(0.4)	16.00	2.12-120.647	**0.014** [c]
	VSD	ASD	11(4.9)	REF		
		TDS	1(0.5)	5.80	0.67-50.18	0.220 [b]
		TDP	3(1.3)	5.00	1.10-22.82	0.076 [c]
Head & Brain	**Total**	ASD	13(5.7)	REF		
		TDS	8(4.0)	1.77	0.68-4.64	0.484[b]
		TDP	2(0.9)	6.50	1.47-28.80	**0.028** [c]
	Ventricles	ASD	4(1.8)	REF		
		TDS	2(1)	1.50	0.27-8.52	1[b]

medRxiv preprint doi: https://doi.org/10.1101/2021.07.20.21260824; this version posted July 22, 2021. The copyright holder for this preprint (which was not certified by peer review) is the author/funder, who has granted medRxiv a license to display the preprint in perpetuity. All rights reserved. No reuse allowed without permission.

		TDP	2(0.9)	2.00	0.37-10.92	0.846[c]
	Mega cisterna magna	ASD	2(0.9)	REF		
		TDS	1(0.6)	1.37	0.12-15.48	1[d]
		TDP	0(0)	NA		0.996[d]
	Choroid plexus cyst	ASD	5(2.3)	REF		
		TDS	2(1.2)	2.01	0.39-10.48	0.942[d]
		TDP	1(0.5)	1.71	0.84-3.50	0.284[c]
	Cerebellum	ASD	1(1.1)	REF		
		TDS	0(0)	NA		1[d]
		TDP	0(0)	NA		1[d]
	Skull	ASD	2(0.9)	REF		
		TDS	0(0)	NA		1[d]
		TDP	0(0)	NA		0.490[d]
	Microcephaly	ASD	2(0.9)	REF		
		TDS	2(1)	1.41	0.12-16.33	1[b]
		TDP	0(0)	NA		0.496[d]
Limbs	**Total**	ASD	7(3.1)	REF		
		TDS	5(2.5)	1.65	0.46-5.92	0.880[b]
		TDP	2(0.9)	3.50	0.73-16.85	0.236[c]
	Short femur	ASD	6(2.6)	REF		
		TDS	5(2.5)	1.39	0.36-5.29	1[b]
		TDP	2(0.9)	3.00	0.61-14.86	0.356[c]
	Other malformation	ASD	2(0.9)	REF		
		TDS	0(0)	NA		1[c]
		TDP	0(0)	NA		0.490[c]
Blood vessels	**Total**	ASD	6(2.7)	REF		
		TDS	3(1.5)	2.04	0.44-9.38	0.722[b]
		TDP	2(0.9)	3.00	0.61-14.86	0.356[c]
	Great arteries	ASD	1(0.5)	REF		
		TDS	0(0)	NA		1[d]
		TDP	0(0)	NA		0.980[d]
	Umbilical cord	ASD	5(2.2)	REF		
		TDS	3(1.5)	1.63	0.32-8.17	1[b]
		TDP	2(0.9)	2.50	0.49-12.89	0.546[c]
Gastrointestinal system	**Total**	ASD	2(0.9)	REF		
		TDS	1(0.5)	1.79	0.16-19.93	1[d]
		TDP	3(1.3)	0.67	0.11-3.99	1[c]
	Hyperechogenic bowel	ASD	2(0.9)	REF		
		TDS	1(0.5)	1.79	0.16-19.93	1[d]
		TDP	2(0.9)	1.00	0.14-7.10	1[c]
	Enlarged stomach	ASD	1(0.4)	REF		
		TDS	0(0)	NA		1[d]
		TDP	1(0.4)	1.00	0.06-15.99	1[c]

[a] ASD=229, TDS=201, TDP=229.
[b] Conditional logistic regression, adjusted to fetal sex; [c] Conditional logistic regression; [d] Fisher's Exact Test.
All p-values are Bonferroni corrected for multiple comparison (N=2).
EIF = echogenic intracardiac focus; **VSD** = ventricular septal defect.

medRxiv preprint doi: https://doi.org/10.1101/2021.07.20.21260824; this version posted July 22, 2021. The copyright holder for this preprint (which was not certified by peer review) is the author/funder, who has granted medRxiv a license to display the preprint in perpetuity. All rights reserved. No reuse allowed without permission.

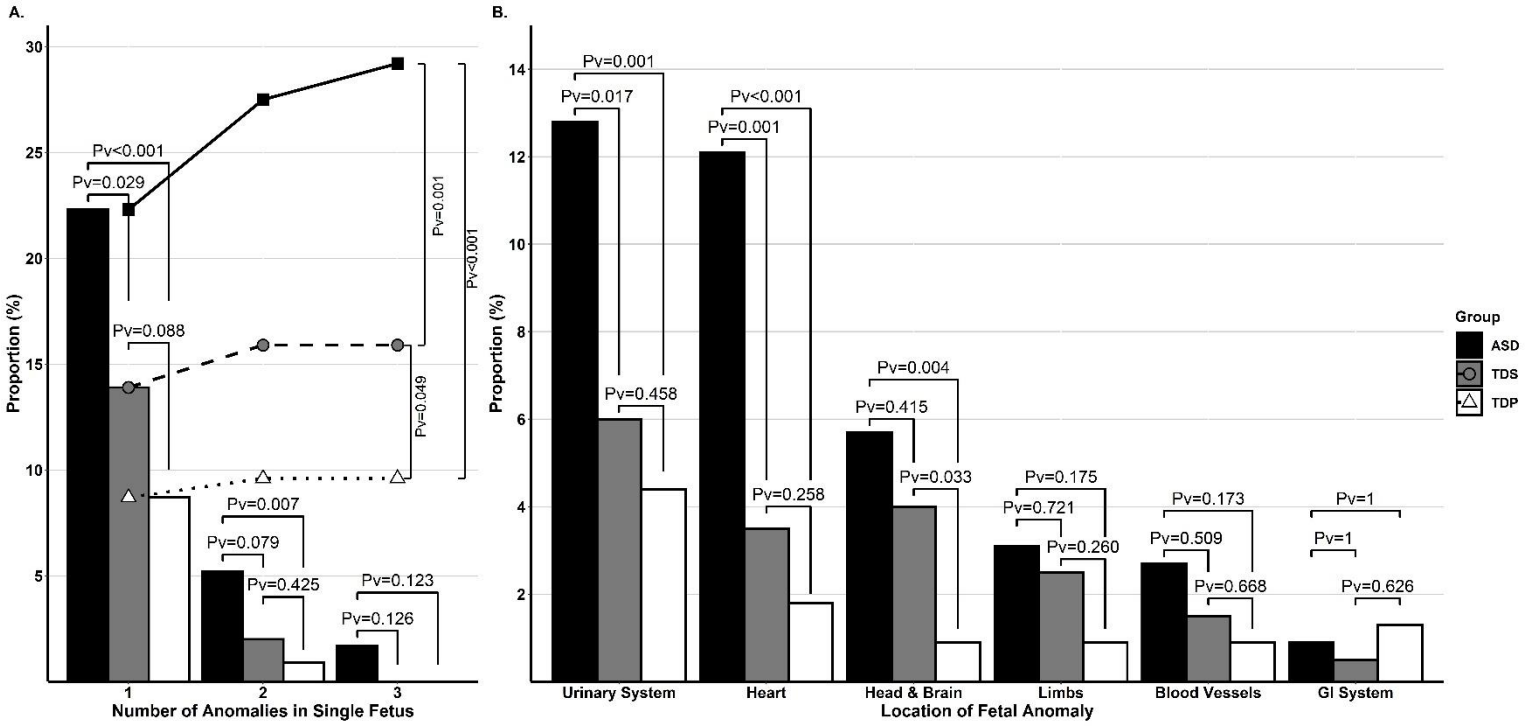

Figure 2: **Proportions of anomalies in different fetal organ systems**. (A.) Proportion of UFAs in each group. The bars represent the proportion of fetuses with 1,2, and 3 co-occurring UFAs. The lines with symbols represent the cumulative proportion of anomalies in each group: ASD (solid black line & black squares), TDS (dashed black line & gray circles), and TDP (dotted black line & white triangles). (B.) Proportion of UFAs in the different organs. Black bars –ASD; gray bars – TDS; white bars – TDP.

medRxiv preprint doi: https://doi.org/10.1101/2021.07.20.21260824; this version posted July 22, 2021. The copyright holder for this preprint (which was not certified by peer review) is the author/funder, who has granted medRxiv a license to display the preprint in perpetuity. All rights reserved. No reuse allowed without permission.

Association with ASD Severity

Finally, we examined the association between UFAs and biometric measures with the severity of ASD symptoms (**Table 3**). Overall, the presence of a UFA during gestation was associated with more severe ASD symptoms. The most significant associations were those between fetal cardiac anomalies and younger age at diagnosis (p=0.031), and between UFAs of the head&brain and DSM5-A criteria (p=0.017). Specifically, children for whom there were observable cardiac anomalies during gestation were diagnosed with ASD 6 months earlier than other children with ASD (33.6±11.7 vs. 39.4±16.5 months, p=0.031). Furthermore, children for whom there were observable head&brain UFAs were diagnosed as requiring more support than other children with ASD according to DSM5-A criteria.

Sensitivity analysis

The study sample included one randomly selected ASD case from each of the eight multiplex families in the study. We repeated all the reported analyses in this study using a sample that included the other ASD case in each family. The results of these analyses are reported in **eTables 3-5** and show the same differences in UFA rates between the study groups.

medRxiv preprint doi: https://doi.org/10.1101/2021.07.20.21260824; this version posted July 22, 2021. The copyright holder for this preprint (which was not certified by peer review) is the author/funder, who has granted medRxiv a license to display the preprint in perpetuity. All rights reserved. No reuse allowed without permission.

Table 3. Association between Clinical Severity and Fetal Abnormalities

Abnormality Type	Clinical Test		Abnormality Yes	Abnormality No	P-value
Any Fetal Organ Abnormality	**Cognitive score, mean (SD)**		73.18±15.8	76.97±14.2	0.218[a]
	Diagnosis age, months, mean (SD)		38.69±17.1	38.65±15.6	0.986[a]
	ADOS, median (IQR)		8(6-10)	8(6-9)	0.142[b]
	DSM5-A, No. (%)	RS	7(11.7)	9(6.2)	0.173[c]
		RSS	18(30)	61(41.8)	
		RVSS	35(58.3)	76(52.1)	
	DSM5-B, No. (%)	RS	6(10)	14(9.7)	0.671[c]
		RSS	30(50)	82(56.6)	
		RVSS	24(40)	49(33.8)	
Heart	**Cognitive score, mean (SD)**		73.80±15	75.95±14.2	0.623[b]
	Diagnosis age, months, mean (SD)		33.61±11.7	39.39±16.5	**0.031[a]**
	ADOS, median (IQR)		8.5(6-10)	8(6-9)	0.427[b]
	DSM5-A, No. (%)	RS	2(8.3)	14(7.9)	0.840[c]
		RSS	8(33.3)	70(39.5)	
		RVSS	14(58.3)	93(52.5)	
	DSM5-B, No. (%)	RS	1(4.2)	19(10.8)	0.393[c]
		RSS	16(66.7)	94(53.4)	
		RVSS	7(29.2)	63(35.8)	
Urinary System	**Cognitive score, mean (SD)**		74.92±16.8	75.96±14.6	0.694[b]
	Diagnosis age, months, mean (SD)		35.72±14.7	39.17±16.2	0.280[a]
	ADOS, median (IQR)		9(6-10)	8(6-9)	0.201[b]
	DSM5-A, No. (%)	RS	2(7.7)	14(7.9)	0.890[c]
		RSS	9(34.6)	70(39.3)	
		RVSS	15(57.7)	94(52.8)	
	DSM5-B, No. (%)	RS	4(15.4)	16(9)	0.341[c]
		RSS	11(42.3)	100(56.5)	
		RVSS	11(42.3)	61(34.5)	
Head & Brain	**Cognitive score, mean (SD)**		69.83±17.3	76.18±14.6	0.344[b]
	Diagnosis age, months, mean (SD)		41.78±15.7	38.47±16.0	0.373[b]
	ADOS, median (IQR)		8(6-10)	8(6-9)	0.643[b]
	DSM5-A, No. (%)	RS	3(23.1)	13(6.7)	**0.017[b]**
		RSS	1(7.7)	78(40.4)	
		RVSS	9(69.2)	102(52.8)	
	DSM5-B, No. (%)	RS	1(7.7)	19(9.9)	0.127[c]
		RSS	4(30.8)	108(56.3)	
		RVSS	8(61.5)	65(33.9)	

Each category includes all the abnormalities specified in Table 1.
[a] Two-sided t-test; [b] Mann-Whitney U test; [c] Chi-square. **RS** = Requiring Support; **RSS** = Requiring Substantial Support; **RVSS** = Requiring Very Substantial Support.

medRxiv preprint doi: https://doi.org/10.1101/2021.07.20.21260824; this version posted July 22, 2021. The copyright holder for this preprint (which was not certified by peer review) is the author/funder, who has granted medRxiv a license to display the preprint in perpetuity. All rights reserved. No reuse allowed without permission.

Discussion

This study is the first to comprehensively examine prenatal organ development in ASD children via an examination of the fetal ultrasound anatomic survey. We show that fetuses developing into children later diagnosed with ASD had significantly higher rates of UFAs compared to both their typically developing siblings and to matched typically developing children from the general population. These finding highlight the association of certain UFAs with ASD susceptibility of the developing fetus. These UFAs, which can be detected in standard prenatal anatomical ultrasound surveys conducted during mid-gestation, could form the basis of new prenatal screening approaches for ASD. The results of such prenatal screening will reveal fetuses at risk to develop ASD and may facilitate their earlier diagnosis, a factor that has already been shown to optimize the long-term outcomes of ASD treatment.[50–52]

Most of the identified UFAs were observed in the urinary system, heart, and head&brain, suggesting a shared etiology for the abnormal development of these organs in ASD. Dilation of the renal pelvis (pyelectasis or hydronephrosis) was the most prevalent UFA in the ASD cases in our study. This finding is consistent with the higher rates of pyelectasis in ASD fetuses compared with the prevalence of this anomaly in the general population.[26] Pyelectasis is considered a “soft marker” associated with an underlying fetal genetic risk[36,38] and may progress to a functional abnormality, such as hydronephrosis, that may require further treatment during childhood.[39] Furthermore, a number of genetic syndromes associated with ASD are characterized by various renal anomalies. For example, children with the 16q24.2 deletion or the17q12 microdeletion usually manifest both ASD and various congenital abnormalities of the kidney and urinary tract, including dilation of the renal pelvis,[30,31,53–55]; some of these congenital abnormalities could indeed be identified in prenatal ultrasound scans.[27–29,31] Another example is Phelan-McDermid

medRxiv preprint doi: https://doi.org/10.1101/2021.07.20.21260824; this version posted July 22, 2021. The copyright holder for this preprint (which was not certified by peer review) is the author/funder, who has granted medRxiv a license to display the preprint in perpetuity. All rights reserved. No reuse allowed without permission.

syndrome, caused by 22q13 deletion or by disruptive mutations in *SHANK3*, one of the most common monogenic causes of ASD, with renal abnormalities being found in 25–38% of children with this syndrome.[10,56]

As mentioned above, higher odds of an ASD diagnosis were significantly associated with cardiac UFAs, including echogenic intracardiac focus, which is considered a "soft marker" associated with various genetic anomalies,[36] and ventricular septal defect, which is a structural malformation that may progress to congenital heart disease (CHD) after birth.[4,33] Indeed, there is emerging evidence supporting a possible association between CHD and ASD, with several population-based studies reporting a higher risk of ASD in children with CHD.[4–6,8,12,15,57–59] Furthermore, recent findings from exome sequencing studies demonstrate a striking overlap between genes associated with ASD and CHD.[4,60] A genetic link between ASD and CHD can also be seen in several genetic syndromes associated with ASD; for example, approximately 3–25% of children with Phelan-McDermid syndrome also manifest various cardiac abnormalities,[10,56] and comorbidity of ASD and cardiac defects is also seen in children with the 22q11 deletion.[61,62]

Relatively high UFA rates were also seen for the head&brain. These UFAs consisted of anomalies in the cerebrospinal fluid (CSF) circulation, including choroid plexus cysts, enlarged lateral ventricles, and mega cisterna magna, suggesting abnormal development of CSF circulation in ASD. Indeed, increased pre- and postnatal ventricle volumes have been proposed as early structural markers of altered development of the cerebral cortex and increased risk for neuropsychiatric disorders, including ASD.[22,25,63] In addition, ventriculomegaly, enlarged cisterna magna, hydrocephalus, and increased extra-axial CSF were associated with ASD in multiple MRI and population-based studies.[7,22,25,63–67] Finally, children with 22q13 deletion

medRxiv preprint doi: https://doi.org/10.1101/2021.07.20.21260824; this version posted July 22, 2021. The copyright holder for this preprint (which was not certified by peer review) is the author/funder, who has granted medRxiv a license to display the preprint in perpetuity. All rights reserved. No reuse allowed without permission.

syndrome associated with ASD are characterized by abnormalities in the CSF circulation, including ventricle dilation, enlarged cisterna magna, and arachnoid cysts.[10,56,68]

Abnormalities in the CSF circulation in the extra-axial space may lead to an accumulation of CSF above the frontal lobes,[67] resulting in an abnormal and elongated (dolichocephalic) head shape, as revealed in this analysis and our previous smaller study.[20] In addition, ASD fetuses had relatively wider set eyes vs. the other fetuses in the cohort. This finding is in line with evidence from postnatal head image analysis demonstrating wide-set eyes in a subgroup of children with ASD.[69] Both dolichocephaly and wide-set eyes have been linked to several genetic anomalies associated with ASD, including copy-number variants in the 16p11.2[70] and 22q13[10,71,72] chromosomal loci and mutations in the *CHD8* gene.[73]

Our findings also suggest a positive association between fetal structural anomalies and ASD severity. Indeed, congenital anomalies have been shown to be more prevalent among individuals with autism and intellectual disability,[11] and ASD children with CHD or wider-set eyes have worse cognitive, language, and attention disabilities than other children with ASD.[12,58,69] In addition, ASD children with CHD usually also suffer from developmental delay and tend to be diagnosed earlier than most other children with ASD.[58] Furthermore, children with genetic syndromes that include both ASD and congenital malformations usually manifest additional cognitive and clinical impairments that lead to a more severe ASD outcome.[30,61,62]

This study is the first to systematically examine organogenesis in fetuses later developing into children with ASD by exploiting retrospectively the fetal ultrasound anatomic survey. The use of two distinct control groups, TDS and TDP, enabled us to adjust our findings to multiple familial and prenatal confounders that are known to have a considerable effect on both ASD risk

medRxiv preprint doi: https://doi.org/10.1101/2021.07.20.21260824; this version posted July 22, 2021. The copyright holder for this preprint (which was not certified by peer review) is the author/funder, who has granted medRxiv a license to display the preprint in perpetuity. All rights reserved. No reuse allowed without permission.

and fetal growth (e.g., sex[2,20] and shared genetics among siblings[1,74,75]), making our findings more compelling.

Study Limitations

The study has some limitations. There was a slight underrepresentation of Jews in the study sample, probably because Jewish parents tend to use private insurance to conduct a more comprehensive anatomical survey than that offered by the HMO. In addition, despite the large size of the study cohort, consisting of over 650 children, it still lacked sufficient statistical power to enable us to draw conclusions about rare UFAs (e.g., UFAs in the cerebellum, cisterna magna, great arteries, and gastrointestinal system) or about variables with a significant fraction of missing data such as biometric measures and clinical severity.

Conclusions

The association of UFAs with ASD, especially in the urinary system, heart, head, and brain, sheds important light on the abnormal multiorgan embryonic development of this complex disorder and suggests several fetal ultrasonography biomarkers for ASD. Thus, we conclude that the widely used prenatal anatomic survey is an excellent tool to identify fetuses with an ASD susceptibility.

Acknowledgements

We thank Mrs. Inez Mureinik for critical reviewing and editing of the manuscript.

medRxiv preprint doi: https://doi.org/10.1101/2021.07.20.21260824; this version posted July 22, 2021. The copyright holder for this preprint (which was not certified by peer review) is the author/funder, who has granted medRxiv a license to display the preprint in perpetuity. All rights reserved. No reuse allowed without permission.

This study was conducted as part of the requirements to obtain a degree in medicine from the Joyce & Irving Goldman Medical School, Faculty of Health Sciences, Ben-Gurion University of the Negev.

medRxiv preprint doi: https://doi.org/10.1101/2021.07.20.21260824; this version posted July 22, 2021. The copyright holder for this preprint (which was not certified by peer review) is the author/funder, who has granted medRxiv a license to display the preprint in perpetuity. All rights reserved. No reuse allowed without permission.

References

1. Kim YS, Leventhal BL. Genetic Epidemiology and Insights into Interactive Genetic and Environmental Effects in Autism Spectrum Disorders. *Biol Psychiatry*. 2015;77(1):66-74. doi:10.1016/j.biopsych.2014.11.001

2. Battle DE. Diagnostic and Statistical Manual of Mental Disorders (DSM). *CoDAS*. 2013;25(2):191-192. doi:10.1590/s2317-17822013000200017

3. Mannion A, Leader G. Comorbidity in autism spectrum disorder: A literature review. *Res Autism Spectr Disord*. 2013;7(12):1595-1616. doi:10.1016/j.rasd.2013.09.006

4. Sigmon ER, Kelleman M, Susi A, Nylund CM, Oster ME. Congenital Heart Disease and Autism: A Case-Control Study. *Pediatrics*. 2019;144(5):e20184114. doi:10.1542/peds.2018-4114

5. Wier ML, Odouli R, Yoshida CK, Grether JK, Croen LA. Congenital anomalies associated with autism spectrum disorders. *Dev Med Child Neurol*. 2007;48(6):500-507. doi:10.1111/j.1469-8749.2006.tb01303.x

6. Dizitzer Y, Meiri G, Flusser H, Michaelovski A, Dinstein I, Menashe I. Comorbidity and health services' usage in children with autism spectrum disorder: a nested case–control study. *Epidemiol Psychiatr Sci*. 2020;29:e95. doi:10.1017/S2045796020000050

7. Munch TN, Hedley PL, Hagen CM, et al. Co-occurring hydrocephalus in autism spectrum disorder: a Danish population-based cohort study. *J Neurodev Disord*. 2021;13(1):19. doi:10.1186/s11689-021-09367-0

medRxiv preprint doi: https://doi.org/10.1101/2021.07.20.21260824; this version posted July 22, 2021. The copyright holder for this preprint (which was not certified by peer review) is the author/funder, who has granted medRxiv a license to display the preprint in perpetuity. All rights reserved. No reuse allowed without permission.

8. Dawson S, Glasson EJ, Dixon G, Bower C. Birth Defects in Children With Autism Spectrum Disorders: A Population-based, Nested Case-Control Study. *Am J Epidemiol*. 2009;169(11):1296-1303. doi:10.1093/aje/kwp059

9. Ozgen HM, Hop JW, Hox JJ, Beemer FA, van Engeland H. Minor physical anomalies in autism: a meta-analysis. *Mol Psychiatry*. 2010;15(3):300-307. doi:10.1038/mp.2008.75

10. Soorya L, Kolevzon A, Zweifach J, et al. Prospective investigation of autism and genotype-phenotype correlations in 22q13 deletion syndrome and SHANK3 deficiency. *Mol Autism*. 2013;4(1):18. doi:10.1186/2040-2392-4-18

11. Timonen-Soivio L, Vanhala R, Malm H, et al. The association between congenital anomalies and autism spectrum disorders in a Finnish national birth cohort. *Dev Med Child Neurol*. 2015;57(1):75-80. doi:10.1111/dmcn.12581

12. Bean Jaworski JL, Flynn T, Burnham N, et al. Rates of autism and potential risk factors in children with congenital heart defects. *Congenit Heart Dis*. 2017;12(4):421-429. doi:10.1111/chd.12461

13. Newschaffer CJ, Croen LA, Daniels J, et al. The Epidemiology of Autism Spectrum Disorders. *Annu Rev Public Health*. 2007;28(1):235-258. doi:10.1146/annurev.publhealth.28.021406.144007

14. Deykin EY. Pregnancy, Delivery, and Neonatal Complications Among Autistic Children. *Arch Pediatr Adolesc Med*. 1980;134(9):860. doi:10.1001/archpedi.1980.02130210044012

medRxiv preprint doi: https://doi.org/10.1101/2021.07.20.21260824; this version posted July 22, 2021. The copyright holder for this preprint (which was not certified by peer review) is the author/funder, who has granted medRxiv a license to display the preprint in perpetuity. All rights reserved. No reuse allowed without permission.

15. Hultman CM, Sparén P, Cnattingius S. Perinatal Risk Factors for Infantile Autism. *Epidemiology*. 2002;13(4):417-423. doi:10.1097/00001648-200207000-00009

16. Rogers SJ. Diagnosis of autism before the age of 3. In: *International Review of Research in Mental Retardation*. Vol 23. Academic Press Inc.; 2000:1-31. doi:10.1016/S0074-7750(00)80004-X

17. Mizejewski GJ, Lindau-Shepard B, Pass KA. Newborn screening for autism: in search of candidate biomarkers. *Biomark Med*. 2013;7(2):247-260. doi:10.2217/bmm.12.108

18. Courchesne E. Evidence of Brain Overgrowth in the First Year of Life in Autism. *JAMA*. 2003;290(3):337. doi:10.1001/jama.290.3.337

19. Hazlett HC, Gu H, Munsell BC, et al. Early brain development in infants at high risk for autism spectrum disorder. *Nature*. 2017;542(7641):348-351. doi:10.1038/nature21369

20. Regev O, Cohen G, Hadar A, et al. Association Between Abnormal Fetal Head Growth and Autism Spectrum Disorder. *J Am Acad Child Adolesc Psychiatry*. 2020;0(0). doi:10.1016/j.jaac.2020.11.019

21. Courchesne E, Gazestani VH, Lewis NE. Prenatal Origins of ASD: The When, What, and How of ASD Development. *Trends Neurosci*. 2020;43(5):326-342. doi:10.1016/j.tins.2020.03.005

22. Fulceri F, Guzzetta A, Athanasiadou A, Iaconianni L, Scattoni ML. Antenatal ultrasound value in risk calculation for Autism Spectrum Disorder: A systematic review to support future research. *Neurosci Biobehav Rev*. 2018;92(April):83-92.

medRxiv preprint doi: https://doi.org/10.1101/2021.07.20.21260824; this version posted July 22, 2021. The copyright holder for this preprint (which was not certified by peer review) is the author/funder, who has granted medRxiv a license to display the preprint in perpetuity. All rights reserved. No reuse allowed without permission.

doi:10.1016/j.neubiorev.2018.05.016

23. Wang C, Geng H, Liu W, Zhang G. Prenatal, perinatal, and postnatal factors associated with autism. *Medicine (Baltimore)*. 2017;96(18):e6696. doi:10.1097/MD.0000000000006696

24. Courchesne E, Mouton PR, Calhoun ME, et al. Neuron Number and Size in Prefrontal Cortex of Children With Autism. *JAMA*. 2011;306(18):2001. doi:10.1001/jama.2011.1638

25. Gamliel M, Ebstein R, Yirmiya N, Mankuta D. Minor Fetal Sonographic Findings in Autism Spectrum Disorder. *Obstet Gynecol Surv*. 2012;67(3):176-186. doi:10.1097/OGX.0b013e31824bb5d6

26. Hobbs K, Kennedy A, DuBray M, et al. A Retrospective Fetal Ultrasound Study of Brain Size in Autism. *Biol Psychiatry*. 2007;62(9):1048-1055. doi:10.1016/j.biopsych.2007.03.020

27. Gilboa Y, Perlman S, Pode-Shakked N, et al. Prenatal diagnosis of 17q12 deletion syndrome: from fetal hyperechogenic kidneys to high risk for autism. *Prenat Diagn*. 2016;36(11):1027-1032. doi:10.1002/pd.4926

28. Jiang YL, Qi QW, Zhou XY, et al. [Prenatal diagnosis of 17q12 microdeletion syndrome in fetal renal abnormalities]. *Zhonghua Fu Chan Ke Za Zhi*. 2017;52(10):662-668. doi:10.3760/cma.j.issn.0529-567X.2017.10.004

29. Jing X-Y, Huang L-Y, Zhen L, Han J, Li D-Z. Prenatal diagnosis of 17q12 deletion syndrome: a retrospective case series. *J Obstet Gynaecol (Lahore)*. 2019;39(3):323-327.

medRxiv preprint doi: https://doi.org/10.1101/2021.07.20.21260824; this version posted July 22, 2021. The copyright holder for this preprint (which was not certified by peer review) is the author/funder, who has granted medRxiv a license to display the preprint in perpetuity. All rights reserved. No reuse allowed without permission.

doi:10.1080/01443615.2018.1519693

30. Handrigan GR, Chitayat D, Lionel AC, et al. Deletions in 16q24.2 are associated with autism spectrum disorder, intellectual disability and congenital renal malformation. *J Med Genet*. 2013;50(3):163-173. doi:10.1136/jmedgenet-2012-101288

31. Loirat C, Bellanné-Chantelot C, Husson I, Deschênes G, Guigonis V, Chabane N. Autism in three patients with cystic or hyperechogenic kidneys and chromosome 17q12 deletion. *Nephrol Dial Transplant*. 2010;25(10):3430-3433. doi:10.1093/ndt/gfq380

32. Ploeger A, Raijmakers MEJ, van der Maas HLJ, Galis F. The Association Between Autism and Errors in Early Embryogenesis: What Is the Causal Mechanism? *Biol Psychiatry*. 2010;67(7):602-607. doi:10.1016/j.biopsych.2009.10.010

33. Miller MT, Strömland K, Ventura L, Johansson M, Bandim JM, Gillberg C. Autism associated with conditions characterized by developmental errors in early embryogenesis: a mini review. *Int J Dev Neurosci*. 2005;23(2-3):201-219. doi:10.1016/j.ijdevneu.2004.06.007

34. Cargill Y, Morin L, Morin L, et al. Content of a Complete Routine Second Trimester Obstetrical Ultrasound Examination and Report. *J Obstet Gynaecol Canada*. 2009;31(3):272-275. doi:10.1016/S1701-2163(16)34127-5

35. Edwards L, Hui L. First and second trimester screening for fetal structural anomalies. *Semin Fetal Neonatal Med*. 2018;23(2):102-111. doi:10.1016/j.siny.2017.11.005

36. Van den Hof MC, Wilson RD, Bly S, et al. Fetal Soft Markers in Obstetric Ultrasound. *J*

medRxiv preprint doi: https://doi.org/10.1101/2021.07.20.21260824; this version posted July 22, 2021. The copyright holder for this preprint (which was not certified by peer review) is the author/funder, who has granted medRxiv a license to display the preprint in perpetuity. All rights reserved. No reuse allowed without permission.

Obstet Gynaecol Canada. 2005;27(6):592-612. doi:10.1016/S1701-2163(16)30720-4

37. Ali MK, Shazly SA, Ali AH, Abdelbadee AY, Abbas AM. Ultrasonographic soft markers of aneuploidy in second trimester fetuses. *Middle East Fertil Soc J*. 2012;17(3):145-151. doi:10.1016/j.mefs.2012.04.007

38. Wickstrom E, Thangavelu M, Parilla B, Tamura R, Sabbagha R. A prospective study of the association between isolated fetal pyelectasis and chromosomal abnormality. *Obstet Gynecol*. 1996;88(3):379-382. doi:10.1016/0029-7844(96)00211-6

39. Maizels M, Wang E, Sabbagha RE, et al. Late second trimester assessment of pyelectasis (SERP) to predict pediatric urological outcome is improved by checking additional features. *J Matern Neonatal Med*. 2006;19(5):295-303. doi:10.1080/14767050600553225

40. Chen C-P, Chern S-R, Tzen C-Y, et al. Prenatal diagnosis ofde novo distal 11q deletion associated with sonographic findings of unilateral duplex renal system, pyelectasis and orofacial clefts. *Prenat Diagn*. 2001;21(4):317-320. doi:10.1002/pd.42

41. Dinstein I, Arazi A, Golan HM, et al. The National Autism Database of Israel: a Resource for Studying Autism Risk Factors, Biomarkers, Outcome Measures, and Treatment Efficacy. *J Mol Neurosci*. 2020;70(9):1303-1312. doi:10.1007/s12031-020-01671-z

42. Meiri G, Dinstein I, Michaelowski A, et al. Brief Report: The Negev Hospital-University-Based (HUB) Autism Database. *J Autism Dev Disord*. 2017;47(9):2918-2926. doi:10.1007/s10803-017-3207-0

43. Lord C, Risi S, Lambrecht L, et al. The autism diagnostic observation schedule-generic: a

medRxiv preprint doi: https://doi.org/10.1101/2021.07.20.21260824; this version posted July 22, 2021. The copyright holder for this preprint (which was not certified by peer review) is the author/funder, who has granted medRxiv a license to display the preprint in perpetuity. All rights reserved. No reuse allowed without permission.

standard measure of social and communication deficits associated with the spectrum of autism. *J Autism Dev Disord*. 2000;30(3):205-223. doi:10.1023/A:1005592401947

44. Levaot Y, Meiri G, Dinstein I, Menashe I, Shoham-Vardi I. Autism Prevalence and Severity in Bedouin-Arab and Jewish Communities in Southern Israel. *Community Ment Health J*. 2019;55(1):156-160. doi:10.1007/s10597-018-0236-x

45. Seeds JW. The Routine or Screening Obstetrical Ultrasound Examination. *Clin Obstet Gynecol*. 1996;39(4):814-830. doi:10.1097/00003081-199612000-00010

46. Manning FA. Fetal Biophysical Profile. *Obstet Gynecol Clin North Am*. 1999;26(4):557-577. doi:10.1016/S0889-8545(05)70099-1

47. Hadlock FP, Deter RL, Harrist RB, Park SK. Estimating fetal age: computer-assisted analysis of multiple fetal growth parameters. *Radiology*. 1984;152(2):497-501. doi:10.1148/radiology.152.2.6739822

48. Hadlock FP, Deter RL, Harrist RB, Park SK. Fetal biparietal diameter: a critical re-evaluation of the relation to menstrual age by means of real-time ultrasound. *J Ultrasound Med*. 1982;1(3):97-104. doi:10.7863/jum.1982.1.3.97

49. Hadlock F, Deter R, Harrist R, Park S. Fetal head circumference: relation to menstrual age. *Am J Roentgenol*. 1982;138(4):649-653. doi:10.2214/ajr.138.4.649

50. Estes A, Munson J, Rogers SJ, Greenson J, Winter J, Dawson G. Long-Term Outcomes of Early Intervention in 6-Year-Old Children With Autism Spectrum Disorder. *J Am Acad Child Adolesc Psychiatry*. 2015;54(7):580-587. doi:10.1016/j.jaac.2015.04.005

medRxiv preprint doi: https://doi.org/10.1101/2021.07.20.21260824; this version posted July 22, 2021. The copyright holder for this preprint (which was not certified by peer review) is the author/funder, who has granted medRxiv a license to display the preprint in perpetuity. All rights reserved. No reuse allowed without permission.

51. Lazaratou H, Economou M, Dikeos D. The necessity of early intervention in autism. *J Pediatr*. 2017;184:240-241. doi:10.1016/j.jpeds.2016.12.030

52. Zwaigenbaum L, Bauman ML, Choueiri R, et al. Early Intervention for Children With Autism Spectrum Disorder Under 3 Years of Age: Recommendations for Practice and Research. *Pediatrics*. 2015;136(Supplement):S60-S81. doi:10.1542/peds.2014-3667E

53. Mitchel MW, Moreno-De-Luca D, Myers SM, Finucane B, Ledbetter DH, Martin CL. *17q12 Recurrent Deletion Syndrome*. University of Washington, Seattle; 1993. http://www.ncbi.nlm.nih.gov/pubmed/27929632. Accessed April 14, 2019.

54. Moreno-De-Luca D, Mulle JG, Kaminsky EB, et al. Deletion 17q12 Is a Recurrent Copy Number Variant that Confers High Risk of Autism and Schizophrenia. *Am J Hum Genet*. 2010;87(5):618-630. doi:10.1016/j.ajhg.2010.10.004

55. Clissold RL, Shaw-Smith C, Turnpenny P, et al. Chromosome 17q12 microdeletions but not intragenic HNF1B mutations link developmental kidney disease and psychiatric disorder. *Kidney Int*. 2016;90(1):203-211. doi:10.1016/j.kint.2016.03.027

56. Phelan K, McDermid HE. The 22q13.3 Deletion Syndrome (Phelan-McDermid Syndrome). *Mol Syndromol*. 2011. doi:10.1159/000334260

57. Razzaghi H, Oster M, Reefhuis J. Long-Term Outcomes in Children with Congenital Heart Disease: National Health Interview Survey. *J Pediatr*. 2015;166(1):119-124.e1. doi:10.1016/j.jpeds.2014.09.006

58. Tsao P-C, Lee Y-S, Jeng M-J, et al. Additive effect of congenital heart disease and early

medRxiv preprint doi: https://doi.org/10.1101/2021.07.20.21260824; this version posted July 22, 2021. The copyright holder for this preprint (which was not certified by peer review) is the author/funder, who has granted medRxiv a license to display the preprint in perpetuity. All rights reserved. No reuse allowed without permission.

developmental disorders on attention-deficit/hyperactivity disorder and autism spectrum disorder: a nationwide population-based longitudinal study. *Eur Child Adolesc Psychiatry*. 2017;26(11):1351-1359. doi:10.1007/s00787-017-0989-8

59. Calderon J, Bellinger DC, Newburger JW. Autism and Congenital Heart Disease: Evidence and Unresolved Questions. *Pediatrics*. 2019;144(5):e20192752. doi:10.1542/peds.2019-2752

60. Jin SC, Homsy J, Zaidi S, et al. Contribution of rare inherited and de novo variants in 2,871 congenital heart disease probands. *Nat Genet*. 2017;49(11):1593-1601. doi:10.1038/ng.3970

61. Niklasson L, Rasmussen P, Óskarsdóttir S, Gillberg C. Autism, ADHD, mental retardation and behavior problems in 100 individuals with 22q11 deletion syndrome. *Res Dev Disabil*. 2009;30(4):763-773. doi:10.1016/j.ridd.2008.10.007

62. Ousley O, Rockers K, Dell ML, Coleman K, Cubells JF. A review of neurocognitive and behavioral profiles associated with 22q11 deletion syndrome: Implications for clinical evaluation and treatment. *Curr Psychiatry Rep*. 2007;9(2):148-158. doi:10.1007/s11920-007-0085-8

63. Gilmore JH, Smith LC, Wolfe HM, et al. Prenatal Mild Ventriculomegaly Predicts Abnormal Development of the Neonatal Brain. *Biol Psychiatry*. 2008;64(12):1069-1076. doi:10.1016/j.biopsych.2008.07.031

64. Piven J, Arndt S, Bailey J, Havercamp S, Andreasen NC, Palmer P. An MRI study of brain size in autism. *Am J Psychiatry*. 1995;152(8):1145-1149.

medRxiv preprint doi: https://doi.org/10.1101/2021.07.20.21260824; this version posted July 22, 2021. The copyright holder for this preprint (which was not certified by peer review) is the author/funder, who has granted medRxiv a license to display the preprint in perpetuity. All rights reserved. No reuse allowed without permission.

doi:10.1176/ajp.152.8.1145

65. Erbetta A, Bulgheroni S, Contarino VE, et al. Low-Functioning Autism and Nonsyndromic Intellectual Disability. *J Child Neurol*. 2015;30(12):1658-1663. doi:10.1177/0883073815578523

66. Shen MD, Nordahl CW, Li DD, et al. Extra-axial cerebrospinal fluid in high-risk and normal-risk children with autism aged 2–4 years: a case-control study. *The Lancet Psychiatry*. 2018;5(11):895-904. doi:10.1016/S2215-0366(18)30294-3

67. Dinstein I, Shelef I. Anatomical brain abnormalities and early detection of autism. *The Lancet Psychiatry*. 2018;5(11):857-859. doi:10.1016/S2215-0366(18)30355-9

68. Aldinger KA, Kogan J, Kimonis V, et al. Cerebellar and posterior fossa malformations in patients with autism-associated chromosome 22q13 terminal deletion. *Am J Med Genet Part A*. 2013;161(1):131-136. doi:10.1002/ajmg.a.35700

69. Aldridge K, George ID, Cole KK, et al. Facial phenotypes in subgroups of prepubertal boys with autism spectrum disorders are correlated with clinical phenotypes. *Mol Autism*. 2011;2(1):15. doi:10.1186/2040-2392-2-15

70. Qiu Y, Arbogast T, Lorenzo SM, et al. Oligogenic Effects of 16p11.2 Copy-Number Variation on Craniofacial Development. *Cell Rep*. 2019;28(13):3320-3328.e4. doi:10.1016/j.celrep.2019.08.071

71. Goizet C, Excoffier E, Taine L, et al. Case with autistic syndrome and chromosome 22q13.3 deletion detected by FISH. *Am J Med Genet*. 2000;96(6):839-844.

medRxiv preprint doi: https://doi.org/10.1101/2021.07.20.21260824; this version posted July 22, 2021. The copyright holder for this preprint (which was not certified by peer review) is the author/funder, who has granted medRxiv a license to display the preprint in perpetuity. All rights reserved. No reuse allowed without permission.

doi:10.1002/1096-8628(20001204)96:6<839::AID-AJMG29>3.0.CO;2-R

72. Cusmano-Ozog K, Manning MA, Hoyme HE. 22q13.3 deletion syndrome: A recognizable malformation syndrome associated with marked speech and language delay. *Am J Med Genet Part C Semin Med Genet*. 2007;145C(4):393-398. doi:10.1002/ajmg.c.30155

73. Bernier R, Golzio C, Xiong B, et al. Disruptive CHD8 Mutations Define a Subtype of Autism Early in Development. *Cell*. 2014;158(2):263-276. doi:10.1016/j.cell.2014.06.017

74. La Batide-Alanore A. Familial Aggregation of Fetal Growth Restriction in a French Cohort of 7,822 Term Births between 1971 and 1985. *Am J Epidemiol*. 2002;156(2):180-187. doi:10.1093/aje/kwf002

75. Sandin S, Lichtenstein P, Kuja-Halkola R, Larsson H, Hultman CM, Reichenberg A. The Familial Risk of Autism. *JAMA*. 2014;311(17):1770. doi:10.1001/jama.2014.4144