Early management of severe COVID-19 coagulopathy should be guided by TEG®, microclot and platelet mapping

Gert Jacobus Laubscher[1], Petrus Johannes Lourens[1], Chantelle Venter[2], Douglas B Kell[2,3,4*], Etheresia Pretorius[2*]

[1] Mediclinic Stellenbosch, Elsie du Toit street, Stellenbosch 7600, South Africa.

[2] Department of Physiological Sciences, Faculty of Science, Stellenbosch University, Stellenbosch, Private Bag X1 Matieland, 7602, South Africa.

[3] Department of Biochemistry and Systems Biology, Institute of Systems, Molecular and Integrative Biology, Faculty of Health and Life Sciences, University of Liverpool, L69 7ZB, UK.

[4] The Novo Nordisk Foundation Centre for Biosustainability, Technical University of Denmark, Kemitorvet 200, 2800 Kgs Lyngby, Denmark.

***Corresponding authors:**

***Etheresia Pretorius**

Department of Physiological Sciences, Stellenbosch University, Private Bag X1 Matieland, 7602, SOUTH AFRICA
resiap@sun.ac.za
http://www.resiapretorius.net/
ORCID: 0000-0002-9108-2384

***Douglas B. Kell**

Department of Biochemistry and Systems Biology, Institute of Systems, Molecular and Integrative Biology, Faculty of Health and Life Sciences, University of Liverpool, L69 7ZB, UK.
dbk@liv.ac.uk

ORCID: 0000-0001-5838-7963

Email addresses of authors:

GJ Laubscher: laubscher911@gmail.com
PJ Lourens: wodie@iafrica.com
E Pretorius: resiap@sun.ac.za
C Venter: chantellev@sun.ac.za
DB Kell: dbk@liv.ac.uk

Abstract

An important component of severe COVID-19 disease is virus-induced endothelilitis. This leads to disruption of normal endothelial function, initiating a state of failing normal clotting physiology. Massively increased levels of von Willebrand Factor (VWF) lead to overwhelming platelet activation, as well as activation of the enzymatic (intrinsic) clotting pathway. In addition, there is an impaired fibrinolysis, caused by, amongst others, increased levels of alpha-(2) antiplasmin. The end result is hypercoagulation [proven by thromboelastography® (TEG®)] and reduced fibrinolysis, inevitably leading to a difficult-to-overcome hypercoagulated physiological state. Platelets in circulation also plays a significant role in clot formation, but themselves may also drive hypercoagulation when they are overactivated due to the interactions of their receptors with the endothelium, immune cells or circulating inflammatory molecules. From the literature it is clear that the role of platelets in severely ill COVID-19 patients has been markedly underestimated or even ignored. We here highlight the value of early management of severe COVID-19 coagulopathy as guided by TEG®, microclot and platelet mapping. We also argue that the failure of clinical trials, where the efficacy of prophylactic versus therapeutic clexane (low molecular weight heparin (LMWH)) were not always successful, might be because the significant role of platelet activation was not taken into account during the planning of the trial. We conclude that, because of the overwhelming alteration of clotting, the outcome of any trial evaluating an any single anticoagulant, including thrombolytic, would be negative. Here we suggest the use of the degree of platelet dysfunction and presence of microclots in circulation, together with TEG®, should be used as a guideline for disease severity. A multi-pronged approach, guided by TEG® and platelet mapping, would be required to maintain normal clotting physiology in severe COVID-19 disease.

Keywords: COVID-19; Consumptive coagulopathy; Platelets; Blood clotting; fibrinolysis; von Willebrand Factor.

Introduction

The coronavirus disease 2019 (COVID-19) caused by the SARS-Cov-2 virus has led to a worldwide, sudden and substantial increase in hospitalizations for pneumonia with multi-organ problems [1-3]. Severe cases of COVID-19 are almost inevitably accompanied by respiratory failure and hypoxia, and treatment includes best practices for supportive management of acute hypoxic respiratory failure [1]. Although, initially thought to be a typical viral pneumonia with acute disseminated intravascular coagulopathy (DIC), it has now been accepted that COVID-19 is primarily an endothelial disease [4] and vascular disease [5]. Endotheliopathy plays a significant role in the severity of COVID-19 [4-11]. Endotheliopathy is also known to be significantly linked to coagulopathies, as it activates microthrombotic pathways and initiates microthrombogenesis, leading to endotheliopathy-associated intravascular microthrombi [12].

Approximately 20% of COVID-19 patients rapidly progress to severe illness characterized by atypical interstitial bilateral pneumonia, acute respiratory distress syndrome and multi-organ dysfunction [9]. It was also shown that one-third of patients hospitalized due to severe COVID-19 develop macrovascular thrombotic complications, including venous thromboembolism, stroke and myocardial injury/infarction [13]. Patients also suffer from right ventricular dilation of the heart [14-16]. Autopsies from COVID-19 patients also revealed multi-organ damage pattern consistent with microvascular injury [11, 13]. Furthermore, autopsy results have also confirmed microthrombi throughout the lung [17]. In 2020, Ackermann and co-workers reported that histologic analysis of pulmonary vessels in patients with COVID-19 showed widespread thrombosis with microangiopathy [8]. The authors also found that alveolar capillary microthrombi were nine times as prevalent in patients with COVID-19 as in patients with influenza ($p<0.001$) [8]. In autopsy samples of lungs from patients with COVID-19, the amount of new vessel growth - predominantly through a mechanism of intussusceptive angiogenesis (i.e. splitting of an existing vessel where the capillary wall extends into the lumen of an existing vessel) - was 2.7 times as high as that in the lungs from patients with influenza ($p<0.001$) [8]. Middleton and co-workers showed the presence of neutrophil extracellular traps (NETs) in lung autopsy results, and suggested that these may be the cause of immune-thrombosis and may, in part, explain the prothrombotic clinical presentations in COVID-19 [18]. Menter and co-workers also showed autopsy findings from 21 COVID-19 patients, and reported that the primary cause of death was respiratory failure, with exudative diffuse alveolar damage and massive capillary congestion, often accompanied by microthrombi despite anticoagulation therapy [19]. A possible reason might be because the extent of systemic hypercoagulation was too significant for the medication to have a substantial enough effect. Hypercoagulability, resulting in a profoundly prothrombotic state, is a distinct feature of the early stages of COVID-19 and is accentuated by a high incidence of fibrinolysis shutdown

[20-30]. We have also recently shown that in COVID-19, the clotting protein fibrin(ogen) changes to an amyloid form, that platelets are hyperactivated, and that they form complexes with erythrocytes [21, 22]. Fibrinogen is the soluble clotting protein, but during the presence of circulating inflammatory molecules, these molecules (including inflammagens from viruses and bacteria) may bind to the protein, causing some of these molecules to polymerize into fibrin hence the use of the term fibrin(ogen), that suggests the presence of both soluble and polymerized clotting protein molecules in circulation [31-33]. Proteomics also revealed that there are significantly dysregulated clotting proteins in microclots, including significant increases in the molecule α-(2)-antiplasmin, which prevents fibrinolysis [23].

Disseminated intravascular coagulopathy (DIC) and COVID-19: an uncommon phenomenon?

From the vast literature in COVID-19 and clotting, it is now well-accepted that coagulopathies occur in the majority of patients who die from COVID-19 [34, 35], and that DIC severe bleeding events are uncommon in COVID-19 patients [11]. However, COVID-19 can be complicated by DIC, which has a strongly prothrombotic character with a high risk of venous thromboembolism [26]. A report from Wuhan, China, indicated that 71% of 183 individuals who died of COVID-19 met criteria for DIC [1, 34]. Spiezia and co-workers argued in most COVID-19 patient's high D-dimer levels are associated with a worse prognosis [36]. The authors also suggest that COVID-19 patients with acute respiratory failure represent the consequence of severe hypercoagulability, that when left untreated results in consumptive coagulopathy [end-stage (DIC)] and that excessive fibrin formation and polymerization may predispose to thrombosis and correlate with a worse outcome [36]. Consumptive coagulopathy is characterized by abnormally increased activation of procoagulant pathways. This results in intravascular fibrin deposition and decreased levels of hemostatic components, including platelets, fibrinogen, and other clotting factors. DIC results in bleeding and intravascular thrombus formation that can lead to tissue hypoxia, multiorgan dysfunction, and death [37]. It is therefore worth noting that DIC is a thrombotic coagulopathy that eventually leads to bleeding. However, in COVID-19, DIC (as defined by the ISTH or other bodies) is an uncommon phenomenon.

The progression of the disease, if untreated is a two-phase 'rollercoaster' of events, characterized by thrombotic pathology followed by bleeding or thrombocytopenia pathologies

In 2020, Aigner and co-workers suggested that there should be four strategies in approaching COVID-19 treatment [38]: 1) antiviral treatments to limit the entry of the virus into the cell, (2) anti-inflammatory treatment to reduce the impact of COVID-19 associated inflammation and

cytokine storm, (3) treatment using cardiovascular medication to reduce COVID-19 associated thrombosis and vascular damage, and (4) treatment to reduce the COVID-19 associated lung injury. As we have learnt more about the disease, we now know that the cytokine storm (followed by bleeding) is only a concern if the disease is left untreated. In 2020 we presented evidence that COVID-19 can be seen as a two-phase 'rollercoaster' of events, characterized by serial (i) thrombotic and (ii) bleeding or thrombocytopenia pathologies [39]. These substantial vascular events are significant accompaniments to ARDS and lung complications and both vascular events are seen in COVID-19 patients [40-46]. Clearly these coagulopathies seem to represent polar opposites, and it might be seen as odd if both are said to accompany COVID-19 pathology; the resolution of the apparent paradox is that these coagulopathies can be differentiated in time. Figure 1 shows the fine balance during COVID-19, between these biomarkers and the development of initial hyperclotting and thrombosis that can be followed by a consumptive coagulopathy, thrombocytopenia and bleeding; the latter is followed by the cytokine storm (at the end stage of the disease) [39]. Depending on the direction (i.e, increases or decreases), dysregulation of fibrin(ogen), D-dimer, von Willebrand Factor (VWF) and P-selectin may result in either hypercoagulation or excessive bleeding and thrombocytopenia (hypocoagulation). We suggested that patients need to be treated early in the disease progression, when hypercoagulation is clinically diagnosed (discussed later in the treatment protocol). Early in the hypercoagulation phase of the disease, high levels of VWF, P-selectin and fibrinogen are present, but that there are still normal or slightly increased levels of D-dimer. If the disease is left to progress until the patient presents with VWF and fibrinogen depletion, and with high D-dimer levels (and even higher P-selectin levels), it will be indicative of a poor prognosis, an imminent cytokine storm, and ultimately death. This rollercoaster disease progression is a continuum and the progression of disease has no specific tipping point (Figure 1). In a 2020 JAMA editorial, the question was also asked whether the cytokine storm should be seen as significantly relevant in COVID-19, and it was referred to as "tempest in a teapot" [47]. The basis for this conclusion was that the presence of elevated circulating mediators in the claimed cytokine storm are likely to reflect endothelial dysfunction and systemic inflammation leading to fever, tachycardia, tachypnea, and hypotension [47], rather than the more immediately lethal ARDS. The JAMA editorial concluded by suggesting that incorporating the cytokine storm may only further increase uncertainty about how best to manage this heterogeneous population of patients [47]. Our rollercoaster diagram (Figure 1) also notes that increased levels of inflammatory cytokines will already start early in the disease [39].

Figure 1: The rollercoaster vascular pathology in acute respiratory syndrome coronavirus 2 (COVID-19) [adapted from [39]]. We focus on fibrin(ogen), D-Dimer, P-selectin and von Willebrand Factor dysregulation, resulting in endothelial, erythrocyte and platelet dysfunction. **A)** Early on in the disease dysregulation in clotting proteins and circulating biomarkers may occur and is suggestive of hypercoagulation. **B)** The disease may progress to bleeding and thrombocytopenia. **C)** We suggest that each patient should be treated using a personalized medicine approach in the early stages of the disease. Image created with BioRender (https://biorender.com/).

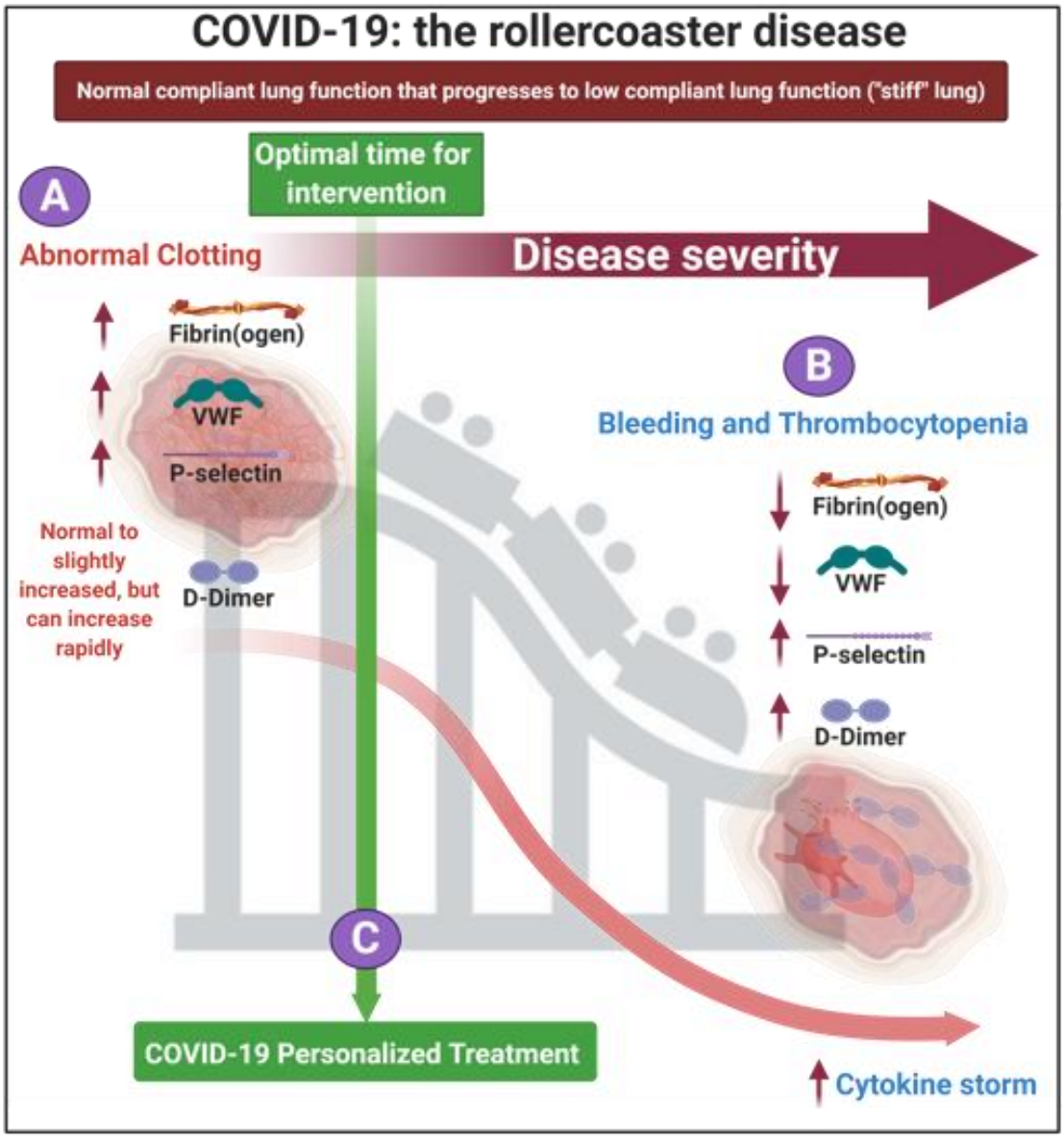

During the progression of COVID-19, the circulating biomarkers P-selectin, VWF, fibrin(ogen) and D-dimer may either be within healthy levels, upregulated or eventually depleted [21, 22]. In COVID-19 patients, dysregulation, has been noted in each of them and this may lead to the extensive endotheliopathy noted in COVID-19 patients [8, 48, 49] (see Table 1). Endotheliopathy could give rise to hypercoagulation by alteration in the levels of different factors such as VWF [10].

Table 1: Dysregulation of circulating biomarkers P-selectin, von Willebrand Factor, fibrin(ogen) and D-dimer in COVID-19. See Figure 1 for levels during COVID-19.

Circulating biomarker	Selected references
P-selectin	[7, 50]
Fibrinogen and D-dimer	[36, 40, 43, 45, 51-57]
Von Willebrand Factor	[17, 35, 58, 59]

With the above-mentioned pathologies in mind, we here argue that the early treating of COVID-19 disease as a vascular and endothelial disease with severe platelet dysfunction and microclot formation, early on in the disease, provides a framework for a rational treatment strategy. We review literature on the use of point-of-care equipment like the thromboelastography® (TEG®) and the PFA200, to manage patient with COVID-19. We also suggest the use of the degree of platelet dysfunction and presence of microclots in circulation, using fluorescence microscopy, as a guideline for disease severity.

A place for existing point-of care techniques to guide COVID-19 treatment

Thromboelastometry (TEM), also known as rotational thromboelastography (ROTEG) or rotational thromboelastometry (ROTEM), is an established viscoelastic method for haemostasis testing. It is a modification of traditional TEG®. These techniques are crucial point-of-care techniques that we suggest should be used to guide the treatment of COVID-19 patients. Spiezia and colleagues also noted that COVID-19 patients with acute respiratory failure present with severe hypercoagulability due to hyperfibrinogenemia, resulting in increased polymerized fibrin cross-linking formation that may predispose the patient to thrombosis. Spiezia and co-workers also concluded that thromboelastometry is an important point-of-care test in COVID-19, as it has the advantage of providing a global assessment of whole blood's ability to clot. On the other hand, it is not able to evaluate the contribution to clot formation of each element (including endothelium, platelets, and clotting factors). In 2020, Wright and co-workers also discussed the use of clot lysis at 30 minutes (LY30) on the TEG® as point-of-care analysis method [44]. The LY30 parameter (measured in %) is recorded at 30 minutes after the point where the maximum amplitude (MA) of the clot is reached (see Figure 2). LY30 of 3% or greater defines clinically relevant hyperfibrinolysis [60]. The TEG® results, particularly an increased MA and G-score (that both measures maximal clot strength) is used to predict thromboembolic events and a poor outcome in critically ill patients with COVID-19 [44]. MA is of great significance as it represents clot size (see Figure 2), as determined by platelet number and function, as well as polymerized fibrin cross-linking to form a stable clot.

Recently, various papers have shown the significance of TEG®, and the levels of coagulopathy in COVID-19 (an important measurement value of the TEG®) in managing COVID-19 patients is also getting more traction [61-64]. Hranjec and co-workers in 2020 also noted that TEG®

with platelet mapping, better characterizes the spectrum of COVID-19 coagulation-related abnormalities and may guide more tailored, patient-specific therapies these patients [63]. Another important test is the PFA-200 platelet test. This test may be seen as a cross between bleeding time and quick aggregation testing. See Table 2 for the various parameters for the TEG® and PFA-200.

Figure 2: TEG® traces with the various parameters discussed in Table 2, visualized. **A)** Healthy (normocotgulable) trace; **B)** Hypercoagulable trace and **C)** Hypocoagulable trace. Image created with BioRender (https://biorender.com/).

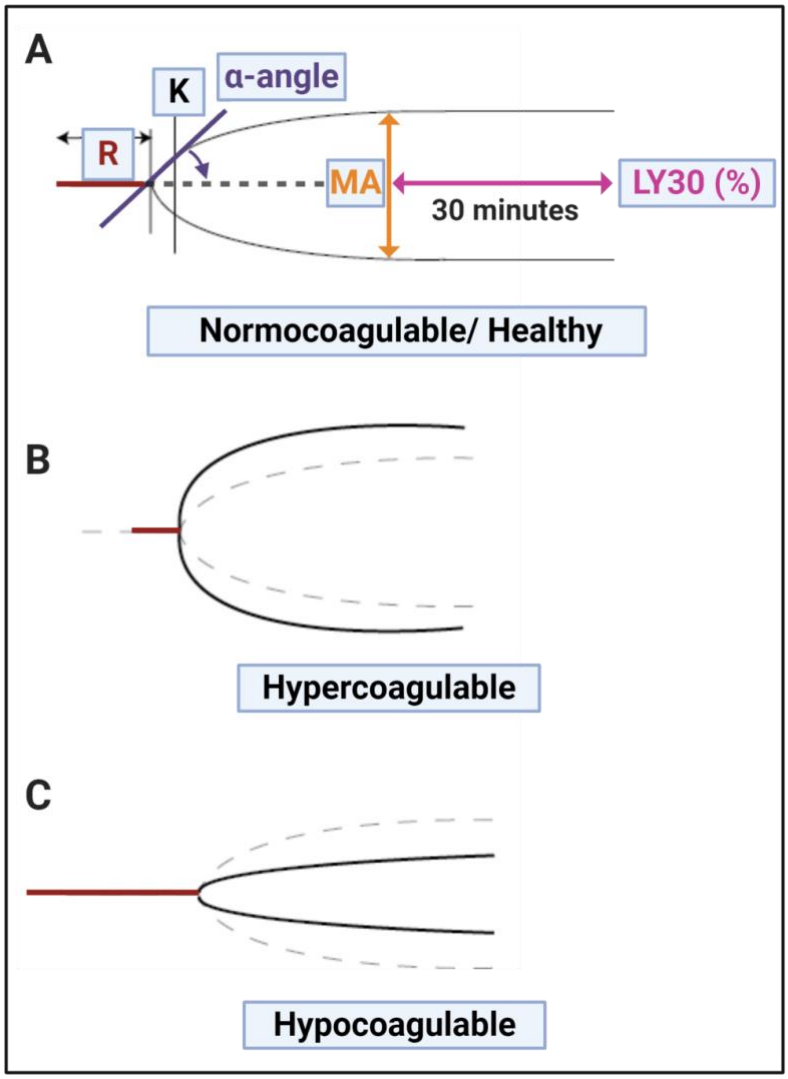

Table 2: Thromboelastography® (TEG®) clot parameters for whole blood and PFA-200 platelet parameters.

Thromboelastography®	
TEG® parameters	**Explanation**
R value: reaction time measured in minutes	Time of latency from start of test to initial fibrin formation (amplitude of 2mm); i.e. initiation time.
K: kinetics measured in minutes	Time taken to achieve a certain level of clot strength (amplitude of 20mm); i.e. amplification.
A (Alpha): Angle (slope between the traces represented by R and K) Angle is measured in degrees	The angle measures the speed at which fibrin build up and cross linking takes place, hence assesses the rate of clot formation, i.e. thrombin burst.
MA: Maximal Amplitude measured in mm	Maximum clot size: it reflects the ultimate strength of the fibrin clot, i.e. overall stability of the clot. The larger the MA the more hypercoagulable the clot.
Maximum rate of thrombus generation (MRTG) measured in Dyn.cm^{-2}.s^{-1}	The maximum velocity of clot growth observed or maximum rate of thrombus generation using G, where G is the elastic modulus strength of the thrombus in dynes per cm^{-2}.
Time to maximum rate of thrombus generation (TMRTG) measured in minutes	The time interval observed before the maximum speed of the clot growth.
Total thrombus generation (TTG) measured in Dyn.cm^{-2}	The clot strength: the amount of total resistance (to movement of the cup and pin) generated during clot formation. This is the total area under the velocity curve during clot growth, representing the amount of clot strength generated during clot growth.
Lysis at 30 minutes (LY30) measured in %	The LY30 parameter (measured in %) is recorded at 30 minutes, measured from the point where the maximum amplitude (MA) of the clot is reached.
G value measured in Dyn.sec	G-value is a log-derivation of the MA and is meant to also represent the clot strength Elevated G-value is associated with a hypercoagulable state and therefore increases the risk for venous thromboembolic disease.

PFA-200 platelet test interpretation		
Citrated whole blood is aspirated at high shear rates through disposable cartridges. These cartridges contain an aperture within a membrane coated agonist. The agonist cartridges are Col/EPI, Col/ADP and P2Y and they report data in **closure time.** The PFA-200 test induces platelet adhesion, activation and aggregation using the three cartridges. Closure times increase progressively as the platelet counts falls below 100 x 10^{9}/L.		
Agonist cartridges [65]	**Test principle**	**Closure time interpretations: measured in seconds**
Collagen and epinephrine (Col/EPI): This cartridge has a collagen (2 µg equine type I) and epinephrine (10 µg)-coated membrane (C/Epi).	Co-stimulation by shear stress, collagen, epinephrine. Gives an indication of effectiveness of aspirin and GP IIβ/IIIα inhibitor dosage.	Col/EPI closure time is 82 - 150 seconds with a value >150 seconds regarded as prolonged.
Collagen and ADP (Col/ADP): This cartridge has a collagen (2 µg equine type I) and adenosine-diphosphate (50 µg)-coated membrane (Col/ADP).	Co-stimulation by shear stress, collagen, ADP. Gives an indication of effectiveness of aspirin and clopidogrel and GP IIβ/IIIα inhibitor dosage.	Col/ADP closure time is 62 - 100 seconds with a value >100 seconds regarded as prolonged.
P2Y: This cartridge has a prostaglandin E1 (5 ng) and ADP (20 µg)-coated membrane.	Co-stimulation by shear stress, ADP, PGE1 and Ca^{2+}. Gives an indication of effectiveness of clopidogrel and GP IIβ/IIIα inhibitor dosage	Shortened PFA P2Y closure times >106 seconds are viewed as prolonged.

An important consideration is that TEG® can be used to study the clotting parameters of both whole blood (WB) and platelet poor plasma (PPP). Whole blood TEG® gives information on the clotting potential affected by the presence of both platelets and fibrinogen, while PPP TEG® only presents evidence of the clotting potential of the plasma proteins [66-69]. Reasons for a hypercoagulable TEG® trace when using PPP, may be indicative of the presence of dysregulated inflammatory biomarkers, including P-selectin, inflammatory cytokines and increased levels of fibrinogen [70-75].

We have also found that during the presence of systemic inflammation, reflected in an increased presence of inflammagens, the biochemistry of the fibrin(ogen) molecule changes its folding characteristics considerably (Figure 3), to produce amyloid forms. We could visualize these changes using fluorescence markers [31, 56, 76-78]. The fluorescence markers we have used to show these structural changes in the fibrin(ogen) biochemistry included thioflavin T (ThT) and various Amytracker dyes. These fluorescence markers are typically used to show amyloid changes to proteins [31, 56, 76-78], suggesting the misfolding seen in fibrin(ogen) during the presence of inflammagens in the blood, could also be described as amyloid. We showed, that when fibrin(ogen) is exposed to increased levels of inflammatory biomarkers and bacterial (viral) inflammagens, either in the laboratory or in patients with increased levels, TEG® of PPP was significantly hypercoagulable [76-79]. Figure 3A shows the uncoiling of the fibrin(ogen) molecule where it caused plasma and WB to become hypercoagulable. Figure 3B and C shows scanning electron micrographs of representative examples of a healthy clot and a clot from a Type 2 Diabetes (T2DM) individual [taken from [75]].

Figure 3: A) The uncoiling of the fibrinogen protein (in part) resulting in whole blood and plasma hypercoagulability. **B and C**) are examples of scanning electron microscopy micrographs of **B)** polymerized fibrin cross-linking fibrin clot from a healthy individual (created with platelet poor plasma with added thrombin); **C)** fibrin clot from a diabetes individual (created with platelet poor plasma with added thrombin) [B and C taken from [75]]. Image in A created with BioRender (https://biorender.com/).

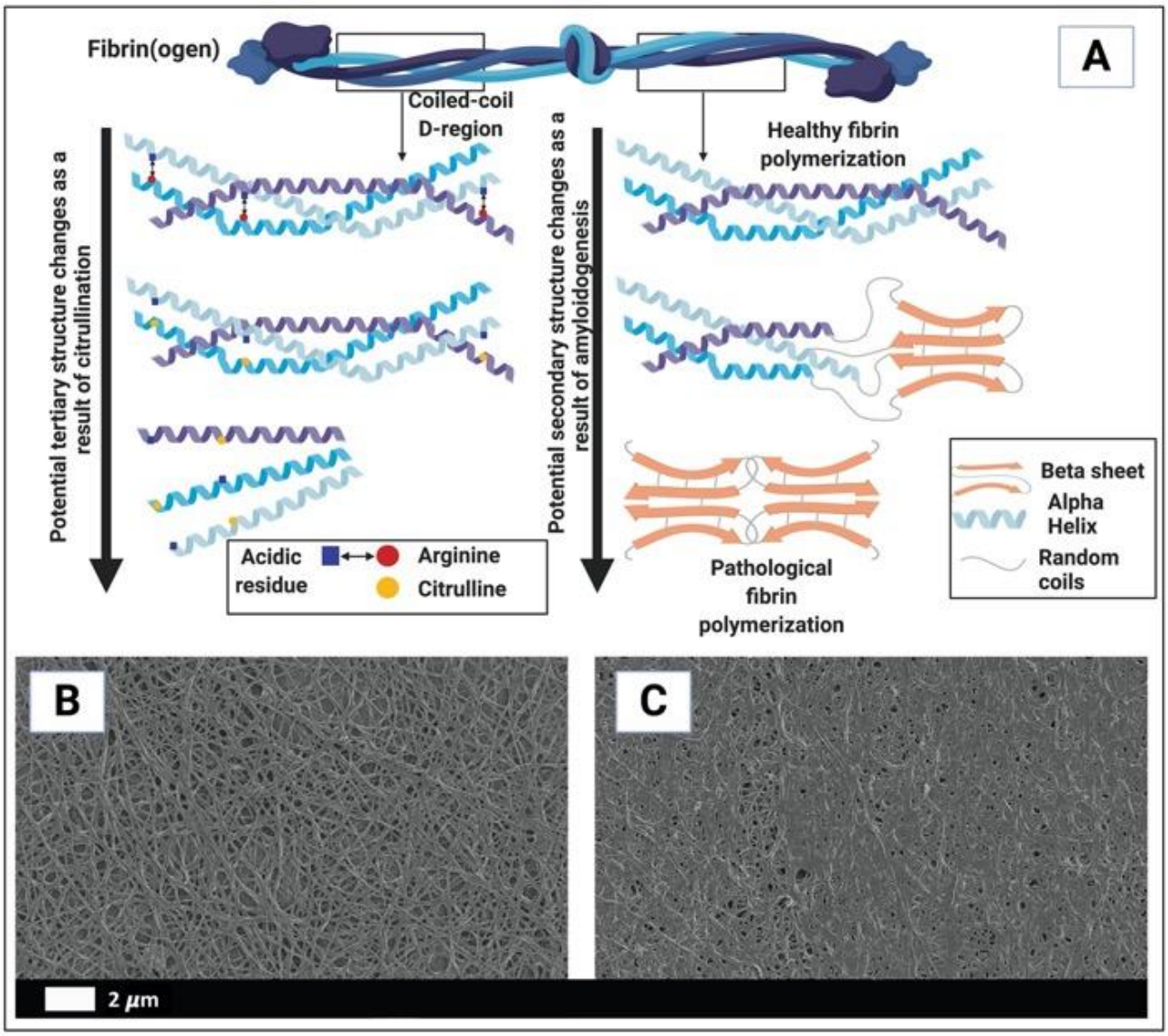

The value of using both the TEG® and fluorescence markers was again seen in our recent studies on the effects that COVID-19 has on the coagulation system, where an increased clot strength and anomalous microclot formation were observed [21, 22].

THE EARLY TREATMENT OF PATIENTS WITH ANTICOAGULATION MEDICATION

Early on in the disease, it was suggested that best practices for supportive management of acute hypoxic respiratory failure and (ARDS should be followed [1, 80]. In 2020, the American Thoracic Society-led international task force has also released a guidance document to help clinicians manage COVID-19. The new guidance - "COVID-19: Interim Guidance on

Management Pending Empirical Evidence"- is published as an open access document on the American Thoracic Society's website (https://www.thoracic.org/covid/covid-19-guidance.pdf) [81]. These guidelines in broad terms suggest the use of ventilation in patients who have refractory hypoxemia and ARDS, to consider extracorporeal membrane oxygenation in patients who have refractory hypoxemia, COVID-19 pneumonia (i.e. ARDS), and have failed prone ventilation. Most significant is that the guidelines recognise and state that: "We believe that in urgent situations like a pandemic, we can learn while treating by collecting real-world data". Evidence-based guideline initiatives have also been established by many countries and professional societies, e.g. in South Africa, the South African Society of Anaesthesiologists (SASA) has detailed guidelines on their website (https://sasacovid19.com/#guidance-documents). In addition, guidelines are updated on a very regular basis by the National Institutes of Health (https://www.covid19treatmentguidelines.nih.gov/).

Potential therapies that address vascular system dysfunction and its sequelae may have an important role in treating patients with COVID-19 and its long-lasting effects [5]. Heparin has also been found in some circumstances to be a helpful treatment for COVID-19 [82, 83]. Patients treated with anticoagulants (such as heparin) had a higher survival rate and a much more favourable outcome was seen in ventilated patients were 62.7% of patients without anticoagulants died. This outcome will of course be improved if the patients are treated when they are still in the early stages of the disease (when hypercoagulation is present). In contrast, only 1% of patients treated with anticoagulants and who were ventilated died [84]. Heparin interferes with VWF, platelet activation, and assists in the prevention of thrombotic events. It was also recently shown, in a study of 449 patients with severe COVID-19, that anticoagulant therapy, mainly with low molecular weight heparin, appeared to be associated with lower mortality in the subpopulation meeting sepsis-induced coagulopathy criteria or with markedly elevated D-dimer [26, 84]. In this study 99 of the patients received heparin (mainly low molecular weight heparin) for 7 days or longer (such treatment was only given in the initial stages of the disease when the patient is hypercoagulable and not during the bleeding or thrombocytopenia phase of the disease). It should be noted that the timeline of the rollercoaster disease progression can be hours and it is a continuum rather than a clear event or “flip” between hypercoagulation and bleeding. If the disease is left unabated, VWF and fibrinogen depletion, and significantly increased levels of D-dimer and P-selectin will progress on a continuum [39].

Anticoagulation Trails

Here we argue that an early and aggressive treatment with a multipronged approach covering the enzymatic pathway, platelets and lysis of microclots, are key in the treatment of COVID-

19. Recently, there were two trials we wish to focus on, that studied the effects of anticoagulation [57, 85].

In an open-label, adaptive, multiplatform, controlled trial, published in New England Journal of Medicine, Lawler and co-workers randomly assigned patients who were hospitalized with COVID-19 and who were not critically ill to receive pragmatically defined regimens of either therapeutic-dose anticoagulation with heparin or usual-care pharmacologic thromboprophylaxis [85]. The findings suggested that in noncritically ill patients with COVID-19, an initial strategy of therapeutic-dose anticoagulation with heparin increased the probability of survival to hospital discharge with reduced use of cardiovascular or respiratory organ support as compared with usual-care thromboprophylaxis. In an editorial, referring to this paper, Ten Cante [86] reiterates the suggestion that intermediate to full anticoagulation is indicated in patients with moderate disease.

In another open-label, multicentre, randomised, controlled trial, published in the Lancet in 2021, researchers investigated therapeutic versus prophylactic anticoagulation for patients admitted to hospital with COVID-19 and elevated D-dimer concentration [57]. In this trial, 3331 patients were screened and 615 were randomly allocated (311 [50%] to the therapeutic anticoagulation group and 304 [50%] to the prophylactic anticoagulation group. 576 (94%) were clinically stable and 39 (6%) clinically unstable. The primary efficacy outcome was not different between patients assigned therapeutic or prophylactic anticoagulation, with 28 899 (34·8%) similar results in the therapeutic group and 34 288 (41·3%) in the prophylactic group (win ratio 0·86 [95% CI 0·59-1·22], p=0·40). Consistent results were seen in clinically stable and clinically unstable patients. The primary safety outcome of major or clinically relevant non-major bleeding occurred in 26 (8%) patients assigned therapeutic anticoagulation and seven (2%) assigned prophylactic anticoagulation (relative risk 3·64 [95% CI 1·61-8·27], p=0·0010).

The treatment regime that was followed:

- Therapeutic anticoagulation was in-hospital oral rivaroxaban (20 mg or 15 mg daily) for stable patients, or initial subcutaneous enoxaparin (1 mg/kg twice per day)
- or intravenous unfractionated heparin (to achieve a 0·3-0·7 IU/mL anti-Xa concentration) for clinically unstable patients, followed by rivaroxaban to day 30.
- Prophylactic anticoagulation was standard in-hospital enoxaparin or unfractionated heparin.

The results from the trial suggest that in-hospital therapeutic anticoagulation with rivaroxaban or enoxaparin followed by rivaroxaban to day 30 did not improve clinical outcomes and

increased bleeding compared with prophylactic anticoagulation. The conclusion of data from the trial was therefore that the use of therapeutic-dose rivaroxaban, and other direct oral anticoagulants, should be avoided in these patients in the absence of an evidence-based indication for oral anticoagulation.

In 2020, Viecca and co-workers reported on a single center, investigator initiated, proof of concept, case control, phase IIb study (NCT04368377) conducted in Italy [87]. The study explored the effects anti-platelet therapy on arterial oxygenation and clinical outcomes in patients with severe Covid-19 with hypercoagulability. Patients received 25 µg/Kg/body weight tirofiban as bolus infusion, followed by a continuous infusion of 0.15 µg/Kg/body weight per minute for 48 hours. Before tirofiban, patients received acetylsalicylic acid 250 mg infusion and oral clopidogrel 300 mg; both were continued at a dose of 75 mg daily for 30 days. Fondaparinux 2.5 mg/day sub-cutaneous was given for the duration of the hospital stay. The investigators found that antiplatelet therapy might be effective in improving the ventilation/perfusion ratio in Covid-19 patients with severe respiratory failure and that the therapy prevent clot formation in lung capillary vessels [87].

A recent publication discussed the outcomes of the largest observational study to date, of prehospital antiplatelet therapy in patients with COVID-19, where a significantly lower in-hospital mortality was seen in the group that received antiplatelet therapy. The propensity score-matched cohort of 17 347 patients comprised of 6781 and 10 566 patients in the antiplatelet and non-antiplatelet therapy groups, respectively. In-hospital mortality was significantly lower in patients receiving prehospital antiplatelet therapy (18.9% vs. 21.5%, $p < .001$), resulting in a 2.6% absolute reduction in mortality (HR: 0.81, 95% CI: 0.76-0.87, $p < .005$).

Our analysis of the conclusions of the above-mentioned trials are as follows: To have a chance at supporting clotting physiology, the enzymatic clotting pathway, as well as platelet activation need to be aggressively controlled and guided by TEG® and platelet functional assays. The aim of treatment is to restore/maintain normal clotting physiology and not aiming for a hypocoagulable state. By doing random controlled trials and severe COVID-19 patients and trying to prove the efficacy of prophylactic vs therapeutic clexane [low molecular weight heparin treatment (LMWH)] (or any single agent for that matter, affecting clotting) would be futile because the important part that the platelet plays, is ignored. The trial would have a predictable negative outcome for both doses of LMWH and one might come to the (incorrect) conclusion that there is no place for anticoagulation in these patients.

There are also other trials including a Montelukast trial for COVID-19 (https://clinicaltrials.gov/ct2/show/NCT04714515). The aim of this trial is to make a therapeutic comparison and effectiveness of Hydroxychloroquine and Montelukast in COVID-19 patients in addition to the standard of care. It was also found by Khan and co-workers in 2021, that hospitalized COVID-19 patients treated with montelukast had fewer events of clinical deterioration, indicating that this treatment may have clinical activity [88]. While this retrospective study highlights a potential pathway for COVID-19 treatment.
It was suggested that montelukast can directly impact on COVID-19 [89], by having an anti-viral effect, or by suppression of heightened cytokine release in response to the virus [90-93]. Montelukast can block Cysteinyl-leukotriene in different organs or indirectly through inhibition of the NF-κB signaling pathway [94].

As Montelukast primarily acts on the leukotriene pathway, and might only be useful at the end-stage of the disease when the cytokine storm is a major concern. According to our understanding of the disease, i.e. treating the hypercoagulable state early on, using Montelukast (a leukotriene re-uptake antagonist) at this stage would have no effect on outcome, because the molecule has no effect on COVID-19 coagulopathy.

FLUORESCENCE MICROSCOPY CAN BE USED TO PROVIDE A MARKER OF MICROCLOT FORMATION AND PLATELET HYPERACTIVATION

Currently there is no effective pathology laboratory diagnosis of acute COVID-19, based on the presence of microclots or level of platelet hyperactivation. However, we developed a fluorescence microscopy-based grading system for both microclot presence as well as platelet hyperactivation. Although specialized fluorescence microscopy is needed, both the methods are relatively easy and greatly cost-effective if a fluorescence microscope is available for the analysis.

Methods used to analyse microclots in platelet poor plasma

To view anomalous clotting of fibrin(ogen) and plasma proteins, in platelet poor plasma (PPP), blood is drawn in citrate tubes, and PPP is collected after a centrifugation step of 15 minutes at 3000 RPM. This method was previously discussed in various of our papers [21-23, 56]. To view microclots, thioflavin T (ThT) (final concentration: 0,005mM) (Sigma-Aldrich, St. Louis, MO, USA) is added to PPP and incubated for 30 minutes. After placing a 3 µL drop of the sample on a microscope slide, the sample is viewed with a fluorescence microscope. In our case, we used the Zeiss Axio Observer 7 fluorescence microscope with a Plan-Apochromat 63x/1.4 Oil DIC M27 objective (Carl Zeiss Microscopy, Munich, Germany) using the excitation wavelength of 450nm to 488nm and emission from 499nm to 529nm.

Methods used to prepare platelets

We are aware that the analysis of platelet activation is extremely difficult, as platelets are easily activated. Flow cytometry and platelet aggregation tests are therefore extremely tedious and difficult procedures, even for pathology laboratories. We therefore developed a method where we use the haematocrit of the citrated blood sample to study platelet activation in patients [21-23]. In patients with COVID-19, platelets are extremely fragile and hyperactivate easily [11, 95]. The whole blood centrifugation step to prepare the haematocrit will therefore easily cause further platelet activation. However, in healthy individuals, this step will have limited influence on platelets, only triggering slight pseudopodia formation. This method could therefore also be seen as a method to show platelet activation under the stress induced by a centrifugation step [22, 23].

After preparing a hematocrit sample as described previously and removing the PPP, we add two fluorescent antibodies, to CD62P (platelet surface P-selectin) (IM1759U, Beckman Coulter, Brea, CA, USA) and to PAC-1 (activated GP IIb/IIIa) (340507, BD Biosciences, San Jose, CA, USA) to the haematocrit [96] CD62P/P-selectin is released from the cellular granules during platelet activation and then moves to the surface of the platelet membrane. The antibody PAC-1 detects the neoepitope of active GPIIb/IIIa. PAC-1 antibody binding is correlated with platelet activation. After the samples are incubated at room temperature for 30 minutes it can also be viewed using a fluorescence microscope. We used the Zeiss Axio Observer 7 fluorescence microscope with a Plan-Apochromat 63x/1.4 Oil DIC M27 objective (Carl Zeiss Microscopy, Munich, Germany), using the excitation wavelength 406 to 440 nm and the emission at 546 to 564 nm for the PAC-1 marker, while the excitation for the CD62P was set at 494–528 nm and the emission 618 to 756 nm [22, 23].

A grading system for plasma microclot formation and platelet activation, spreading and clumping

Figure 4, 5 and 6 shows plates of the various stages of microclot formation and also platelet activation, spreading and clumping, respectively. We suggest a grading system for the use of both microclot presence and platelet activation, as shown in Table 3 and 4. After combining the scores of both the platelet criteria and PPP criteria, Table 5 shows an example of a combined scoring criterion to produce an overall result score for a patient of both microclot and platelet activation. This scoring result may be used as a guide for the level of pathological clotting present in a patient. Together with thromboelastography analysis, this grading could guide clinical practice.

Figure 4: Fluorescence microscopy showing microclots in platelet poor plasma (PPP) with representative examples of the different stages of different stages of microclot formation. Stage 1 shows minimal microclot formation in healthy/control PPP which progresses to the presence of the severe microclotting Stage 4. Stage 1 to 4 is also used as a numerical scoring system, where a score of 1 is given for minimal microclot formation and a score of 4 is given for significant and widespread microclot formation.

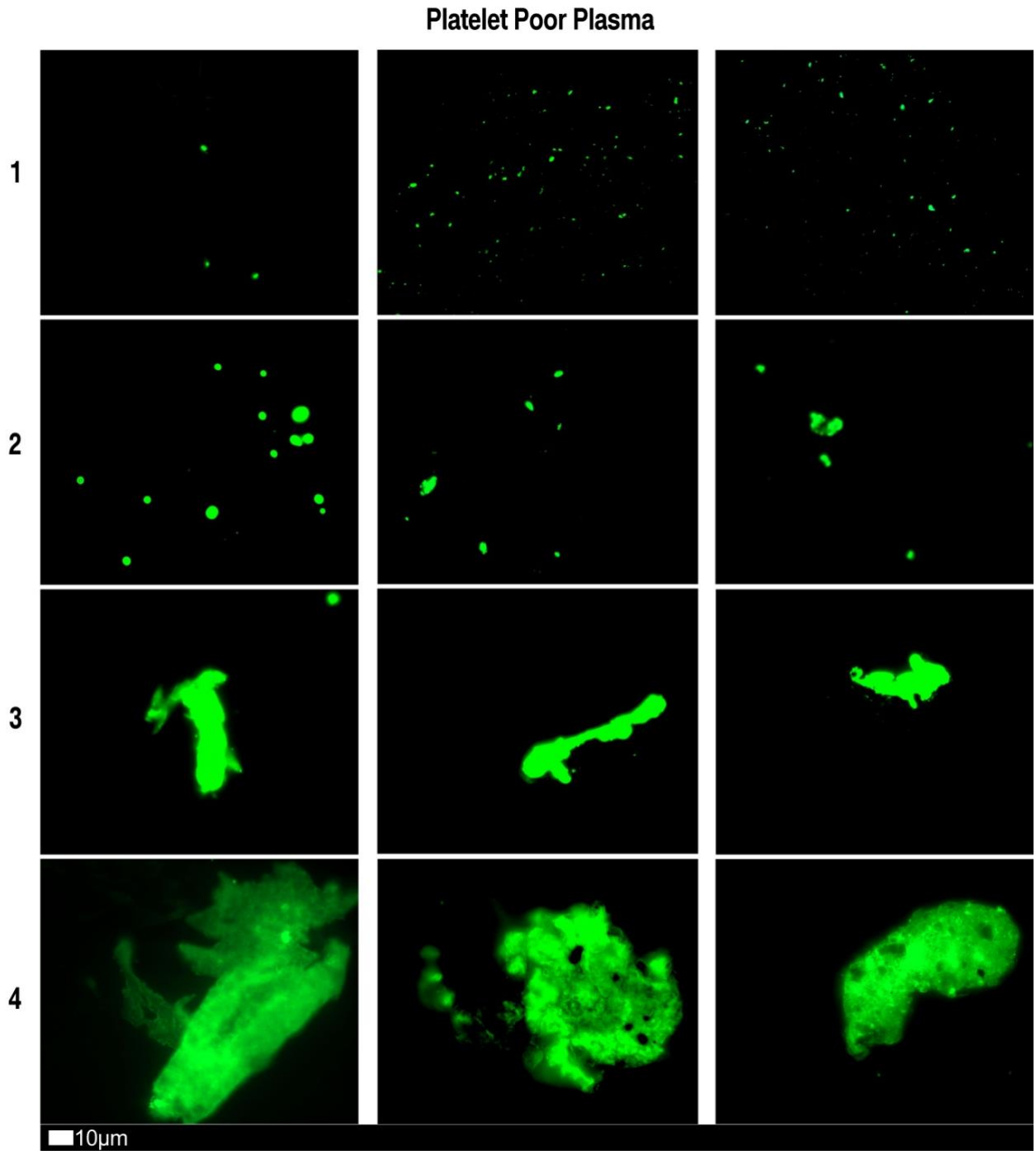

Figure 5: Fluorescence microscopy examples of the different stages of platelet activation and spreading. From healthy/control samples, with minimally activated platelets, seen as small round platelets with a few pseudopodia visible due to contact activation as seen in Stage 1, that progresses to the egg-shaped platelets, indicative of spreading and the beginning of clumping, as seen in Stage 4. Stage 1 to 4 is also used as a numerical scoring system, where a score of 1 is given for slight activation and pseudopodia formations, seen in a healthy individual, and a score of 4 is given for spreading.

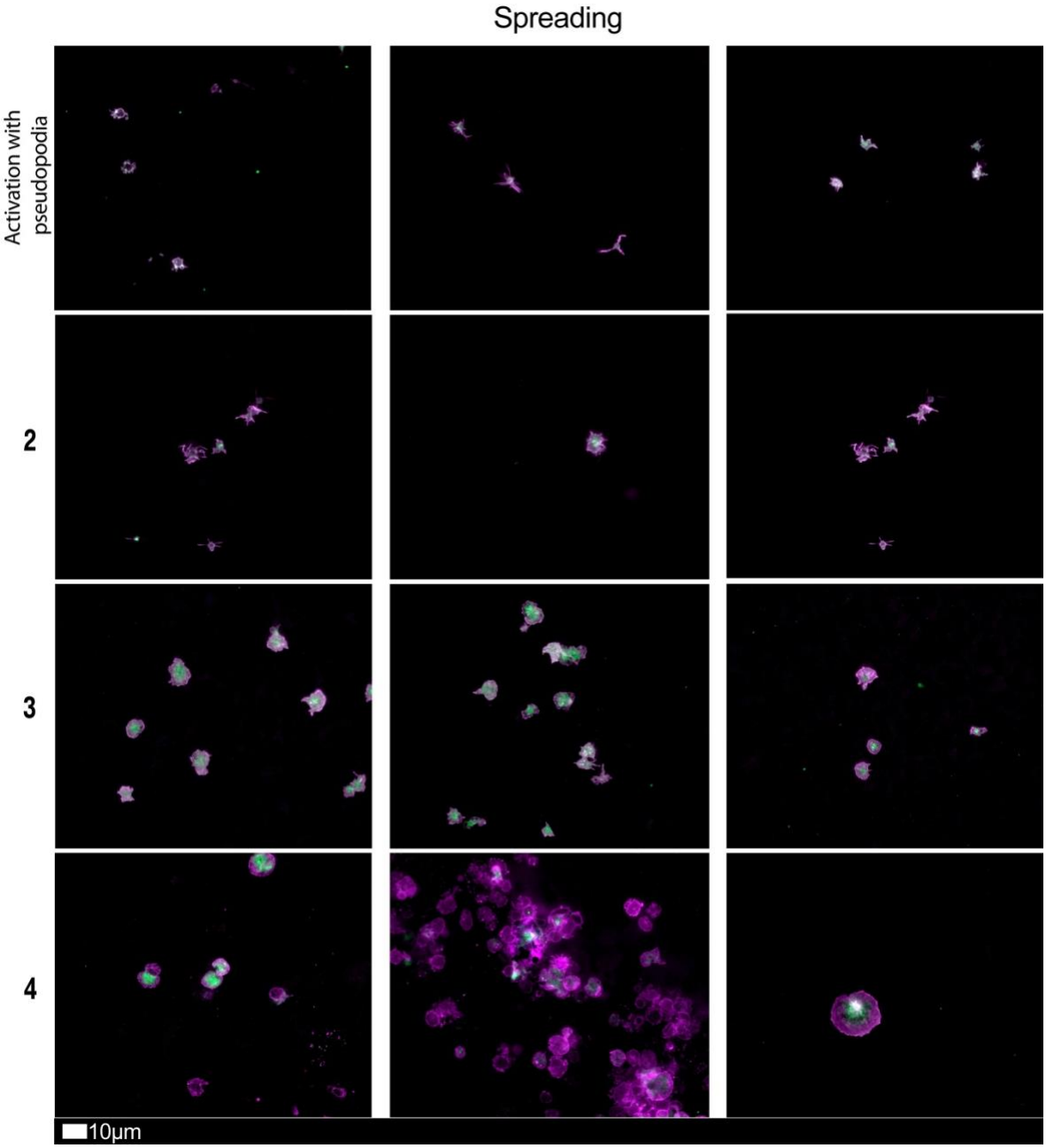

Figure 6: Fluorescence microscopy examples of the different stages of platelet clumping. With no clumping occurring in the healthy/control samples in Stage 1 (no figures shown), progressing to severe clumping of platelets as seen in Stage 4. Stage 1 to 4 is also used as a numerical scoring system, where a score of 1 is given for no clumping and a score of 4 is given for severe clumping.

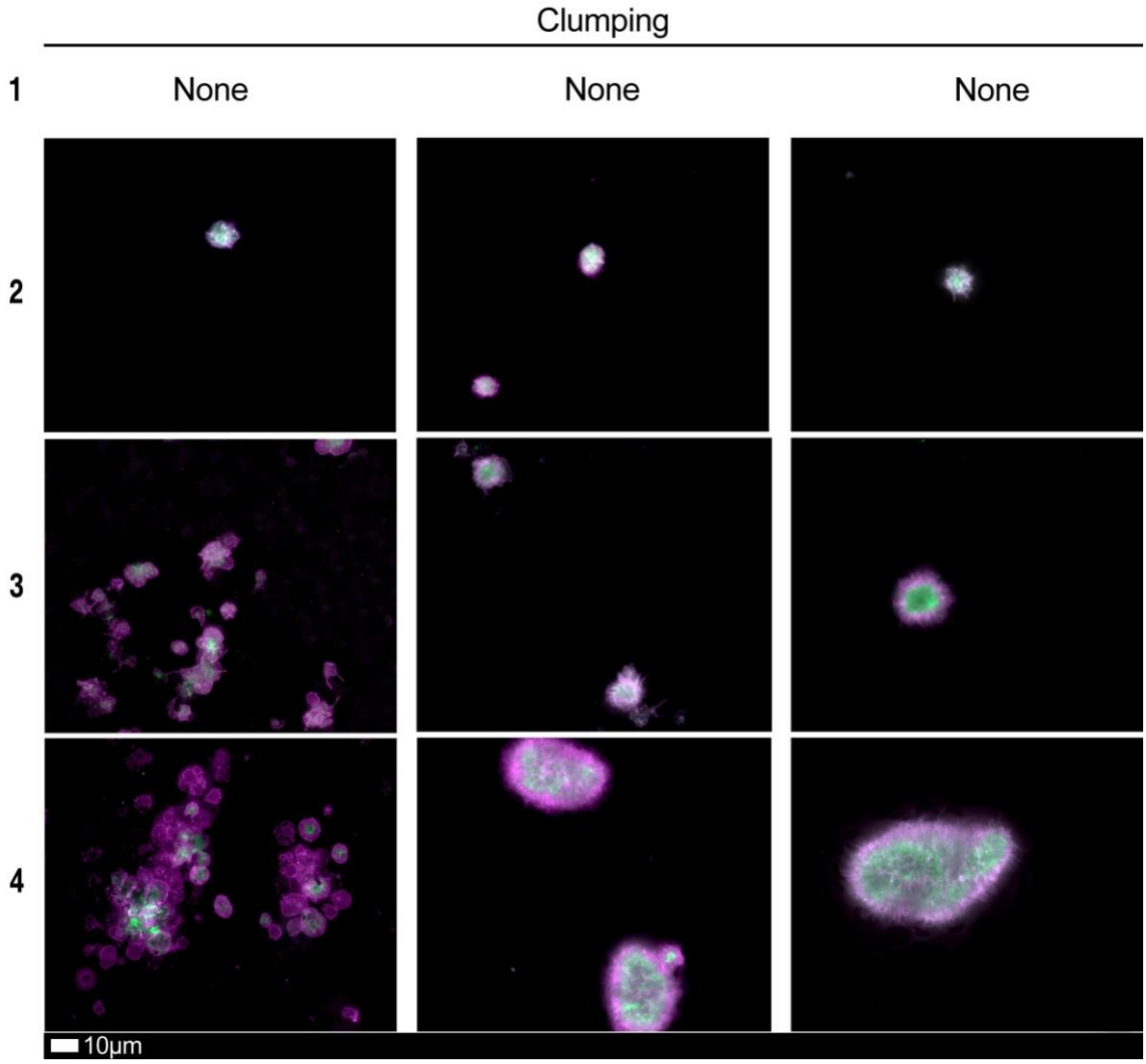

Table 3: Microclot criteria to determine the amount of microclots present the sample.

Score	Spreading	Score	Clumping
1	Activation with pseudopodia	1	None
2	Mild	2	Mild
3	Moderate	3	Moderate
4	Severe	4	Severe

Table 4: Platelet criteria activation criteria showing level of spreading as well as clumping present in the sample.

Score	**Presence of microclots in plasma**
1	Very few areas of plasma protein misfolding (≤1µm) visible with a few ≤10µm microclots
2	Very few areas of plasma protein misfolding (≤1µm) visible with scattered/mild ≤10µm microclots
3	Moderate areas of plasma protein misfolding visible as microclots ≥15µm
4	Severe areas of plasma protein misfolding visible as large microclots

Table 5: Overall microclot and platelet activation score results.

Control / Healthy	**Mild**	**Moderate**	**Severe**
=3	4-7	8-10	11-12
Platelets + PPP scores =			

CONCLUSION

The identification and development of new diagnostic methods, based on emerging research and clinical evidence that may assist the identification of novel therapeutic candidates or treatment regimens is crucial. We suggest here that an approach of early and close monitoring of clinical parameters of clotting, including TEG® parameters, microclot and platelet mapping, are crucial in the successful management of COVID-19 patients. However, it requires clinicians and researchers to be flexible with a willingness to embrace new diagnostic methods and treatment protocols that might deviate slightly from the recognized protocols. With this statement we most certainly do not imply that clinicians and researchers should lower the bar for standards of evidence. However, during this pandemic with the rapidly changing environment, traditional rules may not apply [97]. Because the coagulopathy changes over time (and this timeframe can be within hours), therapy should be guided by clinical parameters, including TEG® parameters, levels of fibrinogen, VWF, as well as D-dimer. Given the high stakes, the imperative for new approaches is greater than ever. Flexible and reflective treatment protocols will be our only chance to lower death rates and eventually contribute to the control of this pandemic. We therefore agree that COVID-19 is indeed (also) a true vascular and endothelial disease. We also suggest that a “single-drug approach” would be insufficient to address the COVID-19 coagulopathy. We suggest that the treatment of COVID-

19 patients, should be based on results from point-of-care analyses like the TEG®, as well as detailed analysis of microclot presence as well as platelet activation, that shows the physiological status of the haematological and coagulation system in real-time. We do realize that a microclot ad platelet grading system is using fluorescence microscopy is not the most user-friendly techniques, and quantification methods would provide better standardization. However, currently there is no such methods available. Developing more robust and quantifiable methods should most definitely be investigated further. We conclude that, because of the overwhelming alteration of clotting, the outcome of any trial evaluating an any single anticoagulant, including thrombolytic drugs, would be negative. A multi-pronged approach, guided by TEG® and platelet mapping, would be required to maintain normal clotting physiology in severe COVID-19 disease.

Declarations

Ethics approval and consent to participate

Ethical approval for blood collection and analysis of patients with acute COVID-19, by the Health Research Ethics Committee (HREC) of Stellenbosch University (reference number: 9521). This laboratory study was carried out in strict adherence to the International Declaration of Helsinki, South African Guidelines for Good Clinical Practice and the South African Medical Research Council (SAMRC), Ethical Guidelines for research. The patients or the public were not involved in the design, or conduct, or reporting, or dissemination plans of our research.

Declarations of interest

EP is a director of a Stellenbosch University start-up company (BioCODE Technologies) that develops point-of-care technology for the early identification of inflammatory disease risk.

Consent for publication

All authors approved submission of the paper.

Competing interests

The authors have no competing interests to declare.

Funding

DBK thanks the Novo Nordisk Foundation for financial support (grant NNF20CC0035580). The funders had no role in study design, data collection and analysis, decision to publish, or preparation of the manuscript.

Authors' contributions

GJL: Clinician and patient sample identification and writing of clinical workflow protocols; PSL: clinical workflow protocols; CV: Sample curation, platelet analysis and preparation of figure plates; DBK: co-corresponding author; EP: Sample analysis, writing and editing of the paper, co-corresponding author.

TABLE AND FIGURE LEGENDS

Table 1: Dysregulation of circulating biomarkers P-selectin, von Willebrand Facto, fibrin(ogen) and D-dimer in COVID-19. See Figure 1 for levels during COVID-19.

Table 2: Thromboelastography® (TEG®) clot parameters for whole blood and PFA-200 platelet parameters.

Table 3: Microclot criteria to determine the amount of microclots present the sample.

Table 4: Platelet criteria activation criteria showing level of spreading as well as clumping present in the sample.

Table 5: Overall microclot and platelet activation score results.

Figure 1: The rollercoaster vascular pathology in acute respiratory syndrome coronavirus 2 (COVID-19) [adapted from [39]]. We focus on fibrin(ogen), D-Dimer, P-selectin and von Willebrand Factor dysregulation, resulting in endothelial, erythrocyte and platelet dysfunction. **A)** Early on in the disease dysregulation in clotting proteins and circulating biomarkers may occur and is suggestive of hypercoagulation. **B)** The disease may progress to bleeding and thrombocytopenia. **C)** We suggest that each patient should be treated using a personalized medicine approach in the early stages of the disease. Image created with BioRender (https://biorender.com/).

Figure 2: TEG® traces with the various parameters discussed in Table 3, visualized. **A)** Healthy (normocotgulable) trace; **B)** Hypercoagulable trace and **C)** Hypocoagulable trace. Image created with BioRender (https://biorender.com/).

Figure 3: A) The uncoiling of the fibrinogen protein (in part) resulting in whole blood and plasma hypercoagulability. **B and C**) are examples of scanning electron microscopy micrographs of **B)** polymerized fibrin cross-linking fibrin clot from a healthy individual (created with platelet poor plasma with added thrombin); **C)** fibrin clot from a diabetes individual (created with platelet poor plasma with added thrombin) [B and C taken from [75]]. Image in A created with BioRender (https://biorender.com/).

Figure 4: Fluorescence microscopy showing microclots in platelet poor plasma (PPP) with representative examples of the different stages of different stages of microclot formation. Stage 1 shows minimal microclot formation in healthy/control PPP which progresses to the presence of the severe microclotting Stage 4. Stage 1 to 4 is also used as a numerical scoring system, where a score of 1 is given for minimal microclot formation and a score of 4 is given for significant and widespread microclot formation.

Figure 5: Fluorescence microscopy examples of the different stages of platelet activation and spreading. From healthy/control samples, with minimally activated platelets, seen as small round platelets with a few pseudopodia visible due to contact activation as seen in Stage 1, that progresses to the egg-shaped platelets, indicative of spreading and the beginning of clumping, as seen in Stage 4. Stage 1 to 4 is also used as a numerical scoring system, where a score of 1 is given for slight activation and pseudopodia formations, seen in a healthy individual, and a score of 4 is given for spreading.

Figure 6: Fluorescence microscopy examples of the different stages of platelet clumping. With no clumping occurring in the healthy/control samples in Stage 1 (no figures shown), progressing to severe clumping of platelets as seen in Stage 4. Stage 1 to 4 is also used as

a numerical scoring system, where a score of 1 is given for no clumping and a score of 4 is given for severe clumping.

References

1. Wiersinga, W. J.; Rhodes, A.; Cheng, A. C.; Peacock, S. J.; Prescott, H. C., Pathophysiology, Transmission, Diagnosis, and Treatment of Coronavirus Disease 2019 (COVID-19): A Review. *Jama* **2020**.
2. Wynants, L.; Van Calster, B.; Collins, G. S.; Riley, R. D.; Heinze, G.; Schuit, E.; Bonten, M. M. J.; Damen, J. A. A.; Debray, T. P. A.; De Vos, M.; Dhiman, P.; Haller, M. C.; Harhay, M. O.; Henckaerts, L.; Kreuzberger, N.; Lohman, A.; Luijken, K.; Ma, J.; Andaur, C. L.; Reitsma, J. B.; Sergeant, J. C.; Shi, C.; Skoetz, N.; Smits, L. J. M.; Snell, K. I. E.; Sperrin, M.; Spijker, R.; Steyerberg, E. W.; Takada, T.; van Kuijk, S. M. J.; van Royen, F. S.; Wallisch, C.; Hooft, L.; Moons, K. G. M.; van Smeden, M., Prediction models for diagnosis and prognosis of covid-19 infection: systematic review and critical appraisal. *Bmj* **2020,** 369, m1328.
3. Docherty, A. B.; Harrison, E. M.; Green, C. A.; Hardwick, H. E.; Pius, R.; Norman, L.; Holden, K. A.; Read, J. M.; Dondelinger, F.; Carson, G.; Merson, L.; Lee, J.; Plotkin, D.; Sigfrid, L.; Halpin, S.; Jackson, C.; Gamble, C.; Horby, P. W.; Nguyen-Van-Tam, J. S.; Ho, A.; Russell, C. D.; Dunning, J.; Openshaw, P. J.; Baillie, J. K.; Semple, M. G., Features of 20 133 UK patients in hospital with covid-19 using the ISARIC WHO Clinical Characterisation Protocol: prospective observational cohort study. *Bmj* **2020,** 369, m1985.
4. Libby, P.; Lüscher, T., COVID-19 is, in the end, an endothelial disease. *Eur Heart J* **2020,** 41, (32), 3038-3044.
5. Siddiqi, H. K.; Libby, P.; Ridker, P. M., COVID-19 - A vascular disease. *Trends Cardiovasc Med* **2021,** 31, (1), 1-5.
6. Meizlish, M.; Pine, A.; Goshua, G.; Chang, C. H.; Zhang, H.; Bishai, J.; Bahel, P.; Patel, A.; Gbyli, R.; Kwan, J.; Price, C.; Dela Cruz, C.; Halene, S.; van Dijk, D.; Hwa, J.; Lee, A. I.; Chun, H. J., Circulating Markers of Angiogenesis and Endotheliopathy in COVID-19. *medRxiv* **2020**.
7. Goshua, G.; Pine, A. B.; Meizlish, M. L.; Chang, C. H.; Zhang, H.; Bahel, P.; Baluha, A.; Bar, N.; Bona, R. D.; Burns, A. J.; Dela Cruz, C. S.; Dumont, A.; Halene, S.; Hwa, J.; Koff, J.; Menninger, H.; Neparidze, N.; Price, C.; Siner, J. M.; Tormey, C.; Rinder, H. M.; Chun, H. J.; Lee, A. I., Endotheliopathy in COVID-19-associated coagulopathy: evidence from a single-centre, cross-sectional study. *Lancet Haematol* **2020**.
8. Ackermann, M.; Verleden, S. E.; Kuehnel, M.; Haverich, A.; Welte, T.; Laenger, F.; Vanstapel, A.; Werlein, C.; Stark, H.; Tzankov, A.; Li, W. W.; Li, V. W.; Mentzer, S. J.; Jonigk, D., Pulmonary Vascular Endothelialitis, Thrombosis, and Angiogenesis in Covid-19. *N Engl J Med* **2020,** 383, (2), 120-128.
9. Perico, L.; Benigni, A.; Casiraghi, F.; Ng, L. F. P.; Renia, L.; Remuzzi, G., Immunity, endothelial injury and complement-induced coagulopathy in COVID-19. *Nat Rev Nephrol* **2021,** 17, (1), 46-64.
10. Smadja, D. M.; Mentzer, S. J.; Fontenay, M.; Laffan, M. A.; Ackermann, M.; Helms, J.; Jonigk, D.; Chocron, R.; Pier, G. B.; Gendron, N.; Pons, S.; Diehl, J. L.; Margadant, C.; Guerin, C.; Huijbers, E. J. M.; Philippe, A.; Chapuis, N.; Nowak-Sliwinska, P.; Karagiannidis, C.; Sanchez, O.; Kümpers, P.; Skurnik, D.; Randi, A. M.; Griffioen, A. W.,

COVID-19 is a systemic vascular hemopathy: insight for mechanistic and clinical aspects. *Angiogenesis* **2021**, 1-34.

11. Wool, G. D.; Miller, J. L., The Impact of COVID-19 Disease on Platelets and Coagulation. *Pathobiology* **2021,** 88, (1), 15-27.
12. Chang, J. C., Disseminated intravascular coagulation: is it fact or fancy? *Blood Coagul Fibrinolysis* **2018,** 29, (3), 330-337.
13. Gąsecka, A.; Borovac, J. A.; Guerreiro, R. A.; Giustozzi, M.; Parker, W.; Caldeira, D.; Chiva-Blanch, G., Thrombotic Complications in Patients with COVID-19: Pathophysiological Mechanisms, Diagnosis, and Treatment. *Cardiovasc Drugs Ther* **2021,** 35, (2), 215-229.
14. Paternoster, G.; Bertini, P.; Innelli, P.; Trambaiolo, P.; Landoni, G.; Franchi, F.; Scolletta, S.; Guarracino, F., Right Ventricular Dysfunction in Patients With COVID-19: A Systematic Review and Meta-analysis. *J Cardiothorac Vasc Anesth* **2021**.
15. Lan, Y.; Liu, W.; Zhou, Y., Right Ventricular Damage in COVID-19: Association Between Myocardial Injury and COVID-19. *Front Cardiovasc Med* **2021,** 8, 606318.
16. Soulat-Dufour, L.; Fauvel, C.; Weizman, O.; Barbe, T.; Pezel, T.; Mika, D.; Cellier, J.; Geneste, L.; Panagides, V.; Marsou, W.; Deney, A.; Attou, S.; Delmotte, T.; Ribeyrolles, S.; Chemaly, P.; Karsenty, C.; Giordano, G.; Gautier, A.; Duceau, B.; Sutter, W.; Chaumont, C.; Guilleminot, P.; Sagnard, A.; Pastier, J.; Trimaille, A.; Bonnet, G.; Canu, M.; Coisne, A.; Cohen, A., Prognostic value of right ventricular dilatation in patients with COVID-19: a multicentre study. *Eur Heart J Cardiovasc Imaging* **2021**.
17. Mancini, I.; Baronciani, L.; Artoni, A.; Colpani, P.; Biganzoli, M.; Cozzi, G.; Novembrino, C.; Boscolo Anzoletti, M.; De Zan, V.; Pagliari, M. T.; Gualtierotti, R.; Aliberti, S.; Panigada, M.; Grasselli, G.; Blasi, F.; Peyvandi, F., The ADAMTS13-von Willebrand factor axis in COVID-19 patients. *J Thromb Haemost* **2021,** 19, (2), 513-521.
18. Middleton, E. A.; He, X. Y.; Denorme, F.; Campbell, R. A.; Ng, D.; Salvatore, S. P.; Mostyka, M.; Baxter-Stoltzfus, A.; Borczuk, A. C.; Loda, M.; Cody, M. J.; Manne, B. K.; Portier, I.; Harris, E.; Petrey, A. C.; Beswick, E. J.; Caulin, A. F.; Iovino, A.; Abegglen, L. M.; Weyrich, A. S.; Rondina, M. T.; Egeblad, M.; Schiffman, J. D.; Yost, C. C., Neutrophil Extracellular Traps (NETs) Contribute to Immunothrombosis in COVID-19 Acute Respiratory Distress Syndrome. *Blood* **2020**.
19. Menter, T.; Haslbauer, J. D.; Nienhold, R.; Savic, S.; Deigendesch, H.; Frank, S.; Turek, D.; Willi, N.; Pargger, H.; Bassetti, S.; Leuppi, J. D.; Cathomas, G.; Tolnay, M.; Mertz, K. D.; Tzankov, A., Postmortem examination of COVID-19 patients reveals diffuse alveolar damage with severe capillary congestion and variegated findings in lungs and other organs suggesting vascular dysfunction. *Histopathology* **2020**.
20. Meizoso, J. P.; Moore, H. B.; Moore, E. E., Fibrinolysis Shutdown in COVID-19: Clinical Manifestations, Molecular Mechanisms, and Therapeutic Implications. *J Am Coll Surg* **2021,** 232, (6), 995-1003.
21. Pretorius, E.; Venter, C.; Laubscher, G. J.; Lourens, P. J.; Steenkamp, J.; Kell, D. B., Prevalence of readily detected amyloid blood clots in 'unclotted' Type 2 Diabetes Mellitus and COVID-19 plasma: a preliminary report. *Cardiovasc Diabetol* **2020,** 19, (1), 193.
22. Venter, C.; Bezuidenhout, J. A.; Laubscher, G. J.; Lourens, P. J.; Steenkamp, J.; Kell, D. B.; Pretorius, E., Erythrocyte, Platelet, Serum Ferritin, and P-Selectin Pathophysiology Implicated in Severe Hypercoagulation and Vascular Complications in COVID-19. *Int J Mol Sci* **2020,** 21, (21).

23. Pretorius, E.; Vlok, M.; Venter, C.; Bezuidenhout, J. A.; Laubscher, G. J.; Steenkamp, J.; Kell, D. B., Persistent clotting protein pathology in Long COVID/Post-Acute Sequelae of COVID-19 (PASC) is accompanied by increased levels of antiplasmin. *Cardiovasc Diabetol* **2021,** 20, (1), 172.
24. Walsh, M. M.; Khan, R.; Kwaan, H. C.; Neal, M. D., Fibrinolysis Shutdown in COVID-19-Associated Coagulopathy: A Crosstalk among Immunity, Coagulation, and Specialists in Medicine and Surgery. *J Am Coll Surg* **2021,** 232, (6), 1003-1006.
25. Giannis, D.; Ziogas, I. A.; Gianni, P., Coagulation disorders in coronavirus infected patients: COVID-19, SARS-CoV-1, MERS-CoV and lessons from the past. *J Clin Virol* **2020,** 127, 104362.
26. Kollias, A.; Kyriakoulis, K. G.; Dimakakos, E.; Poulakou, G.; Stergiou, G. S.; Syrigos, K., Thromboembolic risk and anticoagulant therapy in COVID-19 patients: emerging evidence and call for action. *Br J Haematol* **2020,** 189, (5), 846-847.
27. Middeldorp, S.; Coppens, M.; van Haaps, T. F.; Foppen, M.; Vlaar, A. P.; Müller, M. C. A.; Bouman, C. C. S.; Beenen, L. F. M.; Kootte, R. S.; Heijmans, J.; Smits, L. P.; Bonta, P. I.; van Es, N., Incidence of venous thromboembolism in hospitalized patients with COVID-19. *J Thromb Haemost* **2020,** 18, (8), 1995-2002.
28. Miesbach, W.; Makris, M., COVID-19: Coagulopathy, Risk of Thrombosis, and the Rationale for Anticoagulation. *Clin Appl Thromb Hemost* **2020,** 26, 1076029620938149.
29. Levi, M.; Thachil, J.; Iba, T.; Levy, J. H., Coagulation abnormalities and thrombosis in patients with COVID-19. *Lancet Haematol* **2020,** 7, (6), e438-e440.
30. Liu, P. P.; Blet, A.; Smyth, D.; Li, H., The Science Underlying COVID-19: Implications for the Cardiovascular System. *Circulation* **2020,** 142, (1), 68-78.
31. Kell, D. B.; Pretorius, E., The simultaneous occurrence of both hypercoagulability and hypofibrinolysis in blood and serum during systemic inflammation, and the roles of iron and fibrin(ogen). *Integrative Biology* **2015,** 7, 24-52.
32. Kell, D. B.; Pretorius, E., No effects without causes: the Iron Dysregulation and Dormant Microbes hypothesis for chronic, inflammatory diseases. *Biol Rev Camb Philos Soc* **2018,** 93, (3), 1518-1557.
33. Kell, D. B.; Pretorius, E., To What Extent Are the Terminal Stages of Sepsis, Septic Shock, Systemic Inflammatory Response Syndrome, and Multiple Organ Dysfunction Syndrome Actually Driven by a Prion/Amyloid Form of Fibrin? *Semin Thromb Hemost* **2018,** 44, (3), 224-238.
34. Tang, N.; Li, D.; Wang, X.; Sun, Z., Abnormal coagulation parameters are associated with poor prognosis in patients with novel coronavirus pneumonia. *J Thromb Haemost* **2020,** 18, (4), 844-847.
35. Choudhary, S.; Sharma, K.; Singh, P. K., Von Willebrand factor: A key glycoprotein involved in thrombo-inflammatory complications of COVID-19. *Chem Biol Interact* **2021,** 348, 109657.
36. Spiezia, L.; Boscolo, A.; Poletto, F.; Cerruti, L.; Tiberio, I.; Campello, E.; Navalesi, P.; Simioni, P., COVID-19-Related Severe Hypercoagulability in Patients Admitted to Intensive Care Unit for Acute Respiratory Failure. *Thromb Haemost* **2020,** 120, (6), 998-1000.
37. Costello, R. A.; Nehring, S. M., Disseminated Intravascular Coagulation (DIC). In *StatPearls*, StatPearls Publishing
Copyright © 2020, StatPearls Publishing LLC.: Treasure Island (FL), 2020.

38. Aigner, L.; Pietrantonio, F.; Bessa de Sousa, D. M.; Michael, J.; Schuster, D.; Reitsamer, H. A.; Zerbe, H.; Studnicka, M., The Leukotriene Receptor Antagonist Montelukast as a Potential COVID-19 Therapeutic. *Front Mol Biosci* **2020,** 7, 610132.
39. Grobler, C.; Bredenkamp, J.; Grobbelaar, M.; Maphumulo, S.; Laubscher, J.; Steenkamp, J.; Kell, D. B.; Pretorius, E., COVID-19: The Rollercoaster of Fibrin(ogen), D-dimer, von Willebrand Factor, P-selectin and Their Interactions with Endothelial Cells, Platelets and Erythrocytes. . *Preprints* **2020,** 2020070142.
40. Al-Samkari, H.; Karp Leaf, R. S.; Dzik, W. H.; Carlson, J. C.; Fogerty, A. E.; Waheed, A.; Goodarzi, K.; Bendapudi, P.; Bornikova, L.; Gupta, S.; Leaf, D.; Kuter, D. J.; Rosovsky, R. P., COVID and Coagulation: Bleeding and Thrombotic Manifestations of SARS-CoV2 Infection. *Blood* **2020**.
41. Bikdeli, B.; Madhavan, M. V.; Jimenez, D.; Chuich, T.; Dreyfus, I.; Driggin, E.; Nigoghossian, C.; Ageno, W.; Madjid, M.; Guo, Y.; Tang, L. V.; Hu, Y.; Giri, J.; Cushman, M.; Quéré, I.; Dimakakos, E. P.; Gibson, C. M.; Lippi, G.; Favaloro, E. J.; Fareed, J.; Caprini, J. A.; Tafur, A. J.; Burton, J. R.; Francese, D. P.; Wang, E. Y.; Falanga, A.; McLintock, C.; Hunt, B. J.; Spyropoulos, A. C.; Barnes, G. D.; Eikelboom, J. W.; Weinberg, I.; Schulman, S.; Carrier, M.; Piazza, G.; Beckman, J. A.; Steg, P. G.; Stone, G. W.; Rosenkranz, S.; Goldhaber, S. Z.; Parikh, S. A.; Monreal, M.; Krumholz, H. M.; Konstantinides, S. V.; Weitz, J. I.; Lip, G. Y. H., COVID-19 and Thrombotic or Thromboembolic Disease: Implications for Prevention, Antithrombotic Therapy, and Follow-Up: JACC State-of-the-Art Review. *J Am Coll Cardiol* **2020,** 75, (23), 2950-2973.
42. Boccia, M.; Aronne, L.; Celia, B.; Mazzeo, G.; Ceparano, M.; D'Agnano, V.; Parrella, R.; Valente, T.; Bianco, A.; Perrotta, F., COVID-19 and coagulative axis: review of emerging aspects in a novel disease. *Monaldi Arch Chest Dis* **2020,** 90, (2).
43. Li, C.; Hu, B.; Zhang, Z.; Qin, W.; Zhu, Z.; Zhai, Z.; Davidson, B. L.; Wang, C., D-dimer triage for COVID-19. *Acad Emerg Med* **2020**.
44. Wright, F. L.; Vogler, T. O.; Moore, E. E.; Moore, H. B.; Wohlauer, M. V.; Urban, S.; Nydam, T. L.; Moore, P. K.; McIntyre, R. C., Jr., Fibrinolysis Shutdown Correlation with Thromboembolic Events in Severe COVID-19 Infection. *J Am Coll Surg* **2020**.
45. Zou, Y.; Guo, H.; Zhang, Y.; Zhang, Z.; Liu, Y.; Wang, J.; Lu, H.; Qian, Z., Analysis of coagulation parameters in patients with COVID-19 in Shanghai, China. *Biosci Trends* **2020**.
46. Connors, J. M.; Levy, J. H., COVID-19 and its implications for thrombosis and anticoagulation. *Blood* **2020,** 135, (23), 2033-2040.
47. Sinha, P.; Matthay, M. A.; Calfee, C. S., Is a "Cytokine Storm" Relevant to COVID-19? *JAMA Intern Med* **2020**.
48. Goshua, G.; Pine, A. B.; Meizlish, M. L.; Chang, C. H.; Zhang, H.; Bahel, P.; Baluha, A.; Bar, N.; Bona, R. D.; Burns, A. J.; Dela Cruz, C. S.; Dumont, A.; Halene, S.; Hwa, J.; Koff, J.; Menninger, H.; Neparidze, N.; Price, C.; Siner, J. M.; Tormey, C.; Rinder, H. M.; Chun, H. J.; Lee, A. I., Endotheliopathy in COVID-19-associated coagulopathy: evidence from a single-centre, cross-sectional study. *Lancet Haematol* **2020,** 7, (8), e575-e582.
49. Dwiputra Hernugrahanto, K.; Novembri Utomo, D.; Hariman, H.; Budhiparama, N. C.; Medika Hertanto, D.; Santoso, D.; Hogendoorn, P. C. W., Thromboembolic involvement and its possible pathogenesis in COVID-19 mortality: lesson from post-mortem reports. *Eur Rev Med Pharmacol Sci* **2021,** 25, (3), 1670-1679.
50. Neri, T.; Nieri, D.; Celi, A., P-selectin blockade in COVID-19-related ARDS. *Am J Physiol Lung Cell Mol Physiol* **2020,** 318, (6), L1237-l1238.

51. Panigada, M.; Bottino, N.; Tagliabue, P.; Grasselli, G.; Novembrino, C.; Chantarangkul, V.; Pesenti, A.; Peyvandi, F.; Tripodi, A., Hypercoagulability of COVID-19 patients in Intensive Care Unit. A Report of Thromboelastography Findings and other Parameters of Hemostasis. *J Thromb Haemost* **2020**.
52. Garcia-Olivé, I.; Sintes, H.; Radua, J.; Abad Capa, J.; Rosell, A., D-dimer in patients infected with COVID-19 and suspected pulmonary embolism. *Respir Med* **2020,** 169, 106023.
53. Li, Y.; Zhao, K.; Wei, H.; Chen, W.; Wang, W.; Jia, L.; Liu, Q.; Zhang, J.; Shan, T.; Peng, Z.; Liu, Y.; Yan, X., Dynamic relationship between D-dimer and COVID-19 severity. *Br J Haematol* **2020**.
54. Favaloro, E. J.; Thachil, J., Reporting of D-dimer data in COVID-19: some confusion and potential for misinformation. *Clin Chem Lab Med* **2020**.
55. Lippi, G.; Favaloro, E. J., D-dimer is Associated with Severity of Coronavirus Disease 2019: A Pooled Analysis. *Thromb Haemost* **2020,** 120, (5), 876-878.
56. Pretorius, E.; Page, M. J.; Engelbrecht, L.; Ellis, G. C.; Kell, D. B., Substantial fibrin amyloidogenesis in type 2 diabetes assessed using amyloid-selective fluorescent stains. *Cardiovasc Diabetol* **2017,** 16, (1), 141.
57. Lopes, R. D.; de Barros, E. S. P. G. M.; Furtado, R. H. M.; Macedo, A. V. S.; Bronhara, B.; Damiani, L. P.; Barbosa, L. M.; de Aveiro Morata, J.; Ramacciotti, E.; de Aquino Martins, P.; de Oliveira, A. L.; Nunes, V. S.; Ritt, L. E. F.; Rocha, A. T.; Tramujas, L.; Santos, S. V.; Diaz, D. R. A.; Viana, L. S.; Melro, L. M. G.; de Alcântara Chaud, M. S.; Figueiredo, E. L.; Neuenschwander, F. C.; Dracoulakis, M. D. A.; Lima, R.; de Souza Dantas, V. C.; Fernandes, A. C. S.; Gebara, O. C. E.; Hernandes, M. E.; Queiroz, D. A. R.; Veiga, V. C.; Canesin, M. F.; de Faria, L. M.; Feitosa-Filho, G. S.; Gazzana, M. B.; Liporace, I. L.; de Oliveira Twardowsky, A.; Maia, L. N.; Machado, F. R.; de Matos Soeiro, A.; Conceição-Souza, G. E.; Armaganijan, L.; Guimarães, P. O.; Rosa, R. G.; Azevedo, L. C. P.; Alexander, J. H.; Avezum, A.; Cavalcanti, A. B.; Berwanger, O., Therapeutic versus prophylactic anticoagulation for patients admitted to hospital with COVID-19 and elevated D-dimer concentration (ACTION): an open-label, multicentre, randomised, controlled trial. *Lancet* **2021,** 397, (10291), 2253-2263.
58. Escher, R.; Breakey, N.; Lämmle, B., Severe COVID-19 infection associated with endothelial activation. *Thromb Res* **2020,** 190, 62.
59. Zachariah, U.; Nair, S. C.; Goel, A.; Balasubramanian, K. A.; Mackie, I.; Elias, E.; Eapen, C. E., Targeting raised von Willebrand factor levels and macrophage activation in severe COVID-19: Consider low volume plasma exchange and low dose steroid. *Thromb Res* **2020,** 192, 2.
60. Chapman, M. P.; Moore, E. E.; Ramos, C. R.; Ghasabyan, A.; Harr, J. N.; Chin, T. L.; Stringham, J. R.; Sauaia, A.; Silliman, C. C.; Banerjee, A., Fibrinolysis greater than 3% is the critical value for initiation of antifibrinolytic therapy. *J Trauma Acute Care Surg* **2013,** 75, (6), 961-7; discussion 967.
61. Görlinger, K.; Levy, J. H., COVID-19–associated Coagulopathy: Less Fibrinolysis Can Be More Harmful! *Anesthesiology* **2021,** 134, (3), 366-369.
62. Chandel, A.; Patolia, S.; Looby, M.; Bade, N.; Khangoora, V.; King, C. S., Association of D-dimer and Fibrinogen With Hypercoagulability in COVID-19 Requiring Extracorporeal Membrane Oxygenation. *J Intensive Care Med* **2021**, 885066621997039.

63. Hranjec, T.; Estreicher, M.; Rogers, B.; Kohler, L.; Solomon, R.; Hennessy, S.; Cibulas, M.; Hurst, D.; Hegazy, M.; Lee, J.; Perez, D.; Doctor, N.; Kiffin, C.; Pigneri, D.; LaGuardia, H.; Shaw, K.; Arenas, J.; Rosenthal, A.; Katz, R. S.; Sawyer, R. G.; Pepe, P. E., Integral Use of Thromboelastography With Platelet Mapping to Guide Appropriate Treatment, Avoid Complications, and Improve Survival of Patients With Coronavirus Disease 2019-Related Coagulopathy. *Crit Care Explor* **2020,** 2, (12), e0287.
64. Smolarz, A.; McCarthy, P.; Shmookler, A.; Badhwar, V.; Hayanga, A. J.; Sakhuja, A., Utilization of Thromboelastogram and Inflammatory Markers in the Management of Hypercoagulable State in Patients with COVID-19 Requiring ECMO Support. *Case Rep Crit Care* **2021,** 2021, 8824531.
65. Favaloro, E. J.; Bonar, R., An update on quality control for the PFA-100/PFA-200. *Platelets* **2018,** 29, (6), 622-627.
66. Nielsen, V. G., Kirklin H.K., Hoogendoorn H, Ellis T.C., Holman W.L., Thromboelastographic method to quantify the contribution of factor XIII to coagulation kinetics. *Blood coagulation & Fibrinolysis: an international journal in haemostasis and thrombosis* **2007,** 18, (2), 145-150.
67. Nielsen, V. G., Beyond cell based models of coagulation: analyses of coagulation with clot "lifespan" resistance-time relationships. *Thromb Res* **2008,** 122, (2), 145-52.
68. Nielsen, V. G., Effects of purified human fibrinogen modified with carbon monoxide and iron on coagulation in rabbits injected with Crotalus atrox venom. *Journal of thrombosis and thrombolysis* **2017,** 44, (4), 481-488.
69. Nielsen, V. G.; Audu, P.; Cankovic, L.; Lyerly, R. T., 3rd; Steenwyk, B. L.; Armstead, V.; Powell, G., Qualitative thrombelastographic detection of tissue factor in human plasma. *Anesthesia and analgesia* **2007,** 104, (1), 59-64.
70. Pretorius, E.; Swanepoel, A. C.; DeVilliers, S.; Bester, J., Blood clot parameters: Thromboelastography and scanning electron microscopy in research and clinical practice. *Thrombosis research* **2017,** 154, 59-63.
71. Bester, J.; Matshailwe, C.; Pretorius, E., Simultaneous presence of hypercoagulation and increased clot lysis time due to IL-1β, IL-6 and IL-8. *Cytokine* **2018**, S1043-4666(18)30007-3. .
72. Bester, J.; Pretorius, E., Effects of IL-1β, IL-6 and IL-8 on erythrocytes, platelets and clot viscoelasticity. *Scientific Reports* **2016,** 6, 32188.
73. Bester, J.; Soma, P.; Kell, D. B.; Pretorius, E., Viscoelastic and ultrastructural characteristics of whole blood and plasma in Alzheimer-type dementia, and the possible role of bacterial lipopolysaccharides (LPS). *Oncotarget* **2015,** 6, 35284-303.
74. Pretorius, L.; Thomson, G. J. A.; Adams, R. C. M.; Nell, T. A.; Laubscher, W. A.; Pretorius, E., Platelet activity and hypercoagulation in type 2 diabetes. *Cardiovasc Diabetol* **2018,** 17, (1), 141.
75. Randeria, S. N.; Thomson, G. J. A.; Nell, T. A.; Roberts, T.; Pretorius, E., Inflammatory cytokines in type 2 diabetes mellitus as facilitators of hypercoagulation and abnormal clot formation. *Cardiovascular diabetology* **2019,** 18, (1), 72-72.
76. Kell, D. B.; Pretorius, E., Proteins behaving badly. Substoichiometric molecular control and amplification of the initiation and nature of amyloid fibril formation: lessons from and for blood clotting. *Prog Biophys Mol Biol* **2017,** 123, 16-41.
77. Page, M. J.; Thomson, G. J. A.; Nunes, J. M.; Engelbrecht, A. M.; Nell, T. A.; de Villiers, W. J. S.; de Beer, M. C.; Engelbrecht, L.; Kell, D. B.; Pretorius, E., Serum amyloid A binds to fibrin(ogen), promoting fibrin amyloid formation. *Sci Rep* **2019,** 9, (1), 3102.

78. Pretorius, E.; Mbotwe, S.; Bester, J.; Robinson, C. J.; Kell, D. B., Acute induction of anomalous and amyloidogenic blood clotting by molecular amplification of highly substoichiometric levels of bacterial lipopolysaccharide. *Journal of the Royal Society, Interface / the Royal Society* **2016,** 13, (122).
79. Nunes, J. M.; Fillis, T.; Page. M. J; Venter, C.; Lancry, O.; Kell, D. B.; Windberger, U.; Pretorius, E., Gingipain R1 and lipopolysaccharide from Porphyromonas gingivalis have major effects on blood clot morphology and mechanics. *Frontiers in Immunology* **2020,** In Press.
80. Alhazzani, W.; Møller, M. H.; Arabi, Y. M.; Loeb, M.; Gong, M. N.; Fan, E.; Oczkowski, S.; Levy, M. M.; Derde, L.; Dzierba, A.; Du, B.; Aboodi, M.; Wunsch, H.; Cecconi, M.; Koh, Y.; Chertow, D. S.; Maitland, K.; Alshamsi, F.; Belley-Cote, E.; Greco, M.; Laundy, M.; Morgan, J. S.; Kesecioglu, J.; McGeer, A.; Mermel, L.; Mammen, M. J.; Alexander, P. E.; Arrington, A.; Centofanti, J. E.; Citerio, G.; Baw, B.; Memish, Z. A.; Hammond, N.; Hayden, F. G.; Evans, L.; Rhodes, A., Surviving Sepsis Campaign: Guidelines on the Management of Critically Ill Adults with Coronavirus Disease 2019 (COVID-19). *Crit Care Med* **2020,** 48, (6), e440-e469.
81. Wilson, K. C.; Chotirmall, S. H.; Bai, C.; Rello, J., COVID-19: Interim Guidance on Management Pending Empirical
Evidence. https://www.thoracic.org/covid/covid-19-guidance.pdf. *American Thoracic Society-led International*
Task Force **2020**.
82. Ayerbe, L.; Risco, C.; Ayis, S., The association between treatment with heparin and survival in patients with Covid-19. *Journal of thrombosis and thrombolysis* **2020**, 1-4.
83. Menezes-Rodrigues, F. S.; Padrão Tavares, J. G.; Pires de Oliveira, M.; Guzella de Carvalho, R.; Ruggero Errante, P.; Omar Taha, M.; Fagundes, D. J.; Caricati-Neto, A., Anticoagulant and antiarrhythmic effects of heparin in the treatment of COVID-19 patients. *J Thromb Haemost* **2020**.
84. Tang, N.; Bai, H.; Chen, X.; Gong, J.; Li, D.; Sun, Z., Anticoagulant treatment is associated with decreased mortality in severe coronavirus disease 2019 patients with coagulopathy. *Journal of Thrombosis and Haemostasis* **2020,** 18, (5), 1094-1099.
85. Lawler, P. R.; Goligher, E. C.; Berger, J. S.; Neal, M. D.; McVerry, B. J.; Nicolau, J. C.; Gong, M. N.; Carrier, M.; Rosenson, R. S.; Reynolds, H. R.; Turgeon, A. F.; Escobedo, J.; Huang, D. T.; Bradbury, C. A.; Houston, B. L.; Kornblith, L. Z.; Kumar, A.; Kahn, S. R.; Cushman, M.; McQuilten, Z.; Slutsky, A. S.; Kim, K. S.; Gordon, A. C.; Kirwan, B. A.; Brooks, M. M.; Higgins, A. M.; Lewis, R. J.; Lorenzi, E.; Berry, S. M.; Berry, L. R.; Aday, A. W.; Al-Beidh, F.; Annane, D.; Arabi, Y. M.; Aryal, D.; Baumann Kreuziger, L.; Beane, A.; Bhimani, Z.; Bihari, S.; Billett, H. H.; Bond, L.; Bonten, M.; Brunkhorst, F.; Buxton, M.; Buzgau, A.; Castellucci, L. A.; Chekuri, S.; Chen, J. T.; Cheng, A. C.; Chkhikvadze, T.; Coiffard, B.; Costantini, T. W.; de Brouwer, S.; Derde, L. P. G.; Detry, M. A.; Duggal, A.; Džavík, V.; Effron, M. B.; Estcourt, L. J.; Everett, B. M.; Fergusson, D. A.; Fitzgerald, M.; Fowler, R. A.; Galanaud, J. P.; Galen, B. T.; Gandotra, S.; García-Madrona, S.; Girard, T. D.; Godoy, L. C.; Goodman, A. L.; Goossens, H.; Green, C.; Greenstein, Y. Y.; Gross, P. L.; Hamburg, N. M.; Haniffa, R.; Hanna, G.; Hanna, N.; Hegde, S. M.; Hendrickson, C. M.; Hite, R. D.; Hindenburg, A. A.; Hope, A. A.; Horowitz, J. M.; Horvat, C. M.; Hudock, K.; Hunt, B. J.; Husain, M.; Hyzy, R. C.; Iyer, V. N.; Jacobson, J. R.; Jayakumar, D.; Keller, N. M.; Khan, A.; Kim, Y.; Kindzelski, A. L.; King, A. J.; Knudson, M. M.; Kornblith, A. E.; Krishnan, V.; Kutcher, M. E.; Laffan, M. A.; Lamontagne, F.; Le Gal, G.; Leeper, C. M.;

Leifer, E. S.; Lim, G.; Lima, F. G.; Linstrum, K.; Litton, E.; Lopez-Sendon, J.; Lopez-Sendon Moreno, J. L.; Lother, S. A.; Malhotra, S.; Marcos, M.; Saud Marinez, A.; Marshall, J. C.; Marten, N.; Matthay, M. A.; McAuley, D. F.; McDonald, E. G.; McGlothlin, A.; McGuinness, S. P.; Middeldorp, S.; Montgomery, S. K.; Moore, S. C.; Morillo Guerrero, R.; Mouncey, P. R.; Murthy, S.; Nair, G. B.; Nair, R.; Nichol, A. D.; Nunez-Garcia, B.; Pandey, A.; Park, P. K.; Parke, R. L.; Parker, J. C.; Parnia, S.; Paul, J. D.; Pérez González, Y. S.; Pompilio, M.; Prekker, M. E.; Quigley, J. G.; Rost, N. S.; Rowan, K.; Santos, F. O.; Santos, M.; Olombrada Santos, M.; Satterwhite, L.; Saunders, C. T.; Schutgens, R. E. G.; Seymour, C. W.; Siegal, D. M.; Silva, D. G., Jr.; Shankar-Hari, M.; Sheehan, J. P.; Singhal, A. B.; Solvason, D.; Stanworth, S. J.; Tritschler, T.; Turner, A. M.; van Bentum-Puijk, W.; van de Veerdonk, F. L.; van Diepen, S.; Vazquez-Grande, G.; Wahid, L.; Wareham, V.; Wells, B. J.; Widmer, R. J.; Wilson, J. G.; Yuriditsky, E.; Zampieri, F. G.; Angus, D. C.; McArthur, C. J.; Webb, S. A.; Farkouh, M. E.; Hochman, J. S.; Zarychanski, R., Therapeutic Anticoagulation with Heparin in Noncritically Ill Patients with Covid-19. *N Engl J Med* **2021,** 385, (9), 790-802.

86. Ten Cate, H., Surviving Covid-19 with Heparin? *N Engl J Med* **2021,** 385, (9), 845-846.
87. Viecca, M.; Radovanovic, D.; Forleo, G. B.; Santus, P., Enhanced platelet inhibition treatment improves hypoxemia in patients with severe Covid-19 and hypercoagulability. A case control, proof of concept study. *Pharmacol Res* **2020,** 158, 104950.
88. Khan, A. R.; Misdary, C.; Yegya-Raman, N.; Kim, S.; Narayanan, N.; Siddiqui, S.; Salgame, P.; Radbel, J.; Groote, F.; Michel, C.; Mehnert, J.; Hernandez, C.; Braciale, T.; Malhotra, J.; Gentile, M. A.; Jabbour, S. K., Montelukast in hospitalized patients diagnosed with COVID-19. *J Asthma* **2021**, 1-7.
89. Barré, J.; Sabatier, J. M.; Annweiler, C., Montelukast Drug May Improve COVID-19 Prognosis: A Review of Evidence. *Front Pharmacol* **2020,** 11, 1344.
90. Almerie, M. Q.; Kerrigan, D. D., The association between obesity and poor outcome after COVID-19 indicates a potential therapeutic role for montelukast. *Med Hypotheses* **2020,** 143, 109883.
91. Dey, M.; Singh, R. K., Possible Therapeutic Potential of Cysteinyl Leukotriene Receptor Antagonist Montelukast in Treatment of SARS-CoV-2-Induced COVID-19. *Pharmacology* **2021,** 106, (9-10), 469-476.
92. Fidan, C.; Aydoğdu, A., As a potential treatment of COVID-19: Montelukast. *Med Hypotheses* **2020,** 142, 109828.
93. Sanghai, N.; Tranmer, G. K., Taming the cytokine storm: repurposing montelukast for the attenuation and prophylaxis of severe COVID-19 symptoms. *Drug Discov Today* **2020,** 25, (12), 2076-2079.
94. Al-Kuraishy, H. M.; Al-Gareeb, A. I.; Almulaiky, Y. Q.; Cruz-Martins, N.; El-Saber Batiha, G., Role of leukotriene pathway and montelukast in pulmonary and extrapulmonary manifestations of Covid-19: The enigmatic entity. *Eur J Pharmacol* **2021,** 904, 174196.
95. Zaid, Y.; Puhm, F.; Allaeys, I.; Naya, A.; Oudghiri, M.; Khalki, L.; Limami, Y.; Zaid, N.; Sadki, K.; Ben El Haj, R.; Mahir, W.; Belayachi, L.; Belefquih, B.; Benouda, A.; Cheikh, A.; Langlois, M. A.; Cherrah, Y.; Flamand, L.; Guessous, F.; Boilard, E., Platelets Can Associate with SARS-Cov-2 RNA and Are Hyperactivated in COVID-19. *Circ Res* **2020,** 127, (11), 1404-18.

96. Lu, Q.; Malinauskas, R. A., Comparison of two platelet activation markers using flow cytometry after in vitro shear stress exposure of whole human blood. *Artif Organs* **2011,** 35, (2), 137-44.
97. Oldenburg, C. E.; Doan, T., Rigorous Randomized Controlled Trial Implementation in the Era of COVID-19. *Am J Trop Med Hyg* **2020,** 102, (6), 1154-1155.