Is endometriosis metastasizing? Shared somatic alterations suggest common origins across endometriotic lesions.

Teresa H. Praetorius[1,2], Vivian Lac[2], Basile Tessier-Cloutier[2,3], Janine Senz[2], Tayyebeh M. Nazeran[2], Martin Köbel[4], Marcel Grube[1], Bernhard Krämer[1], Paul J. Yong[2,5,6], Stefan Kommoss[1,*], Michael S. Anglesio[2,5*]

Affiliations:

1) Department of Women's Health, Tübingen University Hospital, 72076 Tübingen, Germany
2) British Columbia's Gynecological Cancer Research (OVCARE) Program, University of British Columbia, Vancouver General Hospital, and BC Cancer, Vancouver, BC, Canada, V5Z 4E6
3) Department of Anatomical Pathology, Vancouver General Hospital, Vancouver, Canada, V5Z 1M9
4) Department of Pathology and Laboratory Medicine, University of Calgary, Calgary, Canada, T2N 2T9
5) Department of Obstetrics and Gynecology, University of British Columbia, Vancouver, Canada, V6H 3Z6
6) BC Women's Centre for Pelvic Pain & Endometriosis, BC Women's Hospital and Health Centre, Vancouver, Canada, V6H 3N1

*Corresponding Authors (equal contributions):

Dr. Michael S. Anglesio, PhD
m.anglesio@ubc.ca; University of British Columbia, OVCARE @ the Robert HN Ho Research Centre; 2660 Oak Street, Vancouver, BC, Canada. V6H 3Z6
Prof. Dr. med. Stefan Kommoss
stefan.kommoss@med.uni-tuebingen.de; Department of Women's Health, Tübingen University Hospital, Calwerstraße 7, 72076 Tübingen, Germany

Summary

Endometriosis has yielded controversy on whether it constitutes a single disease or distinct types. Current classification systems poorly correlate with the severity of symptoms and do not provide prognostic tools that can guide management or predict recurrence or success of treatment. Our previous work has uncovered recurrent cancer-driver alterations in endometriosis. Here we examined anatomically separate types of endometriosis (ovarian endometriomas, deep infiltrating, and superficial endometriosis) in 27 individual patients for evidence of a common origin. Specimens were analyzed using high-sensitivity targeted sequencing with orthogonal validation from droplet digital PCR and mutation-surrogate immunohistochemistry. Results show clonality between lesions is common (observed in 9/27 cases) and that endometriomas have potential for higher mutational load, often resulting in multiple subclonal lineages. Our data further confirms that endometriosis is generally an oligoclonal disease with dissemination likely to consist of multiple epithelial clones travelling together.

Keywords

Endometriosis; deep infiltrating endometriosis; endometrioma; clonality; metastasis; dissemination; targeted genomics; immunohistochemistry

Introduction

Endometriosis is a chronic estrogen-dependent inflammatory disease defined by the presence of endometrial epithelial glands and stroma outside the uterine lumen and a small but significant risk of malignant transformation (Giudice, 2010; Munksgaard and Blaakaer, 2012; Zondervan et al., 2020). It is estimated to affect up to 10% of women of reproductive age and can result in severe adverse effects on quality of life and productivity(Bulun, 2009; Eskenazi and Warner, 1997). Clinical symptoms of endometriosis are diverse and include pelvic pain, dysmenorrhea, dyspareunia and infertility. (Vercellini et al., 2014; Zondervan et al., 2020) Three major anatomically described types of endometriosis are recognized: superficial peritoneal endometriosis (EM), deep infiltrating endometriosis (DIE) and ovarian endometriomas (OMA). In addition, rare types such as mass forming/tumorous or iatrogenic forms also exist. Current classification systems such as the revised American Society for Reproductive Medicine (rASRM) scoring system and the ENZIAN classification for DIE are useful in documenting surgical findings in a standardized manner. However, they poorly correlate with the severity of symptoms and fail to provide a prognostic tool concerning the treatment outcome for pain or infertility(Johnson et al., 2017) (American Society for Reproductive Medicine, 1997). Current classification and staging of endometriosis are based on clinical findings and surgical presentation and do not include any information about the molecular potential or microenvironment of these lesions.

Recent studies have now shown that multiple forms of endometriosis harbor somatic cancer-driver alterations including recurrent activating changes in *KRAS, PIK3CA, ARID1A* and others (Anglesio et al., 2017; Lac et al., 2019b; Suda et al., 2018). While it appears the underlying malignant potential for the vast majority of lesions, despite the presence of recurrent driver mutations, remains low (Vercellini et al., 2014), their ultimate function in the pathobiology of endometriosis remains unclear. These findings are particularly important to monitoring disease since somatic alteration could be therapeutically targeted or tracked to examine etiology and potential disease dissemination. The concept that endometriosis disseminates is not novel. Endometriosis frequently presents with multiple anatomical sites affected by lesions and has an origin arguably attributed to displaced endometrial tissue, all endometriosis lesions may well have disseminated from a eutopic point of origin (Suda et al., 2020; Suda et al., 2018). Nonetheless, there is little objective evidence widespread clonal dissemination of endometriosis tissues.

Clinical presentation of endometriosis is heterogeneous and it is controversial whether endometriosis constitutes one disease entity or whether independent types with different underlying pathogenesis exist (Montgomery and Giudice, 2017). As noted above somatic alteration could be used to examine the spread and distribution of distinct endometriosis clones within a given woman. Here we explored the potential clonal relationship of endometriosis from 27 women with multiple anatomically separated lesions, and each having at least two distinct types of endometriosis. Our initial objective was clonality at the level of endometriosis anatomically described types, asking questions such as: are mutations frequently shared between lesions and/or between lesion types. If they are not this would suggest each anatomically defined type represents a unique disease. If they are this would indicate plasticity between types and/or that our understanding of endometriosis types is currently insufficient.

Results

We examined 73 endometriosis lesions from 27 women with a mean age of 34.9 years (23-45 years; Table S1; Figure S1). 53 lesions were subjected to panel-based sequencing with validation of selected

alteration by ddPCR, 6 additional samples included in ddPCR validation only, when possible lesions from the full panel were also subject to mutation-surrogate IHC for PTEN (66 interpretable), ARID1A (66 interpretable) and p53 (47 interpretable). A total of 27/59 (45.8%) lesions from 13/27 (48%) cases were confirmed to have identifiable somatic cancer-driver mutations. It should be noted that lesion with mutations observed near, but below, our positive detection thresholds were considered negative, as were alteration which appeared above threshold in panel sequencing data but failed to exceed detection threshold in ddPCR. For example, in a 14th case panel testing suggested alteration but these fell below detection threshold at the ddPCR stage (case 7; Table S1). Nonetheless, potential interpretation for sub-clonal/sub-detection threshold alterations is discussed in a limited context where relevant.

Amongst the panel screened lesions, where identical assays were applied, *PIK3CA* alterations were the most common (27 hotspot mutations, affecting 12/53 lesions in 6 cases), followed by *KRAS* (16 hotspot mutations, affecting 15 lesions in 6 cases) and *CTNNB1* (10 hotspot mutations, affecting 7/53 lesions in 4 cases; Figure 1). Alterations were less frequently observed in *NRAS* (6 mutations, 6/53 lesions, 4 cases), *ERBB2* (2 mutations, 2/53 lesions, 1 case) and *EGFR* (2 mutations, 2/53 lesions, 2 cases). Although our cohort had insufficient numbers to support strong associations, we noted many lesions, predominantly amongst OMA, contained multiple mutations in the same genes. OMA also tended to have higher mutational burden on average (amongst our screened panel mutations). No samples had identifiable p53-abnormal staining pattern (0/47 lesions), PTEN loss was observed in 5 cases (8/66 lesions), and ARID1A loss was observed in 1 case (2/66 lesions).

Immunohistochemical data is inconclusive with respect to clonality and similar abnormal patterns were considered in support mutation findings. Our mutation data suggested a single *TP53* alteration but no abnormal p53 pattern was observed by IHC, we considered this as a false positive (case 22; Table S1A). We observed no *PTEN* mutations in sequencing data despite evidence of loss in PTEN protein expression by IHC in 8/66 lesions (Table S1B), however only a small number of hotspots are covered in panel sequencing. In one case (case 2) with PTEN loss in multiple lesions other somatic (clonal) point mutations were shared between the PTEN-loss affected lesions (Table 1; Table S1A). Case 3 showed loss of ARID1A protein consistent with loss-of function somatic mutation (Khalique et al., 2018) in both an EM and OMA samples from this patient (Figure 2). Unfortunately, insufficient tissue was available to validate any mutation in the EM sample however *PIK3CA* and *KRAS* alterations were shared across all other lesions from this case. Altogether we observed clonality between at least two endometriotic lesions in 8 out of 13 informative cases (Table S1A; Figure S2).

For ease in presenting results details we have divided informative cases into two categories. Simple cases, with only one or two altered genes and/or one or two informative lesions, and complex cases, with larger numbers of alterations across lesions and lesions with functionally redundant mutations.

<u>Simple cases</u>

We annotated 7 cases as simple (Table 1) based on presence of up to 2 alterations and no functionally redundant (i.e. equivalent activating change resulting from different nucleotide and/or amino acid substitution in the same gene) mutations seen in same lesion. We identified and validated shared mutations across multiple lesions and different types in 3 cases (Figure S2). Case 6 shared mutations in *PIK3CA* between EM and DIE. The other two cases shared mutations in *KRAS*. Case 19 shared a p.Gly12Ser mutation between an OMA and a DIE. Case 21 shared a p.Gly12Asp between an OMA and three different DIE lesions.

In 4 cases mutations were uninformative with respect to clonality (Figure S2), 3 of which had mutations observed in only a single lesion (*KRAS* or *EGFR*). In the last (Case 9) we detected different mutations in the lesions, consisting of different *KRAS* alterations as well as one *PIK3CA* alteration - none shared between lesions.

Complex Cases

All six cases in this complex category showed evidence of a clonal relationships between lesions and in each case at least one lesion showed multiple functionally redundant hotspot alterations (Figure S2; Figure 2 and 3). In one case we observed identical somatic alterations between EM and DIE lesions (case 13), in 4 cases between DIE and OMA (cases 1, 2, 3, 8; Figure 2) and in one case between all three types (case 4; Figure 3). Functional redundancy was most common with *PIK3CA*, seen in 12 lesions across 5 cases. Up to 5 simultaneously observed activating changes in *PIK3CA* were validated in a single lesion (case 2). In 4/5 cases with *PIK3CA* mutations we further observed co-existing alterations in *CTNNB1*, where at least one was shared across multiple sites/types within the affected patient. In 3/4 cases redundancy in *CTNNB1* was seen with up to 3 simultaneously observed alterations in the same lesion (case 1 OMA; case 2 DIE; and case 4 shared between DIE and EM). The fourth case had only a single observed (*PIK3CA*) co-existing *CTNNB1* alteration shared between an OMA and a DIE (case 8). A single complex case with a *PIK3CA* alteration had no co-existing *CTNNB1* alterations, at least within our panel assay and therefore no further testing by ddPCR was done. A single case (Case 13) lacking *PIK3CA* alteration did have multiple redundant *CTNNB1* alterations, with at least one shared between DIE and EM (an OMA specimen from the same case had insufficient material for testing).

KRAS alterations were seen in 5 of 6 complex cases, only case 1 in this category showed multiple redundant activating changes (p.Gly12Val in DIE, p.Gly12Ser in both DIE and OMA). This particular case also had multiple redundant mutations in *PIK3CA* (4/4 shared), and *CTNNB1* (3/3 shared), as well as an *NRAS* (shared) alteration. As *PIK3CA*, *CTNNB1* and *KRAS* alteration were all relatively common we saw co-existence between these in 3/6 cases. The single case (Case 13) that lacked *PIK3CA* alterations had both *CTNNB1*, *EGFR* and *ERBB2*, shared between DIE and EM. A *KRAS* mutation was detectable in this case only in the DIE.

NRAS alteration were detected in 4 of 6 complex cases, no case showed multiple redundant alterations of *NRAS* itself but overlaps with *KRAS* mutations were present. In 3 cases (Cases 1, 2, 8) an *NRAS* alteration was shared between an OMA and a DIE lesion. In case 4 we detected one *NRAS* alteration shared between an OMA, a DIE lesion and an EM.

ERBB2 alterations were detected in 2 of 6 complex cases, one alteration shared between an OMA and two DIE lesions (case 3) as well as the shared mutation in case 13 as noted above. An *EGFR* alteration was also shared between the two analyzed lesions in case 13.

Discussion

We examined a total of 73 lesions from 27 women affected by endometriosis, we focused on within patient heterogeneity – a largely overlooked feature amongst current genomic studies on endometriosis. Cases were specifically selected to have multiple anatomical sites affected as well as multiple “types” of endometriosis including EM, DIE and OMA. Using a high-sensitivity, and error-correcting, sequencing technology followed by validation and additional screening with ddPCR we identified somatic cancer driver alterations in lesions from 13 women. A total of 27 lesions had at least one driver alteration, 7 lesions had more than 5.

We found evidence of identical alteration across lesions in 10 women, all of which spanned more than one type of endometriosis. The relatively commonplace finding of identical mutations across lesions suggests that at least a subset are clonal, sharing one or more common ancestor. Given our present data set the order/directionality of dissemination cannot be determined (Figures 2 and 3). We found that in 9 lesions there appeared to be multiple functionally redundant alterations (i.e. equivalent activating change resulting from different nucleotide and/or amino acid substitution in the same gene) which would be consistent with individual lesions being oligoclonal. Functionally redundant mutations were seen in *PIK3CA*, *KRAS*, and *CTNNB1*. This extended to 6 of 13 cases with observed somatic alteration. In 3 of these cases the redundant alterations were identified in two or more, suggesting dissemination likely involved multiple epithelial clones traveling together.

Examining the specific prevalence of mutations across lesions we observed more *PIK3CA* mutations than any other. OMAs tended to have a higher average mutation burden, at least within our panel, with OMA lesions from cases 1,2,3 having multiple activating *PIK3CA* and/or *CTNNB1* (and others) driving this average mutation burden up. When examining prevalence at a per lesion or per individual level we found more lesions, and more individuals, to be affected by somatic KRAS mutations. Despite a higher mutation burden within a subset of OMAs, DIE appeared to have a wider range of mutations from our panel with *EGFR* and *ERBB2* mutations seen only in DIE.

Our study is unique in examination of a modest number of co-existing lesions. Particular strengths include enrichment of endometriosis glands and stroma, the use of proven high-sensitivity and specificity digital sequencing methods, and orthogonal validation for the majority of alterations (Yong et al., 2021). We elected to be relatively conservative in calling mutations, however, it should be noted that a number of alterations were found to be just below detection thresholds, if a single assay was done, or both just above on panel sequencing and just below on ddPCR. In such cases we considered alteration to be negative/unvalidated. In sampling tissue for sequencing assays and subsequent ddPCR we took sequential tissue sections from a block for enrichment and analysis, often requiring re-sampling of tissue for validation. Hence, we must consider that in a small population of cells, such as a microscopic glands of endometriosis epithelium, it is possible that the proportion of mutation harboring cells changes as a specimen is sectioned such that it would genuinely yield a fraction of cells below a detection threshold in one sampling and above a detection threshold in another. If we were to be more liberal with assessment of ground-truth mutations our overall conclusion would not change though it would suggest greater complexity and more examples of oligoclonal dissemination throughout our cohort.

Potential weaknesses include the use of macrodissection instead of laser capture microdissection. In this context we cannot reliably use the variant allele frequency for anything other than binary presence or absence assessment of somatic alterations. Likewise, we are unable to verify that mutations were exclusive to epithelium, as observed in previous studies, though this was consistent in IHC observations. In addition, we used only a relatively limited panel assay to screen for mutations. Therefore, while we can make suggestions about potential lineage of samples with informative mutations, we are missing considerable data about the un-analyzed genome – this should be considered as a minimum estimate of clonality. We cannot strictly conclude that any cells or lesions (within a given patient) that do not share mutations with those found within our panel are of unrelated lineage. Nonetheless the presence of functionally redundant alterations (e.g. multiple *KRAS, PIK3CA*, and *CTNNB1* alterations) does suggest divergence of subclones within lesions is likely at the very least.

Finding of multiple redundant *PIK3CA* activating mutation was more prevalent in OMAs. This may be of particular interest for further study on malignant potential given the prevalence of *PIK3CA* alterations in endometriosis-associated cancers, their tendency to arise predominantly in the context of OMAs (Saavalainen et al., 2018), and model system finding suggesting *PIK3CA* mutation is necessary for the generation of clear cell ovarian carcinomas in mice (Chandler et al., 2015).

It is clear that all major anatomically described types of endometriosis can harbor recurrent somatic cancer-driver alterations. Our findings validate a modest spectrum of driver alterations, as has been described previously (Anglesio et al., 2017; Lac et al., 2019b) (Noe et al., 2018). While single cases have been described to share alteration between lesions of the same type (Anglesio et al., 2017; Suda et al., 2020), we provide considerable evidence that shared lineage between lesions is common, not only between lesions of the same type, but across anatomically defined lesion types. If we consider the likelihood of clonal dissemination of endometriosis, then anatomical lesion type descriptions alone are insufficient and should be supplemented with molecular characterizations – albeit which features are clinically useful is not yet established.

To make significant impact the next generation of endometriosis-genomic studies must apply high stringency methods, with appropriate enrichment of tissues, orthogonal validation and/or error correcting sequencing technologies, and most critically be coupled to large clinical data registries conforming to accepted standards in phenotyping data (Yong et al., 2021) - such as those promoted by WERF-Ephect (Fassbender et al., 2014; Rogers et al., 2017). Early studies on somatic genomics of endometriosis have suggested relatively few alterations per lesion (Anglesio et al., 2017; Bulun et al., 2019; Suda et al., 2018) (Noe et al., 2018), however our work suggests endometriosis may have moderate genomic complexity. Any future study wishing to correlate genomic heterogeneity with the clinical phenotypic spectrum may be complex, it is not sufficiently informative to sample only one lesion per patient for mutation testing. Accurate assessment of somatic mutation profiles may require a significant fraction of lesions are excised and tested at surgery (rather than ablated without biopsy). As we move forward studies will need to be done to determine if patient-wide endometriosis mutation profiles should include ranking of allele frequency, dissemination/spread, clonality across lesions and anatomic types. Phenotyping clinical characteristics should also monitor eutopic endometrium and pathway enrichment across mutations. Intra-lesion spatial heterogeneity (such as in a large OMA or deep nodules) may warrant study especially in relapse/persistent chronic disease and those associated with malignant progression. Simple binary assessment now seems insufficient and modeling with machine learning approaches may be paramount to identify associations between heterogeneous molecular profiles and heterogeneous clinical presentation.

Acknowledgements

Major funding was provided by Canadian Institutes of Health Research (Early Career Investigator Grant in in Maternal, Reproductive, Child & Youth Health to M.S. Anglesio) M. Köbel received support through the Calgary Laboratory Services research support fund (RS19-609). M.S. Anglesio is funded through a Michael Smith Foundation for Health Research Scholar Award and the Janet D. Cottrelle Foundation Scholars program (managed by the BC Cancer Foundation). This project received technical and data management support from Calgary Laboratory Services and the Genetic Pathology Evaluation Centre (GPEC). GPEC receive core support from BC's Gynecological Cancer Research team (OVCARE), and the VGH+UBC Hospital Foundation. Dr. M Köbel was supported by internal research support (RS19-621).

The authors thank all the study participants who contributed to this study. We further recognize the invaluable contributions of Prof. Dr. Sara Y. Brucker for continuous support of international collaborations between the University Hospital Tübingen and the University of British Columbia, as well as PD Dr. Annette Staebler and the staff of the Institute of Pathology, University Hospital Tübingen for facilitating access to their archives.

Author contributions

MSA and SK conceptualized the study and designed the experiments. THP, MG, BK, and SK identified patients and obtained consent. BTC, TMN, and MK reviewed pathological diagnosis and scored immunohistochemistry. THP, VL, JS conducted experiments. THP, JS, and MSA analyzed data. THP, SK, PJY, and MSA wrote the first draft. All authors provided input on revisions and approved the final manuscript.

Declaration of Interests

none

Figure Legends

Figure 1: Fraction of cohort affected by somatic hotspot mutations detected in panel sequencing. (A) Overall split of cases with at least one lesions having at least one somatic cancer-driver alteration. We found nearly half of cases tested with our panel had at least one mutation. (B) Numbers of detected somatic mutations, split by affected gene, across our entire cohort. Mutations affecting *PIK3CA* (27) were the most frequently observed hotspots, followed by *KRAS* (16) and *CTNNB1* (10) hotspots. (C) Fraction of mutation affected lesions, split by mutation type. In contrast to the overall frequency of alterations more lesions were affected by KRAS alteration overall. This trend was the same regardless of lesion type as shown in (D) or if summarizing by fraction of affected cases (E). Further, endometriomas (OMA) tended to have a higher proportion of lesions affected by somatic cancer-driver alterations (D) and subsequently higher mutation load than other lesion types (see also Table S1).

Figure 2: Clonal relationships in Case 3 patient presenting with DIE of the vagina, DIE of the cul-de-sac, an OMA of the left ovary, and EM of the rectum. (A) Detected somatic alteration from sequencing and mutation surrogate IHC suggest identical/clonal alteration in *KRAS*, *ERBB2*, and *PIK3CA* (p.Met1043Ile) between OMA and two anatomically distinct lesions of DIE. Additional *PIK3CA* alterations are also visible in the OMA and vaginal DIE. Heterogeneous loss of ARID1A is observed in only the OMA and EM (insufficient material was available for mutation testing in EM). (B) Three possible dissemination models explaining the mutational pattern: (1) top panel illustrates a linear pattern wherein clones from the cul-de-sac travel to the vagina and acquired additional alterations in *PIK3CA*. Subsequent transfer of all clones to the ovary where subclonal-ARID1A loss occurs. It may further be speculated that the EM resulted from a transfer of clones between the vaginal DIE and OMA (as the initial site for ARID1A loss) or subsequent spread after clones established on the ovary. Given the lack of mutational data on the EM it may also be entirely independent. (2) middle panel illustrates an example where a complex set of clones exist at the ovary and only a subset of these break-off and colonize vaginal, cul-de-sac and EM/rectal sites. Finally, (3) Lower panel illustrates parallel dissemination from the cul-de-sac lesion to both the vaginal and ovarian sites. Herein we may consider sub-threshold signal from ddPCR of p.Arg88Gln, p.Glu545Lys and p.Gly1049Ser PIK3CA alteration (Table S1) as weak evidence of emerging/undetectable clones that subsequently expand post-transfer of cells to both vagina and ovary. In this model again, the OMA acquires loss-of function ARID1A alterations. Additional possibilities may also explain the mutational patterns. (C-D-E) photomicrographs showing ARID1A IHC results including regions of loss (surrogate for loss-of function mutation; black arrows) and normal (retained nuclear staining; red arrows) in endometriosis epithelium.

Figure 3: Clonal relationships in Case 4 patient presenting with DIE of the rectum, EM of the cul-de-sac and an OMA on the left ovary. (A) Detected somatic alteration from sequencing suggest all variants are shared between DIE and EM lesions. In contrast the ovarian lesion shares only 1 *PIK3CA* and 1 *KRAS* alteration with the other two and has no (detected) unique changes. (B) Three possible dissemination models explaining the mutational pattern: (1) top panel illustrates a linear model wherein clones from the ovary travel to the rectum, expand and acquire additional alteration. Cells from the DIE containing all clones then seed the EM on the Cul-de-sac. (2) middle panel illustrates another linear model of dissemination wherein a complex clonal population at the Rectum seed the cul-de-sac. Subsequently only a subset of these clone travel to and populate the ovary. Finally, (3) illustrates a differing model of spread wherein a complex clonal population at the Rectum seed the cul-de-sac with all clones. Only a subset with a single *PIK3CA* and *KRAS* altered clone break-off to the ovary (or alternatively only a subset with these specific alterations can colonize the ovary).

		DIE																EM											OMA			
	Case ID	appendix	bladder	cul-de-sac	left sacrouterine ligament	rectovaginal septum	rectum	right psoas	right sacrouterine ligament	right pelvic wall	left pelvic wall	right pararectal space	right fossa ovarica	sigmoid	incisional	vagina	umbilicus	bladder	cul-de-sac	rectum	right abdominal wall	right pelvic wall	left pelvic wall	right sacrouterine ligament	left sacrouterine ligament	colon	right ovary	left pararectal space	left ovary	pararectal space	right ovary	Grand Total
Complex Cases	1						1																								1	2
	2						1																								1	2
	3			1												1				[1]									1			4
	4						1												1										1			3
	8	1																				[1]		[1]					1			4
	13		1																		1								[1]			3
Simple Cases	6								1														1									2
	9	1																													1	2
	19													1																1		2
	20				1													1														2
	21		1		1	1			[1]																				1		1	6
	22				1				1										1													3
	24				1	1		1										[1]														4
Uninformative Cases	5						1																				1					2
	7														1								1									2
	10		1																							[1]						2
	11													1;[1]															[1]			3
	12		1																										1			2
	14													1															1			2
	15						1									[1]													1			3
	16					1																									1	2
	17														1										1							2
	18	1																													1	2
	23																1														1	2
	25									1													1						1			3
	26										1								[1]													2
	27								1			[1]	[1]					[1]										1				5
	Grand Total	3	4	1	4	3	5	1	4	1	1	1	1	4	2	2	1	3	3	1	1	1	3	1	1	1	1	1	10	1	7	73

Table 1: Cohort Overview**.** Each cell shows the number of lesions available and tested from the noted anatomical site/type (always 1; number in brackets denote lesions were not tested in panel sequencing). Blue cell = shared alteration within case/between lesions marked by blue cells in table (cells not in blue were uninformative/did not show evidence of clonality with any other lesion from the given case), Grey lines/cases were entirely uninformative (no mutation detected in panel sequencing from any tested lesion). Abbreviations: abd.= abdominal, DIE= Deep infiltrating endometriosis, EM= superficial endometriosis, OMA= endometrioma, pr= pararectal, rv= rectovaginal, su. lig.= sacrouterine ligament

STAR Methods

Resource Availability

Lead Contact

Requests for resources and reagents should be directed to Dr. Michael S. Anglesio (m.anglesio@ubc.ca)

Materials Availability

This study did not generate new reagents.

Requests for access to materials (e.g tissue), raw sequence data outputs, or additional IHC images, please contact the corresponding authors. Requestors should note that due to the small nature of endometriosis lesions little material will remain after experiments. Access may be granted subject to availability, review of proposed use consistent with patient consent/waiver, and appropriate material transfer agreement(s). Request for details on the proprietary Canexia Health FindIT™ assay models should be directed to Canexia Health.

Data and Code Availability

All data for the study is contained in the manuscript and supplemental figures/tables. No unique code was generated for analysis of data.

Experimental subject details

Formalin-fixed and paraffin-embedded (FFPE) archival tissues from 27 patients from the Tübingen University Hospital, Germany were included. Inclusion criteria included histopathological diagnosis of endometriosis, presentation of two or more types of endometriosis (deep infiltrating, and/or superficial, and/or ovarian endometrioma) in distinct anatomical locations, and lesions estimated to be of sufficient size for macrodissection. Patients with a history of, or co-existing, gynecological cancer were excluded. Experiments were done at the University of British Columbia and the University of Calgary. The project was conducted in compliance with the Canadian Tri-Council Policy Statement on Ethical Conduct for Research Involving Humans (TCPS2, 2018), effort to obtain written informed consent was exercised for all patients. Specimen from non-contactable patients (lost contact/deceased) treated more than 5 years before the start of the study were included under institutionally approved waiver of consent (Tübingen University Hospital Research Ethics Board). All institutions approved use of materials and associated clinical data through local research ethics boards.

Method Details

Sample processing and DNA extraction

FFPE specimens were sectioned onto glass slides, stained with dilute hematoxylin and eosin, and manually enriched for endometriosis glands and stroma by manual microdissection as described previously (Lac et al., 2019a; Lac et al., 2019b). DNA was extracted using the ARCTURUS® PicoPure® DNA Extraction Kit (ThermoFisher Scientific, USA) and quantitated using the Qubit 2.0 Fluorometer (ThermoFisher Scientific, USA).

Targeted sequencing

DNA (45-75ng) was sequenced using a proprietary hypersensitive cancer hotspot sequencing panel: FIND IT™, version 3.4 (Canexia Health, Canada) (Anglesio et al., 2017; Lac et al., 2019b). This assay includes hotspots from 33 genes (Lac et al., 2019a; Lac et al., 2019b) (Table S2). Mutations were considered “true”, if they were genuine hotspot mutations targeted by the FIND IT assay and previously reported in the Catalogue of Somatic Mutations in Cancer (COSMIC) (Forbes et al., 2011),

as well as prior observations with validation (Anglesio et al., 2017; Lac et al., 2019b), including a probability score >0.8 and a variant allele frequency (VAF) >0.8% (see Table S1A).

Validation via droplet digital PCR

Somatic mutations identified by targeted sequencing were orthogonally validated through droplet digital polymerase-chain-reaction (ddPCR) assays. In addition, select alterations were tested by ddPCR in all available lesions from a given patient if they were observed either in any one lesion from a given patient (subjected to the FIND IT panel assay), regardless of the results obtained in other panel-tested lesions from the same patient and including any specimens from the same patient that were initially omitted from panel testing due to low DNA yield. Using previously established methods (Lac et al., 2019a; Lac et al., 2019b), extracted DNA was pre-amplified for targets over 10 cycles then diluted before assembling the ddPCR assay. Droplets were generated using the QX200 Droplet Generator (Bio-Rad Laboratories, USA), amplified by thermal cycling, and quantified using the QX2000 Droplet Reader (Bio-Rad Laboratories, USA). As above alterations were considered “true” if they passed the above noted probability and VAF thresholds for targeted sequencing or were detected using ddPCR above a droplet count set at the average of the negative control specimens plus 3 times the standard deviation of negative controls the relevant assay. See key resource table for primer/probe sequences.

ARID1A, PTEN and p53 Immunohistochemistry

Immunohistochemistry (IHC) assays for ARID1A (Khalique et al., 2018) , p53 (Kobel et al., 2016; Kobel et al., 2019) and PTEN (Lac et al., 2019a; Lac et al., 2019b) were used as surrogate for somatic alterations following established standards for staining and scoring. ARID1A was stained Dako Omnis automated immunostainer (Agilent Technologies, USA) or Ventana BenchMark Ultra autostainer (Ventana Medical Systems, USA) the ARID1A rabbit polyclonal antibody, HPA005456 (Sigma-Aldrich). PTEN was stained on Ventana Discovery Ultra (Ventana Medical Systems, USA) using the rabbit monoclonal antibody, 138G6 (Cell Signaling, USA). p53 was stained on Dako Omnis (Agilent Technologies, USA) using the p53 mouse monoclonal antibody DO-7 (GA61661-2; Agilent Technologies, USA). Slides were scored by pathologists TMN, and/or BTC, and/or MK.

Quantification and Statistical Analysis

Calling criteria was applied to all detected alterations as noted above, including a probability score >0.8 and VAF >0.8% for panel sequencing and individual droplet count thresholds for each ddPCR assay.

Immunohistochemistry assays were performed and scored according to established standards, briefly ARID1A loss if nuclear staining was absent in endometriosis epithelium cells and internal control (stroma) was intact. (Khalique et al., 2018) p53abn if high intensity positive staining was observed in 10 or more adjacent cells in the epithelial cyst wall of endometriosis or complete absence of staining in the entire cyst wall. (Kobel et al., 2016; Kobel et al., 2019) PTEN loss if cytoplasmic and nuclear staining was absent in endometriosis epithelium cells and internal control (stroma) was intact. (Lac et al., 2019a; Lac et al., 2019b)

Student’s t-test was performed to compare the affected genes and lesion types. However, given our limited sample size, they remained not significant.

Supplemental Information

Figure S1: Project workflow. 27 patients were selected all with more than one type and more than one anatomical site of endometriosis. A total of 73 lesions were reviewed for analysis. 53 lesions had sufficient tissue for digital panel sequencing while an additional 6 samples had sufficient yield for only ddPCR of select alterations. A total of 83 somatic alterations were initially detected in sequencing, 72 subjected to ddPCR validation (58 validated). During the ddPCR validation stage additional lesion were tested for alterations observed in panel sequencing resulting in a total of 90 detected alterations in 13 cases across the entire cohort. Immunohistochemistry for PTEN (loss in 11%), ARID1A (loss in 3%), and p53 (no abnormal staining observed) was done in parallel.

Figure S2: Per-Case summary of detected alterations across lesions as derived from sequencing, digital droplet PCR (ddPCR), and immunohistochemistry (IHC) in informative cases. Legend: Abd = abdominal, atyp= atypical, DIE= deep infiltrating endometriosis, EM= superficial endometriosis, Het loss= heterogeneous loss, l= left, lig= ligament, pararec=pararectal, OMA= endometrioma, r=right rv= rectovaginal, su= sacrouterine

Table S1A: Panel Sequencing and ddPCR validation data. Full list of sequence and droplet digital PCR (ddPCR) data with variant allele frequencies (VAFs) and probability scores (PR.)
DIE= deep infiltrating endometriosis, EM= superficial endometriosis, OMA= endometrioma

Table S1B: Immunohistochemistry. Full list of IHC results, DIE= deep infiltrating endometriosis, EM= superficial endometriosis, OMA= endometrioma

Table S2: Hotspots and Exons analyzed in the FIND IT™ panel version 3.4 (Canexia Health, Canada)

References

American Society for Reproductive Medicine (1997). Revised American Society for Reproductive Medicine classification of endometriosis: 1996. Fertility and sterility *67*, 817-821.

Anglesio, M.S., Papadopoulos, N., Ayhan, A., Nazeran, T.M., Noe, M., Horlings, H.M., Lum, A., Jones, S., Senz, J., Seckin, T.*, et al.* (2017). Cancer-Associated Mutations in Endometriosis without Cancer. The New England journal of medicine *376*, 1835-1848.

Bulun, S.E. (2009). Endometriosis. The New England journal of medicine *360*, 268-279.

Bulun, S.E., Wan, Y., and Matei, D. (2019). Epithelial Mutations in Endometriosis: Link to Ovarian Cancer. Endocrinology *160*, 626-638.

Chandler, R.L., Damrauer, J.S., Raab, J.R., Schisler, J.C., Wilkerson, M.D., Didion, J.P., Starmer, J., Serber, D., Yee, D., Xiong, J.*, et al.* (2015). Coexistent ARID1A-PIK3CA mutations promote ovarian clear-cell tumorigenesis through pro-tumorigenic inflammatory cytokine signalling. Nature communications *6*, 6118.

Eskenazi, B., and Warner, M.L. (1997). Epidemiology of endometriosis. Obstetrics and gynecology clinics of North America *24*, 235-258.

Fassbender, A., Rahmioglu, N., Vitonis, A.F., Vigano, P., Giudice, L.C., D'Hooghe, T.M., Hummelshoj, L., Adamson, G.D., Becker, C.M., Missmer, S.A.*, et al.* (2014). World Endometriosis Research Foundation Endometriosis Phenome and Biobanking Harmonisation Project: IV. Tissue collection, processing, and storage in endometriosis research. Fertility and sterility *102*, 1244-1253.

Forbes, S.A., Bindal, N., Bamford, S., Cole, C., Kok, C.Y., Beare, D., Jia, M., Shepherd, R., Leung, K., Menzies, A.*, et al.* (2011). COSMIC: mining complete cancer genomes in the Catalogue of Somatic Mutations in Cancer. Nucleic acids research *39*, D945-950.

Giudice, L.C. (2010). Clinical practice. Endometriosis. The New England journal of medicine *362*, 2389-2398.

Johnson, N.P., Hummelshoj, L., Adamson, G.D., Keckstein, J., Taylor, H.S., Abrao, M.S., Bush, D., Kiesel, L., Tamimi, R., Sharpe-Timms, K.L.*, et al.* (2017). World Endometriosis Society consensus on the classification of endometriosis. Human reproduction *32*, 315-324.

Khalique, S., Naidoo, K., Attygalle, A.D., Kriplani, D., Daley, F., Lowe, A., Campbell, J., Jones, T., Hubank, M., Fenwick, K.*, et al.* (2018). Optimised ARID1A immunohistochemistry is an accurate predictor of ARID1A mutational status in gynaecological cancers. J Pathol Clin Res *4*, 154-166.

Kobel, M., Piskorz, A.M., Lee, S., Lui, S., LePage, C., Marass, F., Rosenfeld, N., Mes Masson, A.M., and Brenton, J.D. (2016). Optimized p53 immunohistochemistry is an accurate predictor of TP53 mutation in ovarian carcinoma. J Pathol Clin Res *2*, 247-258.

Kobel, M., Ronnett, B.M., Singh, N., Soslow, R.A., Gilks, C.B., and McCluggage, W.G. (2019). Interpretation of P53 Immunohistochemistry in Endometrial Carcinomas: Toward Increased Reproducibility. Int J Gynecol Pathol *38 Suppl 1*, S123-S131.

Lac, V., Nazeran, T.M., Tessier-Cloutier, B., Aguirre-Hernandez, R., Albert, A., Lum, A., Khattra, J., Praetorius, T., Mason, M., Chiu, D.*, et al.* (2019a). Oncogenic mutations in histologically normal endometrium: the new normal? The Journal of pathology *249*, 173-181.

Lac, V., Verhoef, L., Aguirre-Hernandez, R., Nazeran, T.M., Tessier-Cloutier, B., Praetorius, T., Orr, N.L., Noga, H., Lum, A., Khattra, J.*, et al.* (2019b). Iatrogenic endometriosis harbors somatic cancer-driver mutations. Human reproduction *34*, 69-78.

Montgomery, G.W., and Giudice, L.C. (2017). New Lessons about Endometriosis - Somatic Mutations and Disease Heterogeneity. The New England journal of medicine *376*, 1881-1882.

Munksgaard, P.S., and Blaakaer, J. (2012). The association between endometriosis and ovarian cancer: a review of histological, genetic and molecular alterations. Gynecologic oncology *124*, 164-169.

Noe, M., Ayhan, A., Wang, T.L., and Shih, I.M. (2018). Independent development of endometrial epithelium and stroma within the same endometriosis. The Journal of pathology.

Rogers, P.A., Adamson, G.D., Al-Jefout, M., Becker, C.M., D'Hooghe, T.M., Dunselman, G.A., Fazleabas, A., Giudice, L.C., Horne, A.W., Hull, M.L.*, et al.* (2017). Research Priorities for Endometriosis. Reproductive sciences *24*, 202-226.

Saavalainen, L., Lassus, H., But, A., Tiitinen, A., Harkki, P., Gissler, M., Pukkala, E., and Heikinheimo, O. (2018). Risk of Gynecologic Cancer According to the Type of Endometriosis. Obstetrics and gynecology.

Suda, K., Cruz Diaz, L.A., Yoshihara, K., Nakaoka, H., Yachida, N., Motoyama, T., Inoue, I., and Enomoto, T. (2020). Clonal lineage from normal endometrium to ovarian clear cell carcinoma through ovarian endometriosis. Cancer science.

Suda, K., Nakaoka, H., Yoshihara, K., Ishiguro, T., Tamura, R., Mori, Y., Yamawaki, K., Adachi, S., Takahashi, T., Kase, H.*, et al.* (2018). Clonal Expansion and Diversification of Cancer-Associated Mutations in Endometriosis and Normal Endometrium. Cell Rep *24*, 1777-1789.

Vercellini, P., Vigano, P., Somigliana, E., and Fedele, L. (2014). Endometriosis: pathogenesis and treatment. Nat Rev Endocrinol *10*, 261-275.

Yong, P.J., Talhouk, A., and Anglesio, M.S. (2021). Somatic genomic events in endometriosis: review of the literature and approach to phenotyping. Reproductive sciences *epub ahead of print*, x.

Zondervan, K.T., Becker, C.M., and Missmer, S.A. (2020). Endometriosis. The New England journal of medicine *382*, 1244-1256.

A

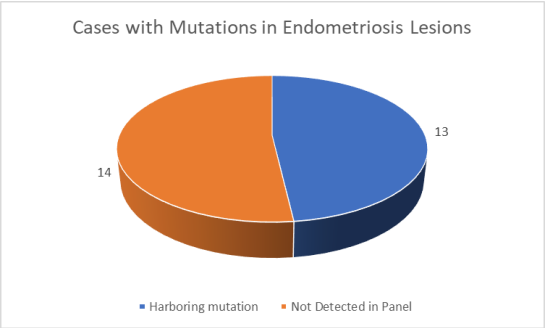

B

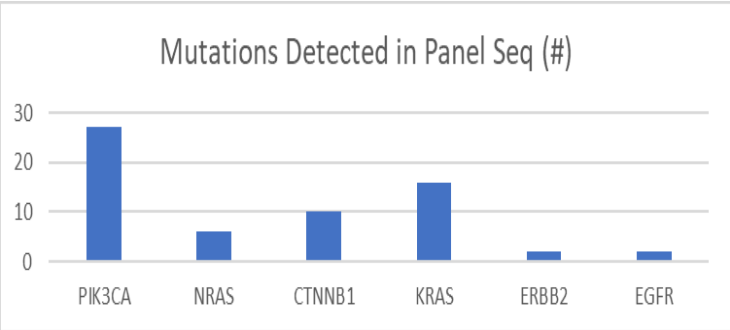

C

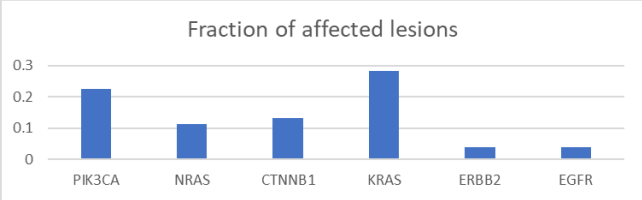

D

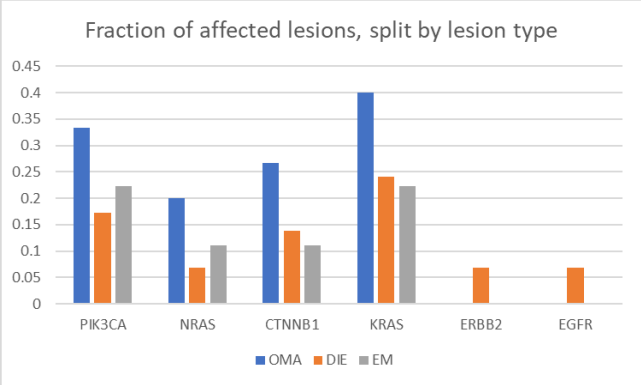

E

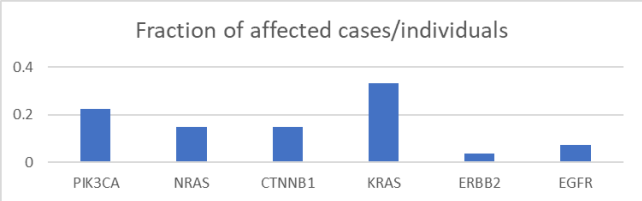

Figure 1

A

Case 3 Detected Alterations					
Gene	Hotspot	OMA Left ovary	DIE (v) Vagina	DIE (c) Cul-de-sac	EM Rectum
PIK3CA	p.Glu545Lys	X	X		Insufficient size for sequencing
PIK3CA	p.Gly1049Ser	X	X		
PIK3CA	p.Arg88Gln	X	X		
PIK3CA	p.Met1043Ile	X	X	X	
KRAS	p.Gly12Asp	X	X	X	
ERBB2	p.Ser310Phe	X	X	X	
ARID1A IHC		Loss in atypical endometriosis			Hetero-geneous loss

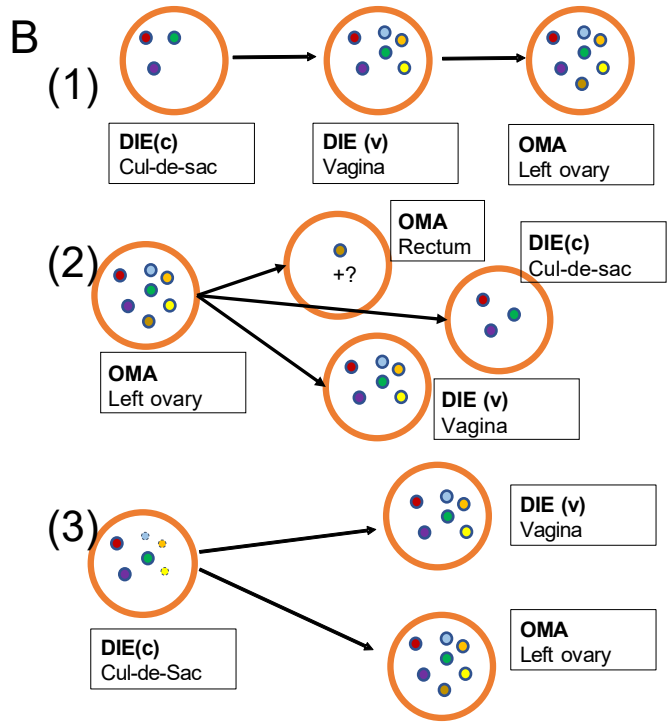

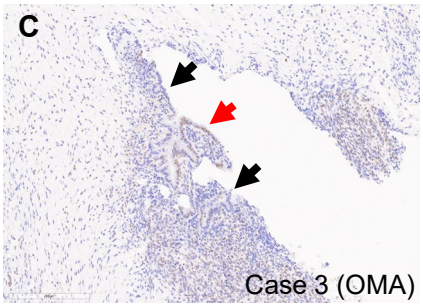

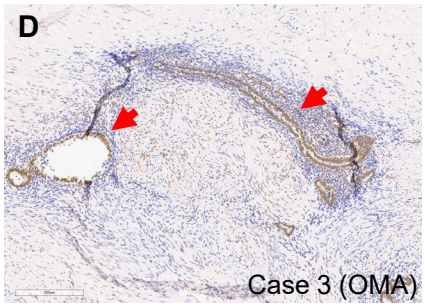

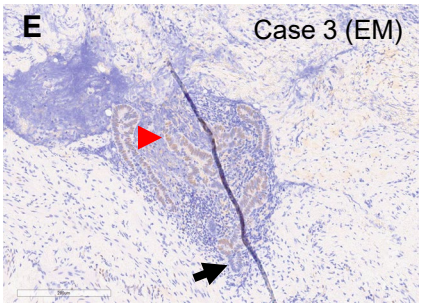

Figure 2

A

Case 4 Detected Alterations				
Gene	**Hotspot**	**DIE** Rectum	**OMA** Left ovary	**EM** Cul-de-sac
PIK3CA	p.Glu542Lys	X		X
PIK3CA	p.Glu545Lys	X		X
PIK3CA	p.Gly1049Ser	X		X
PIK3CA	p.Met1043Ile	X	X	X
NRAS	p.Gly13Asp	X	X	X
CTNNB1	p.His36Tyr	X	X	X
CTNNB1	p.Gly34Glu	X		X
KRAS	p.Gly12Asp	X	X	X

B

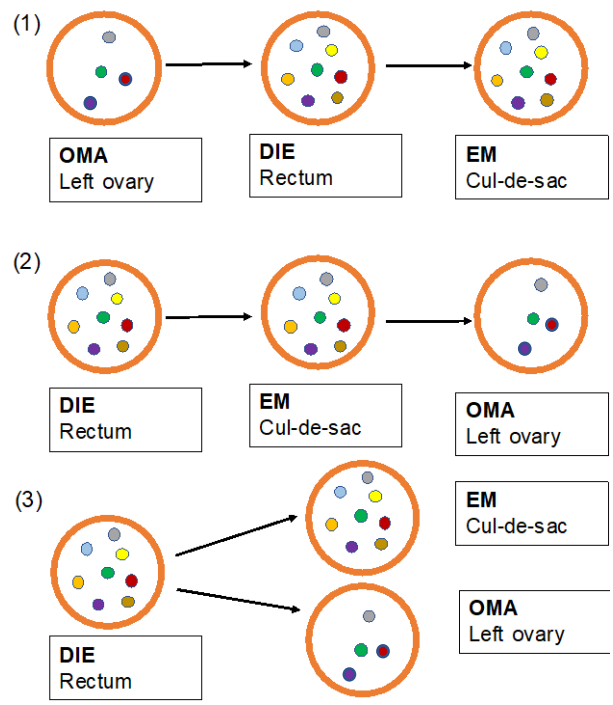

Figure 3

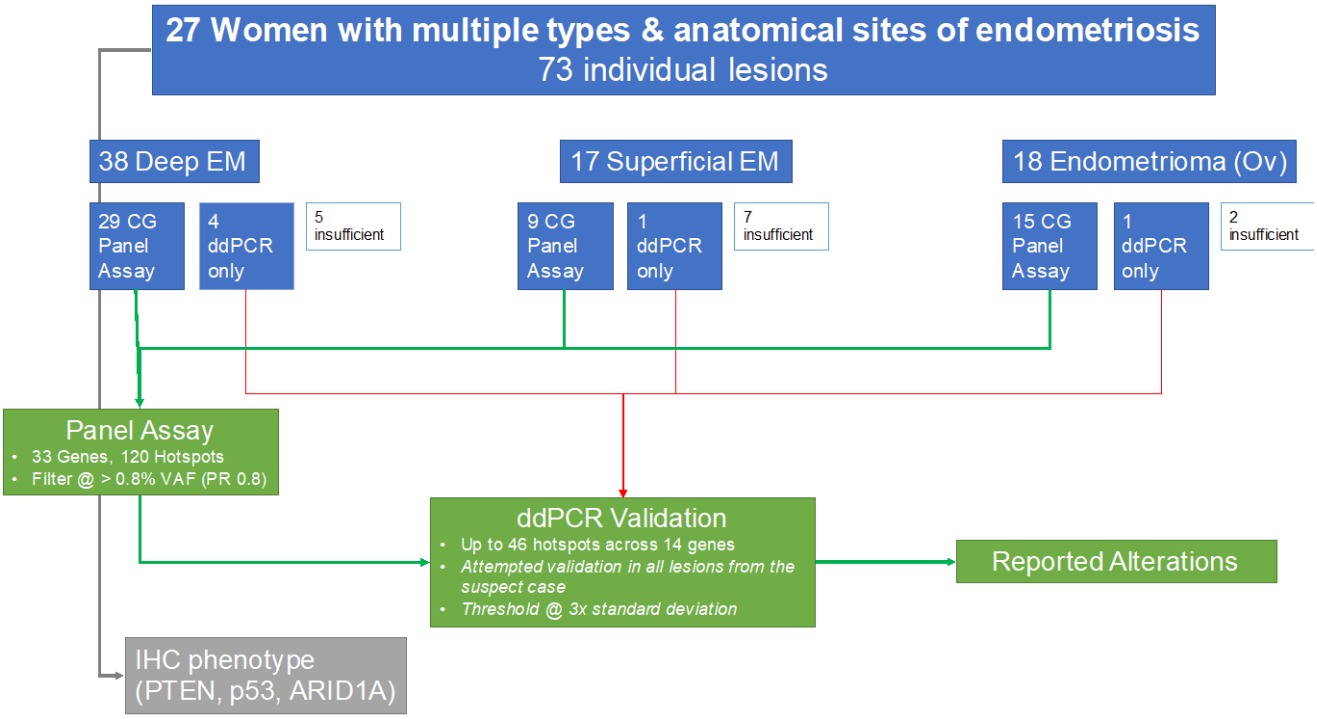

Figure S1: Project Workflow

Figure S2

Detected Alterations in Complex Cases

Case 1 Detected Alterations			
Gene	Hotspot	OMA R.Ovary	DIE Rectum
PIK3CA	**p.Glu542Lys**	**X**	
PIK3CA	**p.Gly1049Ser**	**X**	**X**
PIK3CA	**p.Arg88Gln**	**X**	
PIK3CA	**p.Met1043Ile**	**X**	**X**
NRAS	**p.Gly13Asp**	**X**	**X**
CTNNB1	**p.His36Tyr**	**X**	
CTNNB1	**p.Gly34Glu**	**X**	**X**
CTNNB1	**p.Thr41Ile**	**X**	**X**
KRAS	**p.Gly12Ser**	**X**	
KRAS	**p.Gly12Val**		**X**

Case2 Detected Alterations			
Gene	Hotspot	OMA R.ovary	DIE Rectum
PIK3CA	p.Glu542Lys	X	X
PIK3CA	p.Glu545Lys	X	
PIK3CA	**p.Gly1049Ser**	**X**	
PIK3CA	**p.Arg88Gln**	**X**	
PIK3CA	**p.Met1043Ile**	**X**	
NRAS	p.Gly13Asp	X	X
CTNNB1	p.His36Tyr		X
CTNNB1	p.Gly34Glu	X	
CTNNB1	p.Thr41Ile	X	
PTEN	IHC	Het loss	Het loss

Case 3 Detected Alterations				
Gene	Hotspot	OMA L.ovary	DIE Vagina	DIE Cul-de-sac
PIK3CA	p.Glu545Lys	X	X	
PIK3CA	p.Gly1049Ser	X	X	
PIK3CA	p.Arg88Gln	X	X	
PIK3CA	p.Met1043Ile	X	X	X
KRAS	p.Gly12Asp	X	X	X
ERBB2	p.Ser310Phe	X	X	X
ARID1A	IHC	Loss atyp. EM	Het loss	

Case 4 Detected Alterations				
Gene	Hotspot	DIE Rectum	OMA L.ovary	EM Cul-de-sac
PIK3CA	p.Glu542Lys	X		X
PIK3CA	p.Glu545Lys	X		X
PIK3CA	p.Gly1049Ser	X		X
PIK3CA	p.Met1043Ile	X	X	X
NRAS	p.Gly13Asp	X	X	X
CTNNB1	p.His36Tyr	X	X	X
CTNNB1	p.Gly34Glu	X		X
KRAS	p.Gly12Asp	X	X	X

Case 8 Detected Alterations				
Gene	Hotspot	OMA L. ovary	DIE Appendix	EM* R.pel.wall
PIK3CA	p.Glu545Lys	X		
NRAS	p.Gly13Asp	X	X	
CTNNB1	p.Ser37Phe	X	X	
KRAS	p.Gly12Val	X		
PTEN	IHC		Het loss	Het loss

*Insufficient size for sequencing.

Case 13 Detected Alterations			
Gene	Hotspot	DIE Bladder	EM R.abd.wall
EGFR	p.Thr790Met	X	X
CTNNB1	p.His36Tyr		X
CTNNB1	p.Thr41Ile		X
ERBB2	p.Ser310Phe		X

Detected Alterations in Simple Cases

Case 6 Detected Alterations			
Gene	Hotspot	EM L.pel.wall	DIE R.su.lig.
PIK3CA	p.Met1043Ile	X	X

Case 9 Detected Alterations			
Gene	Hotspot	DIE Appendix	OMA R.ovary
PIK3CA	p.Gln546Arg		X
KRAS	p.Gly12Ala	X	
KRAS	p.Gly12Cys	X	
KRAS	p.Gly12Val		X

Case 19 Detected Alterations			
Gene	Hotspot	OMA Pararec.Space	DIE Sigmoid
KRAS	p.Gly12Ser	X	X
PTEN	IHC	Het loss	

Case 20 Detected Alterations			
Gene	Hotspot	EM Bladder	DIE L.su.lig
KRAS	p.Gly12Asp		X
PTEN	IHC	Loss	

Case 21 Detected Alterations						
Gene	Hotspot	OMA R. ovary	DIE Rv.septum	OMA L. ovary	DIE L.su.lig	DIE Bladder
KRAS	p.Gly12Asp	X	X		X	X

Case 22 Detected Alterations				
Gene	Hotspot	DIE R.su.lig	EM Cul-de-sac	DIE L. su. lig
KRAS	p.Gly12Ala		X	

Case 24 Detected Alterations				
Gene	Hotspot	DIE Right psoas	DIE Rv. septum	DIE L.su.lig.
EGFR	p.Thr790Met			X
PTEN	IHC		Het loss	