Amyloid deposition in granuloma of tuberculosis patients: A pilot study

Shreya Ghosh, MSc[1], Akansha Garg, MSc[1], Chayanika Kala, MD[2] and Ashwani Kumar Thakur, PhD[1*]

[1]Department of Biological Sciences and Bioengineering, Indian Institute of Technology Kanpur, Kanpur–208016, Uttar Pradesh, India.
[2]Department of Pathology, LPS Institute of Cardiology and Cardiac Surgery, Kanpur-208019, Uttar Pradesh, India.

*Corresponding author: Dr. Ashwani K Thakur, Department of Biological Sciences and Bioengineering, Indian Institute of Technology Kanpur, Kanpur – 208016, Uttar Pradesh, India. E-mail: akthakur@iitk.ac.in

Abstract:

The formation of granuloma is one of the characteristic feature of tuberculosis. Besides, rise in the concentration of acute phase response proteins mainly serum amyloid A is the indicator for chronic inflammation associated with tuberculosis. Serum amyloid A drives secondary amyloidosis in tuberculosis and other chronic inflammatory conditions. The linkage between serum amyloid A (SAA) protein and amyloid deposition site is not well understood in tuberculosis and other chronic inflammatory conditions. We hypothesized that granuloma could be a potential site for amyloid deposition because of the presence of serum amyloid A protein and proteases that cleave SAA and trigger amyloid formation. Based on this hypothesis, for the first time we have shown the presence of amyloid deposits in the granuloma of tuberculosis patients using the gold standard, Congo red dye staining.

Keywords tuberculosis, granuloma, amyloid, periphery

Abbreviations TB, tuberculosis; WHO, world health organization; FDA, Food and Drug Administration; SAA, serum amyloid A; H&E, Hematoxylin and eosin; FFPE, formalin fixed paraffin embedded; CR, Congo red; MMPs, matrix metalloproteinases; Mtb, *Mycobacterium tuberculosis*.

Introduction:

Tuberculosis is one of the leading airborne disease, caused by *Mycobacterium tuberculosis* infection among adults.[1] TB is highly prevalent across worldwide affecting 10 million people in a year.[2] Amongst all WHO regions in South-East Asia, India is reported as the highest TB burden country accounting for 26% of the global TB prevalence in the year 2019.[2]

Lungs are the most common site for mycobacterial infection in majority of cases. However, organs systems like gastrointestinal, musculoskeletal, lymphoreticular, skin, liver, reproductive and the central nervous system are also affected in some cases.[3] Despite, of having various treatment options, it remains one of the leading causes of morbidity. Evolution of several multidrug resistant mycobacterial tuberculosis strains is one of the reasons behind it.[4]

During the chronic TB infection, SAA levels often increases to 1000 folds after 24 hours.[5] This induces cleavage of the SAA protein by cathepsins (cysteine proteases) and MMPs to form N-terminal fragment.[6,7] Subsequently, both full length and truncated form of SAA gets deposited as amyloid fibrils in the extracellular spaces of various organs.[8] SAA was first identified as the "amyloid of unknown origin" underlying chronic inflammation in 1961 by Benditt and Eriksen.[9] In the subsequent years, various other studies depicted the complete sequence of protein as well as the amyloidogenic N-terminal fragment.[10-12] Later it was named as serum amyloid A protein because it was the first non-immunoglobulin serum protein identified to have a role in amyloid formation.[5]

Prevalence of secondary amyloidosis underlying chronic inflammatory conditions in tuberculosis patients has been reported since early 1900s. In a study carried out at Uppsala University with 65-83 years old formalin fixed organs from pulmonary TB patients, 48 out of 156 organ autopsies was reported to be associated with amyloidosis.[13,14] In the recent years, the incidence of AA amyloidosis is quite higher in developing countries including India.[15] Various epidemiological studies on Indian population have revealed secondary amyloidosis as one of the major outcomes of pulmonary tuberculosis.[16-20]

One of the major signature of tuberculosis patients is formation of granuloma, comprising of aggregate of mature macrophages and Langhans giant cells.[21] It is formed as a result of first line of host defense to eradicate the microbes. But in later stages, it is utilized by the mycobacterial species as a vehicle for its cellular expansion within host system.[22] MMP 9, a known membrane bound endopeptidase plays a major role in macrophage recruitment and granuloma formation post Mtb infection.[23] Besides, SAA is known to have a high affinity for the macrophages.[24] Chen et.al in 2010 reported that SAA expression was localized around the periphery of tuberculous granuloma.[25] As SAA, after proteolytic cleavage drives the systemic form of amyloidosis in tuberculosis patients, we suspected that the presence of both SAA and MMPs might account for the onset of amyloid formation in the granulomas. Hence, in this study, we have reported the presence of amyloid deposits mostly around the periphery of granuloma in tuberculosis patients.

Congo red staining is considered as the gold standard for identifying amyloid deposits in the affected organs and tissues.[26] The characteristic apple green birefringence under polarized light along with its transformation from green to reddish orange upon changing angle of polarizer is a

strong signature of amyloid fibrils.[27,28] In our study we have utilized this birefringence property of CR staining to trace the amyloid deposits in tuberculous granuloma of patients.

Methods:

Sample collection: In a two year single center study carried out from 2018 to 2020, 150 patients were screened positive for tuberculosis based on sputum examination, histological features and other distinct biochemical parameters in blood. Biopsy specimens of the respective affected organs of these TB patients were collected after taking their informed consent.

Histological examination of the tissue specimens: A series of staining procedures were carried out for the identification of TB specific histological signatures and presence of amyloid deposits in the FFPE tissue sections. The detailed protocols are outlined in the following paragraphs.

1. **Hematoxylin-Eosin staining:** Deparaffinized sections were put in Hematoxylin-Mayer's solution for 2 minutes followed by a brief wash in distilled water. It was then counterstained with 1% eosin solution followed by subsequent dehydration and xylene treatment. The slides were then mounted in synthetic mounting media and observed under bright light in a microscope.

2. **Congo red Staining:** Stock and working solutions were prepared according to the previously published protocol.[29] Sections were deparaffinized and stained with Hematoxylin-Mayer's solution followed by brief rinsing in water to remove excess stain. It was then transferred to solution A for 20 minutes immediately followed by 20 minutes incubation in solution B. Sections were then rinsed briefly in two changes of absolute ethanol, not exceeding for 10 seconds each followed by xylene treatment. It was then mounted in synthetic mounting media. Stained sections were then visualized under crossed and uncrossed polarized light.

Results and Discussion:

FFPE tissue specimens of all the TB patients of varying age groups upon H&E staining, showed inflammation throughout the tissue. The periphery of granulomatous structures in 11 out of 150

patients (Table 1) was observed to be laden with hyaline rich eosinophilic deposits (Figure 1 A, B, C). Expression of SAA, a known amyloidogenic protein is reported to be localized in the periphery of tuberculous granuloma.[25] This heightened the suspicion for amyloid presence in these patients. Hence, CR staining was done in the biopsies of these 11 patients to identify amyloid deposits. The granulomatous structure was observed to exhibit characteristic apple green birefringence, mostly around its periphery (Figure 1 D, E, F) under crossed polarized light. A transition from apple green birefringence to reddish orange coloration was observed under uncrossed polarized light, upon changing the angle of polarizer anticlockwise (Figure 1 G, H, I). Pathologists use this characteristic feature for confirming amyloid presence.[27,28] This confirmed the presence of amyloid deposits in these patients. The findings of this study have pave new ways for understanding the synergistic role of granuloma and SAA in driving amyloid formation in tuberculosis patients. In future, it might also help in accurate diagnosis of amyloid progression and onset even in early stages of tuberculosis.

Patient's code	**Sex**	**Affected organ**	**Biopsy site**
Patient 1	Female	Axillary lymph node	Lymph node
Patient 2	Male	Lymph node	Lymph node
Patient 3	Male	Skin	Skin
Patient 4	Male	Lymph node	Lymph node
Patient 5	Male	Intestine	Intestine
Patient 6	Male	Axillary lymph node	Lymph node
Patient 7	Female	Submandibular lymph node	Lymph node

Patient 8	Female	Uterus	Endometrium and ovary
Patient 9	Female	Lymph node	Lymph node
Patient 10	Male	Intestine	Intestine
Patient 11	Male	Lymph node	Lymph node

Table 1: Detailed information about the organ affected and the biopsy site for amyloid suspected TB patients

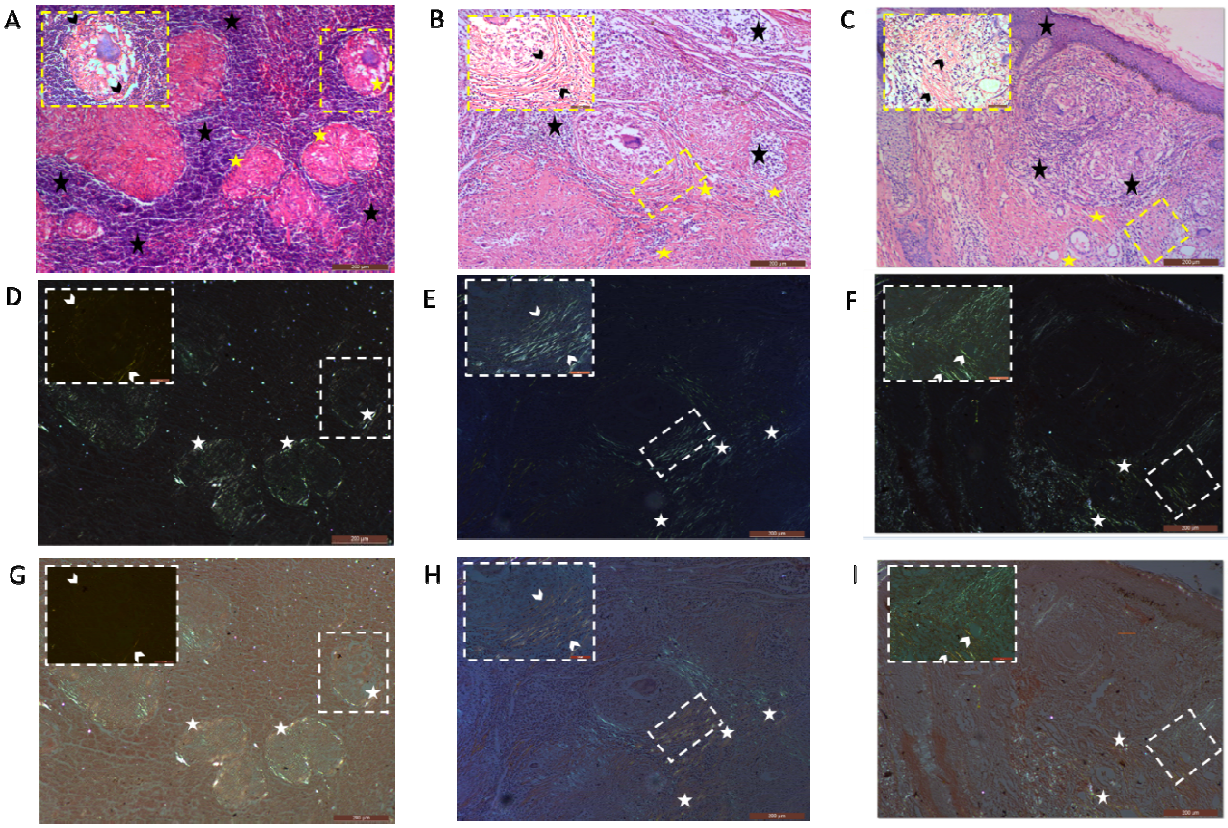

Figure 1: Histology representation of three TB patients showing moderate to extensive inflammation throughout the section (black stars). Eosinophilic hyaline rich deposits were mostly

seen around the periphery of the granulomatous structure (yellow stars and marked by black arrow heads in the inset images) (A, B, C). Congo red staining of the same tissue sections showed apple green birefringence pattern around the periphery of the granuloma (white stars and marked by white arrow heads in the inset images) (D, E, F), consistent with the area having eosinophilic deposits. A reddish orange color (indicated by white stars and marked by white arrow heads in the inset images) observed under uncrossed polarized light (upon rotating the polarizer anticlockwise) confirmed the presence of amyloid deposits (G, H, I). Scale bar: 200μm. Scale bar for inset images: 50 μm.

References

1. Furin, J., Cox, H. & Pai, M. Tuberculosis. *The Lancet* **393**, 1642-1656 (2019).
2. Organization, W.H. Global tuberculosis report 2020. in *Global tuberculosis report 2020* (2020).
3. Loddenkemper, R., Lipman, M. & Zumla, A. Clinical Aspects of Adult Tuberculosis. *Cold Spring Harbor perspectives in medicine* **6**, a017848-a017848 (2015).
4. Seung, K.J., Keshavjee, S. & Rich, M.L. Multidrug-Resistant Tuberculosis and Extensively Drug-Resistant Tuberculosis. *Cold Spring Harbor perspectives in medicine* **5**, a017863-a017863 (2015).
5. Sack, G.H. Serum amyloid A – a review. *Molecular Medicine* **24**, 46 (2018).
6. Stix, B. et al. Proteolysis of AA amyloid fibril proteins by matrix metalloproteinases-1, -2, and -3. *The American journal of pathology* **159**, 561-570 (2001).
7. Röcken, C. et al. Proteolysis of serum amyloid A and AA amyloid proteins by cysteine proteases: cathepsin B generates AA amyloid proteins and cathepsin L may prevent their formation. *Annals of the Rheumatic Diseases* **64**, 808-815 (2005).
8. Lu, J., Yu, Y., Zhu, I., Cheng, Y. & Sun, P.D. Structural mechanism of serum amyloid A-mediated inflammatory amyloidosis. *Proceedings of the National Academy of Sciences* **111**, 5189-5194 (2014).
9. Benditt, E.P. & Eriksen, N. AMYLOID. II. STARCH GEL ELECTROPHORETIC ANALYSIS OF SOME PROTEINS EXTRACTED FROM AMYLOID. *Arch Pathol* **78**, 325-30 (1964).
10. Benditt, E.P., Eriksen, N., Hermodson, M.A. & Ericsson, L.H. The major proteins of human and monkey amyloid substance: Common properties including unusual N-terminal amino acid sequences. *FEBS Lett* **19**, 169-173 (1971).
11. Levin, M., Franklin, E.C., Frangione, B. & Pras, M. The amino acid sequence of a major nonimmunoglobulin component of some amyloid fibrils. *J Clin Invest* **51**, 2773-6 (1972).
12. Ein, D., Kimura, S. & Glenner, G.G. An amyloid fibril protein of unknown origin: partial amino-acid sequence analysis. *Biochem Biophys Res Commun* **46**, 498-500 (1972).
13. Westermark, P. & Nilsson, G.T. Demonstration of amyloid protein AA in old museum specimens. *Arch Pathol Lab Med* **108**, 217-9 (1984).

14. Westermark, G.T., Fändrich, M. & Westermark, P. AA amyloidosis: pathogenesis and targeted therapy. *Annu Rev Pathol* **10**, 321-44 (2015).
15. Nienhuis, H.L.A., Bijzet, J. & Hazenberg, B.P.C. The Prevalence and Management of Systemic Amyloidosis in Western Countries. *Kidney diseases (Basel, Switzerland)* **2**, 10-19 (2016).
16. Chugh, K. et al. Pattern of renal amyloidosis in Indian patients. *Postgraduate medical journal* **57**, 31-35 (1981).
17. Mehta, H.J. et al. Pattern of renal amyloidosis in western India. A study of 104 cases. *J Assoc Physicians India* **38**, 407-10 (1990).
18. Dixit, R., Gupta, R., Dave, L., Prasad, N. & Sharma, S. Clinical profile of patients having pulmonary tuberculosis and renal amyloidosis. *Lung India : official organ of Indian Chest Society* **26**, 41-45 (2009).
19. Engineer, D., Kute, V., Patel, H. & Shah, P. Clinical and laboratory profile of renal amyloidosis: A single-center experience. *Saudi Journal of Kidney Diseases and Transplantation* **29**, 1065-1072 (2018).
20. Sharma, S. et al. Are we Treating or Curing Tuberculosis? Profile of Secondary Renal Amyloidosis in Patients Receiving Anti Tubercular Treatment. *BANTAO Journal* **12**, 103-107 (2014).
21. Petersen, H.J. & Smith, A.M. The role of the innate immune system in granulomatous disorders. *Frontiers in immunology* **4**, 120-120 (2013).
22. Pagán, A.J. & Ramakrishnan, L. Immunity and Immunopathology in the Tuberculous Granuloma. *Cold Spring Harbor perspectives in medicine* **5**, a018499 (2014).
23. Sabir, N., Hussain, T., Mangi, M.H., Zhao, D. & Zhou, X. Matrix metalloproteinases: Expression, regulation and role in the immunopathology of tuberculosis. *Cell Proliferation* **52**, e12649 (2019).
24. Kisilevsky, R. & Subrahmanyan, L. Serum amyloid A changes high density lipoprotein's cellular affinity. A clue to serum amyloid A's principal function. *Lab Invest* **66**, 778-85 (1992).
25. Chen, E.S. et al. Serum amyloid A regulates granulomatous inflammation in sarcoidosis through Toll-like receptor-2. *American journal of respiratory and critical care medicine* **181**, 360-373 (2010).
26. Yakupova, E.I., Bobyleva, L.G., Vikhlyantsev, I.M. & Bobylev, A.G. Congo Red and amyloids: history and relationship. *Bioscience reports* **39**, BSR20181415 (2019).
27. Howie, A.J., Brewer, D.B., Howell, D. & Jones, A.P. Physical basis of colors seen in Congo red-stained amyloid in polarized light. *Laboratory Investigation* **88**, 232-242 (2008).
28. Howie, A.J. & Brewer, D.B. Optical properties of amyloid stained by Congo red: history and mechanisms. *Micron* **40**, 285-301 (2009).
29. Westermark, P. Subcutaneous adipose tissue biopsy for amyloid protein studies. *Methods Mol Biol* **849**, 363-71 (2012).