medRxiv preprint doi: https://doi.org/10.1101/2021.01.04.21249198; this version posted January 4, 2021. The copyright holder for this preprint (which was not certified by peer review) is the author/funder, who has granted medRxiv a license to display the preprint in perpetuity. It is made available under a CC-BY-ND 4.0 International license .

T cell Homeostatic Imbalance in Placentae from Women Infected with HIV in the absence of Vertical Transmission.

Nadia M. Ikumi[1], Komala Pillay[3,4], Tamara Tilburgs[5,6], Thokozile R. Malaba[7], Sonwabile Dzanibe[1] Elizabeth Ann L Enninga[8], Rana Chakraborty[8,9,10], Mohammed Lamorde[11], Landon Myer[7], Saye Khoo[12], Heather B Jaspan[1] and Clive M. Gray[1,2,3*], for the DolPHIN-2 Study Group

[1]Division of Immunology, Institute of Infectious Disease and Molecular Medicine, University of Cape Town, South Africa.

[2]Department of Pathology, University of Cape Town, Cape Town, South Africa

[3]National Health Laboratory Services, Groote Schuur Hospital, Cape Town, South Africa

[4]Division of Anatomical Pathology, Department of Pathology, University of Cape Town, Cape Town, South Africa

[5]Division of Immunobiology, Center for Inflammation and Tolerance, Cincinnati Children's Hospital, Cincinnati OH 45229, USA

[6]Department of Pediatrics, University of Cincinnati College of Medicine, Cincinnati OH 45229, USA

[7]Division of Epidemiology and Biostatistics, School of Public Health and Family Medicine, University of Cape Town, Cape Town, South Africa

[8]Department of Obstetrics and Gynecology, Mayo Clinic, Rochester, MN 55905

[9]Department of Pediatric and Adolescent Medicine, Mayo Clinic College of Medicine and Science, Minnesota, USA

[10]Department of Immunology, Mayo Clinic, Rochester, MN 55905

[11]Infectious Diseases Institute, College of Health Sciences, Makerere University, Kampala, Uganda

[12]Molecular and Clinical Pharmacology, University of Liverpool, Liverpool, UK; Royal Liverpool and Broadgreen University Hospitals NHS Trust, Liverpool, UK

Running title: Altered T cell immunity during HIV in the placenta

NOTE: This preprint reports new research that has not been certified by peer review and should not be used to guide clinical practice.

medRxiv preprint doi: https://doi.org/10.1101/2021.01.04.21249198; this version posted January 4, 2021. The copyright holder for this preprint (which was not certified by peer review) is the author/funder, who has granted medRxiv a license to display the preprint in perpetuity. It is made available under a CC-BY-ND 4.0 International license .

Conflict of interest statement

The authors have declared that no conflict of interest exists.

***Corresponding Author**

Clive M Gray, Division of Immunology, Institute of Infectious Disease and Molecular Medicine, Falmouth Building, Faculty of Health Sciences, University of Cape Town, Anzio Road, Observatory, Cape Town, South Africa, 7925; Tel: +27 21 406 6616; Email: clive.gray@uct.ac.za

Word count: Abstract: 200 words, Lay abstract: 192 words; Main text 3490; 47 references; 5 Figures and 2 Tables; supplementary figures <25MB.

medRxiv preprint doi: https://doi.org/10.1101/2021.01.04.21249198; this version posted January 4, 2021. The copyright holder for this preprint (which was not certified by peer review) is the author/funder, who has granted medRxiv a license to display the preprint in perpetuity. It is made available under a CC-BY-ND 4.0 International license .

ABSTRACT

Background: Implementation of Option B+ antiretroviral therapy (ART) has significantly lowered vertical transmission rates but has also increased numbers of HIV-exposed uninfected children (HEU), who remain vulnerable to morbidities. Here, we investigated whether altered immune status in HEU originates in the placenta.

Methods: We analyzed T cells from term placentae decidua and villous tissue and paired cord blood from pregnant women living with HIV (PWLWH) who initiated ART late in pregnancy (n=21) with HIV negative controls (n=9).

Results: Placentae from PWLWH showed inverted CD4:CD8 ratios and higher proportions of tissue resident CD8+ T cells in villous tissue relative to control placentae. CD8+ T cells in the fetal capillaries, which were of fetal origin, positively correlated with maternal plasma viraemia prior to ART initiation, implying that imbalanced T cells persisted throughout pregnancy. Additionally, the expanded memory differentiation of CD8+ T cells was confined to the fetal placental compartment and cord blood, but was not observed in the maternal decidua.

Conclusion: T cell homeostatic imbalance in the blood circulation of PWLWH is reflected in the placenta. The placenta may be a causal link between HIV-induced maternal immune changes during gestation and altered immunity in newborn infants in the absence of vertical transmission.

Keywords: T cells, placenta, HIV, prolonged exposure, placenta pathology

medRxiv preprint doi: https://doi.org/10.1101/2021.01.04.21249198; this version posted January 4, 2021. The copyright holder for this preprint (which was not certified by peer review) is the author/funder, who has granted medRxiv a license to display the preprint in perpetuity. It is made available under a CC-BY-ND 4.0 International license .

Lay Summary

The effective prevention of HIV transmission during pregnancy with the rollout of antiretroviral therapy (ART) has resulted in increased numbers of HIV-exposed uninfected children (HEU). These children are vulnerable to infections and health problems and they have altered cellular immune systems at birth. We investigated whether these immune alterations may originate in the placenta, as this fetal organ maintains life during pregnancy. Do immune alterations in the newborn child originate in the placenta? After collecting placentae at term from pregnant women living with HIV (PWLWH), who started ART in the third trimester (n=21) and from HIV negative controls (n=9), we isolated T cells from dissected placental tissue and matching cord blood. Placentae from PWLWH showed inverted CD4:CD8 ratios in the placenta and cord blood with higher numbers of CD8+ T cells in the fetal part of the placenta. These CD8+ T cells mirrored events in the blood circulation of the mother and the altered balance of T cell immunity in the PWLWH was reflected in the placenta. Accordingly, the placenta may be a pivotal link between HIV-induced maternal immune changes and altered immunity in newborn infants in the absence of vertical transmission.

medRxiv preprint doi: https://doi.org/10.1101/2021.01.04.21249198; this version posted January 4, 2021. The copyright holder for this preprint (which was not certified by peer review) is the author/funder, who has granted medRxiv a license to display the preprint in perpetuity. It is made available under a CC-BY-ND 4.0 International license .

Background

In adults, HIV causes severe immune dysregulation, characterized by systemic depletion of CD4+ T cells, increased HIV-1 specific CD8+ T cells, inflammation and a progressive failure of the immune system[1–3]. Initiation of ART has been shown to augment HIV-specific CD4+ T cell responses, but normalization of the CD4:CD8 T cell ratio does not occur in a large proportion of HIV positive individuals[4]. In pregnant women living with HIV (PWLWH), pregnancy is not associated with HIV disease progression, although it has been associated with functional impairment of systemic effector T cells and an overall altered response against HIV control[5,6].

Placentae from PWLWH exhibit increased signs of inflammation and injury affecting maternal vasculature and circulation[7,8]. Although the maternal and fetal circulation within the placenta takes place in distinct compartments, there is evidence that maternal HIV infection impacts the fetal immune system. HIV-unexposed uninfected children (HUU) have an almost completely naïve T cell repertoire, but at birth HIV-exposed uninfected children (HEU) can have increased proportions of differentiated immune cells suggestive of antigen experience *in utero*[9,10]. This scenario raises the question of how HIV exposure *in utero* potentially creates perturbations of immunity in HEU[11,12].

In healthy human pregnancies, T cells in the placenta have been shown to constitute approximately 5-20% of total leukocytes in the decidua and this proportion increases up to over 40% at term[13,14]. CD8+ T cells are the most abundant subset and are important in promoting embryo implantation and providing immune protection against infection[15,16]. CD4+ T cell subsets have a number of key roles including the establishment and maintenance of fetal-maternal (FM) tolerance[17,18]. Fetus-specific CD4+ Tregs have been shown to migrate towards the FM interface where they are enriched to guard against breakdown in FM tolerance[18]. In contrast, the presence of CD8+ T cells in the villous tissue is often associated with villitis of unknown etiology (VUE), an

medRxiv preprint doi: https://doi.org/10.1101/2021.01.04.21249198; this version posted January 4, 2021. The copyright holder for this preprint (which was not certified by peer review) is the author/funder, who has granted medRxiv a license to display the preprint in perpetuity. It is made available under a CC-BY-ND 4.0 International license .

inflammatory state of the placenta characterized by the infiltration of maternal CD8+ T cells and macrophages into the villi[19,20].

To test the hypothesis that maternal HIV infection is associated with disruption of T cell homeostasis in the placenta and cord blood from HEU newborns, we examined term placentae from PWLWH from a randomized trial in pregnant mothers initiating dolutegravir versus efavirenz-containing therapy in the third trimester (DolPHIN-2: NCT03249181)[21], as well as pregnant women not living with HIV (PWNLHIV), serving as controls. We show that placentae from PWLWH have inverted CD4:CD8 ratios with higher CD8+ T cells in villous tissue relative to control placentae contributing to T cell homeostatic imbalance in the placenta at birth.

medRxiv preprint doi: https://doi.org/10.1101/2021.01.04.21249198; this version posted January 4, 2021. The copyright holder for this preprint (which was not certified by peer review) is the author/funder, who has granted medRxiv a license to display the preprint in perpetuity. It is made available under a CC-BY-ND 4.0 International license .

Methods

Cohort

We included 21 placentae with 9 paired cord blood samples from PWLWH and HEU and 9 placentae from PWNLHIV with 5 cord blood samples from HUU in this study. The PWLWH group was nested in the DolPHIN-2 study and recruited from the Gugulethu Community Health Centre, Cape Town[21]. HIV negative controls were enrolled nearby from the Khayelitsha Site B Midwife Obstetric Unit, Cape Town. All placentae were from term deliveries (>37 weeks' gestation).

Clinical Data collection

As part of DolPHIN-2, maternal systemic CD4 T cell counts were measured at ART initiation and plasma viral load (VL) copies were measured at screening, enrolment and ART initiation (visit 1), one week after ART initiation (visit 2), four weeks after ART initiation (visit 3), thirty-six weeks' GA (visit 4) and approximately ± 14 days after delivery (visit 5). The level of detection was 50 copies per ml[21].

Placenta and cord blood processing.

Cells were isolated from each placenta as previously described[22] and illustrated in Figure 1. Placentae were collected in RPMI 1640 supplemented with 10% fetal calf serum (FCS) and penicillin/streptomycin at room temperature and processing was performed within six hours of delivery. Briefly, each placenta was macroscopically inspected and dissected to obtain the decidua parietalis, basalis and villous tissue. The sections were rinsed in phosphate-buffered saline (PBS) to remove maternal blood. Enzymatic lymphocyte isolation was performed using 0.2% Collagenase I and 0.02% DNAse I in RPMI 1640 at 37^0C for 75 minutes. We then obtained the lymphocyte fraction following Percoll density centrifugation at the 70-45% interface and incubated the cells with violet amine reactive viability dye (VIVID, Thermofisher) according to manufacturer's instructions. The cells were then fixed using BD FACS™ lysing solution, cryopreserved in 90% FCS - 10% Dimethyl sulfoxide

medRxiv preprint doi: https://doi.org/10.1101/2021.01.04.21249198; this version posted January 4, 2021. The copyright holder for this preprint (which was not certified by peer review) is the author/funder, who has granted medRxiv a license to display the preprint in perpetuity. It is made available under a CC-BY-ND 4.0 International license .

(DMSO) and stored in liquid nitrogen until analysis. Cord blood mononuclear cells were isolated on Ficoll, fixed and cryopreserved in the same fashion as placental lymphocytes.

Placenta pathology

Placentae were fixed in 10% buffered formalin prior to histopathology examination at Red Cross Memorial Children's Hospital, Cape Town, South Africa. Specimens were macroscopically examined and samples from the umbilical cord, placental membranes and placental disk were obtained based on the Amsterdam Placental Workshop Group Consensus Statement.[23] Briefly, four blocks were prepared from each placenta; including a roll of the placental membranes, two cross sections of the umbilical cord; and full-thickness sections of the placental parenchyma including one from the cord insertion. Tissue sections were 3-5µm thick and were stained with haemotoxylin and eosin for routine histological examination. Placentae were examined for features of prolonged meconium exposure, chorioamnionitis with or without a maternal or fetal inflammatory response[24,25], maternal vascular malperfusion (MVM) with decidual vasculopathy, and in the absence of decidual vasculopathy, MVM was indicated by a small placenta for gestational age accompanied by at least two villous changes (villous infarct, retroplacental haematoma, accelerated villous maturation or distal villous hypoplasia). In the case of normal placenta weights for gestational age, at least 3-4 villous features were noted to be placed in the category of MVM[26]. Chronic deciduitis was defined as abnormal infiltration of lymphocytes and plasma cells in the decidua[23].

Flow cytometry

Placental and cord blood cells were labeled with fluorochrome-conjugated monoclonal antibodies: CD3 (Clone UCHT1), CD4 (Clone SK3), CD8 (Clone SK1), CD45RA (Clone H100), CD28 (Clone CD28.2), CD14 (Clone MHCD1417) and CD45 (Clone MHCD4530). Samples were acquired using an LSR II flow cytometer (BD Biosciences). Total CD4+ and CD8+ T cells were expressed as a proportion of CD3+ T cells gated from the viable CD45+ CD14- cells (Supplementary Figure 1).

medRxiv preprint doi: https://doi.org/10.1101/2021.01.04.21249198; this version posted January 4, 2021. The copyright holder for this preprint (which was not certified by peer review) is the author/funder, who has granted medRxiv a license to display the preprint in perpetuity. It is made available under a CC-BY-ND 4.0 International license .

Immunohistochemistry

Formalin fixed paraffin embedded (FFPE) placenta tissue blocks were cut into 5 µM sections and stained with CD8 (Clone C8/144B), with tonsillar tissue serving as a control. Briefly, the slides were baked overnight at 56^{0}C and rehydrated in xylene followed by varying concentrations of alcohol and then incubated in 3% hydrogen peroxide. Heat-mediated antigen retrieval was performed using an EDTA buffer (pH9). The slides were then incubated with 1% Bovine Serum Albumin (BSA) and stained with the primary antibody anti-CD8. The images were acquired on Zeiss Axioskop 200 upright Fluorescence microscope with an AxioCam high resolution colour (HRC) camera.

Fluorescence in situ hybridization (FISH)

We used five placental samples from male fetuses to identify the origin of the infiltrating lymphocytes by FISH. Briefly, the slides were baked at 90^{0}C for 15 minutes, deparaffinized in xylene, dehydrated in 100% ethanol and then placed in 10mM Citric Acid (pH 6.0). The slides were then dehydrated in varying concentrations of ethanol (70%, 85% and 100%). We then applied a working solution of DXZ1/DYZ3 (Abbott Laboratories, Des Plaines, IL, USA) to the target areas, co-denatured with a ThermoBrite (Abbott Laboratories) and hybridized overnight at 37^{0}C. The slides were then counter stained with 4'-6'-diamidino-2-phenylindole (DAPI) (Vector Laboratories). Tissue samples were scanned and the qualitative result was determined based on observed signal patterns by CytoVision (Leica Biosystems, Germany).

Statistics

All flow cytometry data were analyzed using FlowJo version 10 (Treestar). Statistical analyses were performed using Prism version 8 (Graphpad Software, San Diego, CA), STATA version 12.0 (Stata Corporation, College Station, Texas, USA) or R[27]. Immunohistochemistry tissue cell counts for each tissue section were obtained by counting the total number of positive CD8+ T cells on the immunostained slides (40x magnification) using Image J Fiji version 2 (WS Rasband, National

medRxiv preprint doi: https://doi.org/10.1101/2021.01.04.21249198; this version posted January 4, 2021. The copyright holder for this preprint (which was not certified by peer review) is the author/funder, who has granted medRxiv a license to display the preprint in perpetuity. It is made available under a CC-BY-ND 4.0 International license .

Institute of Health, Bethesda, MD). Tests of significance were performed using Mann-Whitney *U* and Kruskal-Wallis tests for intergroup comparisons. The associations between cell proportions and viral load or CD4 T cell counts were assessed using simple linear regression. All bivariate analyses including maternal and infant characteristics, and placental pathology stratified by HIV-exposure or by ART regimen were compared using Chi^2 or Fisher's exact test and Wilcoxon rank-sum tests.

Study approval

The study protocol, informed consent forms and all data collection tools were approved by the University of Cape Town, Faculty of Health Sciences Research Ethics Committee. Written and signed informed consent was obtained from all participants, including collection of placentae prior to study inclusion.

Results

Participant Characteristics.

Maternal and newborn infant characteristics are shown in Table 1. No differences in maternal age were noted between PWNLHIV and PWLWH at enrolment, with the median gestational age (GA) being 30 weeks and 28 weeks between the groups. PWLWH were more likely to be multigravida (p=0.003). Median GA at delivery was 40 weeks in PWNLHIV and 39 weeks in the PWLWH (p=0.03) and there was a tendency toward lower birthweight in HEU (p=0.07). Among the 21 PWLWH, 16 (76.2%) were randomised to receive efavirenz (EFV + TDF + 3TC) and 5 (23.8%), dolutegravir (DTG + TDF + 3TC), shown in Supplementary Table 1. Median CD4 count at ART initiation was 358 cells/mm^3 (IQR 278 – 477), with no difference between ART groups (Supplementary Table 2). The median VL at ART initiation was 4.54 log_{10} RNA copies/ml (IQR 3.85 – 4.80) in the EFV group versus 3.83 log_{10} RNA copies/ml (3.49 – 3.83) in the DTG group, with a combined viraemia of 4.28 log_{10} RNA copies/ml (Supplementary Table 2). Both ART groups were on treatment for a median of 84 days IQR (44 - 105) and women in the DTG arm achieved viral suppression at a faster rate (cut off ≤ 50 copies/ml or 1.69

medRxiv preprint doi: https://doi.org/10.1101/2021.01.04.21249198; this version posted January 4, 2021. The copyright holder for this preprint (which was not certified by peer review) is the author/funder, who has granted medRxiv a license to display the preprint in perpetuity. It is made available under a CC-BY-ND 4.0 International license .

$\log_{10}$ RNA copies/ml) at 4 weeks versus 2 weeks after delivery (Supplementary Table 2 and [21]). For the purposes of this study, we combined the placentae from two ART groups, as there were only 5 collected from the DTG arm.

Placental weight is altered by HIV.

Table 2 shows placenta characteristics and pathology stratified by HIV status. PWNLHIV had significantly larger placentae (468g, IQR 426 - 533) compared to the PWLWH (394g, IQR 343 - 469; p=0.02), with 38% of placentae in PWLWH being <10th percentile weight-for-gestation compared to 0% in PWNLHIV. These differences were also reflected the in the fetal-placental (FP) ratios, where all cases with FP ratios > 90th percentile were in the PWLWH cases (p=0.02). Placental histopathology identified 2 cases (9.5%) of chronic deciduitis and 6 cases (28.6%) of MVM, all in the PWLWH. There were no significant differences in the incidence of meconium exposure and chorioamnionitis between PWLWH and PWNLHIV, and there was no evidence of villitis of unknown etiology (VUE) in any of the placentae. There were no significant differences in the placental weight, FP ratio and placental pathology between the two ART groups (Supplementary Table 3).

HIV infection during pregnancy alters placental CD4+ and CD8+ T cell proportions.

Figure 2A shows significantly lower proportions of CD4+ T cells in decidua parietalis and basalis, but not in the villous tissue, comparing placentae from PWLWH with PWNLHIV. The proportion of CD8+ T cells was significantly increased (Figure 2A) in all three placental compartments resulting in significantly lower CD4:CD8 T cell ratios in the three placental tissues from PWLWH (Figure 2B). Notably, the inverted CD4:CD8 ratio in villous tissue was due to the increased CD8+ T cells in the villous tissue. The inverted CD4:CD8 ration was partially reflected in cord blood from HEU (Figures 2B). No differences were identified in T cell proportions when stratified by the different ART regimens (Supplementary Figure 2).

medRxiv preprint doi: https://doi.org/10.1101/2021.01.04.21249198; this version posted January 4, 2021. The copyright holder for this preprint (which was not certified by peer review) is the author/funder, who has granted medRxiv a license to display the preprint in perpetuity. It is made available under a CC-BY-ND 4.0 International license .

Maternal absolute peripheral blood CD4 T cell counts, measured pre-ART at a median of 28 weeks' gestation, positively correlated with the proportion of CD4+ T cells in the decidua and negatively correlated with the proportion of CD8+ T cells in decidua and villous tissue (Figure 2C and D). A similar trend, without significance, was observed in cord blood. Thus, the inverted placental tissue CD4:CD8+ T cell ratios appeared to reflect the maternal peripheral immune status but was mirrored to a lesser extent in the cord blood of HEU. This correlation was temporally dissociated, where correlations were made between blood measured at 28 weeks and placentae measured at 38-40 weeks of gestation, suggesting that inverted T cell ratios persisted throughout pregnancy.

Maternal viral load prior to ART initiation correlates with placental, but not cord blood, CD4+ and CD8+ T cell proportions.

Maternal plasma viraemia dropped precipitously over time from enrolment to delivery (-12 weeks beforehand), where PWLWH receiving DTG decreased at a faster rate (Figure 3A)[17]. As expected, the enrolment plasma viraemia, ranging from 1.69 - 6.0 $\log_{10}$ RNA copies/ml, significantly inversely correlated with the absolute maternal peripheral blood CD4+ T cell count determined pre-ART, at enrolment (Figure 3B). Interestingly, pre-ART viremia also showed a significant negative correlation with proportions of CD4+ T cells in the decidua parietalis and basalis (Figure 3C) and a positive correlation with CD8+ T cells in the decidua parietalis, basalis and villous tissue at delivery (Figure 3D). The association between maternal viral loads over time and the proportions of decidual CD4+ and CD8+ T cells were maintained at -8 weeks and -4 weeks before delivery for CD4+ T cells (Supplementary Figure 3) and up to -8 weeks before delivery for CD8+ T cells (Supplementary Figure 4). Maternal viremia did not correlate with the proportion of T cells in the cord blood (Figure 3C and 3D), suggesting that maternal VL (pre- and post-ART initiation) can influence the homeostatic balance of T cells in the placenta, but not in the "newborn" immune compartment.

medRxiv preprint doi: https://doi.org/10.1101/2021.01.04.21249198; this version posted January 4, 2021. The copyright holder for this preprint (which was not certified by peer review) is the author/funder, who has granted medRxiv a license to display the preprint in perpetuity. It is made available under a CC-BY-ND 4.0 International license .

Immunohistochemistry confirms anatomical location and fetal origin of CD8+ T cells in villous tissue.

Analysis of placental villi from 13 PWLWH and 3 PWNLHIV controls showed the presence of CD8+ cells in the fetal capillaries (Figure 4A). The numbers of CD8+ T cells positively correlated with pre-ART maternal viremia (Figure 4B), confirming the flow cytometric analysis (Figures 2A, 3D). Using FISH to detect X and Y chromosomes in cells located within the villi from 5 placentae with male births, we confirmed the presence of male (fetal) cells in fetal capillaries (Figure 4C). Thus the immunohistochemistry analysis confirms the anatomical location and fetal origin of the increased proportions of CD8+ T cells in villous tissue. The fetal (male) origin of the CD8+ T cells in placental villi is consistent with the absence of VUE, a lesion that is characterized by maternal immune infiltrates[20,28].

HIV exposure increases differentiation of CD8+ T cells in placental villi and fetal cord blood, but not in the maternal placental compartments.

CD45RA and CD28 was used to identify the proportions of naïve (CD45RA+CD28+), early differentiated (ED, CD45RA-CD28+), late differentiated (LD, CD45RA-CD28-) and terminally differentiated (TD, CD45RA+CD28-) memory CD4+ and CD8+ T cells from villous tissue and matching cord blood (Figure 5A). We observed significantly lower proportions of naïve CD8+ T cells and significantly higher proportions of LD CD8+ T cells in villous tissue and cord blood of HEU compared to HUU (Figure 5B). The CD4+ T cells in the villous tissue were predominantly of a naïve and ED phenotype while the cord blood cells were predominantly naïve. There were no significant differences in CD4+ T cell differentiation state based on HIV-exposure (Supplementary Figure 5). In addition, no significant differences in the stage of CD4+ and CD8+ T cell differentiation in decidua parietalis and decidua basalis was observed between the HIV groups (Supplementary Figure 6). Thus, the increased differentiation state of CD8+ T cells is confined to the fetal placental and fetal cord blood compartments and not observed in the maternal placental compartments. Interestingly, there

medRxiv preprint doi: https://doi.org/10.1101/2021.01.04.21249198; this version posted January 4, 2021. The copyright holder for this preprint (which was not certified by peer review) is the author/funder, who has granted medRxiv a license to display the preprint in perpetuity. It is made available under a CC-BY-ND 4.0 International license .

was no correlation between maternal pre-ART VL and memory stage of CD8+ T cells in placental villous tissue and cord blood (data not shown).

medRxiv preprint doi: https://doi.org/10.1101/2021.01.04.21249198; this version posted January 4, 2021. The copyright holder for this preprint (which was not certified by peer review) is the author/funder, who has granted medRxiv a license to display the preprint in perpetuity. It is made available under a CC-BY-ND 4.0 International license .

Discussion

We present data from a unique cohort of PWLWH who initiated ART late in pregnancy and show that maternal HIV infection has a clear impact on T cell subsets in the decidua, villous tissue and cord blood. As the decidua and decidual immune cells are of maternal origin, it may not be surprising to find such a footprint[29]. Maternal HIV infection likely affects and kills maternal decidual CD4+ T cells and fewer peripheral blood T cells may traffic to decidual tissue; chemokine gradients have been shown to play a key role in the trafficking of maternal T cells into the decidua during pregnancy[30]. We show that in contrast to the decidua, the inverted CD4:CD8 ratio in the fetal villous tissue was largely due to an increased proportion of CD8+ T cells and not, as observed in the other tissues, due to a decrease in CD4+ T cells. These CD8+ T cells were of an early-late differentiated phenotype, suggestive of previous antigen experience[31,32].

The human placenta has two circulatory compartments: the utero-placental unit for the trafficking of maternal blood and the feto-placental unit for the fetal blood circulation[33,34]. Approximately 40% of the total fetal-placental blood volume exists as a reservoir in the placenta[34]. The cells we characterised in the villous tissue and cord blood are from the feto-placental unit and these villous tissue resident cells are likely predominantly from the placental reservoir. A key question is whether the increased CD8+ T cell differentiation in placental villi and cord blood is due to direct exposure to HIV antigens, presence of other pathogens in placental or fetal compartments (e.g. CMV) or increased levels of other non-infectious inflammatory cues in placentae of PWLWH. There is evidence that despite separation of fetal and maternal circulations, viral particles, structural and core HIV proteins have been shown to cross the placental barrier in the absence of fetal infection leading to altered immune profiles in HEU infants[35,36]. A number of studies have also described HIV-specific T cell responses in HEU infants, postulated to have been primed by exposure to HIV antigens *in utero*[11,37,38]. The magnitude of these responses is greatest soon after birth but are not detected in older HEU children, suggesting that in the absence of continuous exposure these

medRxiv preprint doi: https://doi.org/10.1101/2021.01.04.21249198; this version posted January 4, 2021. The copyright holder for this preprint (which was not certified by peer review) is the author/funder, who has granted medRxiv a license to display the preprint in perpetuity. It is made available under a CC-BY-ND 4.0 International license .

responses wane[10,38]. The lower proportion of naïve cells and increased memory T cells reflected in villous tissue and cord blood mirror previous studies; HEU infants have been shown to have reduced CD4+ T cell numbers and increased CD8+ T cells compared to HUU infants at birth[39,40]. HEU infants have also been shown to have lower naïve cells thought to be due to thymic involution and frequent stimulation and expansion of the antigen-specific T cells in an effort to regenerate the T cell pool[41–43]. Whether the same findings would be recapitulated in PWLHIV with preconception suppressed viral loads is unknown.

Interestingly the elevated proportions of CD8+ T cells found embedded in the placental villous tissue from PWLHIV were shown to be sequestered within the fetal capillaries. Furthermore, these CD8+ T cells within villous tissue were proportional to maternal viremia. The absence of overt VUE corroborates the finding that expanded CD8+ T cell fractions are of fetal and not maternal origin. Previous studies have suggested that the presence of T cells in the villi during normal pregnancy reflect VUE[20]. However, there is emerging evidence, using IHC staining of villi sections from early elective termination placentae, of the presence of CD45+ $\alpha\beta$ T cells, although these cells were undetectable at term[44]. In a separate study, using single cell transcriptomic analysis in placentae from women with or without preterm labour, where there were no reported maternal infections, and villous tissue was shown to contain a mixture of fetal and maternal immune cells[45]. We cannot discount the possibility that there was also a mix of maternal and fetal CD8+ T cells in placental villi in our study.

Of particular note, women were ART naïve during the first and second trimester and it is likely that prolonged HIV exposure may have contributed to altered placental development and the significantly lower placental weight observed. Interestingly, all cases of maternal vascular malperfusion (MVM) were reported in placentae from HIV-infected women and possibly reflects placental injury affecting maternal vasculature and perfusion and increasing the risk of an adverse

medRxiv preprint doi: https://doi.org/10.1101/2021.01.04.21249198; this version posted January 4, 2021. The copyright holder for this preprint (which was not certified by peer review) is the author/funder, who has granted medRxiv a license to display the preprint in perpetuity. It is made available under a CC-BY-ND 4.0 International license .

birth outcome[26]. We have previously reported on MVM in placentae from PLWHIV on long-term ART, an incidence of about 27% overall, similar to Kalk *et al*. [7,46]. It is likely that HIV and/or ART exposure alters factors involved in vascular development, resulting in placental insufficiency and increased risk of adverse birth outcomes[47].

In conclusion, we provide evidence that *in utero* exposure to HIV results in an altered immune footprint in both the utero-placental and feto-placental compartments. Despite the initiation of ART in the third trimester, resulting in either full or partial maternal viral suppression by the time of delivery, there was a significant imbalance in term placental T cell homeostasis and to a lesser degree in the cord blood. Our data suggests that the placenta may be a causal link between maternal and neonatal T cell perturbations previously observed in HEU newborns.

medRxiv preprint doi: https://doi.org/10.1101/2021.01.04.21249198; this version posted January 4, 2021. The copyright holder for this preprint (which was not certified by peer review) is the author/funder, who has granted medRxiv a license to display the preprint in perpetuity. It is made available under a CC-BY-ND 4.0 International license .

Author contributions

NMI, ML, SK, LM, HBJ, CMG: Conceptualization and design of the study

NMI, TT: Panel design, sample preparation and development of methods

KP: Histopathology scoring and interpretation

NMI, TRM and SD: Statistical analysis

NMI, TT, KP, TM, LM, EAE, RC, HBJ, CMG: Writing the manuscript

Funding

This research was supported by a Fellowship to NMI from the AXA Research Fund, Paris. The content is solely the responsibility of the authors and does not necessarily represent the official views of those of the AXA Research Fund. The research is part of the DOLPHIN-2 clinical trial sponsored by UNITAID (ClinicalTrials.gov NCT03249181).

Acknowledgments

We wish to thank all the study participants in this study; all the members of the DOLPHIN-2 clinical trial and INFANT placenta study. We also wish to thank Nonzwakazi Bangani, Goitseone Thamae, Michelle Barboure, Berenice Alinde and Lizette Fick for their expert assistance in sample processing and Dr Amsha Ramburan for capturing the FISH images.

medRxiv preprint doi: https://doi.org/10.1101/2021.01.04.21249198; this version posted January 4, 2021. The copyright holder for this preprint (which was not certified by peer review) is the author/funder, who has granted medRxiv a license to display the preprint in perpetuity. It is made available under a CC-BY-ND 4.0 International license .

Figure Legends

Figure 1: Lymphocyte isolation from the human placenta

Stepwise isolation of lymphocytes from the human placenta decidua parietalis (DP), decidua basalis (DB) and villous tissue (VT): (1) dissection of the whole placenta; (2) multiple rounds of maternal blood rinsing to avoid contamination followed by enzymatic digestion of each dissected tissue; (3) lymphocyte separation obtained by Percoll density centrifugation; (4) cryopreservation of fixed cells and immunophenotyping using flow cytometry.

Figure 2: Proportions of T cells in the placenta and cord blood

(A) Box plots (showing medians and interquartile ranges) of CD3+CD4+CD8- T cells and CD3+CD4-CD8+ T cell proportions isolated from the decidua parietalis, decidua basalis, villous tissue and cord blood from Pregnant Women not living with HIV (PWNLHIV) and Pregnant Women living with HIV (PWLWH) and HIV unexposed uninfected (HUU) and HIV exposed uninfected (HEU) cord bloods. **(B)** Box plots (showing medians and interquartile ranges) of CD4:CD8 T cell ratios in the decidua parietalis, decidua basalis, villous tissue and cord blood from Pregnant Women not living with HIV (PWNLHIV) and Pregnant Women living with HIV (PWLWH) and HIV unexposed and uninfected (HUU) and HIV exposed uninfected (HEU) cord bloods. Tests of significance were performed using the Mann-Whitney *U* test. **(C)** Correlation plots between the absolute maternal CD4 count at 28 weeks' gestation prior to ART initiation and the proportion of CD4+ T cells isolated from the decidua parietalis, basalis, villous tissue and cord blood. Statistical analysis was performed using the Spearman rank test and the grey shaded areas represent the 95% confidence intervals. **(D)** Correlation plots between the absolute maternal CD4 count at 28 weeks' gestation prior to ART initiation and the proportion of CD8+ T cells isolated from the decidua parietalis, basalis, villous tissue and cord blood. Statistical analysis was performed using the Spearman rank test and the grey shaded areas represent the 95% confidence intervals.

Figure 3: Proportions of CD4+ and CD8+ T cells in the placenta and maternal viral load

(A) Line plot depicting participant viral load trajectories over time at enrolment and ART initiation (VLV1, 12 weeks before delivery), one week after ART initiation (VLV2, 8 weeks before delivery), four weeks after ART initiation (VLV3, 4 weeks before delivery), thirty-six weeks' GA (VLV4, 2 weeks before delivery) and +/- 14 days after delivery (VLV5, +/- 2 weeks after delivery). The women were randomised to receive efavirenz (EFV + TDF

medRxiv preprint doi: https://doi.org/10.1101/2021.01.04.21249198; this version posted January 4, 2021. The copyright holder for this preprint (which was not certified by peer review) is the author/funder, who has granted medRxiv a license to display the preprint in perpetuity. It is made available under a CC-BY-ND 4.0 International license .

+ 3TC) (denoted in black) and dolutegravir (DTG + TDF + 3TC) (denoted in blue). **(B)** Correlation plot between maternal systemic absolute CD4 counts at enrolment prior to ART initiation with maternal viral load at enrolment and ART initiation (28 weeks GA). Statistical analysis was performed using the Spearman rank test and the grey shaded area represents the 95% confidence intervals. **(C)** Correlation plots between CD4+ T cell proportions in the placenta and maternal viral load at enrolment and ART initiation (28 weeks GA) in the decidua parietalis, basalis, villous tissue and cord blood. Statistical analysis was performed using the Spearman rank test and the grey shaded area represents the 95% confidence intervals. **(D)** Correlation plots between CD8+ T cell proportions in the placenta and maternal viral load at enrolment and ART initiation (28 weeks GA) in the decidua parietalis, basalis, villous tissue and cord blood. Statistical analysis was performed using the Spearman rank test and the grey shaded area represents the 95% confidence intervals.

Figure 4: Anatomical location of CD8+ T cells in the villous tissue

(A) Representative immunohistochemical stained images of CD8+ T cells in villous tissue sections denoted in brown dots and black arrows in the villi of placentae from HIV-infected and –uninfected mothers (40x magnification). **(B)** Correlation plot between the density of tissue-bound CD8+ T cells in the villi and maternal viral load at ART initiation (pre-ART). Statistical analysis was performed using the Spearman rank test and the black curved lines represent the 95% confidence intervals. **(C)** Representative Fluorescence in situ Hybridization (FISH) images of lymphocytes (white arrows) in the villous tissue from placentas from male infants. The X chromosome is denoted in green and Y chromosome denoted in red (digitally scanned slides).

Figure 5: Memory phenotype of CD4 and CD8 T cells in the Villous Tissue

(A) Representative flow cytometry contour plots of Naïve, Early differentiated (ED), Late differentiated (LD) and Terminally differentiated (TD) CD4+ T cells and CD8+ T cells in the villous tissue (VT; upper panel) of placentae from PWNLHIV and PWLWH and cord blood from HIV unexposed and uninfected (HUU) and HIV exposed uninfected (HEU). **(B)** Box plots (showing medians and interquartile ranges) of CD8+ Naïve, Early differentiated (ED), Late differentiated (LD) and Terminally differentiated (TD) T cells in the villous tissue and cord blood from HIV unexposed and uninfected (HUU) and HIV exposed uninfected (HEU). Tests of significance were performed using the Mann-Whitney *U* test.

medRxiv preprint doi: https://doi.org/10.1101/2021.01.04.21249198; this version posted January 4, 2021. The copyright holder for this preprint (which was not certified by peer review) is the author/funder, who has granted medRxiv a license to display the preprint in perpetuity. It is made available under a CC-BY-ND 4.0 International license .

Supplementary Figures

Supplementary Figure 1: Gating strategy to delineate CD3+ T cells

Representative flow cytometry dot plots depicting the gating strategy to delineate CD4+ and CD8+ T cells gated from a live CD45+ CD14- CD3+ population in the placenta.

Supplementary Figure 2: Proportions of CD3+ T cells in the placenta and cord blood by ART group

Box plots (showing medians and interquartile ranges) of (A) CD4+ and (B) CD8+ T cells in the decidua parietalis (DPar), decidua basalis (DBas), villous tissue (VTiss) and cord blood (Cblood) from HIV-uninfected (MHIV neg) and infected mothers on efavirenz (EFV) or dolutegravir (DTG) and HIV unexposed and uninfected (HUU) and HIV exposed uninfected (HEU) cord bloods. Tests of significance were performed using the Kruskal-Wallis test.

Supplementary Figure 3: Proportions of CD4+ T cells in the placenta, cord blood and maternal viral load

Correlation plots between CD4+ T cell proportions in the placenta and cord blood and maternal viral load one week after ART initiation (visit 2, 8 weeks before delivery), four weeks after ART initiation (visit 3, 4 weeks before delivery) and thirty-six weeks' GA (visit 4, 2 weeks before delivery) in the decidua parietalis, basalis, villous tissue and cord blood. Statistical analysis was performed using the Spearman rank test and the grey shaded area represents the 95% confidence intervals.

Supplementary Figure 4: Proportions of CD8+ T cells in the placenta, cord blood and maternal viral load

Correlation plots between CD8+ T cell proportions in the placenta and cord blood and maternal viral load one week after ART initiation (visit 2, 8 weeks before delivery), four weeks after ART initiation (visit 3, 4 weeks before delivery) and thirty-six weeks' GA (visit 4, 2 weeks before delivery) in the decidua parietalis, basalis, villous tissue and cord blood. Statistical analysis was performed using the Spearman rank test and the grey shaded area represents the 95% confidence intervals.

Supplementary Figure 5: Memory differentiation of CD4+ T cells in the villous tissue and cord blood

Box plots (showing medians and interquartile ranges) of CD4+ Naïve, Early differentiated (ED), Late differentiated (LD) and Terminally differentiated (TD) T cells in the villous tissue (VT; upper panel) and cord

medRxiv preprint doi: https://doi.org/10.1101/2021.01.04.21249198; this version posted January 4, 2021. The copyright holder for this preprint (which was not certified by peer review) is the author/funder, who has granted medRxiv a license to display the preprint in perpetuity. It is made available under a CC-BY-ND 4.0 International license .

blood (CB; lower panel) from HIV-uninfected (MHIV neg) and infected mothers (MHIV pos) and HIV unexposed and uninfected (HUU) and HIV exposed uninfected (HEU) cord bloods. Tests of significance were performed using the Mann-Whitney *U* test.

Supplementary Figure 6: Memory differentiation of CD4 and CD8 T cells in the decidua parietalis and decidua basalis

Representative flow cytometry contour plots of Naïve, Early differentiated (ED), Late differentiated (LD) and Terminally differentiated (TD) CD4+ T cells (upper panel) and CD8+ T cells (lower panel) in the decidua parietalis and basalis.

Supplementary Figure 7: Memory phenotype of CD4 T cells in the Villous Tissue

Box plots (showing medians and interquartile ranges) of CD4+ and CD8+ Naïve, Early differentiated (ED), Late differentiated (LD) and Terminally differentiated (TD) T cells in the decidua parietalis and basalis from HIV-uninfected (MHIV neg) and infected mothers (MHIV pos). Tests of significance were performed using the Mann-Whitney *U* test.

medRxiv preprint doi: https://doi.org/10.1101/2021.01.04.21249198; this version posted January 4, 2021. The copyright holder for this preprint (which was not certified by peer review) is the author/funder, who has granted medRxiv a license to display the preprint in perpetuity. It is made available under a CC-BY-ND 4.0 International license .

References

1. Okoye AA, Picker LJ. CD4 + T-cell depletion in HIV infection: mechanisms of immunological failure. Immunol Rev [Internet]. 2013 Jul;254(1):54–64. Available from: http://doi.wiley.com/10.1111/imr.12066
2. Demers KR, Makedonas G, Buggert M, et al. Temporal Dynamics of CD8+ T Cell Effector Responses during Primary HIV Infection. Douek DC, editor. PLOS Pathog [Internet]. 2016 Aug 3;12(8):e1005805. Available from: http://dx.plos.org/10.1371/journal.ppat.1005805
3. Hileman CO, Funderburg NT. Inflammation, Immune Activation, and Antiretroviral Therapy in HIV. Curr HIV/AIDS Rep [Internet]. 2017;14(3):93–100. Available from: http://www.ncbi.nlm.nih.gov/pubmed/28434169
4. Okhai H, Vivancos-Gallego MJ, Hill T, Sabin CA. CD4+:CD8+ T Cell Ratio Normalization and the Development of AIDS Events in People with HIV Starting Antiretroviral Therapy. AIDS Res Hum Retroviruses [Internet]. 2020 Oct 1;36(10):808–16. Available from: https://www.liebertpub.com/doi/10.1089/aid.2020.0106
5. Cocker ATH, Shah NM, Raj I, et al. Pregnancy Gestation Impacts on HIV-1-Specific Granzyme B Response and Central Memory CD4 T Cells. Front Immunol [Internet]. 2020 Feb 11;11. Available from: https://www.frontiersin.org/article/10.3389/fimmu.2020.00153/full
6. Heffron R, Donnell D, Kiarie J, et al. A Prospective Study of the Effect of Pregnancy on CD4 Counts and Plasma HIV-1 RNA Concentrations of Antiretroviral-Naive HIV-1–Infected Women. JAIDS J Acquir Immune Defic Syndr [Internet]. 2014 Feb;65(2):231–6. Available from: http://journals.lww.com/00126334-201402010-00016
7. Kalk E, Schubert P, Bettinger JA, et al. Placental pathology in HIV infection at term: a comparison with HIV-uninfected women. Trop Med Int Health [Internet]. 2017;22(5):604–13. Available from: http://www.ncbi.nlm.nih.gov/pubmed/28214384
8. Mwanyumba F, Gaillard P, Inion I, et al. Placental Inflammation and Perinatal Transmission of HIV-1. JAIDS J Acquir Immune Defic Syndr [Internet]. 2002 Mar;29(3):262–9. Available from:

medRxiv preprint doi: https://doi.org/10.1101/2021.01.04.21249198; this version posted January 4, 2021. The copyright holder for this preprint (which was not certified by peer review) is the author/funder, who has granted medRxiv a license to display the preprint in perpetuity. It is made available under a CC-BY-ND 4.0 International license .

http://journals.lww.com/00126334-200203010-00006

9. Ono E, Santos AMN dos, Succi RC de M, et al. Imbalance of naive and memory T lymphocytes with sustained high cellular activation during the first year of life from uninfected children born to HIV-1-infected mothers on HAART. Brazilian J Med Biol Res [Internet]. 2008 Aug;41(8):700–8. Available from: http://www.scielo.br/scielo.php?script=sci_arttext&pid=S0100-879X2008000800011&lng=en&tlng=en

10. Clerici M, Saresella M, Colombo F, et al. T-lymphocyte maturation abnormalities in uninfected newborns and children with vertical exposure to HIV. Blood [Internet]. 2000 Dec 1;96(12):3866–71. Available from: http://www.ncbi.nlm.nih.gov/pubmed/11090071

11. Afran L, Garcia Knight M, Nduati E, Urban BC, Heyderman RS, Rowland-Jones SL. HIV-exposed uninfected children: a growing population with a vulnerable immune system? Clin Exp Immunol [Internet]. 2014 Apr;176(1):11–22. Available from: http://www.ncbi.nlm.nih.gov/pubmed/24325737

12. Slogrove AL, Powis KM, Johnson LF, Stover J, Mahy M. Estimates of the global population of children who are HIV-exposed and uninfected, 2000–18: a modelling study. Lancet Glob Heal [Internet]. 2020 Jan;8(1):e67–75. Available from: https://linkinghub.elsevier.com/retrieve/pii/S2214109X19304486

13. Williams PJ, Searle RF, Robson SC, Innes BA, Bulmer JN. Decidual leucocyte populations in early to late gestation normal human pregnancy. J Reprod Immunol [Internet]. 2009 Oct;82(1):24–31. Available from: https://linkinghub.elsevier.com/retrieve/pii/S0165037809004100

14. Nancy P, Erlebacher A. T cell behavior at the maternal-fetal interface. Int J Dev Biol [Internet]. 2014;58(2–4):189–98. Available from: http://www.ncbi.nlm.nih.gov/pubmed/25023685

15. Tilburgs T, Schonkeren D, Eikmans M, et al. Human Decidual Tissue Contains Differentiated CD8 + Effector-Memory T Cells with Unique Properties. J Immunol [Internet]. 2010 Oct

medRxiv preprint doi: https://doi.org/10.1101/2021.01.04.21249198; this version posted January 4, 2021. The copyright holder for this preprint (which was not certified by peer review) is the author/funder, who has granted medRxiv a license to display the preprint in perpetuity. It is made available under a CC-BY-ND 4.0 International license .

1;185(7):4470–7. Available from: http://www.jimmunol.org/lookup/doi/10.4049/jimmunol.0903597

16. Tilburgs T, Strominger JL. CD8+ effector T cells at the fetal-maternal interface, balancing fetal tolerance and antiviral immunity. Am J Reprod Immunol [Internet]. 2013 Apr;69(4):395–407. Available from: http://www.ncbi.nlm.nih.gov/pubmed/23432707

17. Mjösberg J, Berg G, Jenmalm MC, Ernerudh J. FOXP3+ regulatory T cells and T helper 1, T helper 2, and T helper 17 cells in human early pregnancy decidua. Biol Reprod [Internet]. 2010 Apr;82(4):698–705. Available from: http://www.ncbi.nlm.nih.gov/pubmed/20018909

18. Tilburgs T, Roelen DL, van der Mast BJ, et al. Evidence for a selective migration of fetus-specific CD4+CD25bright regulatory T cells from the peripheral blood to the decidua in human pregnancy. J Immunol [Internet]. 2008 Apr 15;180(8):5737–45. Available from: http://www.ncbi.nlm.nih.gov/pubmed/18390759

19. Redline RW. Villitis of unknown etiology: noninfectious chronic villitis in the placenta. Hum Pathol [Internet]. 2007 Oct;38(10):1439–46. Available from: http://www.ncbi.nlm.nih.gov/pubmed/17889674

20. Tamblyn JA, Lissauer DM, Powell R, Cox P, Kilby MD. The immunological basis of villitis of unknown etiology – Review. Placenta [Internet]. 2013 Oct;34(10):846–55. Available from: https://linkinghub.elsevier.com/retrieve/pii/S0143400413005894

21. Kintu K, Malaba TR, Nakibuka J, et al. Dolutegravir versus efavirenz in women starting HIV therapy in late pregnancy (DolPHIN-2): an open-label, randomised controlled trial. Lancet HIV [Internet]. 2020 May;7(5):e332–9. Available from: https://linkinghub.elsevier.com/retrieve/pii/S2352301820300503

22. Tilburgs T, Crespo ÂC, van der Zwan A, et al. Human HLA-G+ extravillous trophoblasts: Immune-activating cells that interact with decidual leukocytes. Proc Natl Acad Sci [Internet]. 2015 Jun 9;112(23):7219–24. Available from: http://www.pnas.org/lookup/doi/10.1073/pnas.1507977112

medRxiv preprint doi: https://doi.org/10.1101/2021.01.04.21249198; this version posted January 4, 2021. The copyright holder for this preprint (which was not certified by peer review) is the author/funder, who has granted medRxiv a license to display the preprint in perpetuity. It is made available under a CC-BY-ND 4.0 International license .

23. Khong TY, Mooney EE, Ariel I, et al. Sampling and Definitions of Placental Lesions: Amsterdam Placental Workshop Group Consensus Statement. Arch Pathol Lab Med [Internet]. 2016 Jul;140(7):698–713. Available from: http://www.archivesofpathology.org/doi/10.5858/arpa.2015-0225-CC

24. Kallapur S, Presicce P, Rueda C, Jobe A, Chougnet C. Fetal Immune Response to Chorioamnionitis. Semin Reprod Med [Internet]. 2014 Jan 3;32(01):056–67. Available from: http://www.thieme-connect.de/DOI/DOI?10.1055/s-0033-1361823

25. Kim CJ, Romero R, Chaemsaithong P, Chaiyasit N, Yoon BH, Kim YM. Acute chorioamnionitis and funisitis: definition, pathologic features, and clinical significance. Am J Obstet Gynecol [Internet]. 2015 Oct;213(4):S29–52. Available from: https://linkinghub.elsevier.com/retrieve/pii/S0002937815009102

26. Ernst LM. Maternal vascular malperfusion of the placental bed. APMIS [Internet]. 2018 Jul;126(7):551–60. Available from: http://doi.wiley.com/10.1111/apm.12833

27. R Core Team. R: A language and environment for statistical computing [Internet]. Vienna, Austria: R Foundation for Statistical Computing; 2020. Available from: https://www.r-project.org/

28. Enninga EAL, Raber P, Quinton RA, et al. Maternal T Cells in the Human Placental Villi Support an Allograft Response during Noninfectious Villitis. J Immunol [Internet]. 2020 Jun 1;204(11):2931–9. Available from: http://www.jimmunol.org/lookup/doi/10.4049/jimmunol.1901297

29. Ander SE, Diamond MS, Coyne CB. Immune responses at the maternal-fetal interface. Sci Immunol [Internet]. 2019 Jan 11;4(31):eaat6114. Available from: http://immunology.sciencemag.org/lookup/doi/10.1126/sciimmunol.aat6114

30. Huang Y, Zhu X-Y, Du M-R, Li D-J. Human trophoblasts recruited T lymphocytes and monocytes into decidua by secretion of chemokine CXCL16 and interaction with CXCR6 in the first-trimester pregnancy. J Immunol [Internet]. 2008 Feb 15;180(4):2367–75. Available from:

medRxiv preprint doi: https://doi.org/10.1101/2021.01.04.21249198; this version posted January 4, 2021. The copyright holder for this preprint (which was not certified by peer review) is the author/funder, who has granted medRxiv a license to display the preprint in perpetuity. It is made available under a CC-BY-ND 4.0 International license .

http://www.ncbi.nlm.nih.gov/pubmed/18250446

31. Tilburgs T, Strominger JL. CD8+ Effector T Cells at the Fetal-Maternal Interface, Balancing Fetal Tolerance and Antiviral Immunity. Am J Reprod Immunol [Internet]. 2013 Apr;69(4):395–407. Available from: http://doi.wiley.com/10.1111/aji.12094

32. White JT, Cross EW, Kedl RM. Antigen-inexperienced memory CD8+ T cells: where they come from and why we need them. Nat Rev Immunol [Internet]. 2017 Jun;17(6):391–400. Available from: http://www.ncbi.nlm.nih.gov/pubmed/28480897

33. Dawe GS, Tan XW, Xiao Z-C. Cell migration from baby to mother. Cell Adh Migr [Internet]. 2007;1(1):19–27. Available from: http://www.ncbi.nlm.nih.gov/pubmed/19262088

34. Acharya G, Sonesson S-E, Flo K, Räsänen J, Odibo A. Hemodynamic aspects of normal human feto-placental (umbilical) circulation. Acta Obstet Gynecol Scand [Internet]. 2016 Jun;95(6):672–82. Available from: http://doi.wiley.com/10.1111/aogs.12919

35. Nielsen SD, Jeppesen DL, Kolte L, et al. Impaired progenitor cell function in HIV-negative infants of HIV-positive mothers results in decreased thymic output and low CD4 counts. Blood [Internet]. 2001 Jul 15;98(2):398–404. Available from: http://www.ncbi.nlm.nih.gov/pubmed/11435309

36. Evans C, Jones CE, Prendergast AJ. HIV-exposed, uninfected infants: new global challenges in the era of paediatric HIV elimination. Lancet Infect Dis [Internet]. 2016 Jun;16(6):e92–107. Available from: https://linkinghub.elsevier.com/retrieve/pii/S1473309916000554

37. Kuhn L, Coutsoudis A, Moodley D, et al. T-helper cell responses to HIV envelope peptides in cord blood: protection against intrapartum and breast-feeding transmission. AIDS [Internet]. 2001 Jan 5;15(1):1–9. Available from: http://www.ncbi.nlm.nih.gov/pubmed/11192849

38. Holditch SJ, Eriksson EM, Tarosso LF, et al. Decay kinetics of HIV-1 specific T cell responses in vertically HIV-1 exposed seronegative infants. Front Immunol [Internet]. 2011;2:94. Available from: http://www.ncbi.nlm.nih.gov/pubmed/22566883

39. Huo Y, Patel K, Scott GB, et al. Lymphocyte subsets in HIV-exposed uninfected infants and

medRxiv preprint doi: https://doi.org/10.1101/2021.01.04.21249198; this version posted January 4, 2021. The copyright holder for this preprint (which was not certified by peer review) is the author/funder, who has granted medRxiv a license to display the preprint in perpetuity. It is made available under a CC-BY-ND 4.0 International license .

HIV-unexposed uninfected infants. J Allergy Clin Immunol [Internet]. 2017 Aug;140(2):605-608.e3. Available from: https://linkinghub.elsevier.com/retrieve/pii/S009167491730338X

40. Borges-Almeida E, Milanez HM, Vilela MMS, et al. The impact of maternal HIV infection on cord blood lymphocyte subsets and cytokine profile in exposed non-infected newborns. BMC Infect Dis [Internet]. 2011 Dec 3;11(1):38. Available from: http://bmcinfectdis.biomedcentral.com/articles/10.1186/1471-2334-11-38

41. Mansoor N, Abel B, Scriba TJ, et al. Significantly skewed memory CD8+ T cell subsets in HIV-1 infected infants during the first year of life. Clin Immunol [Internet]. 2009 Mar;130(3):280–9. Available from: http://www.ncbi.nlm.nih.gov/pubmed/18996749

42. Akbar AN, Fletcher JM. Memory T cell homeostasis and senescence during aging. Curr Opin Immunol [Internet]. 2005 Oct;17(5):480–5. Available from: http://www.ncbi.nlm.nih.gov/pubmed/16098721

43. Linton PJ, Dorshkind K. Age-related changes in lymphocyte development and function. Nat Immunol [Internet]. 2004 Feb 28;5(2):133–9. Available from: http://www.nature.com/articles/ni1033

44. Bonney EA, Pudney J, Anderson DJ, Hill JA. Gamma-Delta T Cells in Midgestation Human Placental Villi. Gynecol Obstet Invest [Internet]. 2000;50(3):153–7. Available from: https://www.karger.com/Article/FullText/10315

45. Pique-Regi R, Romero R, Tarca AL, et al. Single cell transcriptional signatures of the human placenta in term and preterm parturition. Elife [Internet]. 2019 Dec 12;8. Available from: https://elifesciences.org/articles/52004

46. Ikumi NM, Malaba TR, Komala P, et al. Associating antiretroviral therapy initiated before or during pregnancy with placenta pathology in HIV infected women. medRixv. 2020;

47. Weckman AM, Ngai M, Wright J, McDonald CR, Kain KC. The Impact of Infection in Pregnancy on Placental Vascular Development and Adverse Birth Outcomes. Front Microbiol [Internet]. 2019 Aug 22;10. Available from:

medRxiv preprint doi: https://doi.org/10.1101/2021.01.04.21249198; this version posted January 4, 2021. The copyright holder for this preprint (which was not certified by peer review) is the author/funder, who has granted medRxiv a license to display the preprint in perpetuity. It is made available under a CC-BY-ND 4.0 International license .

https://www.frontiersin.org/article/10.3389/fmicb.2019.01924/full

medRxiv preprint doi: https://doi.org/10.1101/2021.01.04.21249198; this version posted January 4, 2021. The copyright holder for this preprint (which was not certified by peer review) is the author/funder, who has granted medRxiv a license to display the preprint in perpetuity. It is made available under a CC-BY-ND 4.0 International license .

Table 1: Maternal and infant characteristics

	PWNLHIV N=9	PWLWH N=21	P-Value
Age, years			1.0
≤24	1 (11.1)	2 (9.5)	
25-29	5 (55.6)	11 (52.4)	
≥30	3 (33.3)	8 (38.1)	
Median (IQR)	29 (25 - 31)	29 (26 - 30)	
Median gestation at enrolment	30 (26 - 32)	28 (28 - 31)	0.6
Gravidity			***0.003***
1	5 (55.6)	1 (4.8)	
2	3 (33.3)	7 (33.3)	
≥3	1 (11.1)	13 (61.9)	
Median (IQR)	1 (1 - 2)	3 (2 - 3)	
Infant Characteristics			
Sex			1.0
Female	6 (66.7)	12 (57.1)	
Male	3 (33.3)	6 (28.6)	
Missing	*0 (0)*	*3 (14.3)*	
Median gestation at delivery (completed weeks)	40 (40)	39 (38 - 39)	***0.003***
Birthweight in grams, Median (IQR)	3420 (3420 - 4000)	3305 (3010 - 3570)	0.07

medRxiv preprint doi: https://doi.org/10.1101/2021.01.04.21249198; this version posted January 4, 2021. The copyright holder for this preprint (which was not certified by peer review) is the author/funder, who has granted medRxiv a license to display the preprint in perpetuity. It is made available under a CC-BY-ND 4.0 International license .

Table 2: Placental characteristics and pathology at delivery

	PWNLHIV N=9	PWLWH N=21	P-Value
Placental basal plate weight (g), median (IQR)	468 (426 - 533)	394 (343 – 469)	***0.02***
Placental weight (g)			***0.03***
Small (<10th percentile)	0 (0)	8 (38.1)	
Appropriate (10 - 90th percentile)	9 (100.0)	12 (57.1)	
Large (>90th percentile)	0 (0)	0 (0)	
Missing	*0 (0)*	*1 (4.8)*	
Fetal-Placenta weight ratio			***0.02***
Small (<10th percentile)	1 (11.1)	0 (0)	
Appropriate (10 - 90th percentile)	8 (88.9)	11 (52.4)	
Large (>90th percentile)	0 (0)	7 (33.3)	
Missing	*0 (0)*	*3 (14.9)*	
Placenta greatest diameter (mm), median (IQR)	180 (172 - 210)	180 (170 - 199)	0.6
Placenta thickness (mm), median (IQR)	20 (15 -20)	25 (16.5 - 27.5)	0.2
Cord insertion			0.7
Central	3 (33.3)	3 (33.3)	
Off centre	5 (55.6)	12 (57.1)	
Marginal	1 (11.1)	5 (23.8)	
Missing	*0 (0)*	*1 (4.76)*	
Meconium exposure			0.1
+	3 (33.3)	2 (9.5)	
-	6 (66.7)	19 (90.5)	
Chorioamnionitis			
Maternal Inflammatory Response			0.6
+	2 (22.2)	2 (9.5)	
-	7 (77.8)	19 (90.5)	
Fetal Inflammatory Response			0.6
+	2 (22.2)	3 (14.3)	
-	7 (77.8)	18 (85.7)	
Chronic Deciduitis			0.5
+	0 (0)	2 (9.5)	
-	9 (100)	19 (90.5)	
Maternal Vascular Malperfusion			0.09
+	0 (0)	6 (28.6)	
-	9 (100)	15 (71.4)	
Villitis of Unknown Etiology			1.0
+	0 (0)	0 (0)	
-	9 (100)	21 (100)	

medRxiv preprint doi: https://doi.org/10.1101/2021.01.04.21249198; this version posted January 4, 2021. The copyright holder for this preprint (which was not certified by peer review) is the author/funder, who has granted medRxiv a license to display the preprint in perpetuity. It is made available under a CC-BY-ND 4.0 International license .

Figure 1

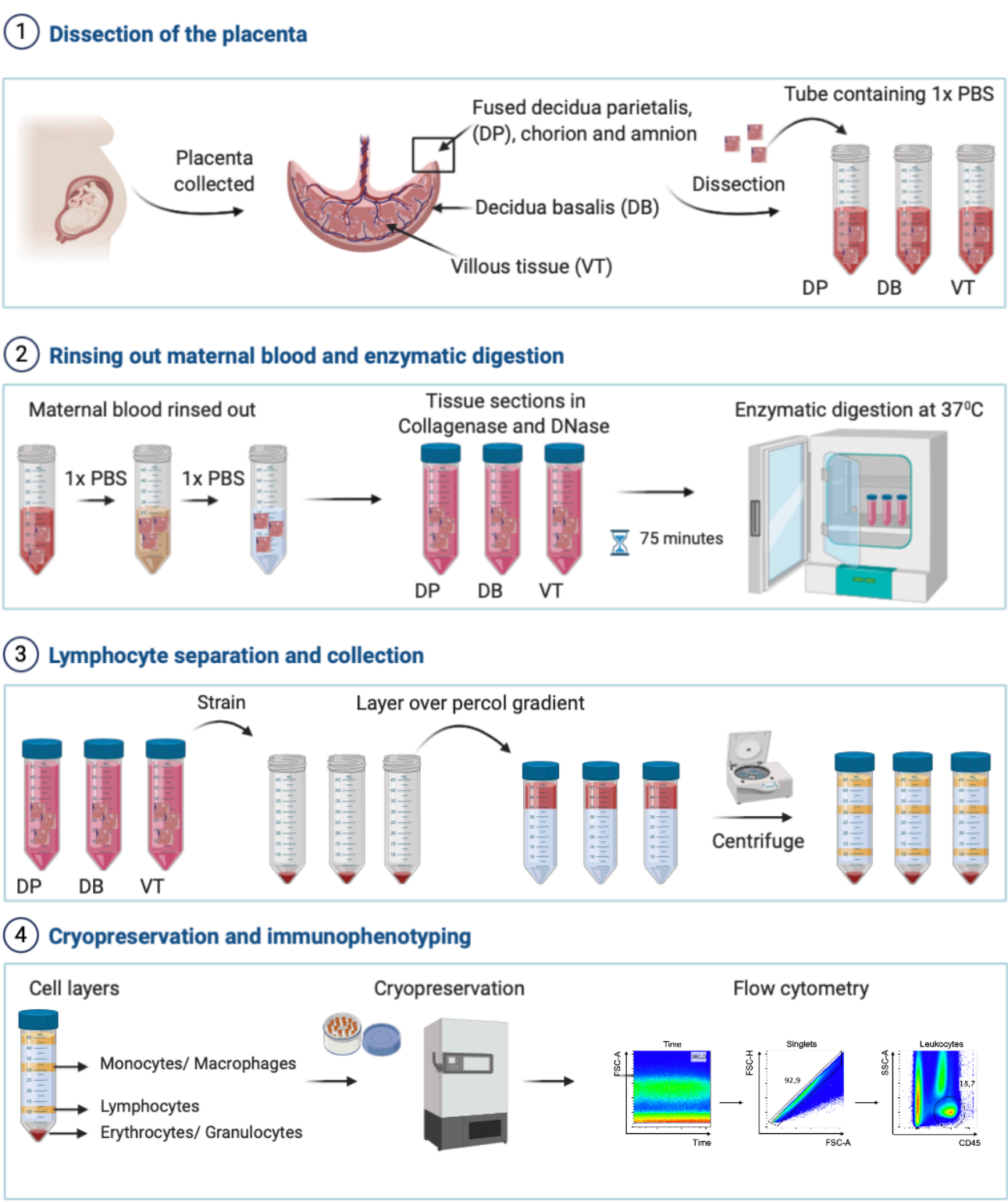

medRxiv preprint doi: https://doi.org/10.1101/2021.01.04.21249198; this version posted January 4, 2021. The copyright holder for this preprint (which was not certified by peer review) is the author/funder, who has granted medRxiv a license to display the preprint in perpetuity. It is made available under a CC-BY-ND 4.0 International license .

Figure 2

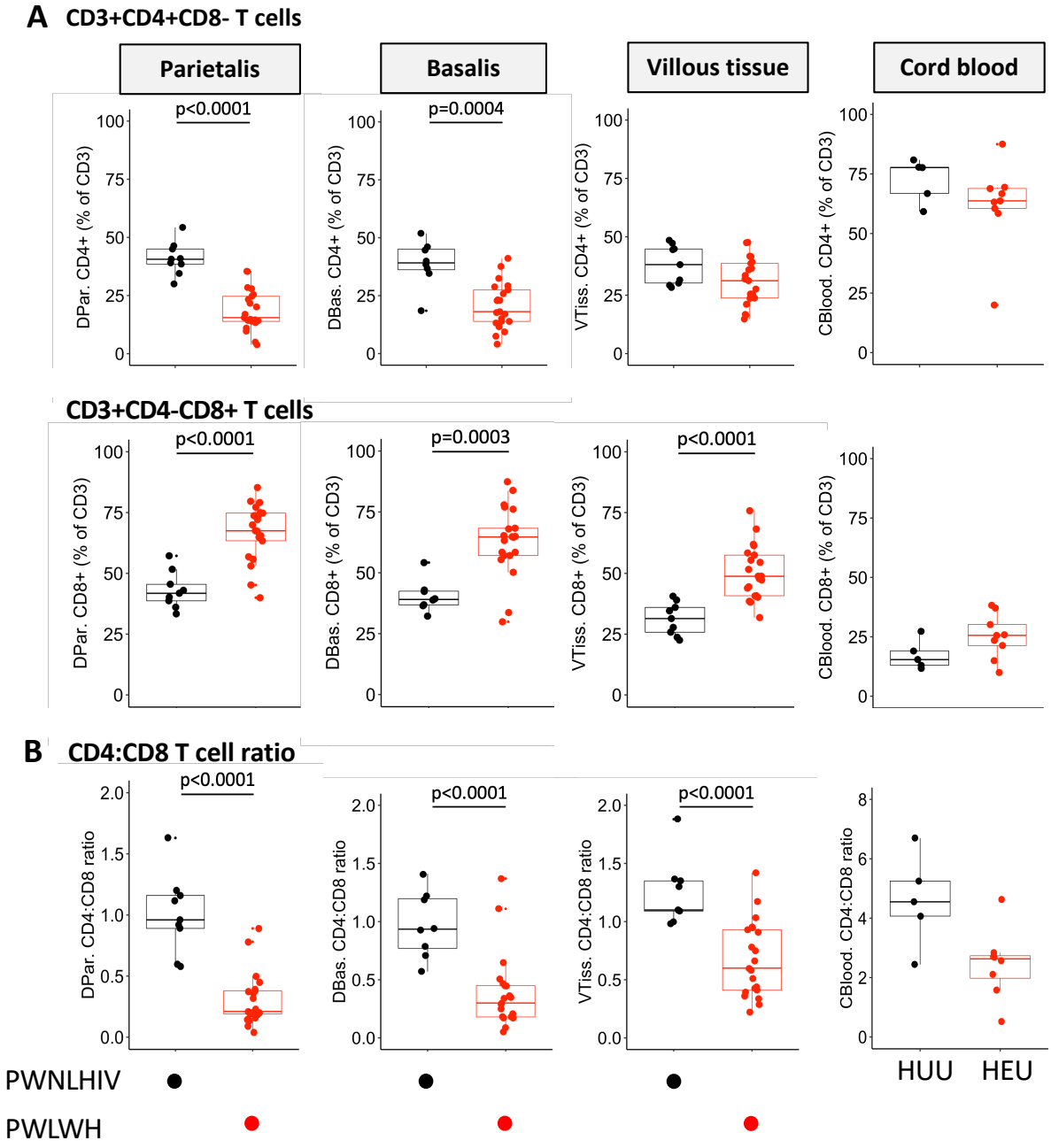

medRxiv preprint doi: https://doi.org/10.1101/2021.01.04.21249198; this version posted January 4, 2021. The copyright holder for this preprint (which was not certified by peer review) is the author/funder, who has granted medRxiv a license to display the preprint in perpetuity. It is made available under a CC-BY-ND 4.0 International license .

Figure 2

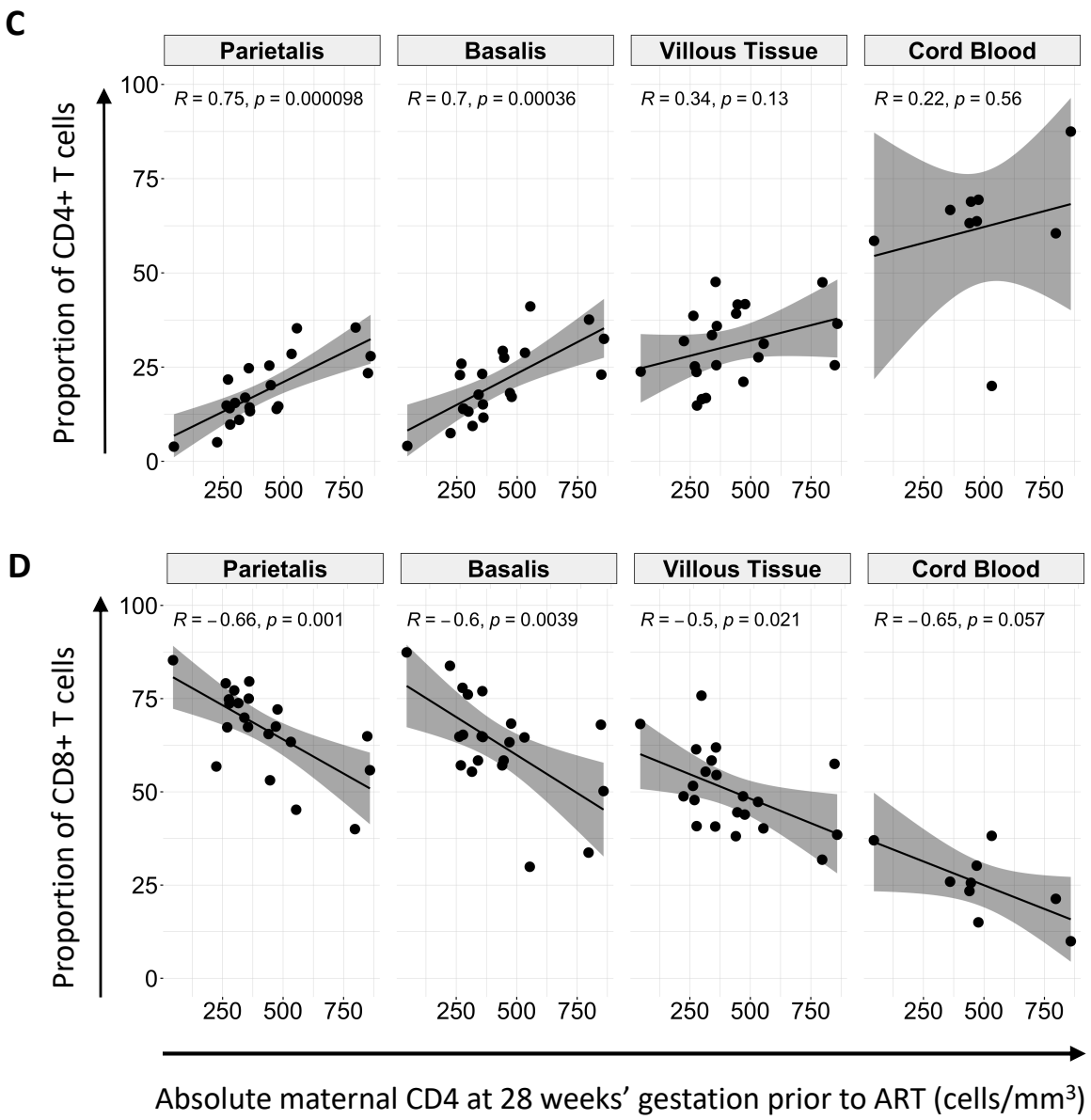

medRxiv preprint doi: https://doi.org/10.1101/2021.01.04.21249198; this version posted January 4, 2021. The copyright holder for this preprint (which was not certified by peer review) is the author/funder, who has granted medRxiv a license to display the preprint in perpetuity. It is made available under a CC-BY-ND 4.0 International license .

Figure 3

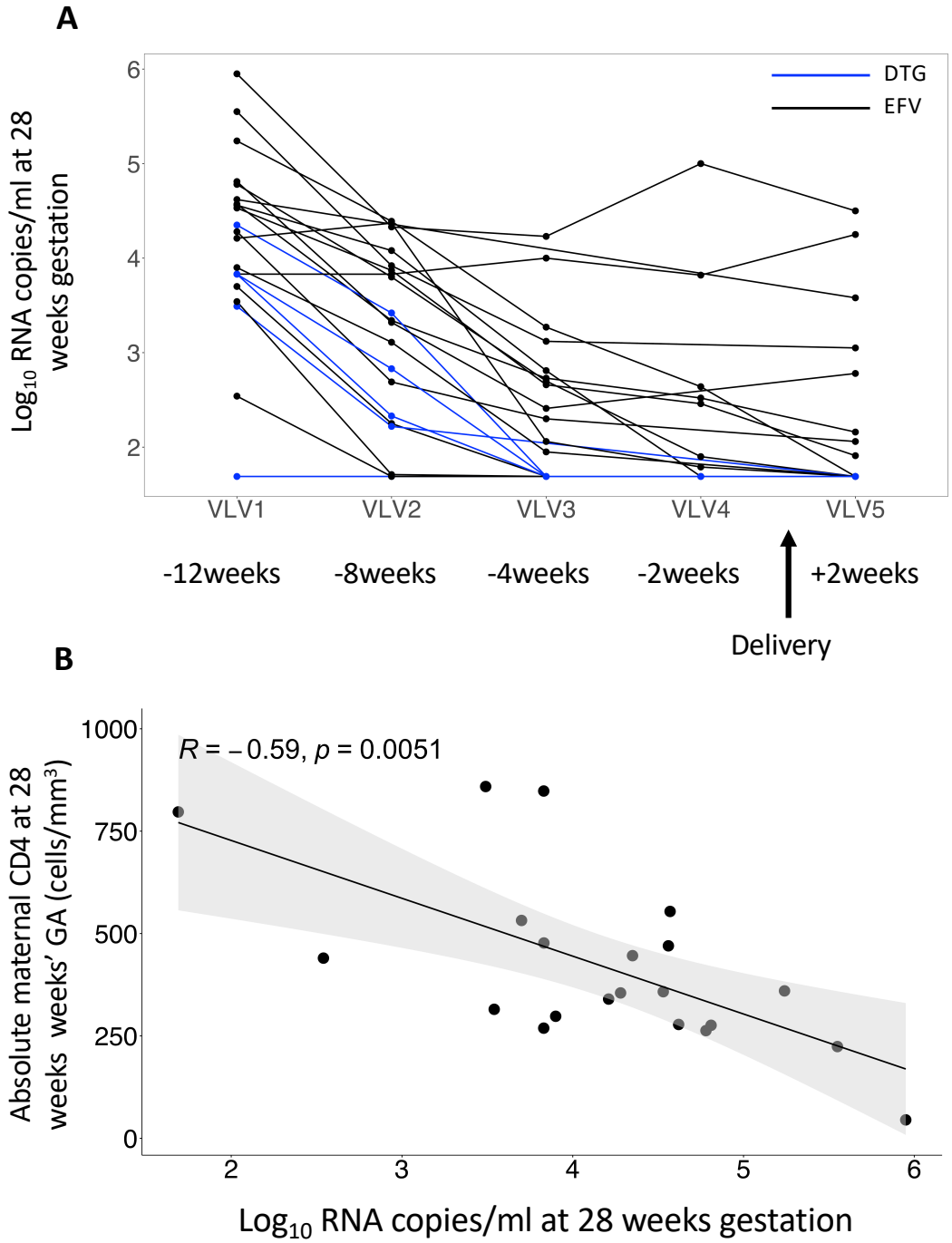

medRxiv preprint doi: https://doi.org/10.1101/2021.01.04.21249198; this version posted January 4, 2021. The copyright holder for this preprint (which was not certified by peer review) is the author/funder, who has granted medRxiv a license to display the preprint in perpetuity. It is made available under a CC-BY-ND 4.0 International license .

Figure 3

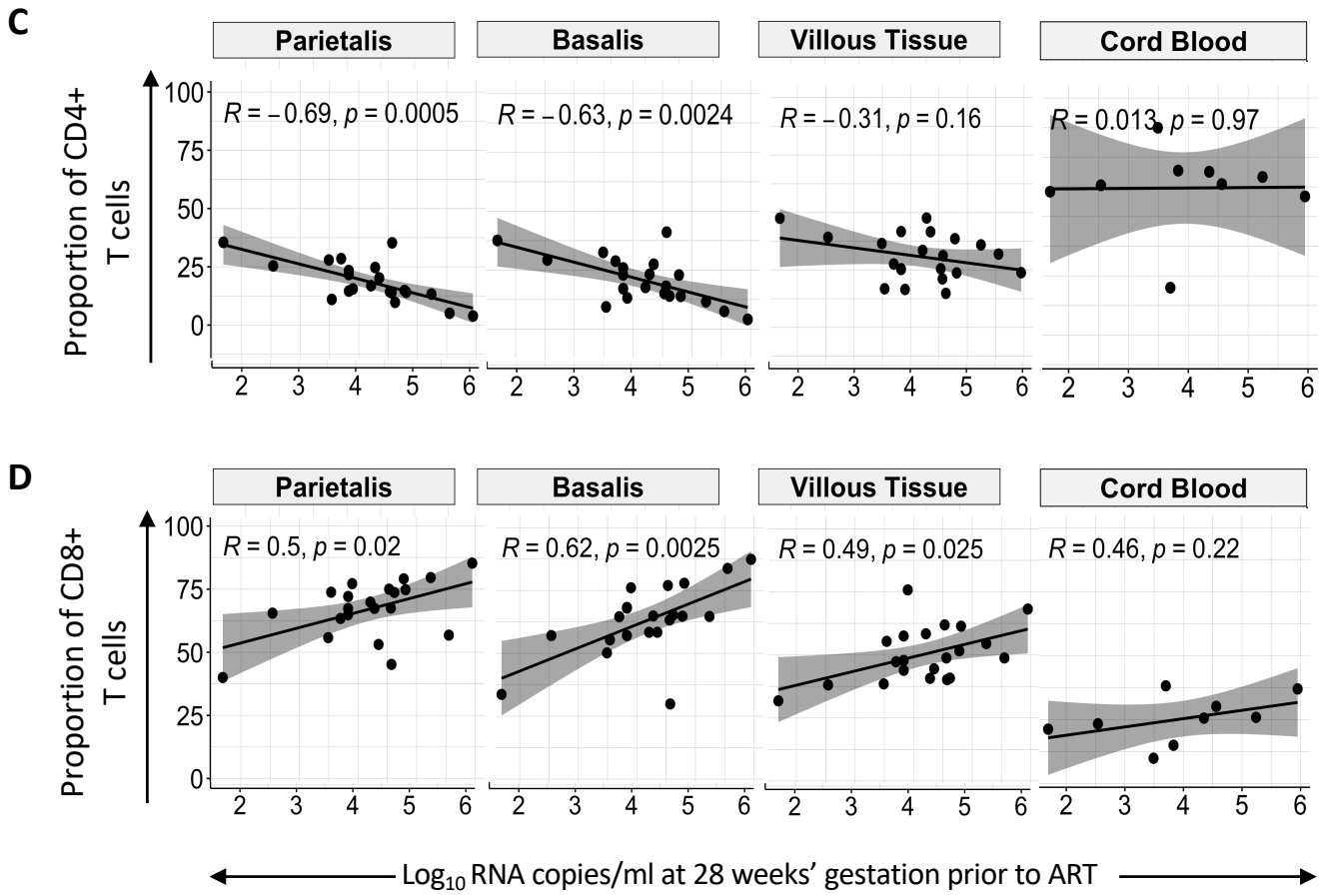

Figure 4

medRxiv preprint doi: https://doi.org/10.1101/2021.01.04.21249198; this version posted January 4, 2021. The copyright holder for this preprint (which was not certified by peer review) is the author/funder, who has granted medRxiv a license to display the preprint in perpetuity. It is made available under a CC-BY-ND 4.0 International license .

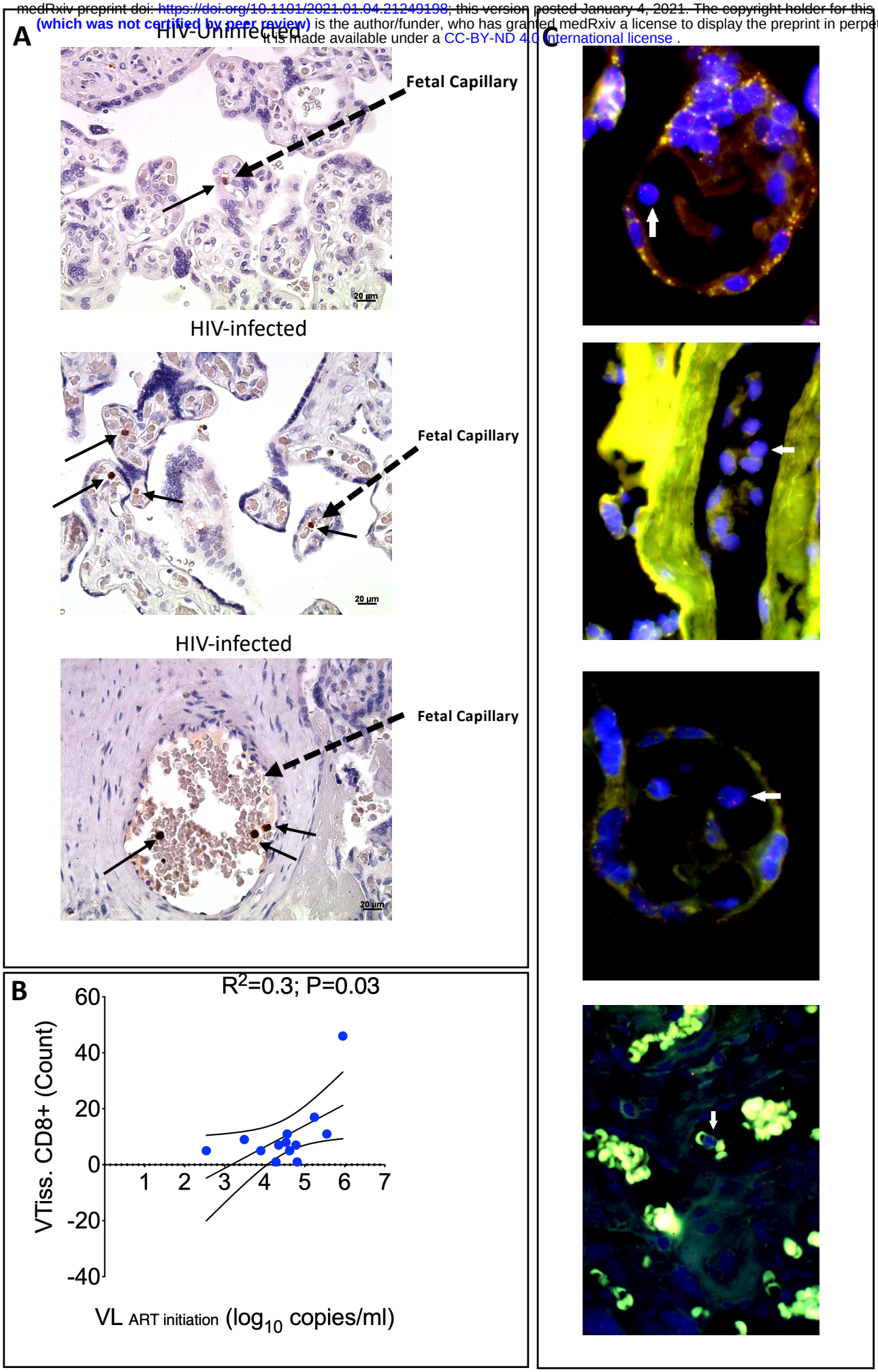

medRxiv preprint doi: https://doi.org/10.1101/2021.01.04.21249198; this version posted January 4, 2021. The copyright holder for this preprint (which was not certified by peer review) is the author/funder, who has granted medRxiv a license to display the preprint in perpetuity. It is made available under a CC-BY-ND 4.0 International license .
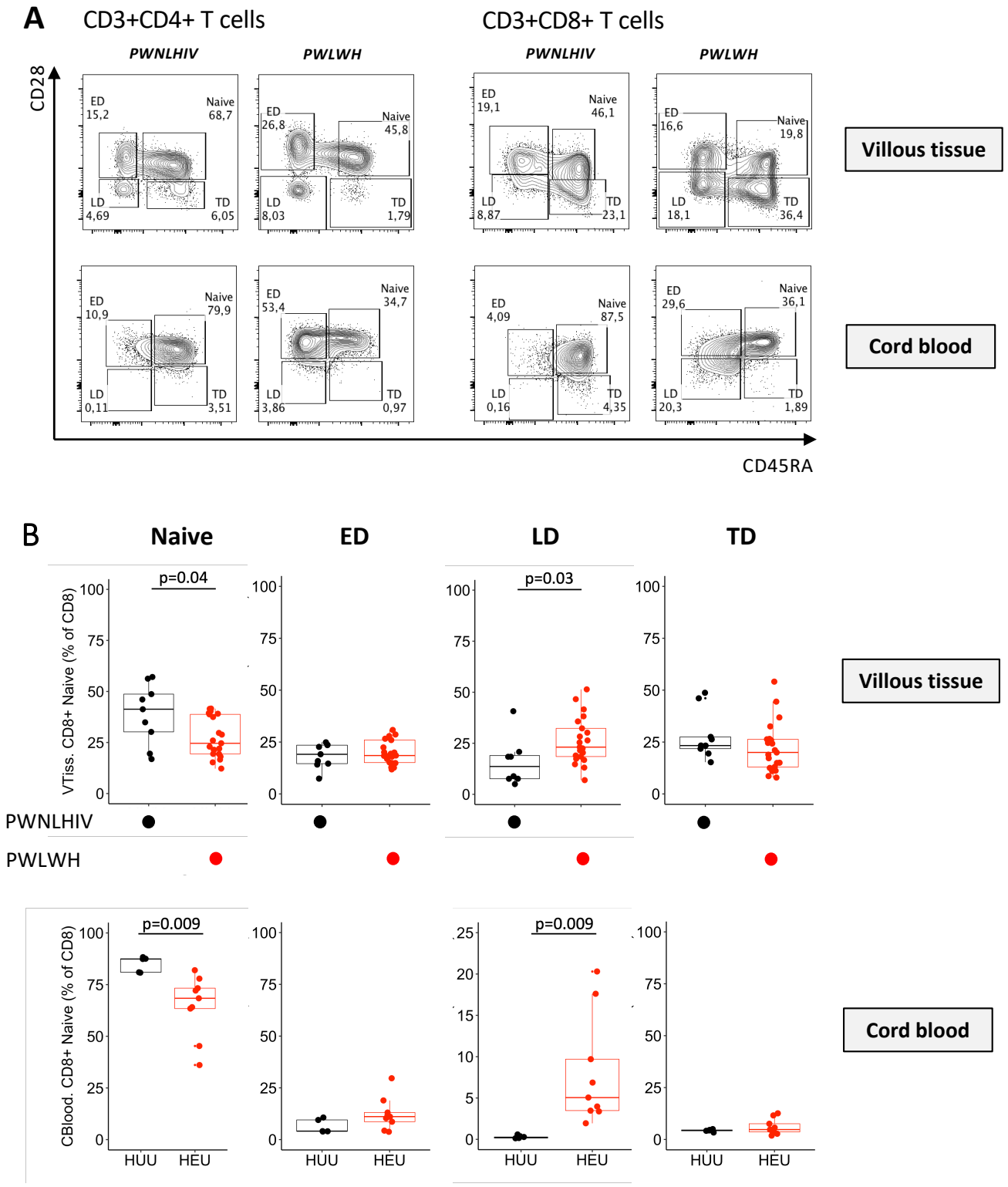
Figure 5