medRxiv preprint doi: https://doi.org/10.1101/2020.11.22.20235184; this version posted December 11, 2020. The copyright holder for this preprint (which was not certified by peer review) is the author/funder, who has granted medRxiv a license to display the preprint in perpetuity.
All rights reserved. No reuse allowed without permission.

Neurological Disorders associated with COVID-19 Hospital Admissions : Experience of a Single Tertiary Healthcare Centre

Permesh Singh Dhillon* [1,2,3], Robert Dineen[1,3] , Haley Morris[1] , Radu Tanasescu[1,4], Esmaeil Nikfekr[4], Jonathan Evans[4], Cris S. Constantinescu[1,4], Akram A. Hosseini*[1,4]

1. Division of Clinical Neuroscience, University of Nottingham
2. Interventional Neuroradiology, Nottingham University Hospitals NHS Trust
3. NIHR Nottingham Biomedical Research Centre
4. Department of Neurology, Queen's Medical Centre, Nottingham University Hospitals NHS Trust, United Kingdom.

*Correspondence to: Akram Hosseini ; akram.hosseini@nuh.nhs.uk Tel : 01159249924 Mailing address : Department of Neurology, D Floor, Queens Medical Centre, Derby Road, NG7 2UH, Nottingham, United Kingdom.

Keywords : COVID-19; encephalopathy; neurology; delirium; stroke

Disclosures : AAH is partly funded by the Medical Research Council (UK). No other disclosures or conflict of interest declared.

NOTE: This preprint reports new research that has not been certified by peer review and should not be used to guide clinical practice.

medRxiv preprint doi: https://doi.org/10.1101/2020.11.22.20235184; this version posted December 11, 2020. The copyright holder for this preprint (which was not certified by peer review) is the author/funder, who has granted medRxiv a license to display the preprint in perpetuity.
All rights reserved. No reuse allowed without permission.

Abstract

Background: Early reports have detailed a range of neurological symptoms in patients with the SARS-CoV-2 infection. However, there is a lack of detailed description and incidence of the neurological disorders amongst hospitalized COVID-19 patients. We describe a range of neurological disorders (other than non-specific neurological symptoms), including their clinical, radiological and laboratory findings, encountered in our cohort COVID-19 patients admitted to a large tertiary institution.

Methods: We reviewed our prospectively collated database of all adult Neurology referrals, Neurology and Stroke admissions and Neurological multi-disciplinary team meetings for all hospitalized patients with suspected or proven COVID-19 from 17 March 2020 to 31 August 2020.

Results: Twenty-nine of 1243 COVID-19 inpatients (2.3%) presented with COVID-19-related neurological disorders. The mean age was 68.9 +/- 13.5(SD) years, age range of 34-97 years, and there were 17 males. 22 patients had confirmed, 5 were probable and 2 had suspected COVID-19 infection according to the WHO case classification. Eight patients (27%) required critical care admission. Neurological symptoms at presentation included acute confusion and delirium, seizures, and new focal neurological deficits. Based on the pre-defined neurological phenotype, COVID-19 patients were grouped into four main categories. 16 patients had cerebrovascular events (13 with acute ischaemic stroke and 3 had haemorrhagic features), 7 patients were found to have inflammatory, non-inflammatory and autoimmune encephalopathy (including 2 with known Multiple Sclerosis), whilst movement and peripheral nervous system disorders were diagnosed in 3 patients each.

medRxiv preprint doi: https://doi.org/10.1101/2020.11.22.20235184; this version posted December 11, 2020. The copyright holder for this preprint (which was not certified by peer review) is the author/funder, who has granted medRxiv a license to display the preprint in perpetuity.
All rights reserved. No reuse allowed without permission.

Conclusion: Although the exact prevalence and aetiology remains unclear, non-sporadic new onset of neurological disorders, in addition to anosmia, occurs during the acute COVID-19-infection. Longitudinal follow-up of these patients is required to determine the long-term effects, treatment response and outcome of the SARS-CoV-2 infection.

Introduction

The coronavirus disease 2019 (COVID-19), a manifestation of the severe acute respiratory syndrome coronavirus-2 (SARS-CoV-2), was declared a pandemic by the World Health Organisation (WHO) on 11 March 2020 (1, 2). At present, the COVID-19 incidence in the United Kingdom (UK) is one of highest in the world with 705,428 cases and 43,579 deaths, accurate as of 17 October 2020 (3). Early reports from Wuhan, China detailed a range of neurological symptoms seen in patients with the SARS-CoV-2 infection (4). Recent isolated case reports have also described some of these manifestations, which include acute cerebrovascular disorders [CVD] (5-7), encephalopathy or encephalitis, acute demyelinating encephalomyelitis (ADEM), as well as peripheral neurological associations such as Guillain-Barre syndrome (GBS) (8, 9). Some of the proposed mechanisms underlying the increased prevalence of neurological disorders in COVID-19 include widespread systemic inflammatory and cytokine responses, diffuse intravascular coagulation and/or critical illness-related coagulopathy, direct neuronal injury, immune-mediated disorders and haemodynamic alterations (8-14).

medRxiv preprint doi: https://doi.org/10.1101/2020.11.22.20235184; this version posted December 11, 2020. The copyright holder for this preprint (which was not certified by peer review) is the author/funder, who has granted medRxiv a license to display the preprint in perpetuity.
All rights reserved. No reuse allowed without permission.

Many reports have detailed a range of presenting neurological symptoms in patients with the SARS-CoV-2 infection, including headache, delirium, seizures and altered mental status. However, there is often a lack of detailed description and incidence of the neurological disorders amongst hospitalized patients with COVID-19. Herein, we include neurological disorders instead of non-specific neurological symptoms such as headache, dizziness and anosmia. We describe a range of neurological disorders causing neurological deficits, including their clinical, radiological and laboratory findings, encountered in our cohort of patients with COVID-19 admitted to a large tertiary institution.

Methods

This study was registered with and approved by the East Midlands-Derby Research Ethics Committee (Ref:18/EM/0292) and individual patient consent was waived (15). We reviewed our prospectively collated database of all inpatient Neurology referrals, Neurology and Stroke admissions and Neurological multi-disciplinary team (MDT) meetings for all hospitalized patients with suspected or proven COVID-19 from 17 March 2020 (when national lockdown was declared in the UK) to 31 August 2020, at our institution. Each case, including the clinical, laboratory, and imaging findings, was discussed and a consensus of the underlying COVID-19 associated neurological syndrome was reached amongst the Neurology or Stroke physicians. Cases without definite neurological deficits, symptoms or signs, no clinical/radiological suspicion of COVID-19, or other more likely alternate diagnoses were excluded from our study cohort.

medRxiv preprint doi: https://doi.org/10.1101/2020.11.22.20235184; this version posted December 11, 2020. The copyright holder for this preprint (which was not certified by peer review) is the author/funder, who has granted medRxiv a license to display the preprint in perpetuity.
All rights reserved. No reuse allowed without permission.

Patients presenting with symptoms and/or signs indicative of COVID-19 and the associated positive real-time reverse transcriptase polymerase chain reaction (RT-PCR) status, were classified according to the WHO COVID-19 case definition (16), into confirmed, probable and suspected cases. Further case definitions for the association of COVID-19 with neurological disease were defined based our local MDT consensus and adapted from Ellul et. al's compilation panel of published information (14). These included cerebrovascular disease, encephalitis, myelitis or meningitis, and acute disseminated encephalomyelitis or other acute neuropathies associated with the SARS-CoV-2 infection. Some findings of four patients from our cohort were described in a recent correspondence by the respective clinicians/authors : (Patients 21 and 22) by Hosseini et al. (17) and (Patients 18 and 28) by Dhillon et al. (18).

Results

Our tertiary institution holds a capacity of approximately 1700 hospitals beds and provides services to over 2.5 million residents. During the study period, our institution reported 1243 COVID-19 admissions, of which 29 patients (2.3%) with neurological disorders associated with COVID-19 were identified in our study. The 29 patients included had a mean age of 68.9 +/- 13.5(SD) years, age range of 34-97 years, and there were 16 males. There were 27 Caucasian patients (92%), and only 2 were from the Black, Asian or Minor Ethnicity group (BAME ; 1 Black and 1 Asian). According to the WHO COVID-19 case classification, 22 patients were deemed to have confirmed COVID-19, 5 were probable and 2 had suspected COVID-19 infection. Eight patients (27%) required

medRxiv preprint doi: https://doi.org/10.1101/2020.11.22.20235184; this version posted December 11, 2020. The copyright holder for this preprint (which was not certified by peer review) is the author/funder, who has granted medRxiv a license to display the preprint in perpetuity.
All rights reserved. No reuse allowed without permission.

critical care admission, 6 of whom needed invasive ventilation. There was an array of neurological symptoms at presentation, namely, reduced consciousness, acute confusion, behavioural change and seizures, acute motor or sensory neurological deficits, and acute onset of movement disorders. The onset of neurological symptoms was between 9 days before to 15 days after the diagnosis or symptoms onset of COVID-19. Based on the pre-defined neurological phenotype, COVID-19 patients were grouped into four main categories : 16 patients diagnosed with a Cerebrovascular event (Acute ischaemic and Haemorrhagic), 7 patients with Inflammatory, non-inflammatory and autoimmune encephalopathy (including one case of transverse myelitis and two cases with known Multiple Sclerosis), 3 patients with Movement disorders, and 3 patients Peripheral nervous system syndromes.

Cerebrovascular Event :

Acute Ischaemic Stroke : (Patient 1, 2, 3, 4, 6, 10, 11, 12, 15, 16, 25, 29, 30; Table 1)

Thirteen of the 28 patients (46%) with an age range of 34-97 years, and 7 females, were diagnosed with acute ischaemic stroke, 5 of which were large vessel occlusions involving the middle cerebral artery (MCA). Only one patient presented with a posterior circulation stroke whilst two had multifocal infarcts. All but one patient had at least one known cardiovascular risk factor. Two patients were admitted in the intensive care unit for management of a malignant MCA syndrome. All patients underwent a computed tomography (CT) and/or an MRI Head at presentation (representative examples in Figure 1). Only two patients were given intravenous (IV) thrombolysis and two underwent

medRxiv preprint doi: https://doi.org/10.1101/2020.11.22.20235184; this version posted December 11, 2020. The copyright holder for this preprint (which was not certified by peer review) is the author/funder, who has granted medRxiv a license to display the preprint in perpetuity.
All rights reserved. No reuse allowed without permission.

mechanical thrombectomy (MT). Five patients had deceased within days of their diagnosis due to a combination of the underlying stroke and/or COVID-19 pneumonia.

Haemorrhagic : (Patient 18, 24, 28; Table 1)

Two COVID-19 male patients, Patient 18 and 28, (aged in their 40s and 60s respectively) had isolated intraventricular haemorrhage (IIVH) demonstrated on the CT Head, performed due to reduced conscious levels despite a sedation hold, during their prolonged critical care admission. MRI Head findings of Patient 18 showed cerebral microbleeds (CMB) in the splenium of the corpus callosum and subcortical white matter (Figure 2). Both patients were placed on continuous veno-venous haemofiltration (CVVH) but neither required extracorporeal membrane oxygenation (ECMO). The platelet count level, prothrombin and activated partial thromboplastin times were within the normal referenced ranges.

The third patient in her 50s (Patient 24) presented with recurrent seizures. The MRI Head also revealed CMB, without any other diagnostic features of cerebral amyloid angiopathy. No critical care admission was required and the prothrombin time was normal. Two patients (Patient 24 and 28) made an uneventful recovery. However, Patient 18 reported unilateral hearing impairment following hospital discharge.

Inflammatory, Non-inflammatory and Autoimmune Encephalopathy :

medRxiv preprint doi: https://doi.org/10.1101/2020.11.22.20235184; this version posted December 11, 2020. The copyright holder for this preprint (which was not certified by peer review) is the author/funder, who has granted medRxiv a license to display the preprint in perpetuity.
All rights reserved. No reuse allowed without permission.

Limbic encephalitis (Patient 21); Inflammatory encephalopathy (Patient 22); ADEM (Patient 27); Transverse myelitis (Patient 5); Non-inflammatory encephalopathy (Patient 9); (Table 2)

Three patients (age range between 46 to 79 years, three females) demonstrated a range of inflammatory encephalopathies. Patient 21 was diagnosed with limbic encephalitis, patient 22 with inflammatory encephalopathy, patient 27 with acute demyelinating encephalomyelitis (ADEM). Patient 9 was diagnosed with non-inflammatory encephalopathy and Patient 5 with transverse myelitis. Whilst four patients (9, 21, 22 and 27) presented with acute onset delirium and altered mental status, patients 21 and 22 also suffered from status epilepticus, cognitive impairment (scored 19 and 20 on the Montreal Cognitive Assessment respectively) and amnesia. Patient 5 presented with quadriparesis and altered sensation at the cervical level. Oligoclonal bands and mildly raised proteins were detected in the cerebrospinal fluid (CSF) of Patient 5, 22 and 27, whilst intrathecal SARS-CoV-2, paraneoplastic and autoimmune encephalitis antibodies (including NMDAR, CASPR2, LGI1, GABA and AMPA) were negative in all three patients. The anti-neuronal antibodies were also not detected in these patients. The MRI Head scans showed partial diffusion restriction in the limbic system of patient 21 (Figure 3) and persistent diffusion-weighted hyperintensities without overt restriction in patient 22, suggestive of cellular inflammation. Patient 27 had progressive patchy, asymmetric periventricular and subcortical white matter hyperintense foci with diffusion restriction in the cerebral hemispheres, right cerebellar hemisphere and brainstem, features in keeping with ADEM (Figure 4). The MRI Spine in Patient 5 showed extensive spinal cord abnormality involving the cervical, lower thoracic and conal regions in keeping with

medRxiv preprint doi: https://doi.org/10.1101/2020.11.22.20235184; this version posted December 11, 2020. The copyright holder for this preprint (which was not certified by peer review) is the author/funder, who has granted medRxiv a license to display the preprint in perpetuity.
All rights reserved. No reuse allowed without permission.

transverse myelitis. Small regions of diffusion restriction were also identified in the medulla and middle cerebellar peduncle. Patient 22 required a brief critical care admission for 4 days, Patient 5 and 27 was given a course of intravenous (IV) followed by oral corticosteroids. All five patients recovered from their acute respiratory illness sufficiently for hospital discharge. However, only Patient 22 made a full neurological recovery, whilst the remaining patients were identified as having persistent neurological disability at discharge.

Demyelination **:** (Patient 8, 14; Table 2)

Two male patients with known advanced multiple sclerosis (MS), (aged in their 50s and 60s respectively), presented with symptoms consistent with, and were diagnosed with COVID-19. Patient 8 presented with acute delirium whilst Patient 14 was hospitalized due to the MS relapse associated with worsening of his baseline MS-related limb weakness and dysarthria during the admission. The MRI Head performed showed progression of the inflammatory plaques since 2015 in Patient 14 but no acute changes were identified on the CT Head of Patient 8. None of them were admitted to the intensive care unit. Only Patient 14 survived with ongoing disability, whilst Patient 8 succumbed to septicaemia.

Movement Disorders : Myoclonus ± Opsoclonus (Patient 7, 19, 20; Table 3)

Movement Disorders were seen in three patients with COVID-19 (age range between 57 to 86 years, two males). Patients 7 suffered from mild rest myoclonus of the arm, Patient 20 suffered from generalized rest myoclonus and Patient 19 was diagnosed with opsoclonus-myoclonus syndrome during the admission. No other neurological symptoms were identified. The CT/MRI Head

medRxiv preprint doi: https://doi.org/10.1101/2020.11.22.20235184; this version posted December 11, 2020. The copyright holder for this preprint (which was not certified by peer review) is the author/funder, who has granted medRxiv a license to display the preprint in perpetuity.
All rights reserved. No reuse allowed without permission.

demonstrated no acute abnormality in all patients. There was elevated CSF protein in Patient 19 and 20, with nothing else of note in the CSF analysis (including no detectable intrathecal SARS-CoV-2) in both patients. Normal electroencephalography (EEG) readings were demonstrated in Patient 20. All patients were treated with benzodiazepines and two patients made a full recovery at the time of discharge from hospital while Patient 19 had residual symptoms. Only Patient 7 required critical care admission for pulmonary COVID-19 symptoms.

Peripheral Nervous System Disorders : 2 GBS (Patient 13, 23) and 1 Brachial Plexopathy (Patient 26); (Table 4)

Two COVID-19 patients (Patient 13 and 23 ; aged in their 50s and 60s respectively, two males) with ascending peripheral weakness were diagnosed with GBS. Patient 26 who presented with left upper limb weakness was diagnosed with brachial plexopathy. Elevated CSF protein was identified in Patients 13 and 23 in an otherwise normal CSF analysis, whilst nerve conduction studies confirmed features in keeping with segmental demyelinating peripheral neuropathy in Patient 13 and axonal neuropathy (motor and sensory) in Patient 23. Patient 13 was treated with IV immunoglobulin. Patients 23 and 26 required a short period of critical care admission and all patients have made a partial recovery. Patient 26 reported bilateral hearing loss following hospital discharge and has been referred for further investigation.

Discussion

medRxiv preprint doi: https://doi.org/10.1101/2020.11.22.20235184; this version posted December 11, 2020. The copyright holder for this preprint (which was not certified by peer review) is the author/funder, who has granted medRxiv a license to display the preprint in perpetuity.
All rights reserved. No reuse allowed without permission.

We report a variety of neurological disorders with a clinical impact in patients with COVID-19 infection admitted in a large tertiary institution during the 'first wave' of the COVID-19 pandemic in the UK. There have been isolated reports of various neurological disorders associated with previous outbreaks of the severe acute respiratory syndrome (SARS) and Middle East acute respiratory syndrome (MERS) (19, 20). Similarly, our cohort of cases demonstrates a wide range of COVID-19 related neurological disorders, ischaemic and haemorrhagic cerebrovascular events, inflammatory and non-inflammatory encephalopathy syndromes, transverse myelitis, movement disorders and Guillain-Barre syndrome. The cumulative incidence of disorders is in up to 2.3% of hospitalised patients with COVID-19, with 27% of them requiring critical care admission. The diagnosis of each of the neurological disorders was made in conjunction with a positive diagnosis of COVID-19, suggesting their association may not be fortuitous. Whilst recent case reports/series have described a range of neurological symptoms during the ongoing COVID-19 pandemic, there is often a lack of detailed clinical, radiological and laboratory findings of the neurological disorders amongst hospitalised patients with COVID-19, which reflect the challenge of studying the natural history of COVID-19 complications in this patient cohort.

Evidence from our cohort and recent studies have included non-specific initial presentations such as altered mental status or delirium, features commonly seen in the critically unwell with sepsis and hypoxaemia, as well as being potential early signs of dementia. The neurological disorders have been reported in patients who present solely with neurological signs and symptoms as well as

medRxiv preprint doi: https://doi.org/10.1101/2020.11.22.20235184; this version posted December 11, 2020. The copyright holder for this preprint (which was not certified by peer review) is the author/funder, who has granted medRxiv a license to display the preprint in perpetuity.
All rights reserved. No reuse allowed without permission.

those with established systemic or pulmonary illness related to COVID-19. These neurological features may precede or occur days after the onset of pulmonary symptoms. Hence, the variable and non-specific nature of the presentation and onset of the illness creates a diagnostic and therapeutic dilemma. Furthermore, the occasional delay of presentation and hospital admission during the first peak of the pandemic due to patients' fear, isolation or shielding, may have lead to an increase in severity of the infection and neurological disorders at the point of diagnosis. Interestingly, there was no increased incidence or severity of the COVID-19 infection or neurological disorders amongst the BAME group in our cohort. However, this could be due to the relatively small number of BAME communities in our geographical region.

There has been a reported increase in the incidence and severity of cerebrovascular disease associated with COVID-19, particularly in a younger cohort (6, 21). Our cohort demonstrated a high percentage of patients with acute ischaemic stroke and up to 38% of these had a large vessel occlusion. Some of the acute ischaemic cerebrovascular events with multifocal infarcts may be cardioembolic in nature, due to associated cardiovascular risk factors, but coagulopathy, vasculitis and viral endothelialitis have also been reported as potential causes of multi-vessel stroke in patients with COVID-19 (21, 22). The hyper-inflammatory syndrome or 'cytokine storm' strongly associated with severe COVID-19 infection could also contribute to the underlying aetiology (13).

Thrombotic microangiopathy and endothelial dysfunction, also evident in multiple organ systems related to COVID-19, may be contributory factors in

medRxiv preprint doi: https://doi.org/10.1101/2020.11.22.20235184; this version posted December 11, 2020. The copyright holder for this preprint (which was not certified by peer review) is the author/funder, who has granted medRxiv a license to display the preprint in perpetuity.
All rights reserved. No reuse allowed without permission.

sepsis/critical illness-related CMBs (22, 23). The SARS-CoV-2 has been shown to preferentially bind to the angiotensin converting enzyme (ACE)-2 receptors that can be found in the endothelial lining, leading to the breakdown of the blood-brain barrier (8). However, cerebral CMBs have similarly been reported in acute respiratory distress syndrome patients with a resemblance seen in CMB-related high altitude exposure, sharing a common underlying aetiology of hypoxaemia (24). This could likewise explain the findings in our cases with haemorrhagic neurological manifestations in COVID-19. Interestingly, both patients with isolated intraventricular haemorrhage had normal coagulation parameters, and the observed CMBs were atypical for hypertensive or amyloid angiopathy causes. Other variables that may influence the presence and/or extent of microhaemorrhage in patients with COVID-19 include therapeutic anticoagulation and raised cerebral venous pressure secondary to ventilator measures in optimising patient oxygenation in the critical care setting (18).

The neurotropic potential of COVID-19 via direct viral axonal injury has been alluded to following scarce reports of the SARS-CoV-2 being detected in the CSF of patients with meningo-encephalitis and in animal models (25, 26). Similarly, few case reports have demonstrated imaging features of direct neuronal injury of the olfactory pathway in COVID-19 patients presenting with anosmia, adding strength to this potential mechanism (27). Nonetheless, no detectable intrathecal coronavirus strain was identified in our patients who presented with encephalopathy.

Interestingly, two patients who required critical care admission reported new onset hearing loss following hospital discharge, despite no acute abnormality

medRxiv preprint doi: https://doi.org/10.1101/2020.11.22.20235184; this version posted December 11, 2020. The copyright holder for this preprint (which was not certified by peer review) is the author/funder, who has granted medRxiv a license to display the preprint in perpetuity.
All rights reserved. No reuse allowed without permission.

reported on the admission MRI Head. A recent case report also described a possible association between sensorineural hearing impairment and COVID-19 in the critical care setting (28). It is postulated that such an observation could be due to the underlying hyperinflammatory process and/or the neuro-invasive potential of the SARS-CoV-2 against the auditory nervous system. Hence, it will be important to consider screening patients with severe COVID-19 infection for hearing impairment during the hospital admission.

An immunological response secondary to the SARS-CoV-2, resulting in cerebral inflammation and oedema with clinical encephalopathic features may offer an alternative explanation for the incidence of inflammatory and auto-immune encephalopathy disorders (14, 29). Antibodies against neuronal synaptic proteins have been demonstrated in autoimmune encephalitis, and there have been increased numbers of antibodies reported against other coronavirus strains, suggesting a possible association between auto-immune or inflammatory encephalopathic disorders and the COVID-19 infection (30, 31). Furthermore, the presence of both intrathecal and serum oligoclonal bands in two patients with acute encephalitis and ADEM suggests that the immune-mediated response is not restricted to the intrathecal production of immunoglobulins. Post-infectious autoimmune disorder is also demonstrated in our case cohort of GBS, whereby the onset of neurological symptoms followed an initial period of illness related to COVID-19. Expected electrophysiological changes in keeping with demyelinating peripheral neuropathy was confirmed and the anticipated response to the IV immunoglobulin therapy was observed.

medRxiv preprint doi: https://doi.org/10.1101/2020.11.22.20235184; this version posted December 11, 2020. The copyright holder for this preprint (which was not certified by peer review) is the author/funder, who has granted medRxiv a license to display the preprint in perpetuity.
All rights reserved. No reuse allowed without permission.

Limitations of our study include its lack of pathological evidence to prove causality. Furthermore, we only included hospitalised patients with COVID-19 in our study, thereby potentially underestimating the true incidence of the neurological associations in patients in the community. There were also inherent drawbacks in the sensitivity and specificity of the available RT-PCR swab tests during the study period, which may have underestimated the incidence of COVID-19 in the patient population (32).

Although the exact mechanism and possible causality of the SARS-CoV-2 infection associated with each of the presented neurological disorders remains unclear, it is likely that shared pathophysiological mechanisms are responsible for the various neurological manifestations of COVID-19. Our study lends further support to the growing body of evidence, aiding better understanding of the neurological features and optimizing management strategies using an approach guided by the evolution of clinical, laboratory and imaging features. Longitudinal follow-up of these patients is required to determine the long term effects, treatment response and outcome of the SARS-CoV-2 infection.

References

1. Huang C, Wang Y, Li X, Ren L, Zhao J, Hu Y, et al. Clinical features of patients infected with 2019 novel coronavirus in Wuhan, China. Lancet. 2020;395(10223):497-506.
2. WHO Director-General's opening remarks at the media briefing on COVID-19 - 11 March 2020 2020 [Available from: https://www.who.int/dg/speeches/detail/who-director-general-s-opening-remarks-at-the-media-briefing-on-covid-19---11-march-2020.

medRxiv preprint doi: https://doi.org/10.1101/2020.11.22.20235184; this version posted December 11, 2020. The copyright holder for this preprint (which was not certified by peer review) is the author/funder, who has granted medRxiv a license to display the preprint in perpetuity.
All rights reserved. No reuse allowed without permission.

3. Coronavirus (COVID-19) in the UK https://coronavirus.data.gov.uk/ -category=regions&map=rate2020 [Available from: https://coronavirus.data.gov.uk/ - category=regions&map=rate.
4. Mao L, Jin H, Wang M, Hu Y, Chen S, He Q, et al. Neurologic Manifestations of Hospitalized Patients With Coronavirus Disease 2019 in Wuhan, China. JAMA Neurol. 2020;77(6):683-90.
5. Li Y, Wang M, Zhou Y, Chang J. Acute cerebrovascular disease following COVID-19: a single center, retrospective, observational study. Lancet: Pre-print; 3 March 2020.
6. Oxley TJ, Mocco J, Majidi S, Kellner CP, Shoirah H, Singh IP, et al. Large-Vessel Stroke as a Presenting Feature of Covid-19 in the Young. N Engl J Med. 2020;382(20):e60.
7. Goldberg MF, Goldberg MF, Cerejo R, Tayal AH. Cerebrovascular Disease in COVID-19. AJNR Am J Neuroradiol. 2020.
8. Paterson RW, Brown RL, Benjamin L, Nortley R, Wiethoff S, Bharucha T, et al. The emerging spectrum of COVID-19 neurology: clinical, radiological and laboratory findings. Brain. 2020;143(10):3104-20.
9. Varatharaj A, Thomas N, Ellul MA, Davies NWS, Pollak TA, Tenorio EL, et al. Neurological and neuropsychiatric complications of COVID-19 in 153 patients: a UK-wide surveillance study. Lancet Psychiatry. 2020;7(10):875-82.
10. Lillicrap D. Disseminated intravascular coagulation in patients with 2019-nCoV pneumonia. J Thromb Haemost. 2020;18(4):786-7.
11. Klok FA, Kruip M, van der Meer NJM, Arbous MS, Gommers D, Kant KM, et al. Incidence of thrombotic complications in critically ill ICU patients with COVID-19. Thromb Res. 2020.
12. Smeeth L, Thomas SL, Hall AJ, Hubbard R, Farrington P, Vallance P. Risk of myocardial infarction and stroke after acute infection or vaccination. N Engl J Med. 2004;351(25):2611-8.
13. Mehta P, McAuley DF, Brown M, Sanchez E, Tattersall RS, Manson JJ, et al. COVID-19: consider cytokine storm syndromes and immunosuppression. Lancet. 2020;395(10229):1033-4.
14. Ellul MA, Benjamin L, Singh B, Lant S, Michael BD, Easton A, et al. Neurological associations of COVID-19. Lancet Neurol. 2020;19(9):767-83.
15. COVID-19 : Notice under Regulation 3(4) of the Health Service (Control of Patient Information) Regulations 2002 29 July 2020 [Available from: https://www.gov.uk/government/publications/coronavirus-covid-19-notification-of-data-controllers-to-share-information/coronavirus-covid-19-notice-under-regulation-34-of-the-health-service-control-of-patient-information-regulations-2002-general.
16. World Health Organization (WHO) COVID-19 Case definition 7 August 2020 [Available from: https://www.who.int/publications/i/item/WHO-2019-nCoV-Surveillance_Case_Definition-2020.1.
17. Hosseini AA, Shetty AK, Sprigg N, Auer DP, Constantinescu CS. Delirium as a presenting feature in COVID-19: Neuroinvasive infection or autoimmune encephalopathy? Brain Behav Immun. 2020;88:68-70.
18. Dhillon PS, Chattopadhyay A, Dineen RA, Lenthall R. Hemorrhagic Neurologic Manifestations in COVID-19: An Isolated or Multifactorial Cause? AJNR Am J Neuroradiol. 2020.

medRxiv preprint doi: https://doi.org/10.1101/2020.11.22.20235184; this version posted December 11, 2020. The copyright holder for this preprint (which was not certified by peer review) is the author/funder, who has granted medRxiv a license to display the preprint in perpetuity.
All rights reserved. No reuse allowed without permission.

19. Tsai LK, Hsieh ST, Chang YC. Neurological manifestations in severe acute respiratory syndrome. Acta Neurol Taiwan. 2005;14(3):113-9.
20. Arabi YM, Balkhy HH, Hayden FG, Bouchama A, Luke T, Baillie JK, et al. Middle East Respiratory Syndrome. N Engl J Med. 2017;376(6):584-94.
21. Hernandez-Fernandez F, Sandoval Valencia H, Barbella-Aponte RA, Collado-Jimenez R, Ayo-Martin O, Barrena C, et al. Cerebrovascular disease in patients with COVID-19: neuroimaging, histological and clinical description. Brain. 2020;143(10):3089-103.
22. Nicholson P, Alshafai L, Krings T. Neuroimaging Findings in Patients with COVID-19. AJNR Am J Neuroradiol. 2020.
23. Kremer S, Lersy F, de Seze J, Ferre JC, Maamar A, Carsin-Nicol B, et al. Brain MRI Findings in Severe COVID-19: A Retrospective Observational Study. Radiology. 2020;297(2):E242-E51.
24. Fanou EM, Coutinho JM, Shannon P, Kiehl TR, Levi MM, Wilcox ME, et al. Critical Illness-Associated Cerebral Microbleeds. Stroke. 2017;48(4):1085-7.
25. Moriguchi T, Harii N, Goto J, Harada D, Sugawara H, Takamino J, et al. A first case of meningitis/encephalitis associated with SARS-Coronavirus-2. Int J Infect Dis. 2020;94:55-8.
26. Li YC, Bai WZ, Hashikawa T. The neuroinvasive potential of SARS-CoV2 may play a role in the respiratory failure of COVID-19 patients. J Med Virol. 2020;92(6):552-5.
27. Strauss SB, Lantos JE, Heier LA, Shatzkes DR, Phillips CD. Olfactory Bulb Signal Abnormality in Patients with COVID-19 Who Present with Neurologic Symptoms. AJNR Am J Neuroradiol. 2020;41(10):1882-7.
28. Koumpa FS, Forde CT, Manjaly JG. Sudden irreversible hearing loss post COVID-19. BMJ Case Rep. 2020;13(11).
29. Wu Y, Xu X, Chen Z, Duan J, Hashimoto K, Yang L, et al. Nervous system involvement after infection with COVID-19 and other coronaviruses. Brain Behav Immun. 2020;87:18-22.
30. Leypoldt F, Armangue T, Dalmau J. Autoimmune encephalopathies. Ann N Y Acad Sci. 2015;1338:94-114.
31. Severance EG, Dickerson FB, Viscidi RP, Bossis I, Stallings CR, Origoni AE, et al. Coronavirus immunoreactivity in individuals with a recent onset of psychotic symptoms. Schizophr Bull. 2011;37(1):101-7.
32. Jarrom D, Elston L, Washington J, Prettyjohns M, Cann K, Myles S, et al. Effectiveness of tests to detect the presence of SARS-CoV-2 virus, and antibodies to SARS-CoV-2, to inform COVID-19 diagnosis: a rapid systematic review. BMJ Evid Based Med. 2020.

Table 1. Sixteen patients with cerebrovascular event (13 Ischaemic and 3 Haemorrhagic). ICA = internal carotid artery. ACA = anterior cerebral artery. MCA = middle cerebral artery. PCA = posterior cerebral artery. NR = no result. CRP = C-Reactive protein. mRS = modified Rankin Score BAME = Black, Asian or Minority Ethnic ESR : Erythrocyte sedimentation rate M = male F = female

Patient	**1**	**2**	**3**	**4**	**6**
Age range, M/F, ethnicity, COVID-19 diagnosis	90s, F, White, Definite	90s,F, White, Definite	60s,F, White, Definite	80s, M, White, Probable	70s, M, White, Definite
Stroke type, thrombolysis/thrombectomy	Left ICA/MCA infarct. Thrombolysed	Left partial anterior circulation stroke (PACS)	Left ICA/MCA infarct ; Mechanical thrombectomy	Right MCA infarct. Thrombolysed	Right MCA infarct
Blood results at admission:	Haemoglobin g/l; 136 lymphocyte count 10 E9/L; 1.39 neutrophil count 10 E9/L; 3.41 platelet count 10 E9/L; 207 CRP mg/L; 6 D-dimer ug/l; NR Ferritin; NR Creatinine umol/L; 66 Prothrombin time S; 12.6	Haemoglobin g/l; 125 **lymphocyte count 10 E9/L; 0.98** neutrophil count 10 E9/L; 10.98 platelet count 10 E9/L; 421 **CRP mg/L; 276** **ESR mm/hr: 116** D-dimer ug/l; NR Ferritin; NR Creatinine umol/L; 59 Prothrombin time S; 11.1	Haemoglobin g/l; 131 lymphocyte count 10 E9/L; 2.91 neutrophil count 10 E9/L; 9.74 platelet count 10 E9/L; 400 **CRP mg/L; 62** **D-dimer ug/l; 3144** Ferritin; NR Creatinine umol/L; 64 Prothrombin time S; 11.6	Haemoglobin g/l; 140 **lymphocyte count 10 E9/L; 0.92** neutrophil count 10 E9/L; 5.53 platelet count 10 E9/L; 231 **CRP mg/L; 23** D-dimer ug/l; NR Ferritin; NR Creatinine umol/L; 89 Prothrombin time S; 11.9	Haemoglobin g/l; 106 **lymphocyte count 10 E9/L; 0.15** neutrophil count 10 E9/L; 2.81 **platelet count 10 E9/L; 38** **CRP mg/L; 298** D-dimer ug/l; NR Ferritin; NR Creatinine umol/L; 119 Prothrombin time S; 11.9
Brain Imaging	CT: Acute thrombus within the left ICA and MCA consistent with an acute infarct	CT: No acute abnormality. Severe small vessel disease.	CT: Left MCA territory infarct, with associated mass effect.	CT: Right MCA territory infarct.	CT: Massive acute right MCA territory infarct with mass effect and shift of midline structures
Outcome status	Deceased	Full recovery	Continued recovery in rehabilitation ; mRS 5	Full recovery	Deceased

10	**11**	**12**	**15**	**16**	**25**
80s, F, White, Definite	60s, F, White, Probable	70s, M, White, Suspected	60s, M, White, Definite	80s, M, White, Definite	70s, F, White, Definite
Right PCA Infarct	Left ACA infarct	Right MCA infarct	Right MCA infarct	Right MCA infarct	Left MCA infarct ; Mechanical Thrombectomy
Haemoglobin g/l; 113 **lymphocyte count 10 E9/L; 0.80** neutrophil count 10 E9/L; 6.82 platelet count 10 E9/L; 296 **CRP mg/L; 30** D-dimer ug/l; NR Ferritin ug/l; 126 Creatinine umol/L; 62 Prothrombin time S; NR	Haemoglobin g/l; 108 **lymphocyte count 10 E9/L; 0.76** neutrophil count 10 E9/L; 11.27 platelet count 10 E9/L; 196 **CRP mg/L; 74** D-dimer ug/l; NR Ferritin; NR Creatinine umol/L; 34 Prothrombin time S; 12.1	Haemoglobin g/l; 145 **lymphocyte count 10 E9/L; 0.49** neutrophil count 10 E9/L; 8.14 platelet count 10 E9/L; 332 **CRP mg/L; 132** D-dimer ug/l; NR Ferritin ug/l : 38 Creatinine umol/L; 81 Prothrombin time S; 13	Haemoglobin g/l; 117 **lymphocyte count 10 E9/L; 0.87** neutrophil count 10 E9/L; 10.72 platelet count 10 E9/L; 352 **CRP mg/L; 296** D-dimer ug/l; NR Ferritin; NR Creatinine umol/L; 84 Prothrombin time S; 10.9	Haemoglobin g/l; 136 **lymphocyte count 10 E9/L; 0.82** neutrophil count 10 E9/L; 7.87 platelet count 10 E9/L; 335 **CRP mg/L; 345** D-dimer ug/l; NR Ferritin; NR **Creatinine umol/L; 118** Prothrombin time S; 14.4	Haemoglobin g/l; 105 lymphocyte count 10 E9/L; 1.19 neutrophil count 10 E9/L; 8.49 platelet count 10 E9/L; 362 CRP mg/L; 8 D-dimer ug/l; NR Ferritin; NR **Creatinine umol/L; 106** Prothrombin time S; 12.6
MRI: Acute right PCA infarct	CT: Acute left ACA territory infarct	CT: Small cortical infarcts involving the right pre-central gyrus.	CT: Large acute right MCA territory infarct with mass effect	CT; Acute thrombus within the terminal segment ICA, M1/M2 segments of the right MCA and the proximal right A1 ACA segment	CT : Left MCA thrombus and infarct
Continued recovery in rehabilitation ; mRS 3	Full recovery	Continued recovery in rehabilitation ; mRS 3	Deceased	Deceased	Full recovery

28	**18**	**24**	**29**	**30**
60s, M, White, Definite	40s, M, White, Definite	50s, F, BAME, Suspected	30s, F, White, Definite	60s, M, Definite
Isolated intraventricular haemorrhage	Isolated Intraventricular haemorrhage	Cerebral microbleeds	Multifocal infarct	Multifocal infarcts
Haemoglobin g/l; 127 **lymphocyte count 10 E9/L; 0.17** neutrophil count 10 E9/L; 3.99 platelet count 10 E9/L; 228 **CRP mg/L; 158** **D-dimer ug/l; 8645** **Ferritin** ug/l**; 758** **Creatinine umol/L; 128** Prothrombin time S; 10.8	Haemoglobin g/l; 141 **lymphocyte count 10 E9/L; 0.52** neutrophil count 10 E9/L;3.51 platelet count 10 E9/L; 170 **CRP mg/L; 171** D-dimer ug/l; NR **Ferritin** ug/l**; 2132** Creatinine umol/L; 91 Prothrombin time S; 11.4	Haemoglobin g/l; 147 **lymphocyte count 10 E9/L; 0.86** neutrophil count 10 E9/L;6.02 platelet count 10 E9/L; 202 CRP mg/L; <5 D-dimer ug/l; NR Ferritin; NR Creatinine umol/L; 95 Prothrombin time S; 12.9	Haemoglobin g/l; 91 **lymphocyte count 10 E9/L; 0.94** neutrophil count 10 E9/L; 5.87 platelet count 10 E9/L; 455 **CRP mg/L; 263** **D-dimer ug/l; 6358** **Ferritin** ug/l**; 2986** **Creatinine umol/L; 286** Prothrombin time S; 11.4	Haemoglobin g/l; 132 **lymphocyte count 10 E9/L; 0.66** neutrophil count 10 E9/L; 9.35 platelet count 10 E9/L; 412 **CRP mg/L; 342** D-dimer ug/l; NR **Ferritin** ug/l**; 3712** Creatinine umol/L; 75 **Prothrombin time S; 13.1**
CT; Small amount of intraventricular haemorrhage in the left occipital horn of the lateral ventricle.	CT and MRI: Small volume intraventricular haemorrhage layering in the occipital horns bilaterally.	MRI; Micro-haemorrhagic changes in both cerebral hemispheres	CT and MRI: Multiple bilateral white matter and left cerebellar tiny foci of infarction	CT; Multifocal supra- and infra-tentorial infarcts.
Full recovery	Recovery with slight disability; mRS 1	Full recovery	Deceased	Deceased

Table 2 Six patients with inflammatory/non-inflammatory/autoimmune encephalopathy, including two patients with known multiple sclerosis (MS). One patient with transverse myelitis NR = no result. CRP = C-Reactive protein. mRS = modified Rankin Score BAME = Black, Asian or Minority Ethnic NMDA = N-methyl-D-aspartate, ESR : Erythrocyte sedimentation rate, PCR = polymerase chain reaction, LGI-1 = Leucine-rich glioma inactivated-1, CASPR = contactin-associate protein-like 2 MOG = myelin oligodendrocyte glycoprotein AQP4 = Aquaporin-4 M = male F = female

Patient	**27**	**21**	**22**	**5**	**9**	**8**	**14**
Age range, M/F, ethnicity, COVID-19 diagnosis	60s, F, White, Definite	70s, F, White, Definite	40s, M, BAME, Definite	60s, M, White, Probable	50s, F, White, Definite	60s, M, White, Definite	50s, M, White, Definite
Final neurological diagnosis	Acute demyelinating encephalomyelitis (ADEM)	Limbic encephalitis	Encephalopathy	Transverse myelitis	Non-inflammatory Encephalopathy	Relapse in a Secondary Progressive Advanced MS	Relapse in a known Multiple Sclerosis
Key neurological signs	Delirium, limb weakness, ataxia, visual hallucination,	Delirium, New onset generalised seizure/status epilepticus, dysphagia, cognitive impairment, amnesia	Delirium, New onset generalised seizures, disinhibition and cognitive impairment	Quadriparesis and sensory loss at cervical level	Headache, delirium, reduced conscious level, confusion and behavioural change	Delirium, reduced consciousness	Worsening limb weakness and dysarthria
Blood results at admission:	Haemoglobin g/l; 124 **lymphocyte count 10 E9/L; 0.55** neutrophil count 10 E9/L; 9.11 platelet count 10 E9/L; 336 **CRP mg/L; 262** ESR mm/hr : 10 D-dimer; NR Ferritin; NR Creatinine umol/L; 94 Prothrombin time S; 10	Haemoglobin g/l; 132 **lymphocyte count 10 E9/L; 0.39** neutrophil count 10 E9/L; 5.83 platelet count 10 E9/L; 313 **CRP mg/L; 31** **D-dimer ug/l; 3748** Ferritin; NR Creatinine umol/L; 65 Prothrombin time S; 13.7	Haemoglobin g/l; 147 **lymphocyte count 10 E9/L; 0.89** neutrophil count 10 E9/L; 3.6 platelet count 10 E9/L; 133 **CRP mg/L; 149** **ESR mm/hr : 90** **D-dimer ug/l; 1659** **Ferritin; 1328** Creatinine umol/L; 88 Prothrombin time S; 11.9	Haemoglobin g/l; 120 lymphocyte count 10 E9/L; 1.1 neutrophil count 10 E9/L; 8.9 platelet count 10 E9/L; 407 **CRP mg/L; 24** D-dimer ug/l; NR Ferritin; NR Creatinine umol/L; 53 Prothrombin time S; NT	Haemoglobin g/l; 132 lymphocyte count 10 E9/L; 1 neutrophil count 10 E9/L; 9.1 platelet count 10 E9/L; 203 **CRP mg/L; 47** D-dimer ug/l; NR Ferritin; NR Creatinine umol/L; 67 Prothrombin time S; NR	Haemoglobin g/l; 147 **lymphocyte count 10 E9/L; 0.46** neutrophil count 10 E9/L; 6.4 platelet count 10 E9/L; 154 **CRP mg/L; 168** **D-dimer ug/l; 3748** Ferritin; NR Creatinine umol/L; 69 Prothrombin time S; 10.4	Haemoglobin g/l; 132 **lymphocyte count 10 E9/L; 0.76** neutrophil count 10 E9/L; 3.67 platelet count 10 E9/L; 153 **CRP mg/L; 62** **D-dimer ug/l; 5422** Ferritin ug/l; 381 Creatinine umol/L; 64 Prothrombin time S; 11.2

Brain Imaging	MRI; Multiple patchy , asymmetric periventricular and subcortical white matter lesions in bilateral cerebral hemispheres, midbrain, dorsal pons, right middle cerebellar peduncle, medulla and right cerebellar hemisphere. Mixed diffusivity exhibited. Radiological progression on subsequent imaging during hospital admission	MRI; Lesions in the limbic system, predominantly in the left amygdala and hippocampus with partial restricted diffusion.	MRI; White matter lesions in the left anterior limbic structures with foci of increased diffusivity suggesting cellular inflammation.	MRI; Restricted diffusion in the inferior medulla with enhancement. Small area of restricted diffusion in left middle cerebellar peduncle . MRI spine; Extensive spinal cord abnormality predominantly involving the cervical and lower thoracic regions including the conus in keeping with transverse myelitis	MRI; No acute abnormality. Marked parenchymal atrophy with medial bitemporal predominance.	CT: No acute intracranial finding.	MRI : Progression of inflammatory plaques since 2015
CSF examination	White cell count; 8per µl or mm3, lymphocyte; 8, red cells; 1, **protein; 45.1mg/dl,** glucose; 4.1, Paired blood glucose; 5.6 mmol/L, oligoclonal bands; present. CSF NMDA negative, Viral PCR negative for SARS-CoV-2/enterovirus/HSV, CASPR2 Negative, LGI-1 negative; Glycine receptor negative ; anti-MOG and AQP4 negative	Red cells; 9, white cells none; protein; 340mg/dl, glucose; 4.1, Paired blood glucose; 5.4mmol/L. ; CSF NMDA negative, Viral PCR negative for SARS-CoV-2/enterovirus/HSV, CASPR2 Negative, LGI-1 negative,; Glycine receptor negative ; Oligoclonal bands negative	Red cells; 25, **protein; 98.7mg/dl**, glucose; 4.5, Paired blood glucose; 5.8 mmol/L. NMDA negative, Viral PCR negative for SARS-CoV-2/enterovirus/HSV, CASPR2 Negative, LGI-1 negative,; Glycine receptor negative	White cell; 1, red cells; 0, **protein; 51.4mg/dl**, glucose; 3.1mmol/L. oligoclonal bands; present (same as serum)	Not performed (known early-onset advanced Alzheimer's Dementia with further cognitive decline)	Not performed	Not performed
Neurological treatments; recovery	Corticosteroids; IV methyprednisolone	Benzodiazepine, Levetiracetam IV & maintenance;	Intubation and sedation for status epilepticus, Empirical aciclovir, antibiotics until CSF results available. IV valproate & maintenance	IV methylprednisolone	Supportive	Supportive and antibiotics (due to advanced disorder, osteomyelitis and pressure sores)	Glatiramer acetate injections 3 times/weekly
Outcome status	Recovery with slight disability; mRS 1	Partial recovery with mild neurological deficits (mRS 1)	Full recovery	Partial recovery with neurological deficits ; Moderate disability mRS 4	Partial recovery with neurological deficits ; Severe disability mRS 5	Deceased	Partial recovery with moderate disability; mRS 3

Table 3 Three patients with movement disorders. NR = no result. CRP = C-Reactive protein. mRS = modified Rankin Score NMDA = N-methyl-D-aspartate, ESR : Erythrocyte sedimentation rate, PCR = polymerase chain reaction, LGI-1 = Leucine-rich glioma inactivated-1, CASPR = contactin-associated protein-like 2 M = male F = female

Patient	**7**	**19**	**20**
Age range, M/F, ethnicity, COVID-19 diagnosis	50s, M, White, Definite	80s, F, White, Definite	80s, M, White, Probable
Final neurological diagnosis	Myoclonus	Opsoclonus myoclonus	Generalised rest myoclonus affecting lower face and whole body.
Blood results at admission:	Haemoglobin g/l; 104 **lymphocyte count 10 E9/L; 0.56** neutrophil count 10 E9/L; 3.22 platelet count 10 E9/L; 223 **CRP;mg/L 409** **D-dimer; 17390** **Ferritin; 916** Creatinine ml/min; 84 Prothrombin time: 12.5	Haemoglobin g/l; 109 **lymphocyte count 10 E9/L; 0.86** neutrophil count 10 E9/L; 10.2 platelet count 10 E9/L; 271 CRP mg/L; 5 D-dimer; NR Ferritin; NR Creatinine ml/min; 80 Prothrombin time; NR	Haemoglobin g/l; 97 **lymphocyte count 10 E9/L; 0.76** neutrophil count 10 E9/L; 4.51 platelet count 10 E9/L; 302 **CRP mg/L; 35** **ESR mm/hr : 105** D-dimer; NR Ferritin; NR Creatinine umol/L; 139 Prothrombin time; NR
Brain Imaging	CT : No acute abnormality.	MRI : No acute abnormality	MRI: No acute abnormality Electroencephalography : Normal
CSF examination	Not performed	Yes; red and white cells negative; protein; 46.8 mg/dl, glucose; 3.9, Paired blood glucose; NR,mmol/L ; CSF NMDA negative, Viral PCR negative for SARS-CoV-2/enterovirus/HSV, CASPR2 Negative, LGI-1 negative, Glycine receptor negative	Yes; red cells 265,white cells : none ; **protein; 166.7 mg/dl**, glucose; 3.6, Paired blood glucose; NR, Viral PCR negative for SARS-CoV-2/enterovirus/HSV ; CASPR2 Negative, LGI-1 negative, Glycine receptor negative ; Oligoclonal bands present in serum and CSF
Neurological treatments; recovery	Diazepam -	Levetiracetam and clonazepam	Clonazepam
Outcome status	Full recovery	Partial recovery with neurological deficits ; Moderate disability mRS 3	Full recovery

Table 4 Three patients with Peripheral nervous system disorders. GBS = Guillain-Barre syndrome NR = no result. CRP = C-Reactive protein. mRS = modified Rankin Score NMDA = N-methyl-D-aspartate, PCR = polymerase chain reaction, LGI-1 = Leucine-rich glioma inactivated-1, CASPR = contactin-associated protein-like 2 M = male F = female

Patient	**13**	**23**	**26**
Age range, M/F, ethnicity, COVID-19 diagnosis	60s, M, White, Definite	50s, F, White, Probable	50s, M, White, Definite
Final neurological diagnosis	GBS	GBS	Brachial plexopathy
Blood results at admission:	Haemoglobin g/l; 133 **lymphocyte count 10 E9/L; 0.93** neutrophil count 10 E9/L; 3.81 platelet count 10 E9/L; 242 **CRP mg/L; 112** D-dimer ug/l; NR Ferritin ug/l; 295 Creatinine umol/L; 58 Prothrombin time S; NR	Haemoglobin g/l; 85 **lymphocyte count 10 E9/L; 0.48** neutrophil count 10 E9/L; 5.19 platelet count 10 E9/L; 178 **CRP mg/L; 16** D-dimer ug/l; NR Ferritin ug/l; 340 **Creatinine umol/L; 140** Prothrombin time S; 11.4	Haemoglobin g/l; 101 lymphocyte count 10 E9/L; 1.24 neutrophil count 10 E9/L; 16.36 platelet count 10 E9/L; 224 **CRP mg/L; 351** **D-dimer ug/l; 9251** **Ferritin ug/l; 800** Creatinine umol/L; 62 Prothrombin time S; 11.5
Brain Imaging	Not performed	MRI Brain and Spine : No acute abnormality Electroencephalography : Normal	CT: No acute abnormality
Nerve conduction study	Yes; Segmental demyelinating peripheral neuropathy	Yes : Severe sensory and motor axonal neuropathy	Not performed
CSF examination	Red cells: 1770, white cells : none ; **protein; 155.6 mg/dl**, glucose; 4.2, Paired blood glucose; 6.6mmol/L ; Viral PCR negative for enterovirus/HSV	Red cells 8; White cells : none, **protein; 340.1 mg/dl**, glucose; 4.2, Paired blood glucose; 6.6 mmol/L ; NMDA negative, Viral PCR negative for enterovirus/HSV, CASPR2 Negative, LGI-1 negative, Oligoclonal bands negative.	Not performed
Neurological treatments; recovery	Intravenous Immunoglobulin	IV Methylprednisolone, Levetiracetam & Sodium Valproate (seizures)	No specific treatment administered (neurological disorder identified after ventilation support in critical care)
Outcome status	Recovery with slight disability; mRS 1	Partial recovery with neurological deficits ; Moderate disability mRS 4	Partial recovery with slight disability; mRS 2

medRxiv preprint doi: https://doi.org/10.1101/2020.11.22.20235184; this version posted December 11, 2020. The copyright holder for this preprint (which was not certified by peer review) is the author/funder, who has granted medRxiv a license to display the preprint in perpetuity.
All rights reserved. No reuse allowed without permission.

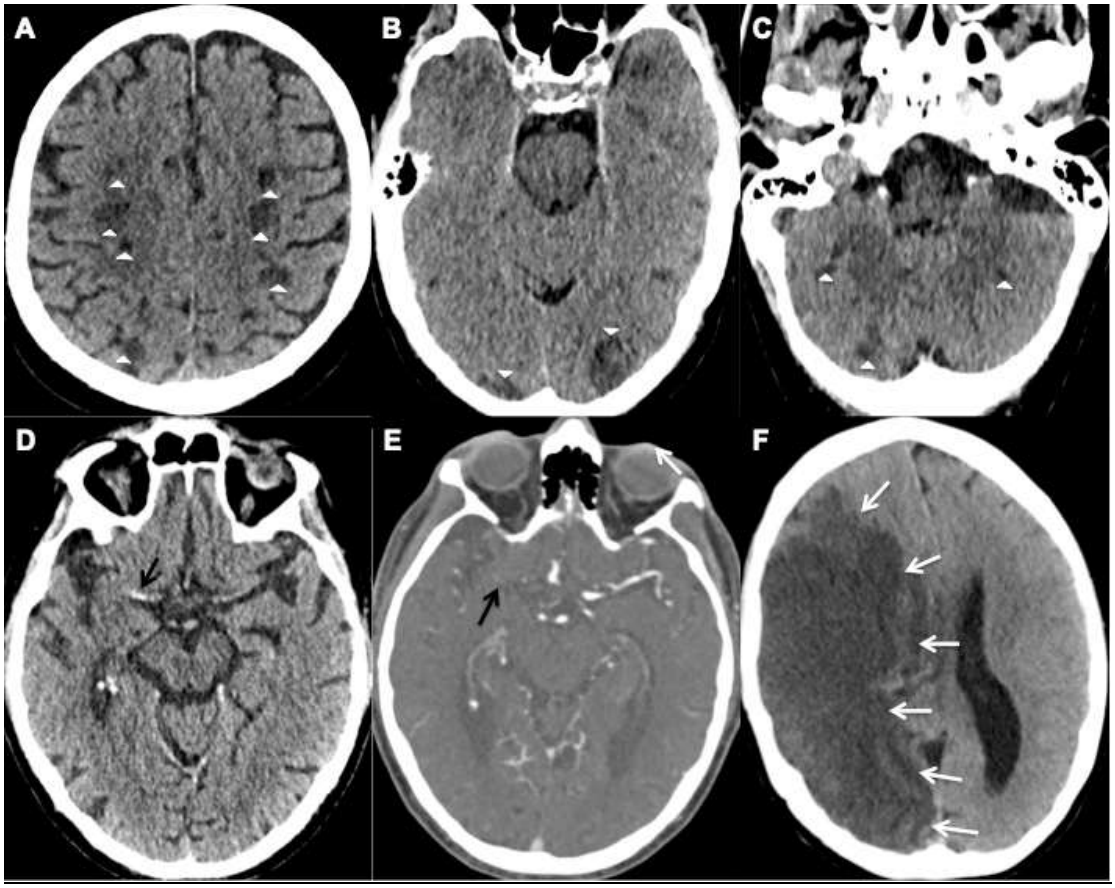

Figure 1 : Representative examples of acute ischaemic stroke events. (A-C) Axial unenhanced CT images of Patient 28 demonstrate multifocal infarcts (white arrowheads) bilaterally along the (A) centrum semiovale, (B) Occipital lobes and (C) Cerebellar hemispheres. (D-E) Axial CT images of Patient 25 demonstrates the hyperdense right middle cerebral artery (MCA) sign (black arrow) and (E) corresponding filling defect on the CT angiogram confirming an occlusive thrombus. (F) Axial unenhanced CT image of Patient 6 shows a large right MCA territory infarct (white arrows) with mass effect in keeping with an MCA malignant syndrome .

medRxiv preprint doi: https://doi.org/10.1101/2020.11.22.20235184; this version posted December 11, 2020. The copyright holder for this preprint (which was not certified by peer review) is the author/funder, who has granted medRxiv a license to display the preprint in perpetuity.
All rights reserved. No reuse allowed without permission.

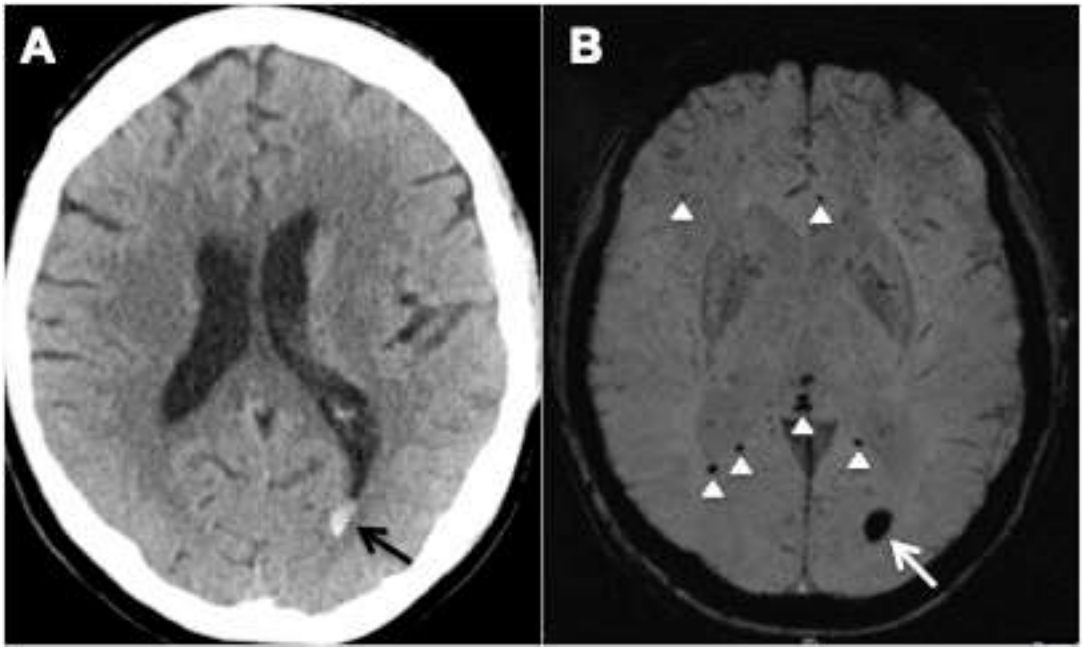

Figure 2 : Axial images of Patient 18. (A) unenhanced CT demonstrates hyperdense layering in the occipital horn of the left lateral ventricle (black arrow) in keeping with isolated intraventricular haemorrhage (IVH), (B) Susceptibility weighted imaging confirms the IVH bleed within the left occipital horn (white arrow) and shows microbleeds at the splenium and genu of the corpus callosum, and subcortical white matter (white arrowheads).

medRxiv preprint doi: https://doi.org/10.1101/2020.11.22.20235184; this version posted December 11, 2020. The copyright holder for this preprint (which was not certified by peer review) is the author/funder, who has granted medRxiv a license to display the preprint in perpetuity.
All rights reserved. No reuse allowed without permission.

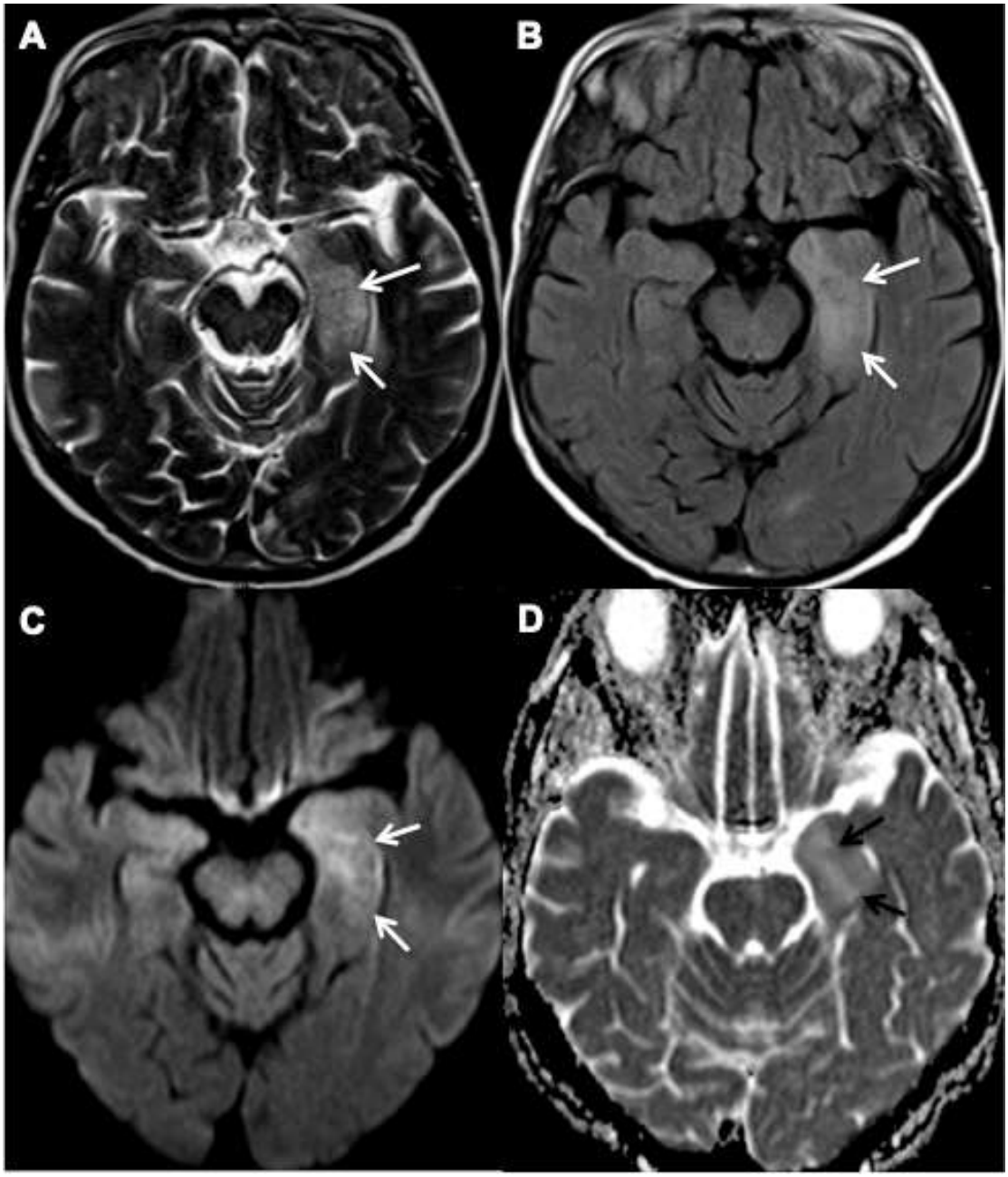

Figure 3 : Axial MR images of Patient 21. (A) T2-weighted and (B) Fluid attenuated inversion recovery (FLAIR) imaging demonstrate hyperintensity within the left medial temporal lobe (white arrow), (C) Diffusion-weighted imaging (white arrows) and (D) Apparent diffusion coefficient (ADC) show corresponding partial diffusion restriction (black arrows), in keeping with cellular inflammation/limbic encephalitis.

medRxiv preprint doi: https://doi.org/10.1101/2020.11.22.20235184; this version posted December 11, 2020. The copyright holder for this preprint (which was not certified by peer review) is the author/funder, who has granted medRxiv a license to display the preprint in perpetuity.
All rights reserved. No reuse allowed without permission.

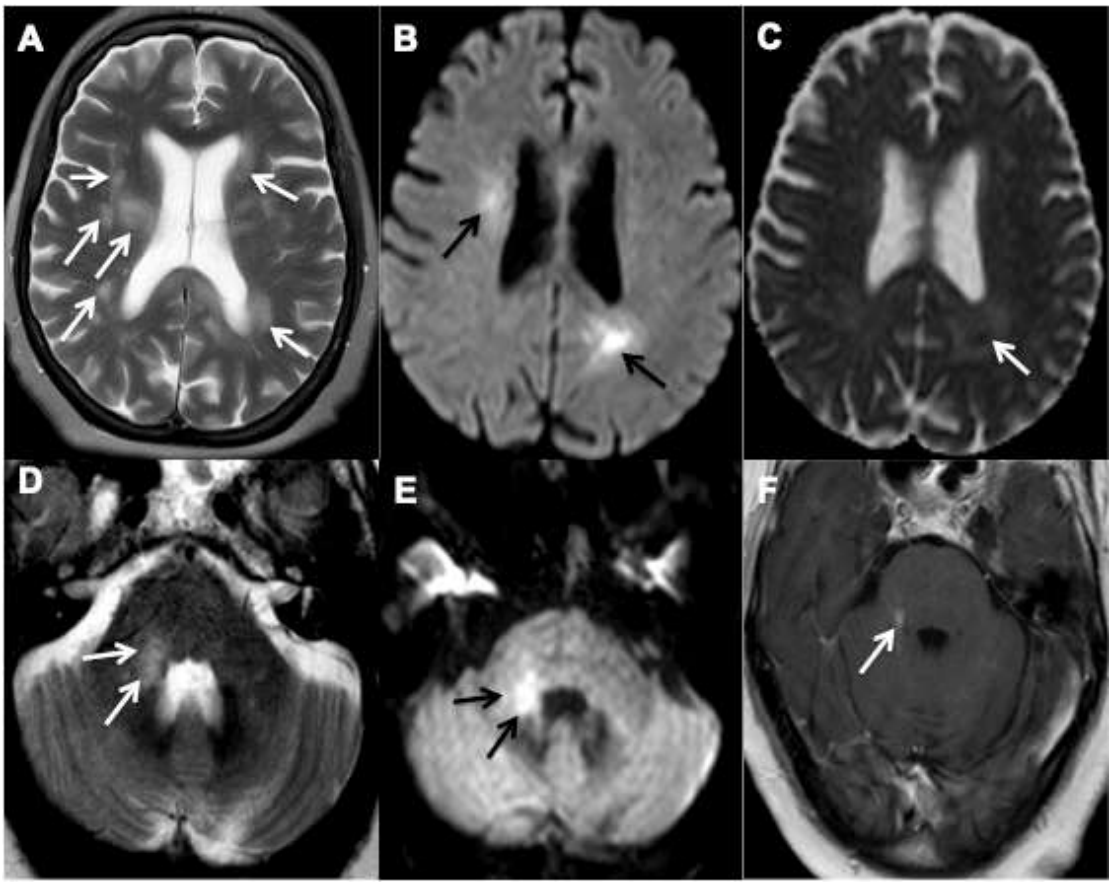

Figure 4 : Axial MR images of Patient 27. (A) T2-weighted imaging demonstrates patchy and asymmetric white matter hyperintensities within the periventricular and subcortical regions and (D) right middle cerebellar peduncle (white arrows). (B) and (E) Diffusion-weighted imaging shows corresponding restriction diffusion (black arrows) with (C) the matched ADC map in demonstrates low ADC value in the left periventricular region. (F) T1-contrast enhanced imaging demonstrates a focus of enhancement in the right superior cerebellar peduncle. Overall features are in keeping with acute demyelinating encephalomyelitis.