

Modelling the Anatomical Distribution of Neurological Events in COVID-19 Patients: A Systematic Review

Nicholas Parsons^{1,2}, Athanasia Outsikas², Annie Parish², Rebecca Clohesy², Nilam Thakkar⁷,
Fiore D'Aprano^{3,4}, Fidel Toomey⁵, Shailesh Advani⁶, Govinda Poudel⁸

1. *Cognitive Neuroscience Unit, Deakin University, Melbourne, Australia*
2. *School of Psychology, Deakin University, Melbourne, Australia*
3. *Melbourne School of Psychological Sciences, The University of Melbourne, Melbourne, Australia*
4. *Department of Neurology, Royal Melbourne Hospital, Melbourne, Australia*
5. *School of Medicine, Deakin University, Geelong, Australia*
6. *Social Behavioural Research Branch, National Human Genome Research Institute, National Institutes of Health*
7. *Curtin University, Perth, Australia*
8. *Mary Mackillop Institute for Health Research, Department of Health Sciences, Australian Catholic University, Melbourne, Australia*

Corresponding Author

Dr. Govinda R. Poudel

Mary Mackillop Institute for Health Research

215 Spring Street, Melbourne, Australia

Ph: +6192308368

Govinda.poudel@acu.edu.au

Summary

Background

Neuropathology caused by the coronavirus disease 2019 (COVID-19) has been reported across several studies. The characterisation of the spatial distribution of these pathology remains critical to assess long and short-term neurological *sequelae* of COVID-19. To this end, Mathematical models can be used to characterise the location and aetiologies underlying COVID-19-related neuropathology.

Method

We performed a systematic review of the literature to quantify the locations of small neurological events identified with magnetic resonance imaging (MRI) among COVID-19 patients. Neurological events were localised into the Desikan-Killiany grey and white matter atlases. A mathematical network diffusion model was then used to test whether the spatial distribution of neurological events could be explained via a linear spread through the structural connectome of the brain.

Findings

We identified 35 articles consisting of 123 patients that assessed the spatial distribution of small neurological events among COVID-19 patients. Of these, 91 patients had grey matter changes, 95 patients had white matter changes and 72 patients had confirmed cerebral microbleeds. White matter events were observed within 14 of 42 white matter bundles from the IIT atlas. The highest proportions (26%) of events were observed within the bilateral corticospinal tracts. The splenium and middle of the corpus callosum were affected in 14% and 9% of the cases respectively. Grey matter events were spatially distributed in the 41 brain regions within the Desikan-Killiany atlas. The highest proportions (~10%) of the events were observed in areas including the bilateral superior temporal, precentral, and lateral occipital cortices. Sub-cortical events were most frequently identified in the Pallidum. The application of a mathematical network diffusion model suggested that the spatial pattern of the small neurological events in COVID-19 can be modelled with a linear diffusion of spread from epicentres in the bilateral cerebellum and basal ganglia (Pearson's $r=0.41$, $p<0.001$, corrected).

Interpretation

To our knowledge, this is the first study to systematically characterise the spatial distribution

of small neurological events in COVID-19 patients and test whether the spatial distribution of these events can be explained by a linear diffusion spread model. The location of neurological events is consistent with commonly identified neurological symptoms including alterations in conscious state among COVID-19 patients that require brain imaging. Given the prevalence and severity of these manifestations, clinicians should carefully monitor neurological symptoms within COVID-19 patients and their potential long-term *sequelae*.

The coronavirus disease 2019 (COVID-19) is caused by severe acute respiratory syndrome coronavirus 2 (SARS-CoV-2).¹ Typically, COVID-19 patients present with fever, cough, fatigue, and dyspnoea, with approximately 20% of cases developing severe life-threatening disease.^{1,2} Extrapulmonary symptoms are also being reported including altered conscious state, seizures and focal neurological injuries, raising concerns over the long-term neurological *sequelae* of COVID-19.³⁻⁸ As of October 15th 2020, more than 38.4 M cases and 1.1 M deaths have been reported globally, with cases rising rapidly in the U.S., India and Brazil.⁹

Several neuroimaging studies have suggested that neurological symptoms in COVID-19 patients are linked to a broad range of acute neurological events, particularly those of cerebrovascular nature. A recent systematic review has shown that these events range from large ischemic strokes to small and localised haemorrhages, vascular thrombosis and microbleeds¹⁰. The presence of cerebral microbleeds (small 2–5 mm perivascular hemosiderin deposits) are also being reported and are presumed to be features of small vessel disease. These smaller neurological events can manifest as fluid-attenuated inversion recovery (FLAIR) signal abnormalities in either grey or white matter,¹⁰ or localised signal changes as measured with T1-weighted, susceptibility-weighted, and diffusion-weighted MRI.¹¹⁻¹³ These events are being associated with increased risk of stroke and poorer functional recovery, which may compromise long-term cognitive outcomes,^{11,13-15} and may therefore reflect a selective vulnerability of brain regions to COVID-19.

Emerging evidence suggests COVID-19 patients may display an atypical distribution of neurological events occurring primarily within the corpus callosum and deep subcortical structures.^{7,16-18} However, these distributions are not well understood and may benefit from mathematical modelling in order to characterise the pattern of distribution and potential epicentres of spread. For instance, network diffusion models (NDM) can emulate the pattern of pathological spread in the brain via white matter pathways, and have been useful in modelling the spread of disease in other neurological conditions such as Huntington's and Alzheimer's disease.¹⁹⁻²¹ However, to date there has been no application of any mathematical model to assess and map the distribution of neurological events associated with COVID-19.

This systematic review aims to (1) critically review current literature investigating the location of neurological events in patients with COVID-19 and (2) shed light on the distribution of COVID-19 related neurological events within grey and white matter. Subsequently, we: (1) summarized recent literature on neurological events (2) mapped the spatial distribution of neurological events and (3) utilised NDM to model the spread of neurological events in COVID-19 patients.

Method

Protocol registration

This systematic review was registered with the International Prospective Register of Systematic Reviews (PROSPERO: registration number CRD42020201161) and conducted according to PRISMA guidelines.²²

Search strategy

We searched Medline, Embase, Scopus and LitCovid databases from 1st January 2020 – 19th July 2020 using the MeSH terms "coronavirus" OR "COVID-19" AND "neurolog*" OR "brain" OR "central nervous system" OR "CNS" AND "MRI" OR "magnetic resonance imaging" OR "hypointensities" OR "microbleeds" OR "cerebral microbleeds" OR "microhemorrhages". Additional studies were identified by manually searching the reference lists of relevant articles. The search strategy is described in supplementary Fig. 1 in a PRISMA flow-chart. Search was conducted with help of a health science librarian.

Selection criteria

We included case reports, case series and observational studies published in peer-reviewed journals and preprints available in English that identified small neurological events in patients with COVID-19 using MRI. Articles without full texts and studies without laboratory-confirmed COVID-19 patient diagnosis were excluded. Any studies only reporting large cerebrovascular events (such as strokes, infarcts) and diffuse pathology (non-specific) were also excluded.

Data extraction

Two independent reviewers screened articles by title and abstract for relevance. These studies were then screened for eligibility for inclusion by full text evaluation. For each included article, two independent reviewers extracted data (AP, RC). Disagreements were collaboratively resolved within the team. Instructions detailing the type of information to be extracted and how to record, categorise or code this information was also discussed amongst team members. The following information was extracted from each manuscript: (a) country, first author and year of publication; (b) sample characteristics (sample size, age group and sex distribution); (c) study design; (d) clinical symptoms; (e) reason for brain imaging; (f) type of MRI performed; (g) imaging findings; and (h) relevant conclusions to assist article interpretation. Two additional reviewers (FD, FT) then validated all the extracted data and the eligibility of each included article.

Neuroimaging data synthesis and coding

Two expert reviewers (NP, GP) screened each included article to identify the location, distribution, and number of neurological events. These events ranged from microbleeds (observed in SWI or T2* GRE images), white matter hyperintensities (FLAIR images), small lesions, or signal changes in diffusion-weighted MRI within grey or white matter. For each article, events were manually localised to grey or white matter regions based on available MRI images and/or radiological descriptions. The Illinios Institute of Technology (IIT) Desikan-Killiany grey matter atlas incorporating 84 brain regions, was used to label any events located within grey matter.²³ IIT white matter bundles were used to label any events located within white matter.²³ FSLeves neuroimaging software from the FMRIB library was used to visualise white matter tracts and grey matter areas from the IIT atlas.²⁴ Any COVID-19 patient with non-specific neuropathological findings (e.g. “juxtacortical white matter”) or without an MRI image or description were excluded from further analyses. This data encoding process generated two tables for grey and white matter regions with columns corresponding to each article and rows corresponding to the name of the region/bundle. Each cell in the table provided information on the number of cases corresponding to the neurological event. A third independent reviewer (FT) validated the encoded data and any discrepancies were discussed and addressed.

Neuroimaging Data Visualisation

Proportions of events $\left(\frac{\text{number of events} \times 100}{\text{total cases}}\right)$ belonging to each encoded region within the IIT Desikan-Killiany grey matter atlas and IIT white matter bundles were used for visualisation. Grey matter events were visualised using MRICroGL software.²⁵ White matter events were visualised using MATLAB 2018a and CONN toolbox version 19b.^{26,27}

Network diffusion model of spread

A graph theoretical meta-analytic model was used to test whether the spatial distribution of small neurological events in the brain can be explained by a spread via the brain's structural connectome (source code available at: <https://github.com/govin2000/covidspread>). NDM was used per previous protocols that identified a spatial pattern of pathology in the brain.^{19,20} NDM models the hypothetical distribution of pathology in a brain network (given by a connectome C) over time by linear diffusion, given by: $x(t) = e^{-\beta H t} x_0$ where x_0 is the initial pattern of the neurological events at $t = 0$, H is the degree normalised graph Laplacian, and β is a diffusivity constant. The unit of the model's diffusion time t is assumed to be days (given the likely progression of 5-14 days^{4,8,14}) for the diffusivity constant β of 1 per day. $x(t)$ is a vector of distribution of pathology in the brain when diffusion is seeded from a given region provided by an initial condition x_0 . We used a repeated seeding approach, which has previously been used to identify potential epicentres of the spread of neuropathology.²⁸ We also used the IIT brain connectome, which is available openly.²³

NDM generates a vector of distribution of pathology $x(t)$ over time. We expect that $x(t)$ should correlate with distribution of neurological events. Thus, Pearson's correlation coefficient strength and p -values were calculated between the empirical proportions of events measured using the systematic review (described above) and $x(t)$ at all model timepoints (t). This process was repeated for all bilateral regions (42 bilateral regions) within the IIT Desikan-Killiany grey matter atlas. The region that showed the largest significant ($p < 0.05$, Family-wise error corrected for 84 regions) association with measured neurological events was defined as the seed region.

Results

The systematic search yielded 461 articles, of which 62 were eligible for full-text assessment (see Supplementary Fig. 1 for PRISMA flow-chart). Of these, 28 were excluded; these were commentaries, response letters and review articles proposing SARS-CoV-2 nervous system invasion but lacking clinical findings. A total of 35 publications reporting small neurological events in patients with COVID-19 were evaluated. Of these, 35 provided specific anatomical detail required for meta-analysis and modelling. These articles contributed 123 unique patients, with a total of 317 neurological events. Of these, 91 patients had grey matter changes, 95 patients had white matter changes and 72 patients had confirmed cerebral microbleeds. Further details on the presentation of grey and white matter events can be found in table 1 below.

Table 1. Clinical presentation and MRI findings in COVID-19 patients

	<i>Clinical features</i>	<i>MRI modalities</i>	<i>MRI findings</i>
Abdel-Mannan et al., ²⁹ (UK)	Four patients (mean age 12 years; two male one female); all had encephalopathy; global proximal muscle weakness; three had headache; two had reduced reflexes; two had brainstem signs with dysarthria or dysphagia; two had dyspnoea; one had meningism; and, one had cerebellar ataxia.	T2, FLAIR	Signal change in splenium of corpus callosum (n=4, diffusion restriction in 3/4); genu of corpus callosum (n=2) bilateral centrum semiovale (n=2).
Afshar et	One female aged 39 years	T1, T2, FLAIR,	FLAIR hyperintensities and T1

al., ³⁰ (Iran)	with altered conscious state, drowsiness, and, two with generalised tonic-clonic seizures on day 11.	DWI	hypointensities in bilateral thalami, medial temporal lobes and pons, without T1 contrast enhancement or diffusion restriction.
Anand et al., ³¹ (USA)	One female aged 61 years with rightward gaze deviation and repeated 3-5min generalised tonic clonic seizures with multiple focal onset events.	FLAIR, DWI	FLAIR hyperintensities in the subcortical U-fibres, periventricular white matter, bilateral cerebellar hemispheres and bifrontal cortices with diffusion restriction, suggestive of extensive leukoencephalopathy.
Aragao et al., ³² (Brazil)	Five adult patients; four with headache; three with anosmia; and, one with motor deficit.	T1, STIR	Hyperintensity in olfactory bulbs (n=5), suggestive of microbleeds.
Bonardel et al., ³³ (France)	One male aged 51 years with headache, abrupt cortical blindness and disorientation.	DWI, SWI, DSC-MRI perfusion	FLAIR hyperintensity and SWI hypointensity in the bilateral occipito-temporal cortex, consistent with infarction.
Collange et al., ³⁴ (France)	One male aged 56 years with confusion, encephalitis, eye damage, observed parkinsonism, quadraparesis and extensor plantar reflex.	T1, FLAIR	FLAIR hyperintensities in the bilateral deep cerebral nuclei (dentate nucleus, pallidum, and thalamus), bilateral internal capsules, corpus callosum and adjacent white matter with some areas of T1 contrast enhancement, suggestive of necrotising haemorrhagic encephalitis.
De Stefano et	One female aged 56 years	DWI, SWI	Diffuse punctiform

al., ³⁵ (Switzerland)	with altered conscious state.		hypointensities or microbleeds in the bilateral juxtacortical white matter, corpus callosum, and internal capsule.
Dixon et al., ³⁶ (UK)	One female aged 59 years with headache, altered conscious state and a generalised tonic-clonic seizure.	T1, T2-Weighted, SWI	T2 hyperintensity, oedema and microhemorrhage bilaterally in the dorsolateral putamina, ventrolateral thalamic nuclei, subinsular regions, splenium of corpus callosum, cingulate gyri, amygdalae, pons and subcortical perirolandic regions with T1 peripheral contrast enhancement and diffusion restriction, suggestive of diffuse haemorrhagic acute necrotising encephalopathy.
Doo et al., ³⁷ (USA)	One male aged 64 years with seizure (post-extubation).	FLAIR, GRE	FLAIR hyperintensity consistent with oedema in the bilateral parieto-occipital white matter and GRE multifocal haemorrhagic foci, suggestive of acute PRES-like leukoencephalopathy with multifocal haemorrhage.
Fitisori et al., ¹⁶ (Switzerland)	Nine patients (mean age 67.7 years; seven male, two female); six with psychomotor agitation or a withdrawal syndrome post-extubation ventilation; three with delayed recovery of consciousness after deep	T1, T1WI (+/- contrast), T2WI, FLAIR, SWI, DWI	Microbleeds in the subcortical white matter (n=7), corpus callosum (n=9), basal ganglia (n=2), anterior or posterior limbs of the internal capsule (n=5), middle cerebellar peduncles (n=5), cerebellum (n=1) and septum pellucidum

	sedation; and, two with headache.		(n=1), with sequelae of parietal haemorrhage (n=1), lacunar infarction (n=2), centrum semiovale infarction (n=1) and central pontine myelinolysis (n=1).
Frisullo et al., ³⁸ (Italy)	One female aged 49 years with dysarthria, left facial weakness, left hemiparesis, and hemianesthesia.	FLAIR, DWI	FLAIR hyperintensities in the right perirolandic cortex (pre and post central gyri).
Hanafi et al., ³⁹ (France)	One male aged 65 years with altered conscious state despite withdrawal of sedation.	T1, T2* weighted, FLAIR, DWI	T2* microhaemorrhage in the globus pallidus bilaterally. FLAIR hyperintensities and DWI focal ischaemic lesions with patchy T1 contrast enhancement in the bilateral hemispheric/periventricular white matter, corpus callosum, basal ganglia, middle cerebellar peduncles and cerebellar hemispheres.
Hernandez-Fernandez et al., ⁴⁰ (Spain)	Three patients (one male (a), with focal neurological deficits and epileptic seizures complicated by left hemispheric focal non-convulsive status epilepticus; one male aged 69 years (b) with altered conscious state after extubation; and, one patient (c) with altered conscious state and focal epileptic	T2, FLAIR, DWI, GRE	(a) FLAIR hyperintensities in the supra and infratentorial deep white matter, basal ganglia, thalamus, brainstem and cerebellar hemispheres. Acute bihemispheric subcortical ischaemic lesions of the posterior circulation. (b) T2* hypointense foci in the left frontal cortex and multiple cortico-subcortical microbleeds. FLAIR

seizures after extubation. Nil other demographics and clinical manifestations reported.

hyperintensities in the bilateral parieto-occipital white matter with extension to centrum semiovale.

(c) Microbleeds in the cortex and subcortical white matter without diffusion restriction, consistent with PRES-type leukoencephalopathy with haemorrhage. FLAIR hyperintensities in the right frontal cortex and bilateral parieto-occipital white matter, with patchy extension to left centrum semiovale.

Kandemirli et al.,⁴¹ (Turkey) 12 patients (mean age 62 years; 11 male, one female); one with anosmia; and, one with altered conscious state. Nil other clinical manifestations reported.

T1, T2, FLAIR, DWI, SWI, 3DTOF, TurboFlash

FLAIR abnormalities with some increased cortical diffusion (n=7), leptomeningeal enhancement (n=5) or cortical blooming artifact (n=3) in the frontal (n=4), parietal (n=3), occipital (n=4), insular (n=3), cingulate (n=3) and temporal (n=1) cortices, and in the subcortical (n=3) and deep white matter (n=3).

Kremer and Lersy et al., ⁸ (France)	37 patients (mean age 61 years; 30 male, 7 female); 27 with altered conscious state; 20 with focal neurological deficits; 15 with intensive care wakefulness; 12 with confusion; and, 7 with agitation; 5 with seizures; and, 4 with headache.	T1, T2, FLAIR, DWI, SWI, GRE	FLAIR hyperintensities with some diffusion restriction in the unilateral medial temporal lobe (n=16), FLAIR non-confluent multifocal white matter hyperintensities with variable enhancement associated with haemorrhagic lesions (n=11) and without (n=2), extensive and isolated white matter microhemorrhages (n=9), FLAIR confluent hyperintensities in the supratentorial white matter (n=4), FLAIR and diffusion ovoid hyperintensity in the splenium of corpus callosum (n=2), acute necrotising encephalopathy (n=2) and FLAIR hyperintensities in the bilateral middle cerebellar peduncles (n=2).
Krett et al., ⁴² (Canada)	One male aged 69 years with agitation, altered conscious state and focal neurological deficits (diffuse paresis, flaccid extremity tone and areflexia)	FLAIR, SWI, GRE	FLAIR and SWI multifocal, multi-compartmental non-enhancing haemorrhages with peri-haemorrhage vasogenic oedema, consistent with haemorrhagic encephalopathy.
Lang et al., ⁴³ (USA)	Six patients (mean age 64; 4 male, 2 female); six with altered conscious state; one with aphasia; one with	T1, T2, FLAIR, DWI, SWI	FLAIR hyperintensities with diffusion restriction in the bilateral deep white matter with relative sparing of

	hypertonicity; and, one with lower extremity paresis.		subcortical U-fibres (n=6), corpus callosum (n=1), middle cerebellar peduncles (n=5) and corticospinal tracts (n=3), consistent with leukoencephalopathy.
Li et al., ⁴⁴ (Taiwan)	One male aged 21 years with anosmia.	T2	Linear hyperintensities in the bilateral olfactory nerves and a smaller right olfactory bulb, suggestive of bilateral olfactory neuropathy.
Mahboob et al., ⁴⁵ (USA)	One female aged 58 years with acute onset left hemiplegia, dysarthria, left homonymous hemianopia, right gaze preference and positive left Babinski sign.	DWI	DWI hyperintensity in the left cerebellum consistent with ischemic infarction in the territory of the posterior inferior cerebellar artery.
Morassi et al., ⁴⁶ (Italy)	One female aged 76 years with focal seizures with a marked post-ictal period.	FLAIR, DWI	FLAIR hyperintensity with diffusion restriction in left precentral gyrus. FLAIR hyperintensity with contrast enhancement in the head of the right caudate nucleus and left middle frontal gyrus.
Moriguchi et al., ⁴⁷ (Japan)	One male aged 24 years with headache, then generalised seizures, reduced consciousness, meningism and convulsion followed by unconsciousness.	T2, FLAIR, DWI	DWI non-enhancing hyperintensity along the wall of the right lateral ventricle (inferior horn), right medial temporal lobe and hippocampus with slight hippocampal atrophy, consistent with right lateral ventriculitis and encephalitis.

Nepal et al., ⁴⁸ (USA)	One male aged 50 years with altered conscious state.	FLAIR, DWI	FLAIR confluent hyperintensities in the bilateral centrum semiovale and multiple bilateral punctate lacunar areas of diffusion restriction in the centrum semiovale and periventricular white matter, suggestive of acute embolic infarcts or vasculitis.
Novi et al., ⁴⁴ (Italy)	One female aged 64 years with headache, bilateral vision impairment with associated sensory deficit on her right leg, headache, bilateral relative afferent pupillary defect, ageusia and anosmia, severe visual loss, right abdominal sensory level, and left-sided lower limb hyperreflexia.	T1, T2	Six T1 ring or nodular enhancing cortical lesions, a right temporal lobe lesion and T2 hyperintensity in the optic nerves bilaterally.
Parauda et al., ⁴⁹ (USA)	Four patients (mean age 71.5 years; two male and two female); all with altered conscious state; two with seizures; one with non-convulsive status epilepticus; one with global aphasia; and, one with right arm weakness.	T2, FLAIR, DWI, SWI	FLAIR hyperintensities with some diffusion restriction in the bilateral occipital white matter (n=2), parieto-occipital white matter (n=2), bilateral frontoparietal white matter (n=1), left thalamus (n=1) and posterior limb of the left internal capsule (n=1), compatible with vasogenic oedema and some microhaemorrhage on SWI, all

			suggestive of posterior reversible encephalopathy syndrome.
Politi, Salsano & Grimaldi, ⁵⁰ (USA)	One female aged 25 years with severe anosmia.	T2, FLAIR	FLAIR hyperintensities in the right posterior gyrus rectus and bilateral olfactory bulbs, resolving on follow up MRI 28 days later with new evidence of olfactory bulb thinning.
Poyiadji et al., ⁵¹ (USA)	One female aged 58 years with altered conscious state.	T2, FLAIR, SWI	FLAIR ring-enhancing hyperintensities with susceptibility hypointensity in the bilateral medial temporal lobes, thalami and subinsular regions with evidence of haemorrhage.
Radmanesh et al., ⁷ (USA)	11 patients (mean age 53 years; 9 male and 2 female); all with altered conscious state. Nil other clinical manifestations reported.	T2, FLAIR, SWI	FLAIR confluent hyperintensities and mild restricted diffusion in the bilateral supratentorial deep and subcortical white matter extending from the precentral gyrus to the centrum semiovale, corona radiata and posterior cerebral white matter (n=10), occipital lobes (n=7), middle cerebellar peduncles (n=4) and cerebellar hemispheres (n=4). Multiple punctate microhaemorrhages in juxtacortical white matter (n=5) and/or the corpus callosum, particularly the

			splenium (n=4). MRI 7-days prior in one patient suggests all reported microhaemorrhages were new.
			Imaging overall consistent with diffuse leukoencephalopathy (n=4), microhemorrhages (n=1) or both (n=6).
Rogg, Baker & Tung, ⁵² (USA)	One male aged 59 years with altered conscious state.	FLAIR, DWI	FLAIR non-enhancing hyperintensities with increased diffusivity in the posterior subcortical and deep white matter, internal and external capsules and cerebellar white matter. FLAIR non-enhancing hyperintensity without diffusion restriction in the deep grey matter. Imaging consistent with posterior reversible encephalopathy syndrome.
Rudilosso, Esteller, Urra & Chamorro, ⁵³ (Spain)	One male aged 50 years with sudden right facial palsy and mild ipsilateral limb weakness.	DWI	DWI punctate hyperintensities in the left medial thalamus and bilateral cerebellum, consistent with ischaemia.
Scullen et al., ¹⁸ (USA)	7 patients (one female aged 63 years, with altered conscious state; one female aged 43 years, with left hemiplegia and extensor posturing). Remaining demographics and clinical manifestations not	FLAIR, DWI, SWI, GRE	Diffuse FLAIR hyperintensities with some diffusion restriction in the deep white matter (n=7), corpus callosum (n=7), basal ganglia or pallidum (n=7), centrum semiovale (n=2), occipital pole (n=1), bilateral medial

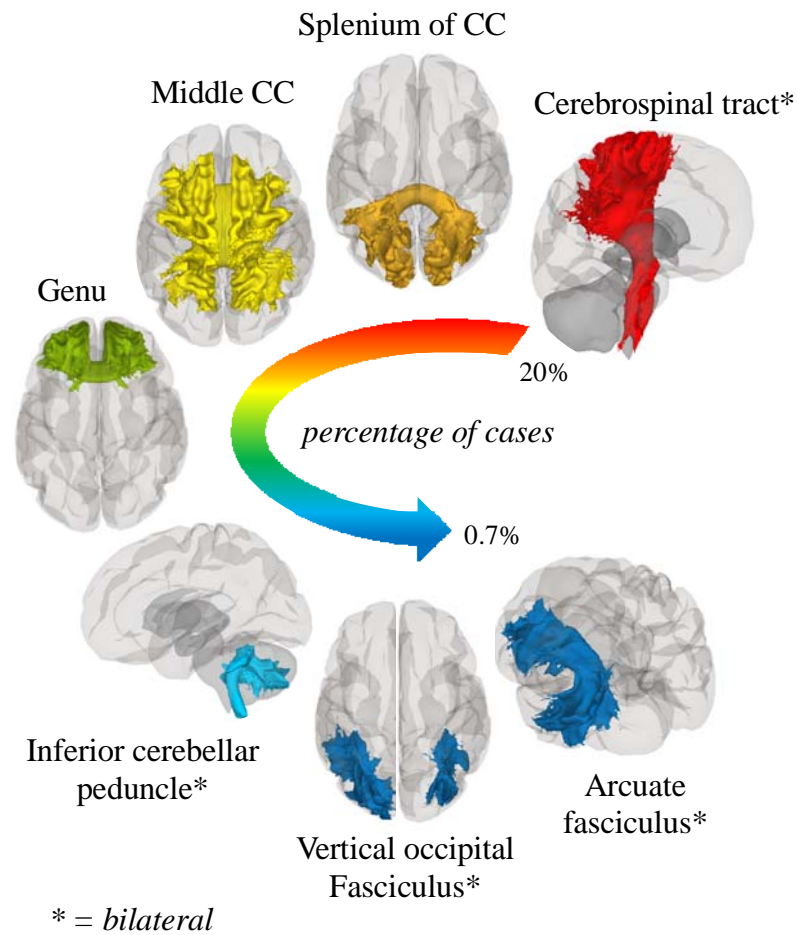
	specified.		temporal lobe (n=1) and crus cerebri (n=1), broadly consistent with viral encephalitis.
Shoskes et al., ⁵⁴ (USA)	One male aged 69 years with altered conscious state.	FLAIR, DWI, SWI	SWI hypointensities and FLAIR hyperintensities mostly with diffusion restriction in the bilateral juxtacortical white matter, corpus callosum, basal ganglia, brainstem and cerebellum, consistent with microhaemorrhages.
Soldatelli et al., ⁵⁵ (Brazil)	One male aged 67 years with altered conscious state.	T1, FLAIR, SWI	SWI hypointensities at the cortico-subcortical junction and in the corpus callosum, consistent with microhaemorrhages. Intraparenchymal haematoma in the left thalamus and posterior internal capsule draining to the lateral ventricle. FLAIR hyperintensities in right frontoparietal convexity consistent with subarachnoid haemorrhage. A follow-up MRI depicted partial reabsorption of the subarachnoid haemorrhage, foci of cortical laminar necrosis, gliosis in the right prefrontal cortex and superficial siderosis with no additional signs of acute

			ischaemia.
Wong et al., ⁵⁶ (UK)	One male aged 40 years with unsteady gait, diplopia, oscillopsia, limb ataxia, right arm paraesthesia, mild bilateral facial weakness and reduced tongue movements to both sides on admission.	T2	T2 hyperintensity in the right inferior cerebellar peduncle, extending to the spinal cord, suggestive of rhombencephalitis myelitis with possible associated oedema and microhaemorrhage.
Zhang et al., ⁵⁷ (USA)	One female in her early 40s with headache, dysphagia, dysarthria, expressive aphasia and altered conscious state.	FLAIR, DWI	FLAIR hyperintensity with some corresponding DWI and ADC changes in the bilateral frontoparietal white matter, anterior temporal lobes, basal ganglia, external capsules and thalami, consistent with acute disseminated encephalomyelitis.
Zoghi et al., ⁵⁸ (Netherlands)	One male aged 21 years with weakness and paraparesis of upper and lower limbs, lower limb paresthesia and a T8 sensory level.	T2, FLAIR	FLAIR hyperintensities in the bilateral corticospinal tract, internal capsules, cerebral peduncles, pons and splenium of the corpus callosum, suggestive of acute disseminated encephalomyelitis or neuromyelitis-optica spectrum disorder.

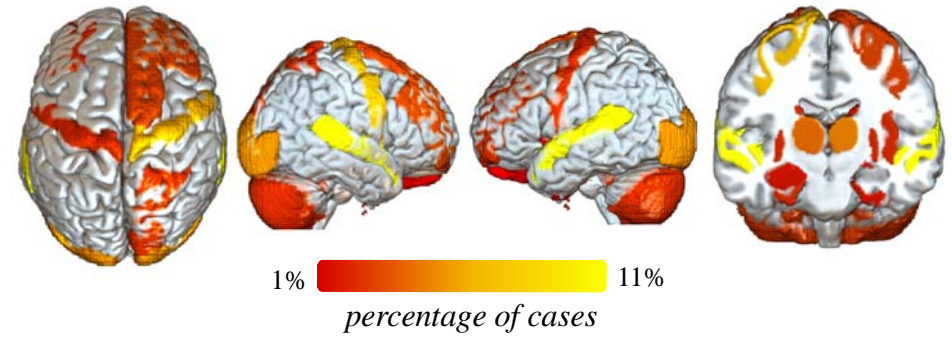
*DWI = Diffusion-weighted imaging, STIR = short inversion time inversion recovery, SWI = susceptibility-weighted imaging, DSC = dynamic susceptibility contrast, GRE = gradient echo, ADC = apparent diffusion coefficient, TOF = time of flight

Figures 1a and b visualise the spatial distribution of white and grey matter neurological events. White matter events were observed within 11 of 42 white matter bundles from the IIT white matter bundles atlas. The highest percentage (26%) of events were observed within the bilateral corticospinal tracts, composed of white matter fibres which connect the primary motor cortex and basal ganglia.⁵⁹ The splenium and middle of the corpus callosum were affected in 14% and 9% of the cases respectively. The remaining tracts show white matter events in less than 9% of cases. Of the cerebral microbleeds observed, a similar pattern emerged; where the largest proportion of cerebral microbleeds were also found in the middle corpus callosum, followed by the splenium of the corpus callosum. Grey matter events were spatially distributed among 41 brain regions within the Desikan-Killiany atlas. The highest proportions (~10%) of the events were observed in bilateral superior temporal, precentral, and lateral occipital cortices. Sub-cortical events were most frequently identified in the Pallidum.

(a) White matter events



(b) Grey matter events



(c) Trans connectome-based network diffusion model

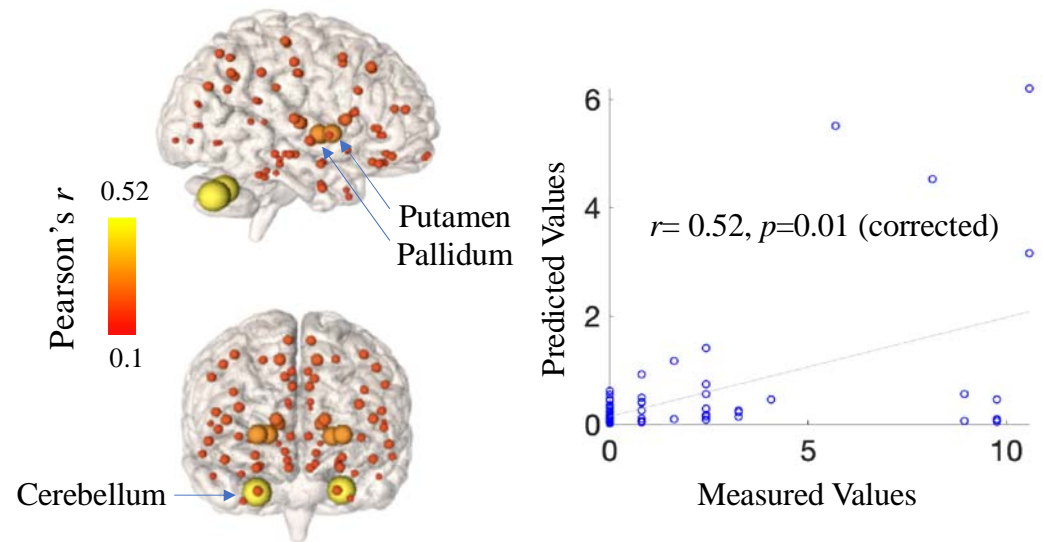


Fig 1. Distribution and modelling of neurological events in the COVID-19 brain.

The highest proportions of events occurred in white matter areas (*a*) such as the corticospinal tract. (*b*) In grey matter, the most vulnerable regions were the bilateral superior temporal cortices, precentral cortices, and pallidum. (*c*) A network diffusion model using structural connectivity edge weights successfully predicted the spread of neurological events. The epicentres of spread which showed the most significant association between predicted and measured distribution of events were the bilateral cerebellum and putamen (*c*).

Network diffusion model findings

Each of the 84 regions within the IIT Desikan-Killiany grey matter atlas were used as a potential seed for the spread of pathology over time. Figure 1d shows a glass-brain visualisation of the best fit (maximum Pearson's correlation coefficient value) between empirical events and predicted values determined using NDM. A significant fit was achieved when seeding the spread from the bilateral cerebellum (Pearson's $r=0.52$, $p < 0.001$ corrected) and putamen ($r=0.4$, $p=0.02$ corrected). Other basal ganglia structures also showed moderate associations ($r>0.3$) but were not significant after correction. The spatial distribution of the fit in all regions reflects the consequence of network spread starting from each of the regions. The correlation-time curve demonstrated the fit between empirical data and the NDM predicted events for all bilateral seeds (42 regions) is shown in Supplementary Figure 1a. The association between empirical events and predicted events was low ($r<0.2$) when Euclidian distance between regions was used as network edges instead of the structural connectivity data (Supplementary Figure 1b).

Discussion

COVID-19 patients are vulnerable to acute neuropathology, commonly in the form of small neurological and cerebrovascular events. We systematically reviewed articles reporting localised MRI findings in COVID-19 patients and spatially encoded them onto a common grey and white matter atlas. We then investigated whether the spatial distribution of these events follows a cortical or subcortical pattern that can be explained by a linear diffusion-based model of pathological spread. We found the *epicentres* of this spread to be the cerebellum and putamen.

Neurological events in white and grey matter

White matter events were identified most frequently in the corticospinal tract and corpus callosum. The corticospinal tract is a major white matter pathway connecting critical subcortical brain regions such as the basal ganglia and thalamus and as such, facilitates information related to voluntary motor control. As a result, diffuse aberrations in the corticospinal tract are associated with motor symptoms such as tendon reflexes, ankle clonus, and bilateral extensor plantar reflexes, which have been commonly reported in COVID-19 patients.^{8,38,42,46,60} Similarly, the corpus callosum plays an important role in interhemispheric communication; which can result in disconnection syndrome and broad neurocognitive deficits.⁶⁵

In grey matter regions, events were identified most frequently in the temporal and precentral gyrus as well as the bilateral thalamus. Alterations in thalamocortical connectivity can disrupt the regulation of consciousness and arousal.^{61,62} As such, acute events in these regions may explain symptoms such as confusion, disorientation, agitation, and loss of consciousness.^{8,30,34,40,51,53,55} Despite their acute manifestation, the accumulation of neurological events in subcortical structures and consequent disruption to distal cortical regions can increase susceptibility to cognitive impairment and decline—bearing significant ramifications for long-term cognitive prognosis.^{63,64}

The epicentre and mechanism of spread

We found that the critical epicentres for triggering the widespread neurological events to be the cerebellum and putamen. Given the potential for SARS-CoV-2 neurotropism, this finding is interesting, as neuropathology in the piriform cortex could be caused initially by the introduction of a virus through a direct axonal connection with the olfactory bulb.⁶⁵ However, a speculative interpretation could be that the cerebellum, due to its anatomical proximity to large cerebral arteries may serve as the initial site of neuropathology. SARS-CoV-2 may then travel to deep subcortical structures that are supplied sequentially with blood *after* the cerebellum such as the putamen, and then to cortical sites such as the precentral gyrus, via retrograde transsynaptic transmission by hijacking axonal transport mechanisms.⁶⁵⁻⁷⁰ While in transit, direct neuronal or endothelial cell disruption may exacerbate the systemic pathophysiology, facilitating cerebrovascular complications and mixed type I/II respiratory failure.^{3,65,69} However, SARS-CoV-2 has rarely been isolated from CSF samples raising doubt over its neurotropism and direct role in neurological event pathogenesis.^{69,71,72}

Patients with neurological symptoms also presented with anosmia,^{32,44,50} encephalopathy, seizures, and changes to vision including cortical blindness and visual confabulation.^{33,44,73} Alterations in olfaction may therefore have a neurological basis, particularly in light of the identified pathology implicating the olfactory bulb in clinical imaging,^{32,44,50} including the presence of microbleeds among these patients. It is plausible that these symptoms relate closely to the mode of infiltration of SARS-CoV-2, with a potential mechanism being direct injury to the nervous system via ACE2 receptor expression on nerve cells, including the olfactory bulb.³⁷

Other proposed pathological mechanisms may explain the distribution of neurological events including neuroinflammatory responses and cytokine and hypoxia-induced injury.^{4,18,69} Emerging evidence is characterising COVID-19 as a vascular disease; a hyperinflammatory response with ensuing cytokine storm and coagulopathy which may synergistically contribute to neurological event pathogenesis.^{3,4,18,69,74} COVID-19-associated coagulopathy occurs proportional to disease severity and leads to treatment-resistant thrombotic and haemorrhagic events; characterised by d-dimer elevation with prothrombin prolongation and thrombocytopenia.⁷⁴⁻⁷⁷

Furthermore, cytokine- and hypoxia-induced injury to the corpus callosum, particularly the splenium, has been reported within critical illness including acute respiratory distress

syndrome and high-altitude cerebral oedema, potentially contributing to a vulnerability in COVID-19.^{17,78-83} Hypoxia directly induces chemical and hydrostatic endothelial cell disruption, promoting vascular permeability and hence contributing to neurological event pathogenesis.⁸⁴ Relative to the cortex, the thalamus, basal ganglia and deep white matter are poorly perfused due to their watershed end-arterial vascular architecture which could exacerbate their baseline hypoxic vulnerability and ultimately promote subcortical neurological events.⁸⁴⁻⁸⁸ While the pathogenesis of white matter hyperintensities remains under debate, roles for hypoxia, immune activation, endothelial cell dysfunction and altered metabolism have been posited; not dissimilar from the neuropathological suggestions within COVID-19.¹³⁻⁸⁹

Limitations

This review has several important limitations. Firstly, we translated neurological events into a standard MRI atlas space using a qualitative method; whereby these pathologies were localised using the radiological description of the location and MRI images where available. While this method is inherently subjective and lacks specificity, we used multiple neuroimaging experts and only included data with specific spatial information or MRI images. As such, the qualitative nature of the translation should be considered with caution while interpreting our findings. Secondly, most of the included articles were cross-sectional case studies and hence cannot directly attribute the observed neuropathology to SARS-CoV-2. Therefore, longitudinal neuroimaging is necessary to directly assess causality. Lastly, some of the neurological events included in our study may be explained by the ageing process; whereby white matter hyperintensities are correlated with age.^{13,90} Hence, findings regarding white matter changes; particularly white matter hyperintensities in the centrum semiovale, should be interpreted with caution.

Conclusion

Patients with COVID-19 exhibit acute neuropathological and cerebrovascular events. These events occur predominantly in white matter tracts such as the corticospinal tract and corpus callosum, as well in grey matter areas such as the pallidum, putamen, thalamus, and cerebellum. These aberrations likely contribute to altered thalamocortical connectivity and may disrupt the regulation of consciousness and arousal. The accumulation of these events in

subcortical structures and the consequent disruption to distal regions, may ultimately increase susceptibility to cognitive impairment and decline—bearing significant long-term cognitive ramifications. Given the prevalence and severity of these manifestations, clinicians should consider having a low threshold for investigating neurological symptoms and monitoring potential long-term *sequelae* in COVID-19 patients.

Author contributions:

Nicholas Parsons: data analysis and interpretation, writing, visualization, original draft preparation, Nasia Outsikas: data extraction, curation original draft preparation, Annie Parish: data extraction, Rebecca Clohesy: data extraction, Nilam Thakkar: data extraction, Fiore D’Aprano: data extraction, interpretation, writing and original draft preparation, Fidel Toomey: data extraction, interpretation, writing and original draft preparation, Shailesh Advani: data extraction, interpretation, original draft preparation, Govinda Poudel: data analysis and interpretation, writing, visualization, original draft preparation.

Supplementary material

Fig. 1. PRISMA flow diagram showing the number of studies screened and included in the meta-analysis.

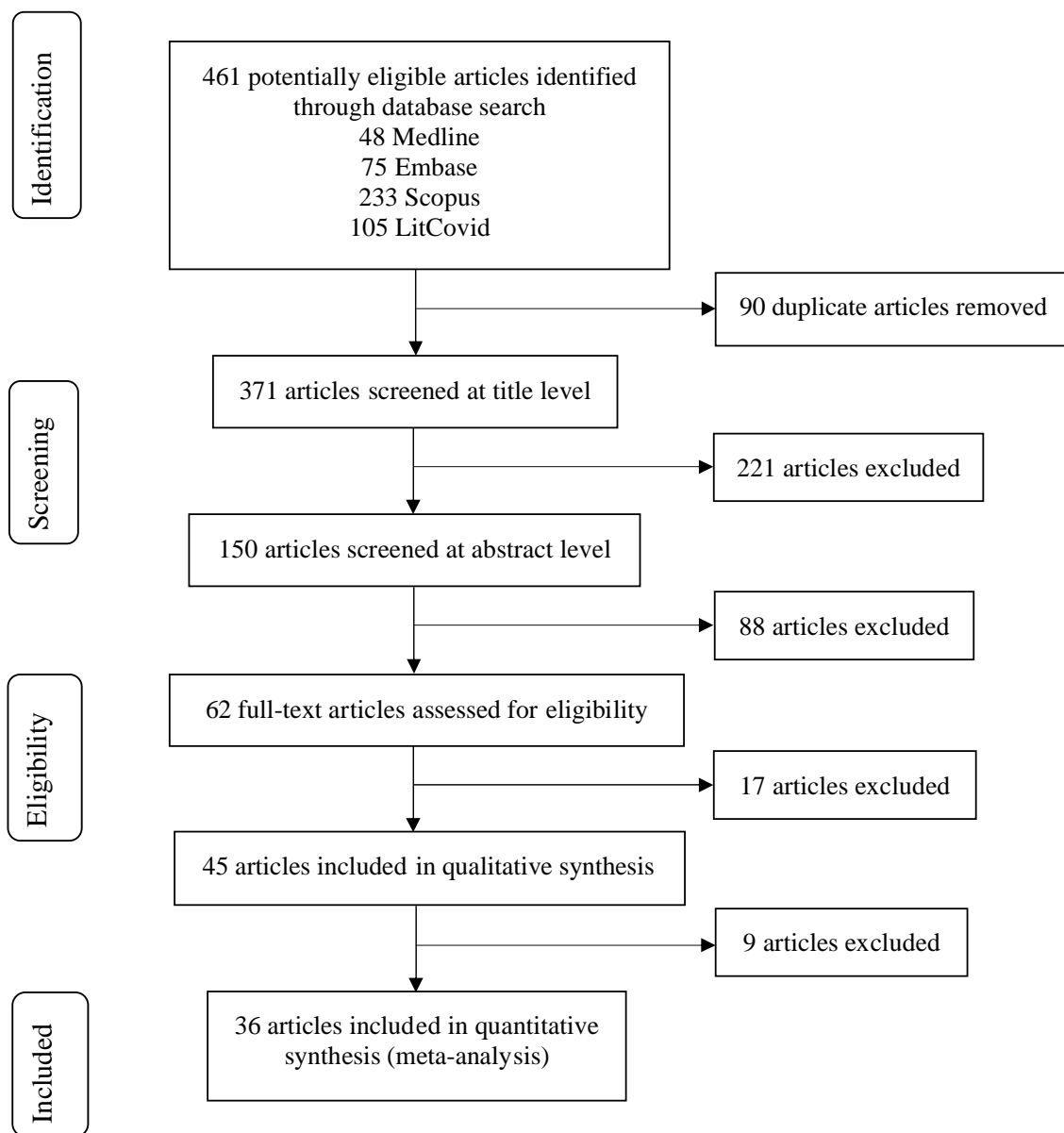
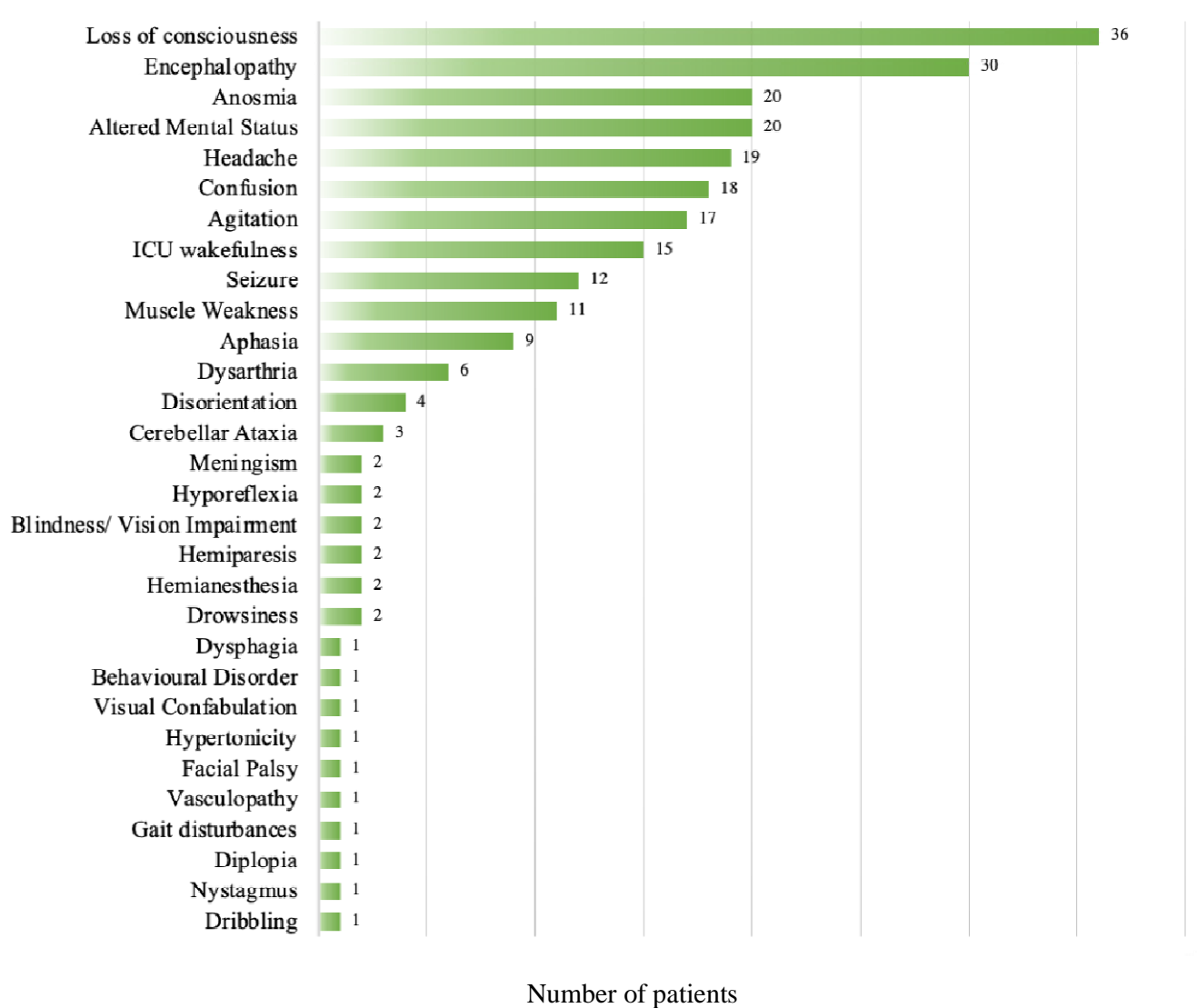


Fig 2. Frequency of COVID-19 relate symptomology



References

1. Grant MC, Geoghegan L, Arbyn M, et al. The Prevalence of Symptoms in 24,410 Adults Infected by the Novel Coronavirus (SARS-CoV-2; COVID-19): A Systematic Review and Meta-Analysis of 148 Studies from 9 Countries. *PLOS One* 2020.
2. Struyf T, Deeks JJ, Dinnes J, et al. Signs and symptoms to determine if a patient presenting in primary care or hospital outpatient settings has COVID-19 disease. *Cochrane Database of Syst. Rev* 2020.
3. Aghagoli G, Gallo Marin B, Katchur NJ, Chaves-Sell F, Asaad WF, Murphy SA. Neurological Involvement in COVID-19 and Potential Mechanisms: A Review. *Neurocrit. Care* 2020.
4. Ellul M, Benjamin L, Singh B, et al. Neurological Associations of COVID-19. *Lancet Neurol.* 2020.
5. Mao L, Jin H, Wang M, et al. Neurologic manifestations of hospitalized patients with coronavirus disease 2019 in Wuhan, China. *JAMA neurol.* 2020; 77(6): 683-90.
6. Varatharaj A, Thomas N, Ellul MA, et al. Neurological and neuropsychiatric complications of COVID-19 in 153 patients: a UK-wide surveillance study. *Lancet Psych.* 2020.
7. Radmanesh A, Derman A, Lui YW, et al. COVID-19 -associated Diffuse Leukoencephalopathy and Microhemorrhages. *Radiology* 2020: 202040.
8. Kremer S, Lersy F, de Seze J, et al. Brain MRI Findings in Severe COVID-19: A Retrospective Observational Study. *Radiology* 2020: 202222.
9. Organisation WH. WHO Coronavirus Disease (COVID-19) Dashboard. 2020. https://covid19.who.int/?gclid=CjwKCAjw5p_8BRBUEiwAPpJO69lnKPMRdb3On_ahlySYGEZrl3pFy6vDGuruxjAyEczZIB_Rug2UehoCnVQQA_vD_BwE.
10. Katal S, Balakrishnan S, Gholamrezanezhad A. Neuroimaging findings in COVID-19 and other coronavirus infections: a systematic review in 116 patients. *J Neuroradiol* 2020.
11. Martinez-Ramirez S, Greenberg SM, Viswanathan A. Cerebral microbleeds: overview and implications in cognitive impairment. *Alzheimer's Res. Ther.* 2014; 6(3): 33.
12. Pantoni L, Fierini F, Poggesi A. Thrombolysis in acute stroke patients with cerebral small vessel disease. *Cerebrovasc. Dis.* 2014; 37(1): 5-13.
13. Wardlaw JM, Valdés Hernández MC, Muñoz-Maniega S. What are white matter hyperintensities made of? Relevance to vascular cognitive impairment. *J. Am. Heart Assoc.* 2015; 4(6).

14. DeBette S, Markus H. The clinical importance of white matter hyperintensities on brain magnetic resonance imaging: systematic review and meta-analysis. *Bmj* 2010; 341.
15. Yang K, Feng Y, Mu J, Fu N, Chen S, Fu Y. The presence of previous cerebral microbleeds has a negative effect on hypertensive intracerebral hemorrhage recovery. *Front. Aging Neurosci.* 2017; 9: 49.
16. Fitsiori A, Pugin D, Thieffry C, Lalive P, Vargas MI. Unusual Microbleeds in Brain MRI of Covid-19 Patients. *J. Neuroimaging* 2020.
17. Cannac O, Martinez-Almoyna L, Hraiech S. Critical illness-associated cerebral microbleeds in COVID-19 acute respiratory distress syndrome. *Neurology* 2020; 95(11): 498-9.
18. Scullen T, Keen J, Mathkour M, Dumont AS, Kahn L. Coronavirus 2019 (COVID-19)-Associated Encephalopathies and Cerebrovascular Disease: The New Orleans Experience. *World Neurosurg.* 2020.
19. Poudel GR, Dominguez D JF, Verhelst H, et al. Network diffusion modeling predicts neurodegeneration in traumatic brain injury. *Ann. Clin. Transl. Neurol.* 2020; 7(3): 270-9.
20. Poudel GR, Harding IH, Egan GF, Georgiou Karistianis N. Network spread determines severity of degeneration and disconnection in Huntington's disease. *Hum. Brain Mapp.* 2019; 40(14): 4192-201.
21. Hawes S, Innes CRH, Parsons N, et al. Sleeping While Awake: The Intrusion of Neural Activity Associated with Sleep Onset in the Awake Human Brain. *bioRxiv* 2020.
22. Liberati A, Altman DG, Tetzlaff J, et al. The PRISMA statement for reporting systematic reviews and meta-analyses of studies that evaluate health care interventions: explanation and elaboration. *J. Clin. Epidemiol.* 2009; 62(10): 1-34.
23. NITRC. IIT Human Brain Atlas (v.5.0). 2019. <https://www.nitrc.org/projects/iit>.
24. AnalysisGroup. FMRIB Software Library v6.0. 2020. <https://fsl.fmrib.ox.ac.uk/fsl/>.
25. NITRC. MRICroGL. 2020. <https://www.nitrc.org/projects/mricrogl>.
26. Inc T. MATLAB 2018a. *Natick, Massachusetts: The MathWorks Inc* 2018.
27. Whitfield-Gabrieli S, Nieto-Castanon A. CONN Functional connectivity toolbox. NITRC.
28. Pandya S, Zeighami Y, Freeze B, et al. Predictive model of spread of Parkinson's pathology using network diffusion. *Neuroimage* 2019; 192: 178-94.
29. Abdel-Mannan O, Eyre M, Löbel U, et al. Neurologic and Radiographic Findings Associated With COVID-19 Infection in Children. *JAMA neurol.* 2020.

30. Afshar H, Yassin Z, Kalantari S, et al. Evolution and resolution of brain involvement associated with SARS- CoV2 infection: A close Clinical – Paraclinical follow up study of a case. *Mult. Scler. Relat. Disord.* 2020; 43.
31. Anand P, Al-Faraj A, Sader E, et al. Seizure as the presenting symptom of COVID-19: a retrospective case series. *E&B* 2020; 112.
32. Aragao MFVV, Leal MC, Cartaxo Filho OQ, Fonseca TM, Valenca MM. Anosmia in COVID-19 Associated with Injury to the Olfactory Bulbs Evident on MRI. *AJNR Am. J. Neuroradiol.* 2020.
33. Bonardel C, Bonnerot M, Ludwig M, et al. Bilateral Posterior Cerebral Artery Territory Infarction in a SARS-Cov-2 Infected Patient: discussion about an unusual case. *J. Stroke Cerebrovasc. Dis.* 2020; 29(9).
34. Collange O, Tacquard C, Delabranche X, et al. Coronavirus Disease 2019: Associated Multiple Organ Damage. *Open Forum Infect. Dis.* 2020; 7(7).
35. De Stefano P, Nencha U, De Stefano L, Mégevand P, Seeck M. Focal EEG changes indicating critical illness associated cerebral microbleeds in a Covid-19 patient. *Clin. Neurophysiol.* 2020; 5: 125-9.
36. Dixon L, Varley J, Gontsarova A, et al. COVID-19-related acute necrotizing encephalopathy with brain stem involvement in a patient with aplastic anemia. *Neurol. Neuroimmunol. Neuroinflamm.* 2020; 7(5).
37. Doo FX, Kassim G, Lefton DR, Patterson S, Pham H, Belani P. Rare presentations of COVID-19: PRES-like leukoencephalopathy and carotid thrombosis. *Clin. Imaging* 2020; 69: 94-101.
38. Frisullo G, Bellavia S, Scala I, et al. Stroke and COVID19: Not only a large-vessel disease. *J. Stroke Cerebrovasc. Dis.* 2020; 29(10).
39. Hanafi R, Roger PA, Perin B, et al. COVID-19 Neurologic Complication with CNS Vasculitis-Like Pattern. *AJNR Am. J. Neuroradiol.* 2020.
40. Hernandez-Fernandez F, Valencia HS, Barbella-Aponte RA, et al. Cerebrovascular disease in patients with COVID-19: neuroimaging, histological and clinical description. *Brain* 2020.
41. Kandemirli SG, Dogan L, Sarikaya ZT, et al. Brain MRI findings in patients in the intensive care unit with COVID-19 infection. *Radiology* 2020: 201697.
42. Krett JD, Jewett GAE, Elton-Lacasse C, et al. Hemorrhagic encephalopathy associated with COVID-19. *J. Neuroimmunol.* 2020; 346.

43. Lang M, Buch K, Li MD, et al. Leukoencephalopathy Associated with Severe COVID-19 Infection: Sequela of Hypoxemia? *Am. J. Neuroradiol* .2020.
44. Novi G, Rossi T, Pedemonte E, et al. Acute disseminated encephalomyelitis after SARS-CoV-2 infection. *Neurol. Neuroimmunol. Neuroinflamm.* 2020; 7(5).
45. Mahboob S, Boppana SH, Rose NB, Beutler BD, Tabaac BJ. Large vessel stroke and COVID-19: Case report and literature review. *eNeurologicalSci* 2020; 20: 100250.
46. Morassi M, Bagatto D, Cobelli M, et al. Stroke in patients with SARS-CoV-2 infection: case series. *Journal of Neurol.* 2020: 1.
47. Moriguchi T, Harii N, Goto J, et al. A first case of meningitis/encephalitis associated with SARS-Coronavirus-2. *Int. J. Infect. Dis.* 2020; 94: 55-8.
48. Nepal P, Batchala PP, Songmen S, Parashar K, Sapire J. An unresponsive COVID-19 patient. *Emergency radiology* 2020.
49. Parauda SC, Gao V, Gewirtz AN, et al. Posterior reversible encephalopathy syndrome in patients with COVID-19. *Journal of the Neurological Sciences* 2020.
50. Politi LS, Salsano E, Grimaldi M. Magnetic Resonance Imaging Alteration of the Brain in a Patient With Coronavirus Disease 2019 (COVID-19) and Anosmia. *JAMA Neurol.* 2020.
51. Poyiadji N, Shahin G, Noujaim D, Stone M, Patel S, Griffith B. COVID-19-associated Acute Hemorrhagic Necrotizing Encephalopathy: CT and MRI Features. *Radiology* 2020.
52. Rogg J, Baker A, Tung G. Posterior reversible encephalopathy syndrome (PRES): Another imaging manifestation of COVID-19. *Interdisciplinary Neurosurgery: Advanced Techniques and Case Management* 2020; 22.
53. Rudilosso S, Esteller D, Urra X, Chamorro A. Thalamic perforating artery stroke on computed tomography perfusion in a patient with coronavirus disease 2019. *J. Stroke Cerebrovasc. Dis.* 2020; 29(8).
54. Shoskes A, Migdady I, Fernandez A, Ruggieri P, Rae-Grant A. Cerebral Microhemorrhage and Purpuric Rash in COVID-19: The Case for a Secondary Microangiopathy. *J. J. Stroke Cerebrovasc. Dis.* 2020; 29(10).
55. Soldatelli MD, Amaral LFD, Veiga VC, Rojas SSO, Omar S, Marussi VHR. Neurovascular and perfusion imaging findings in coronavirus disease 2019: Case report and literature review. *Neuroradiol. J.* 2020.
56. Wong PF, Craik S, Newman P, et al. Lessons of the month 1: A case of rhombencephalitis as a rare complication of acute COVID-19 infection. *Clin. Med.* 2020.

57. Zhang T, Rodricks MB, Hirsh E. COVID-19-Associated acute disseminated encephalomyelitis: a case report. *MedRxiv* 2020.
58. Zoghi A, Ramezani M, Roozbeh M, Darazam IA, Sahraian MA. A case of possible atypical demyelinating event of the central nervous system following COVID-19. *Mult. Scler. Relat. Disord.* 2020; 44
59. Kandel ER, Schwartz JH, Jessell TM, et al. Principles of neural science: Principles of Neural Science. *Ion channels.* 2000;4:5.
60. Payus AO, Lin CLS, Noh MM, Jeffree MS, Ali RA. SARS-CoV-2 infection of the nervous system: A review of the literature on neurological involvement in novel coronavirus disease (COVID-19). *Bosn. J. Basic Med. Sci.* 2020.
61. Edlow BL, Takahashi E, Wu O, et al. Neuroanatomic connectivity of the human ascending arousal system critical to consciousness and its disorders. *J. Neuropathol. Exp. Neurol.* 2012; 71(6): 531-46.
62. Schiff ND. Central thalamic contributions to arousal regulation and neurological disorders of consciousness. *Ann. N. Y. Acad. Sci.* 2008; 1129(1): 105-18.
63. Ding J, Sigurðsson S, Jónsson PV, et al. Space and location of cerebral microbleeds, cognitive decline, and dementia in the community. *Neurology* 2017; 88(22): 2089-97.
64. Wang Y, Jiang Y, Suo C, et al. Deep/mixed cerebral microbleeds are associated with cognitive dysfunction through thalamocortical connectivity disruption: The Taizhou Imaging Study. *NeuroImage: Clin.* 2019.
65. DosSantos MF, Devalle S, Aran V, et al. Neuromechanisms of SARS-CoV-2: A Review. *Front. Neuroanat.* 2020.
66. Baig AM, Khaleeq A, Ali U, Syeda H. Evidence of the COVID-19 virus targeting the CNS: tissue distribution, host–virus interaction, and proposed neurotropic mechanisms. *ACS Chem. Neurosci.* 2020; 11(7): 995-8.
67. Brann DH, Tsukahara T, Weinreb C, et al. Non-neuronal expression of SARS-CoV-2 entry genes in the olfactory system suggests mechanisms underlying COVID-19-associated anosmia. *Sci. Adv.* 2020.
68. Chen R, Yu J, Wang K, et al. The spatial and cell-type distribution of SARS-CoV-2 receptor ACE2 in human and mouse brain. *BioRxiv* 2020.
69. Román GC, Spencer PS, Reis J, et al. The neurology of COVID-19 revisited: A proposal from the Environmental Neurology Specialty Group of the World Federation of Neurology to implement international neurological registries. *J. Neurol. Sci.* 2020.

70. Varga Z, Flammer AJ, Steiger P, et al. Endothelial cell infection and endotheliitis in COVID-19. *The Lancet* 2020; 1417-8.
71. Destras G, Bal A, Escuret V, Morfin F, Lina B, Josset L. Systematic SARS-CoV-2 screening in cerebrospinal fluid during the COVID-19 pandemic. *The Lancet Microbe* 2020.
72. Moriguchi T, Harii N, Goto J, et al. A first case of meningitis/encephalitis associated with SARS-Coronavirus-2. *Int. J. Infect. Dis.* 2020.
73. Guillan M, Villaceros-Alvarez J, Bellido S, et al. Unusual simultaneous cerebral infarcts in multiple arterial territories in a COVID-19 patient. *Thromb. Res.* 2020: 107-9.
74. Becker RC. COVID-19 update: Covid-19-associated coagulopathy. *Thromb. Res.* 2020: 1-14.
75. Al-Samkari H, Karp Leaf RS, Dzik WH, et al. COVID and Coagulation: Bleeding and Thrombotic Manifestations of SARS-CoV2 Infection. *Blood* 2020.
76. Franchini M, Marano G, Cruciani M, et al. COVID-19-associated coagulopathy. *Diagnosis* 2020.
77. Reed GL, Houg AK, Wang D. Microvascular thrombosis, fibrinolysis, ischemic injury, and death after cerebral thromboembolism are affected by levels of circulating α 2-antiplasmin. *Arterioscler. Thromb. Vasc. Biol.* 2014; 34(12): 2586-93.
78. Fanou EM, Coutinho JM, Shannon P, et al. Critical illness-associated cerebral microbleeds. *Stroke* 2017; 48(4): 1085-7.
79. Rasmussen C, Niculescu I, Patel S, Krishnan A. COVID-19 and Involvement of the Corpus Callosum: Potential Effect of the Cytokine Storm? *AJNR. Am. J. Neuroradiol.* ; 41(9): 1625-8.
80. Riech S, Hellen P, Moerer O, et al. Microhemorrhages in the corpus callosum after treatment with extracorporeal membrane oxygenation. *Critical Care* 2015; 19(S1): P277.
81. Schommer K, Kallenberg K, Lutz K, Bärtsch P, Knauth M. Hemosiderin deposition in the brain as footprint of high-altitude cerebral edema. *Neurology* 2013; 81(20): 1776-9.
82. Starkey J, Kobayashi N, Numaguchi Y, Moritani T. Cytotoxic lesions of the corpus callosum that show restricted diffusion: mechanisms, causes, and manifestations. *Radiographics* 2017; 37(2): 562-76.
83. Vattoth S, Abdelhady M, Alsoub H, Own A, Elsotouhy A. Critical illness-associated cerebral microbleeds in COVID-19. *Neuroradiol. J.* 2020.
84. Bailey DM, Bärtsch P, Knauth M, Baumgartner RW. Emerging concepts in acute mountain sickness and high-altitude cerebral edema: from the molecular to the morphological. *Cell. Mol. Life. Sci.* 2009; 66(22): 3583-94.

85. Liu P, Blet A, Md P, Smyth D, Li H, Md P. The Science Underlying COVID-19: Implications for the Cardiovascular System. *Circulation* 2020; 142(1): 68-78.
86. Markus H, Lythgoe D, Ostegaard L, O'sullivan M, Williams S. Reduced cerebral blood flow in white matter in ischaemic leukoaraiosis demonstrated using quantitative exogenous contrast based perfusion MRI. *J. Neurol. Neurosur. Ps.* 2000; 69(1): 48-53.
87. Tuttle C, Boto J, Martin S, et al. Neuroimaging of acute and chronic unilateral and bilateral thalamic lesions. *Insights into Imaging* 2019; 10(1): 24.
88. Wang Y, Liu G, Hong D, Chen F, Ji X, Cao G. White matter injury in ischemic stroke. *Prog. in neurobiol.* 2016; 141: 45-60.
89. Dalby RB, Eskildsen SF, Videbech P, et al. Oxygenation differs among white matter hyperintensities, intersected fiber tracts and unaffected white matter. *Brain Commun.* 2019.
90. Morris Z, Whiteley WN, Longstreth WT, Jr., et al. Incidental findings on brain magnetic resonance imaging: systematic review and meta-analysis. *BMJ* 2009.

Funding disclosure:

None

Conflicts of Interest:

None