Automated measurement of the foveal avascular zone in healthy eyes on Heidelberg Spectralis Optical Coherence Tomography Angiography

Laura Gutierrez-Benitez MD FEBO[1], Yolanda Palomino MD[1], Noe Casas[2]

[1] Ophthalmology department. Consorci Sanitari de Terrassa. Terrassa, Barcelona, Spain

[2] Polytechnic University of Catalonia. Barcelona, Spain

Correspondence:

Laura Gutierrez-Benitez

e-mail: laura.gutierrez.benitez@gmail.com

ABSTRACT

Purpose

Develop and evaluate an automated method to measure the foveal avascular zone (FAZ) area in healthy eyes on Heidelberg Spectralis Optical Coherence Tomography Angiography (HS-OCTA). This method is referred to as the modified Kanno-Saitama macro (mKSM).

Methods

This cross-sectional study included 29 eyes of 25 healthy volunteers who underwent HS-OCTA at the macular area twice at the same time. Regardless of the quality of the images, all of them were included. Macular data on the superficial vascular plexus, intermediate capillary plexus and deep capillary plexus were processed by mKSM. The FAZ area was measured twice automatically using the mKSM and twice manually by two independent examiners.

Results

Intrascan intraclass coefficient ranged from 0,948 to 0,993 for manual measurements and was 1 for mKSM method. Interscan intraclass coefficients ranged from 0,925 to 0,973 for manual measurements and from 0,770 to 0,902 for mKSM method. Despite that the difference between human examiners is smaller than between human examiners and mKSM according to Bland-Altman plots, the scatterplots show a strong correlation between human and automatic measurements. The best results are obtained in intermediate capillary plexus.

Conclusions

Automated determination of the FAZ area in HS-OCTA is feasible and less human-dependent by mKSM even if the image is not perfectly centred or has artefacts. The mKSM processing could contribute to our understanding of the three vascular plexuses.

Keywords: Heidelberg Spectralis, optical coherence tomography angiography, automated measurement, foveal avascular zone, intermediate capillary plexus

INTRODUCTION

Optical coherence tomography angiography (OCTA) has been a significant advance for the visualization of retinal vascularization, without being an invasive test since it does not require intravenous contrast injection, offering results comparable to those obtained with fluorescein angiography (1)(2)(3)(4). The use of OCTA provides high-quality images that can be obtained quickly and reproducibly. It enables the evaluation of multiple retinal pathologies in clinical practice, particularly underlying macular vascular diseases affecting the foveal avascular zone (FAZ) (5).

Earlier studies have reported that the FAZ area size varies significantly among healthy eyes and that it is influenced by age, gender, axial length, spherical equivalent, retinal vascular density, central macular thickness and choroidal thickness (6) (7) (8) (9). Besides, several ischemic pathologies such as diabetic retinopathy and retinal venous occlusion modify its characteristics (10)(11). Glaucoma with central visual field defects has also been reported to cause an enlarged FAZ area (12)(13)(14).

The OCTA FAZ measurement techniques have advanced in recent years (15) evaluating the characteristics of the FAZ area, either in healthy patients or in different pathologies. The main types of OCTA that are commonly used today are spectral-domain OCTA (SD-OCTA) and swept-source OCTA (SS-OCTA). Several studies have shown comparable results between the two types of devices in terms of FAZ area measurements (16)(17).
There are OCTA devices that incorporate embedded software that automatically measures the FAZ area, such as AngioVue OCTA (Optovue, Inc, Fremont, CA) or the SS-OCTA (Plex Elite 9000, Carl Zeiss Meditec Dublin, CA). Some other devices, such as Heidelberg Spectralis OCTA (HS-OCTA), do not incorporate this kind of software. Therefore, the FAZ area has to be measured manually in HS-OCTA (18).

Traditionally, the FAZ area was measured on the fluorescein angiography images where it was not possible to separate the different vascular plexuses. Nowadays, the OCTA enables 3D imaging of retinochoroidal vasculature with high spatial resolution, and the different plexus can be segmented. Therefore, HS-OCTA shows the microvasculature of three distinct retinal vascular layers where the FAZ area can be measured independently on the superficial vascular plexus (SVP), the intermediate capillary plexus (ICP) and the

deep capillary plexus (DCP). These microvascular layers correlate with anatomical structures(19).

The objective of our study is to develop and evaluate an automated method to measure the SVP, ICP and DCP FAZ area in HS-OCTA images, which provides objectivity, reproducibility, speed in measurements and is tolerant with images not perfectly centred or with artefacts. The automated measurements are compared to manual measurements made by two examiners.

To our knowledge, there are no previous studies that evaluate an automated method for FAZ area measurements in images acquired by HS-OCTA that is tolerant with images of suboptimal quality, which is a common situation in daily practice.

METHODS

SUBJECTS

The current study is a cross-sectional study. Healthy patients were recruited from Consorci Sanitari de Terrassa (Terrassa, Barcelona, Spain) from November 2019 to January 2020. The study was conducted following the ethical standards stated in the 1964 Declaration of Helsinki and approved by the Consorci Sanitari de Terrassa Research Ethics Committee.

Subjects were included if they were 18 years or older, not affected by any ophthalmological pathology, with best-corrected visual acuity of 20/20 or better and signed an informed consent form between November 2019 and January 2020.

The exclusion criteria were as follows: any history or clinical evidence of systemic or ocular diseases, refractive error higher than +3.0 diopters or less than -6.0 diopters, axial length exceeding 26 mm, any previous laser treatment, cataract surgery during the previous three months, and media opacities precluding adequate fundus imaging.

EYE EXAMINATIONS

All subjects underwent a thorough ophthalmic examination that included best-corrected visual acuity (BCVA), slit-lamp biomicroscopy and intraocular pressure measurement by Goldman contact tonometry. Axial length was measured with optical biometer IOL Master 500 (Carl Zeiss Meditec, Germany). Optical coherence tomography and OCTA images were performed with enhanced depth imaging methods for all patients using

Heidelberg Spectralis optical coherence tomography (Software Version 6.12.1, Heidelberg Engineering, Heidelberg, Germany).

Pathological history and cardiovascular risk factors such as diabetes mellitus, arterial hypertension, cardiovascular disease, dyslipidaemia and smoking were also recorded.

OPTICAL COHERENCE TOMOGRAPHY ANGIOGRAPHY

A 10º x 10º (2,9 x 2,9mm) OCTA image centred on the fovea was scanned using HS-OCTA (Software Version 6.12.1, Heidelberg Engineering, Heidelberg, Germany). En face images were acquired in High-Resolution mode, which offers a lateral resolution of 5.7 microns per pixel for the visualization of capillaries and an axial resolution of 3,9 microns per pixel that enables precise multilayer segmentation and visualization of the retinal vascular plexuses.

The HS-OCTA software generates en face images from slabs at different layers by automated segmentation, following the slab definitions proposed by Campbell et al. (20). Therefore, the superficial vascular plexus (SVP) slab is segmented as the retinal nerve fibre layer to the inner plexiform layer. The intermediate capillary plexus (ICP) is segmented between the outer 20% of the ganglion cell complex to the inner 50% of the inner nuclear layer (INL). The deep capillary plexus (DCP) is segmented between the outer 50% of the INL to the outer plexiform layer.

IMAGE PROCESSING

Our proposed automatic foveal area estimation method relies on two previous works.

The first work on which our method relies is the processing tool AngioTool software version 0.6a (02.18.14) (21), which automates the processing of OCTA images, detecting and enhancing the vascular network.

The second work on which our method relies is a study by Ishi et al. (22), where the authors proposed and evaluated a macro-based automated analysis method called Kanno-Saitama Macro (KSM) to measure the FAZ area using ImageJ software. The study concluded that this automated method was comparable to manual measurement, saving time and being less user-dependent. The KSM method is specific to the SS-OCTA equipment (Plex Elite 9000, Version 1.6.0.21130; Carl Zeiss Meditec Dublin, CA).

Our work, referred to as modified KSM or mKSM from now on, improves over KSM on the tolerance to visual artefacts and uncentered images and extends its applicability to the HS-OCTA equipment. For that, mKSM first takes an OCTA image and applies the

processing from AngioTool, obtaining a cleaner version of the vascular network image. Then, mKSM estimates the centre of the foveal area by computing the centre of mass of the image pixels, taking the pixel brightness value as its mass. Detecting the centre of the foveal area instead of assuming that it is located at the centre of the image, grants mKSM tolerance to uncentered OCTA images. Once the centre of the foveal area has been estimated, mKSM applies a random 2D shift to it and computes the foveal area by means of the KSM approach. This measure is repeated 20 times, with different values for the random 2D shift of the foveal area centre. The final area is computed by taking the median value of all the previous measures (to deterministically obtaining the same result for an input OCTA image, we use a fixed sequence of random numbers). This area sampling process, together with the median, grants mKSM tolerance to visual artefacts in the foveal area. In KSM, such artefacts were misidentified for the fovea itself. The median of the area sample allows discarding such misidentifications because they result in outliers in the estimated area distribution (see figure 1). mKSM is implemented as an extension to the scientific imaging tool ImageJ.

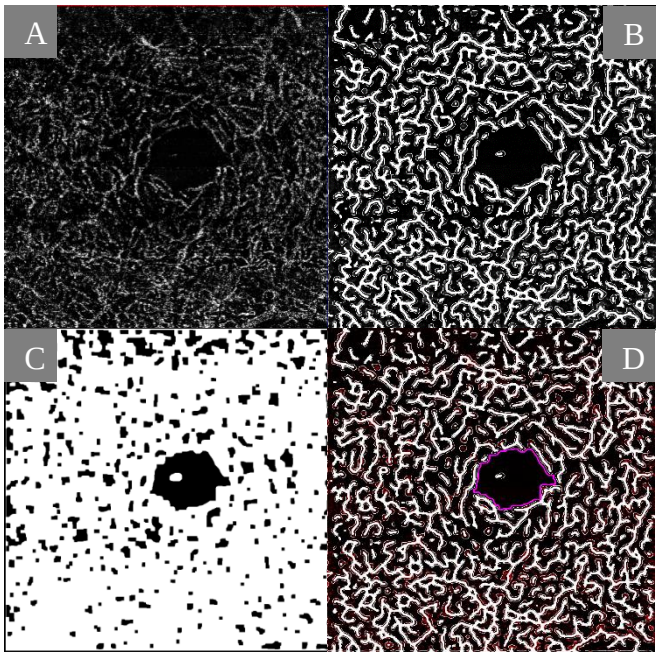

Figure 1. Optical coherence tomography angiography scan not perfectly centred and with artefacts (A) processed by angioTool (B) and by mKSM (C). The foveal avascular zone area is drawn pink on the angioTool image (E).

MANUAL MEASUREMENTS

The OCTA images were imported in the scientific image processing tool ImageJ. The scale parameter of the software was set to define a 964-pixel width in the images as 2,96mm. The manual measurements were performed by two masked examiners (YP and LG) who independently drew the FAZ area contour joining the internal points of the vessels on all the images. The FAZ area was measured in square millimetres.

TESTING PROTOCOL

All subjects were scanned in the morning twice on the same day at the same time. All the images were measured twice by both examiners and mKSM method to calculate the intrascan reproducibility. Interscan reproducibility was calculated using the first measurements obtained in the first and second scans for both examiners and mKSM method.

STATISTICAL ANALYSES

IBM® SPSS® Statistics 25.0 and MedCalc Version 19.3.1 are used for all statistical analyses. The data for quantitative variables are expressed as the mean value and standard deviation (SD). The data for qualitative variables are expressed as an absolute number and relative frequency. Intra and interscan reproducibilities are summarized as the intraclass correlation coefficient (ICC) and the coefficient of variation (CV) between measurements, respectively. Scatterplots are used to show the relationship of each measurement such as examiner 1, examiner 2 and mKSM method. Paired t-test and Bland-Altman plots are used to compare the differences between the measurements of the FAZ area among the three methods and the three plexuses. Statistical significance was defined as $p<0.05$.

RESULTS

29 eyes of 25 healthy volunteers were included in the analysis. Thus, mKSM could be tested in real-life images, none of the images was excluded, although not all of them had good quality. From 174 images, 96 were not perfectly centred and 24 had artefacts.

The mean age of the subjects was 36,6 years-old (SD 11,8), all of them were Caucasian and 64% were women. Eight patients had a history of smoking, but none had diabetes mellitus, hypertension, dyslipidaemia or cardiovascular disease. The best-corrected visual

acuity was 20/20±0, the 72,4% were right eyes, 96,6% eyes were phakic, and the mean axial length was 23,62±0,82 mm.

Intra and Interscan Reproducibility of the FAZ Area

Table 1 shows the intra and interscan reproducibility of the FAZ area for both examiners and mKSM for the plexus SVP, ICP and DCP separately. Globally, intrascan intraclass coefficient ranged from 0,948 to 0,993 for manual measurements and was 1 for mKSM method. Interscan intraclass coefficients ranged from 0,925 to 0,973 for manual measurements and from 0,770 to 0.902 for mKSM method.

Table 1. Intra and Interscan Reproducibility of Foveal Avascular Zone Area

		Intra-Scan			Inter-Scan		
Method	Plexus	FAZ area mm^2	ICC	CV	FAZ area mm^2	ICC	CV
Manual (Examiner 1)	SVP	Examination 1: 0,420±0,122	0,954 (0,902-0,978)	9,06 (6,54-11,63)	Scan 1: 0,420±0,122	0,960 (0,914-0,981)	8,55 (6,18-10,98)
		Examination 2 0,432±0,116			Scan 2: 0,418±0,117		
	ICP	Examination 1: 0,304±0,091	0,997 (0,992-0,999)	2,97 (2,16-3,78)	Scan 1: 0,304±0,091	0,985 (0,968-0,993)	5,37 (3,90-6,87)
		Examination 2 0,309±0,091			Scan 2: 0,308±0,091		
	DCP	Examination 1: 0,415±0,112	0,944 (0,869-0,975)	9,14 (6,60-11,74)	Scan 1: 0,415±0,112	0,908 (0,804-0,957)	11,73 (8,45-15,12)
		Examination 2 0,436±0,118			Scan 2: 0,421±0,103		
Manual (Examiner 2)	SVP	Examination 1 0,376±0,102	0,989 (0.962-0.996)	4,08 (2,97-5,21)	Scan 1: 0,376±0,102	0,944 (0,881-0,974)	8,80 (6,36-11,30)
		Examination 2 0,364±0,099			Scan 2: 0,372±0,089		
	ICP	Examination 1 0,287±0,086	0,998 (0.996-0.999)	1,92 (1,40-2,45)	Scan 1: 0,287±0,086	0,990 (0,980-0,995)	4,52 (3,29-5,78)
		Examination 2 0,286±0,087			Scan 2: 0,290±0,088		
	DCP	Examination 1 0,369±0,099	0,990 (0.979-0.996)	4,20 (3,06-5,37)	Scan 1: 0,369±0,099	0,895 (0,777-0,951)	12,74 (9,16-16,44)
		Examination 2 0,363±0,101			Scan 2: 0,386±0,088		
mKSM	SVP	Examination1: 0,423±0,115	1 (1-1)	0	Scan 1: 0,423±0,115	0,730 (0,437-0,872)	16,89 (12,09-21,90)
		Examination2: 0,423±0,115			Scan 2: 0,461±0,159		
	ICP	Examination1: 0,233±0,086	1 (1-1)	0	Scan 1: 0,233±0,086	0,950 (0,893-0,977)	11,65 (8,39-15,01)
		Examination2: 0,233±0,086			Scan 2: 0,232±0,087		
	DCP	Examination1: 0,451±0,139	1 (1-1)	0	Scan 1: 0,451±0,139	0,657 (0,260-0,840)	22,38 (15,91-29,21)
		Examination2: 0,451±0,139			Scan 2: 0,459±0,172		

Abbreviations: *Values of the foveal avascular zone (FAZ) area are expressed as mean ± standard deviation; ICC, intraclass correlation coefficient; CV, coefficient of variation; SVP, superficial vascular plexus; ICP, intermediate capillary plexus; DCP, Deep capillary plexus.*

Differences among the measurements

Figures 2, 3 and 4 show the differences among measurements between both human examiners (1 and 2) and mKSM for SVP, ICP and DCP FAZ areas. The mean difference and the 95% limits of agreement for each comparison are shown in Bland-Altman plots for every plexus. The results of the paired t-tests betwen the FAZ areas among the three methods show that the human measures of both examiners cannot be considered to belong to the same distribution (p=0,173 for examiner 1 vs mKSM; p=0,010 for examiner 2 vs mKSM; and p=0,000 for examiner 1 vs 2). This suggests that statistical hypothesis testing is not a suitable tool for assessing the quality of the measures of mKSM. Bland-Altman plots show that the the difference between human examiners is smaller than between human examiners and mKSM, besides the scatterplots show a strong correlation between human and automatic measurements.

The best results are obtained in ICP, although the FAZ area measurement is systematically smaller. This error could be palliated by a specific post-processed for ICP to force similar results to the human examiners. In this study, the processing of OCTA images has been the same for the three plexuses to make the processing plexus independent.

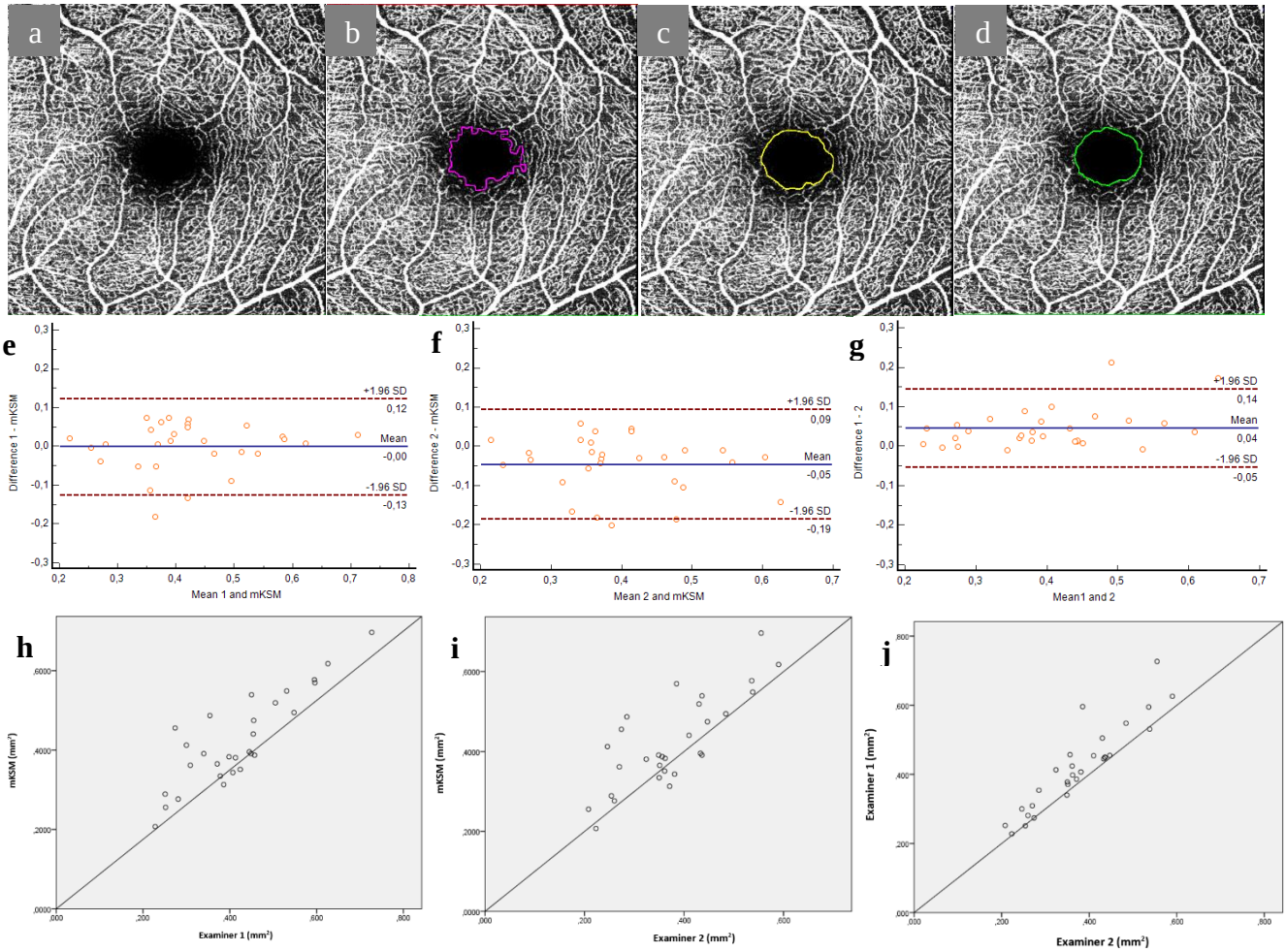

Figure 2. Optical coherence tomography angiography scan (a) showing the superficial vascular plexus. Foveal avascular zone area outlined by mKSM (b), examiner 1 (c) and examiner 2 (d). Below, Bland-Altman plots (e-g) and scatterplots showing the linear agreement (h-j) of the superficial vascular plexus foveal avascular zone measured by two examiners (1 and 2) and mKSM.

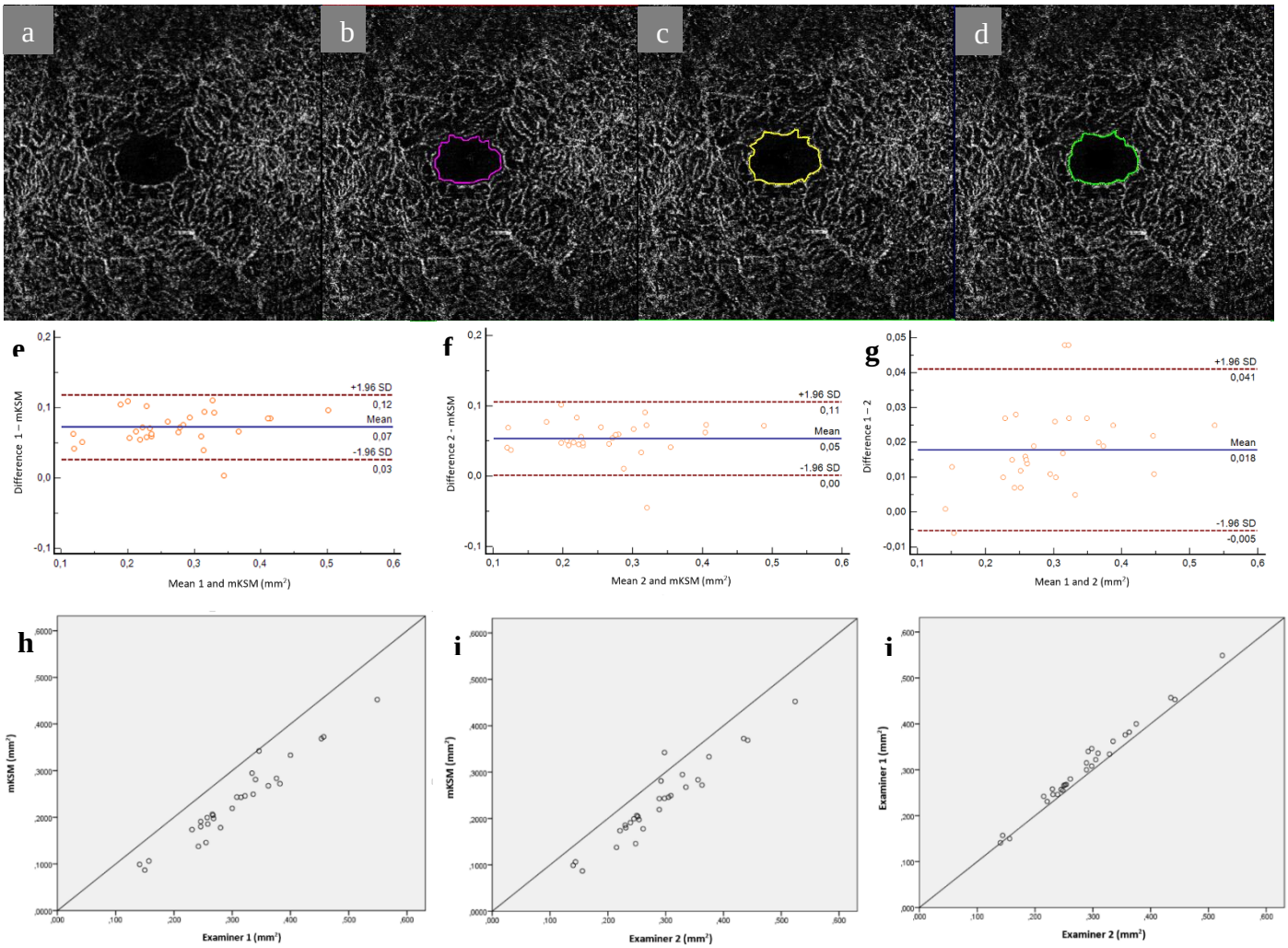

Figure 3. Optical coherence tomography angiography scan (a) showing the intermediate capillary plexus. Foveal avascular zone area outlined by mKSM (b), examiner 1 (c) and examiner 2 (d). Below, Bland-Altman plots (e-g) and scatterplots showing linear agreement (h-j) of the intermediate capillary plexus foveal avascular zone measured by two examiners (1 and 2) and mKSM.

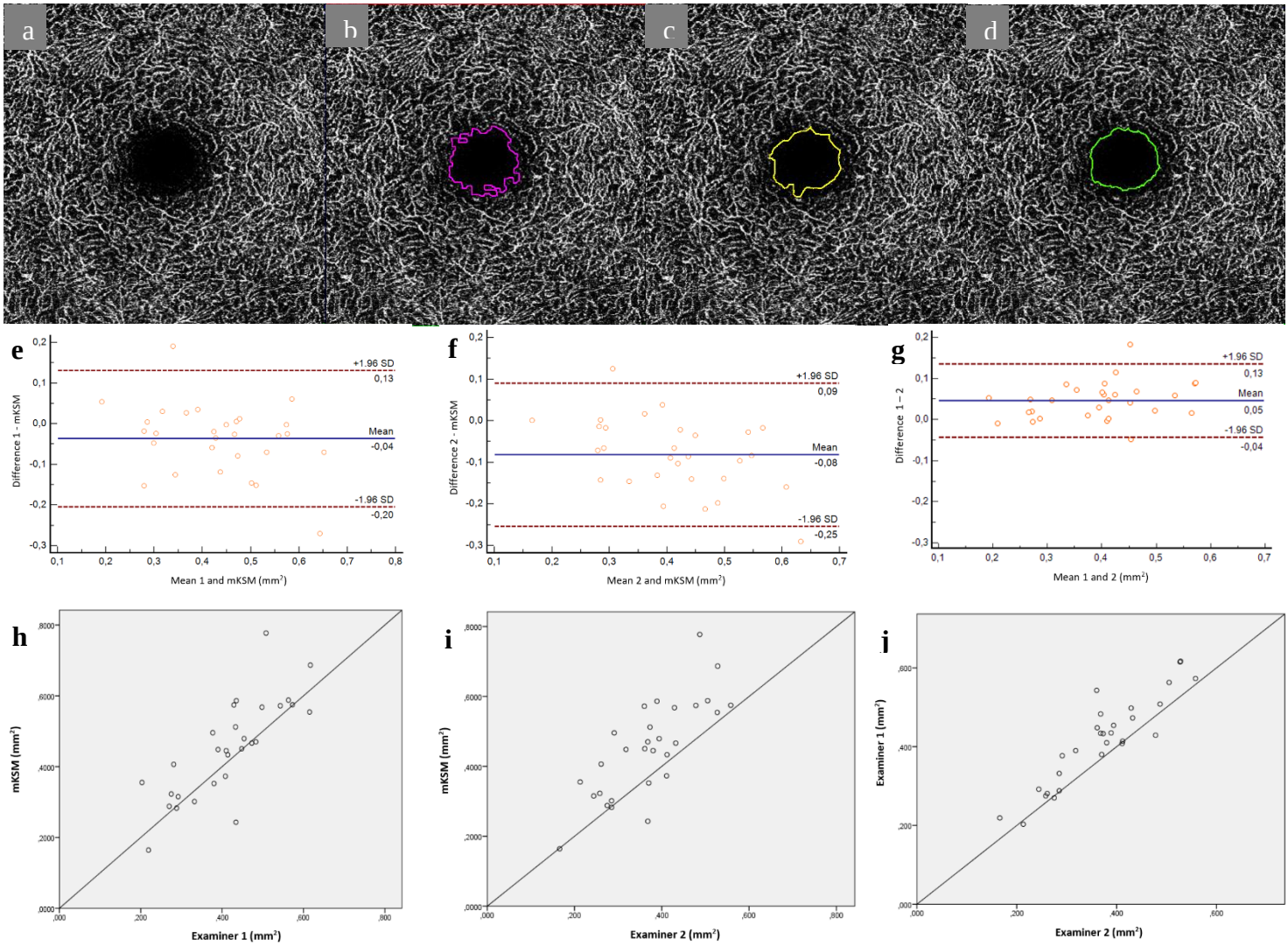

Figure 4. Optical coherence tomography angiography scan (a) showing the deep capillary plexus. Foveal avascular zone area outlined by mKSM (b), examiner 1 (c) and examiner 2 (d). Below, Bland-Altman plots (e-g) and scatterplots showing linear agreement (h-j) of the deep capillary plexus foveal avascular zone measured by two examiners (1 and 2) and mKSM.

<u>Published literature</u>

Table 2 summarizes the HS-OCTA studies where the FAZ area of healthy patients was measured. Only Lupidi et al. (23) used a semiautomated method to measure the FAZ area, while the others measured it manually (19)(24)(25). The mean SVP, ICP and DCP FAZ area results of the current study are similar to Hosari et al. (19) and somewhat larger than Pilotto et al. (24). The results of the current study are not comparable to Lupidi et al. (23) or Mihailovic et al. (25) because in the first one they used a prototype for the acquisition of the images and in the second one the images acquired had a worse resolution.

Table 2. Comparison of Heidelberg Spectralis studies						
STUDY (year)	IMAGING METHOD	NUMBER OF EYES	PATIENTS STATUS	PATIENTS AGE (years)	MEASUREMENT METHOD	MEAN FAZ AREA ± SD (mm^2)
Current study (2020)	Heidelberg Spectralis (Lateral resolution: 5,7µm/pixel)	29	Healthy	36,6 ±11,8	Automated Manual Manual Automated Manual Manual Automated Manual Manual	SVP 0,423±0,115 0,420±0,122 0,376±0,102 ICP 0,233±0,0860, 0,304±0,091 0,287±0,086 DCP 0,451±0,139 0,415±0,112 0,369±0,099
Hosari et al (2019)	Heidelberg Spectralis (Lateral resolution: 5,7µm/pixel)	23	Healthy	26.8 ± 6	Manual	SVP 0,42±0,23 ICP 0,28±0,1 DCP 0,44±0,12
Lupidi et al (2016)	Prototype based on Heidelberg Spectralis (Lateral resolution: 6µm/pixel)	47	Healthy	39 (19 –66)	Semiautomated	SVP 0.28 ± 0.11 DCP 0.30 ± 0.10
Mihailovic et al (2018)	Heidelberg Spectralis (Lateral resolution: 14µm/pixel)	24	Healthy	30.58± 12.11	Manual	SVP 0.329± 0.095 DCP 0.335±0.093
Pilotto et al (2018)	Heidelberg Spectralis (Lateral resolution: 6µm/pixel)	33	Healthy	26 ± 3	Manual	SVP 0.30 ± 0.08 DCP 0.35 ± 0.08
Abbreviations: *Values of the foveal avascular zone (FAZ) area are expressed as mean ± standard deviation;SVP, superficial vascular plexus; ICP, intermediate capillary plexus; DCP, Deep capillary plexus.*						

Study limitations

In the current study, there are some limitations. On the one hand, the proband group is not very large, and the patients are young and healthy, so the results may not be suitable for older patients or with ocular pathologies, which should be needed for additional studies. On the other hand, only 2,9x2,9 mm scans of HS-OCTA were used, so our results could be not applicable for wider scans or OCTA images acquired with other devices.

DISCUSSION

HS-OCTA (Software Version 6.12.1, Heidelberg Engineering, Heidelberg, Germany) does not have embedded software that automatically measures the FAZ area. Therefore, we developed and evaluated an automated method to measure the FAZ area that relies on the processing tool angioTool and the scientific image processing tool ImageJ. This method is referred to as mKSM.

The use of the mKSM method for the measurement of the FAZ area implies more reliability, reproducibility and speed in measurements compared to human manual

measurements. While a human examiner takes about 1 minute to measure the FAZ area manually and its value changes with each measurement, the mKSM takes less than 3 seconds and its value is always the same for the same OCTA image.

Moreover, the mKSM is tolerant to images that are not perfectly centred or with artefacts, while the original Kanno-Saitama macro(22) only used images perfectly centred and without artefacts. This tolerance makes mKSM usable for images from the real world that could be acquired in a regular clinic.

The mKSM processing is plexus independent, besides the best results are obtained in ICP, although specifically in this plexus, the FAZ area measurement is systematically smaller compared to human examiners. This error could be palliated by a specific post-processed for ICP if needed.

Note that this study evaluates the proposed method in all OCTA images taken, without excluding bad quality images or images with discrepancies in the foveal area measures by different specialists. These results are expected to be worse quantitatively than other studies where the image sample has been biased in any of the previously mentioned directions.

In conclusion, automated determination of the FAZ area in HS-OCTA is feasible and less human-dependent by mKSM even if the image is not perfectly centred or has artefacts. There is variability among manual FAZ measurements by humans and among manual measurements and mKSM, although this variability is smaller in ICP FAZ area. mKSM method could contribute to our understanding of the three vascular plexuses, and could be used as a basis for future FAZ area processing.

ACKNOWLEDGMENTS

This research received no specific grant from any funding agency in the public, commercial, or not-for-profit sectors.

DECLARATION OF CONFLICTING INTERESTS

The authors declare that there is no conflict of interests related to this work. Laura Gutierrez-Benitez has collaborated as a consultant for Alcon Healthcare, S.A. and Bayer Hispania, S.L.

REFERENCES

1. Werner JU, Böhm F, Lang GE, et al. Comparison of foveal avascular zone between optical coherence tomography angiography and fluorescein angiography in patients with retinal vein occlusion. PLoS One. 2019 Jun 1;14(6).
2. Mochi T, Anegondi N, Girish M, et al. Quantitative comparison between optical coherence tomography angiography and fundus fluorescein angiography images: Effect of vessel enhancement. Ophthalmic Surg Lasers Imaging Retin. 2018 Nov 1;49(11):E175–81.
3. Soares M, Neves C, Marques IP, et al. Comparison of diabetic retinopathy classification using fluorescein angiography and optical coherence tomography angiography. Br J Ophthalmol. 2017 Jan 1;101(1):62–8.
4. Garcia JM, Lima TT, Louzada RN, et al. Diabetic Macular Ischemia Diagnosis: Comparison Between Optical Coherence Tomography Angiography and Fluorescein Angiography. J Ophthalmol. 2016;2016.
5. Spaide RF, Fujimoto JG, Waheed NK, et al. Optical coherence tomography angiography. Vol. 64, Progress in Retinal and Eye Research. Elsevier Ltd; 2018. p. 1–55.
6. Zhou Y, Zhou M, Gao M, et al. Factors Affecting the Foveal Avascular Zone Area in Healthy Eyes among Young Chinese Adults. Biomed Res Int. 2020;2020.
7. Yu J, Jiang C, Wang X, et al. Macular perfusion in healthy chinese: An optical coherence tomography angiogram study. Investig Ophthalmol Vis Sci. 2015;56(5):3212–7.
8. Tan CS, Lim LW, Chow VS, et al. Optical coherence tomography angiography evaluation of the parafoveal vasculature and its relationship with ocular factors. Investig Ophthalmol Vis Sci. 2016 Jul 1;57(9):OCT224–34.
9. Fujiwara A, Morizane Y, Hosokawa M, et al. Factors affecting foveal avascular zone in healthy eyes: An examination using swept-source optical coherence tomography angiography. PLoS One. 2017 Nov 1;12(11).
10. Yu DY, Cringle SJ, Su EN. Intraretinal oxygen distribution in the monkey retina and the response to systemic hyperoxia. Investig Ophthalmol Vis Sci. 2005 Dec;46(12):4728–33.
11. Gómez-Ulla F, Cutrin P, Santos P, et al. Age and gender influence on foveal avascular zone in healthy eyes. Exp Eye Res. 2019 Dec 1;189.
12. Tang FY, Ng DS, Lam A, et al. Determinants of Quantitative Optical Coherence Tomography Angiography Metrics in Patients with Diabetes. Sci Rep. 2017 Dec 31;7(1):2575.
13. Koulisis N, Kim AY, Chu Z, et al. Quantitative microvascular analysis of retinal venous

occlusions by spectral domain optical coherence tomography angiography. PLoS One. 2017 Apr 1;12(4).

14. Kwon J, Choi J, Shin JW, et al. Alterations of the foveal avascular zone measured by optical coherence tomography angiography in glaucoma patients with central visual field defects. Investig Ophthalmol Vis Sci. 2017 Mar 1;58(3):1637–45.

15. Zheng Y, Gandhi JS, Stangos AN, et al. Automated segmentation of foveal avascular zone in fundus fluorescein angiography. Investig Ophthalmol Vis Sci. 2010 Jul;51(7):3653–9.

16. Al-Sheikh M, Falavarjani KG, Tepelus TC, et al. Quantitative Comparison of Swept-Source and Spectral-Domain OCT Angiography in Healthy Eyes. Ophthalmic Surgery, Lasers Imaging Retin. 2017 May 1;48(5):385–91.

17. Anegondi N, Kshirsagar A, Mochi TB, et al. Quantitative comparison of retinal vascular features in optical coherence tomography angiography images from three different devices. Ophthalmic Surg Lasers Imaging Retin. 2018 Jul 1;49(7):488–96.

18. Corvi F, Pellegrini M, Erba S, et al. Reproducibility of Vessel Density, Fractal Dimension, and Foveal Avascular Zone Using 7 Different Optical Coherence Tomography Angiography Devices. Am J Ophthalmol. 2018 Feb 1;186:25–31.

19. Hosari S, Hohberger B, Theelke L, et al. OCT Angiography: Measurement of Retinal Macular Microvasculature with Spectralis II OCT Angiography-Reliability and Reproducibility. Ophthalmologica. 2020 Jan 1;243(1):75–84.

20. Campbell JP, Zhang M, Hwang TS, et al. Detailed Vascular Anatomy of the Human Retina by Projection-Resolved Optical Coherence Tomography Angiography. Sci Rep. 2017 Feb 10;7.

21. Zudaire E, Gambardella L, Kurcz C VS. A Computational Tool for Quantitative Analysis of Vascular Networks. PLoS One. 2011;6(11):e27385.

22. Ishii H, Shoji T, Yoshikawa Y, et al. Automated measurement of the foveal avascular zone in swept-source optical coherence tomography angiography images. Transl Vis Sci Technol. 2019 May 1;8(3).

23. Lupidi M, Coscas F, Cagini C, et al. Automated Quantitative Analysis of Retinal Microvasculature in Normal Eyes on Optical Coherence Tomography Angiography. Am J Ophthalmol. 2016 Sep;169:9–23.

24. Pilotto E, Frizziero L, Crepaldi A, et al. Repeatability and Reproducibility of Foveal Avascular Zone Area Measurement on Normal Eyes by Different Optical Coherence Tomography Angiography Instruments. Ophthalmic Res. 2018 Feb 8.

25. Mihailovic N, Brand C, Lahme L, et al. Repeatability, reproducibility and agreement of

foveal avascular zone measurements using three different optical coherence tomography angiography devices. Madigan M, editor. PLoS One. 2018 Oct 18;13(10):e0206045.