The Endothelial Dysfunction and Pyroptosis Driving the SARS-CoV-2 Immune-Thrombosis

Seigo Nagashima[1], Monalisa C. Mendes[2], Ana Paula C. Martins[3], Nicolas H. Borges[4], Thiago M. Godoy[4], Anna Flavia M. Ribeiro[1], Felipe S. Dezidério[1], Lucia de Noronha[5/*], Cleber Machado-Souza[6]

[1]Graduate students - School of Medicine - Postgraduate Program of Health Sciences Pontifícia Universidade Católica do Paraná (PUCPR). R. Imaculada Conceição, 1155 - Prado Velho, Curitiba, PR, Brazil.

[2]Graduate student - Postgraduate in Biotechnology Applied in Health of Children and Adolescent. Faculdades Pequeno Príncipe (FPP). Instituto de Pesquisa Pelé Pequeno Príncipe (IPPPP). R. Silva Jardim, 1632 - Água Verde, Curitiba, PR, Brazil.

[3]Laboratory of Experimental Pathology - School of Medicine - Pontifícia Universidade Católica do Paraná (PUCPR). R. Imaculada Conceição, 1155 - Prado Velho, Curitiba, PR, Brazil.

[4]Undergraduate students - School of Medicine - Pontifícia Universidade Católica do Paraná (PUCPR). R. Imaculada Conceição, 1155 - Prado Velho, Curitiba, PR, Brazil.

[5]Coordinator - Laboratory of Experimental Pathology - School of Medicine - Pontifícia Universidade Católica do Paraná (PUCPR). R. Imaculada Conceição, 1155 - Prado Velho, Curitiba, PR, Brazil.

[6]Professor - Postgraduate in Biotechnology Applied in Health of Children and Adolescent. Faculdades Pequeno Príncipe (FPP). Instituto de Pesquisa Pelé Pequeno Príncipe (IPPPP). R. Silva Jardim, 1632 - Água Verde, Curitiba, PR, Brazil.

***Correspondence author:**
Lucia de Noronha
Laboratório de Patologia Experimental
Tel: +55 (41) 3271-2264
Rua Imaculada Conceição, 1155 - Prado Velho Curitiba, Paraná, Brazil
E-mail: lnno.noronha@gmail.com

ABSTRACT

Objective: Endothelial activation after viral infection could contribute to changes in the vascular glycocalyx associated with programmed inflammatory cell death called pyroptosis. Thus, our goal is to recognize endothelial activation and pyroptosis in lung and myocardial samples of Coronavirus disease (COVID-19) cases and compare to H1N1pdm09 and control cases.

Approach and Results: Post-mortem lung (6 cases of COVID-19 group; 10 cases of H1N1 group and 11 cases of Control group) and myocardial samples (2 cases of COVID-19 and one control) were analyzed by conventional immunohistochemistry by using antibodies to identify molecules involving with endothelial activation (CD163, Interleukin-6 (IL-6), Tumor Necrosis Factor alpha (TNF-alpha), Intercellular Adhesion Molecule 1 (ICAM-1)) and pyroptosis (Caspase-1). As a result, IL-6, TNF-alpha, ICAM-1, and Caspase-1 show higher tissue expression in the COVID-19 group compared to H1N1 and Control groups.

Conclusion: Our results indicate that the vascular endothelium has been activated and the presence of pyroptosis and endothelial dysfunction in lung and myocardial samples. These conditions could lead to a systemic immune-thrombotic process that may impair the clinical staff's efforts to prevent fatal outcomes. One aim of the health professionals is to avoid COVID-19 systemic vascular injury and immune-thrombosis by blocking the endothelial dysfunction and its consequences.

INTRODUCTION

The outbreak of the disease (COVID-19) caused by the new coronavirus (SARS-CoV-2) was declared on January 30, 2020, by the World Health Organization (WHO) a Public Health Emergency of International Importance - the Organization's highest alert level,[1,2] and since then, the numbers of patients requiring intensive care treatment have been continuously increasing.

Following the injury in type 1 and 2 pneumocytes triggered by SARS-CoV-2 lung infection, an exponential release of inflammatory cytokines (cytokine storm), might be responsible for the alveolar-capillary endothelial activation. However, the endothelial cells also express ACE-2 type receptors,[3] thus alveolar-capillary endothelial activations may be exacerbated by the SARS-CoV-2 infection, after the damage of the alveolar epithelial barrier by viral injury.[4]

The lung capillary endothelium, acting as the quiescent barrier and gas exchange alveolar-capillary membrane, may switch after its activation to responsive inflammatory phenotype, expressing cytokines and vascular adhesion molecules that aggravate the cytokines storm,[5] and may lead to the immuno-thrombotic phenomena.[6]

The peculiar endothelial activation induced by SARS-CoV-2 differs from the other pandemic respiratory disease, such as H1N1pdm09 (caused by Influenza A virus H1N1 subtype) and could link the diffuse alveolar damage (DAD) with the severe systemic immune-thrombosis phenomenon caused by COVID-19. In addition to COVID-19 endothelial activation, the probable higher significant involvement of pyroptosis, in this pandemic disease, but not in H1N1pdm09, may drive the massive endothelial cell death contributing to thrombogenic mechanism.[7,8]

The hypothesis of this article is that, different from the H1N1pdm09 disease, the SARS-CoV-2 endothelial activation, followed by pyroptosis, may increase the pro-inflammatory stimuli leading COVID-19 pneumonia to a severe systemic disease that may impair the efforts of the clinical staff to prevent fatal outcomes. Viewed from the intensive care perspective, one aim is to avoid COVID-19 systemic vascular injury as a way to prevent the almost always lethal immune-thrombotic phenomena.

This study aimed to analyze endothelial activation and pyroptosis tissue biomarkers in patients who died with COVID-19 compared with cases of H1N1pdm09 and controls.

METHODS

Study population

Pandemic COVID-19 group comprise lung samples from *post mortem* biopsies of patients whose cause of death was SARS-CoV-2 diffuse alveolar damage during the 2020 outbreak. In patients 4 and 6, in addition to the lung, there are myocardium samples. Clinical data of six cases were obtained from medical records during hospitalization in the Intensive Care Unit (ICU) at Hospital Marcelino Champagnat in Curitiba-Brazil. The pandemic COVID-19 group (n=6) was approved by the National Research Ethics Committee (REC: 3.944.734/2020).

Pandemic H1N1 group (n=10) comprise lung samples from *post mortem* biopsies of patients whose cause of death was pandemic Influenza A virus H1N1 subtype severe acute respiratory infections during the 2009 outbreak (H1N1pdm09). Clinical data of all cases were obtained from medical records during hospitalization in the ICU at Hospital de Clínicas in Curitiba-Brazil (REC: 2.550.445/2018).

A Control group (n=11) was composed of the lung (n = 10) and myocardium (n = 1) samples from necropsies of patients who died due to other causes, not involving lung lesions.

Testing for pandemic H1N1 and SARS-CoV-2 was performed on nasopharyngeal swabs taken during ICU hospitalization, and real-time reverse transcriptase-polymerase chain reaction (rRT-PCR) was positive in all cases. Families consented to the post-mortem biopsy for the cases of COVID-19 and H1N1.

Immunohistochemical assays

Minimally invasive lung biopsy was performed through a left anterior mini-thoracotomy with upper left lobe lingular segment resection. The resected pieces were 3x3 cm.

The lung and heart samples provided by post-mortem biopsy/necropsies of all three groups were formalin-fixed paraffin-embedded (FFPE) and stained with hematoxylin and eosin (H&E) to find the proper areas for the immunohistochemical techniques. The FFPE lung samples were also performed by immunohistochemical reactions using primary monoclonal antibodies anti-CD163 (rabbit polyclonal, clone 14215, Thermo Fisher, 1:1000), IL-6 (mouse monoclonal, clone ab9324, Abcam, 1:400), TNF-alpha (rabbit polyclonal, clone ab6671, Abcam, 1:100), ICAM-1(mouse monoclonal, clone 23G12, Novocastra, 1:100) and Caspase-1 (rabbit polyclonal, ab189796, Abcam, 1:200).[9]

The macrophages score was made by scoring CD163+ cells in 30 high-power fields (HPF). The HPF was chosen randomly from the septum and lumen alveolar.

The lung tissue immune-slides of IL-6 (interleukin-6), TNF-alpha (tumor necrosis factor-alpha), and ICAM-1 (intercellular adhesion molecule 1) were scanned on the Axio Scan Scanner. Z1 (Carl Zeiss, Germany). Afterward, 10 HPF per case were selected. The measurement of positive areas took place through a semi-automatic segmentation method of quantification, using Image-Pro Plus software version 4.5 (Media Cybernetics, USA). Subsequently, these areas were converted into percentages to enable statistical analysis.

The semiquantitative analysis was made for Caspase-1 by the Allred score in the endothelium of all arteries of the samples. It was obtained by summing two scores

(proportion and intensity of positivity), ranging from 0 to 8. The proportion score is subdivided according to the percentage of stained cells: score 0 - 0% stained cells, score 1 - <1%, score 2 - 1-10%, score 3 - 11-33%, score 4 - 34-66% and score 5 - > 66%. While the intensity of positivity is evaluated: negative - score 0, weak - score 1, moderate - score 2, and strong - score 3.[10]

The three myocardium immune-slides (cases 4 and 6 of COVID-19 group and one control patient) were also analyzed by Allred score for CD163 (macrophages score), IL-6, TNF-alpha, ICAM-1, and Caspase-1.

Statistical analysis

Data were analyzed using the computer program The R Project for Statistical Computing and IBM® SPSS Statistics v.20.0 software.

RESULTS

The baseline characteristic of COVID-19 patients is presented in table 1. The lung samples immunohistochemical results in all groups can be observed in table 1 and figure 1. When comparing COVID-19 group with H1N1 group IL-6 (p=0.0652), TNF-alpha (p=0.0092), ICAM-1 and Caspase-1 (p=0.0009) presenting higher lung tissue expression (Figure 1). The same pattern can be observed when comparing COVID-19 with Control groups (Table 1). The immunohistochemical results of myocardial post-mortem biopsies/necropsy are resumed in table 1.

The COVID-19 group presented type 2 pneumocyte hyperplasia associated with hyaline membranes and mild septal thickness with lymphocytic infiltration and edema characterizing proliferative DAD. There are scarce septal and intra-alveolar neutrophils recruitment. It was observed numerous small fibrinous thrombi in small and medium pulmonary arteries following by neutrophilic endotheliitis and endothelial cell tumefaction. Signs of secondary bacterial pneumonia were not observed. However, the histopathological features of H1N1 DAD presented fewer hyaline membranes, but higher septal thickness, with massive septal lymphocytic infiltration and intra-alveolar neutrophils recruitment. There was no significant endothelial activation, fibrinous thrombi, and neutrophilic endotheliitis in H1N1 cases. Signs of bacterial coinfections were found in 8 cases.

The COVID-19 myocardial samples presented significant endothelial activation with endothelial cell tumefaction. There was severe intercellular edema surrounding each of the cardiomyocytes of COVID-19 patients, responsible for spacing the myocardial fibers. Lipofuscin pigment and mild signs of myocardial hyperplasia were present in almost all of cardiomyocytes in both control and COVID-19 patients (data not shown).

DISCUSSION

This study aimed to understand the context of the endothelial activation and pyroptosis in patients that died, after hospitalization, with COVID-19, as these aspects may have a possible influence on subsequent thrombogenic events.

Endothelial activation refers to the inability of the endothelium to regulate vascular homeostasis and mainly describes its imbalance in favor of the pro-inflammatory and prothrombotic effects.[11] Infection by SARS-CoV-2 would contribute to endothelial dysfunction and to the peculiar endothelial cell death called pyroptosis.[12] Thus, these two events could also trigger the subsequent immuno-thrombotic process that could have a significant impact on the mortality observed in COVID-19 patients.

The endothelium, without this activation process, provides the suitable luminal surface that does not promote the intrinsic coagulation cascade activation or platelet adhesion, but anticoagulant and fibrinolytic mechanisms.[13] Faced with the aggression of alveolar epithelial cells by SARS-CoV-2, the capillary-alveolar endothelial cells receive a rain of cytokines (IL-1, IL-6, TNF-alpha) promoting its activation and inducing ICAM-1 via the Nuclear factor-kappa-B (NFκB) pathway.[14-16] Thus, under these inflammatory conditions, a subset of leukocytes (polymorphonuclear leukocytes, macrophages, and mast cells)

degranulate enzymes that can contribute to the breakdown of the glycocalyx of endothelial cells.[17,18] The intact glycocalyx serves as a barrier against the platelets and leukocytes and the impairment of its function would lead to the endotheliitis and thrombotic events.[19-23]

The macrophages score (CD163+ cells) in the COVID-19 group could amplify the local pro-inflammatory involvement by an earlier recruit of the complement system. Following this pro-inflammatory pattern, the higher and continuous tissue expression of IL-6 and TNF-alpha in the COVID-19 group compared to H1N1 and Control groups (p=0.0652 and p=0.0049; p=0.0092 and p=0.0048 respectively) demonstrate that inflammatory stimulation may be kept active throughout the disease process. It is known that the cytokine profile of patients with SARS showed a marked increase of interferon-gamma, IL-1, IL-6, and IL-12, by at least two weeks after the onset of the disease.[24,25,26]

Comparing the COVID-19 with H1N1 or Control groups, the ICAM-1 tissue expression was significantly higher in the former (p=0.0034). An essential consequence of endothelial activation is the expression of adhesion molecules such the ICAM family. These molecules have the classic function of attracting leukocytes to the infected region and have the ability to transmit intracellular signals leading and keeping the pro-inflammatory status, thus perpetuating the innate immune response and subsequent promoting systemic activation of endothelial cells.[27,28] The continuous pro-inflammatory condition would result not only in the dysfunctional endothelium but also lead to the loss of its integrity by endothelial cells death.[29] The persistent inflammatory signaling of these adhesion molecules would also contribute to later thrombogenic effects. Patients 5 and 6 (respectively 23 and 38 days of survival) were those with the highest vascular tissue expression of ICAM-1, and this fact could be associated with severe thrombotic events that were seen in these cases.

The relationship between endothelial activation/dysfunction and subsequent thrombotic events is already well-known in cardiovascular diseases[30] and diabetes.[31,32] Five of our cases had already comorbidities (data not shown), such systemic arterial hypertension, dyslipidemia, diabetes, chronic kidney disease, and signs of chronic arterial disease. Thus, the permanent status of endothelial activation promoted by these comorbidities would aggravate endothelial dysfunction caused by viral inflammatory response and could be responsible for the most prevalent fatal outcome describe in these patients.[33] Suo et al.[34] showed that influenza A H1N1 virus is responsible for potentiating endothelial cell apoptosis in patients who already have atherosclerosis.

In this context, SARS-CoV-2 pneumocytes infection, besides, to have an essential role in inflammatory activation/dysfunction of endothelial cells, it also would lead to endothelial cell death, causing the discontinuity of the alveolar-capillary barrier, facilitating the virus to move from alveolar septum through the alveolar-capillary lumen. Thus, the endothelial cells already devoid of glycocalyx become a target for SARS-CoV-2 by ACE-2 binding, aggravating the endothelial damage.

It has been proposed that pyroptosis could contribute to the death of endothelial cells after SARS-CoV-2 infection.[35] Pyroptosis is an inflammatory form of programmed cell death.[36] A group of researchers found that SARS-CoV viral proteins can trigger the mechanism of cellular pyroptosis[37] and in another study, Middle East respiratory syndrome coronavirus (MERS-CoV) infected macrophages promote high pyroptotic biomarker expressions.[38]

The virus surface can hold a highly conserved molecular structure that can be recognized by the endothelial cells NOD-like receptors protein 3 (NLRP3). A multiprotein complex (Inflammasome) would form by the binding of the NLRP3, and Apoptosis-associated speck-like protein containing a caspase recruitment domain (ASC) and procaspase-1[39,40] would activate. This structure would result in the activation caspases-1 that would promote the maturation of pro-IL-1B, and pro-IL-18.[41] Gasdermin-D is another target of the proteolytic action of caspases-1[40-42], and the resulting fragments are oligomerized creating a perforation in the plasma membrane.[43] Given this, in the final phase of this prosses occurs the release of IL-1B and IL-18, cell edema and consequent cell disruption and death called pyroptosis.

The fragmentation resulting from pyroptosis would prevent the replication of pathogens[44-46], and the interleukin release would alert the immune system.

Our results show higher endothelial tissue expressions of Caspase-1 in the COVID-19 group than the H1N1 and Control groups (p=0.0009), suggesting the endothelial cell pyroptosis process promoting by SARS-CoV-2 endothelial infection.

The presence of the same pattern of tissue expression (COVID-19 patients with higher CD163, IL-6, ICAM-1, TNF-alpha, and Caspase-1 tissue expression than control patient) in the myocardial samples might suggest that endothelial dysfunction and pyroptosis mechanism could be more than a local lung process, but a systemic event.

It is known that thrombogenic conditions are quite characteristic in COVID-19[3] patients, and the presence of the endothelial dysfunction leads to considering the SARS-CoV-2 infection as a systemic disease triggered by the immuno-thrombotic response. Understanding the complex of events that can be part of immune-thrombosis mechanism might help the health professional to early identify patients with the potential of endothelial activation/dysfunction based on predisposing comorbidities and systemic biomarkers such D-dimer and Angiopoietin-2.[47] The early diagnosis of endothelial dysfunction could guide health professionals in implementing therapeutic anticoagulation, mitigating thrombogenic events, systemic inflammatory response syndrome (SIRS) and multiple organ failure. It also might be relevant to use pharmacological strategy focusing on endothelial stabilization in patients who already had some chronic type of endothelial activation such as chronic renal disease, diabetes, and hypertension. In conclusion, our findings lead us to suggest the involvement of endothelial activation processes and pyroptosis in a COVID-19. Both processes could be contributing to an immuno-thrombotic response in these patients. This immune-thrombosis event may have devastating clinical consequences with fatal outcome. The study's main limitations are the small number of cases (n=6)[4] and data based on FFPE post-mortem samples that can only provide a piece of static information at the time of the death and cannot reconstruct the evolving disease process.

Table 1. Comparative table between COVID-19, H1N1, and Control groups for gender, age, survival in days, mechanical ventilation in days, and immunohistochemical expression of endothelial dysfunction biomarkers.

Variables	COVID-19 (n=6)	H1N1 (n=10)	*p*-value*	Control (n=11)	*p*-value†
Gender	Male = 66.6% Female = 33.3%	Male = 80.0% Female = 20.0%		Male = 62,5% Female = 7,5%	
Age (years)[1]	76.5/80.5 (53-87)	43.5/44 (23-61)		42.3/45 (18-60)	
Survival (days)[1]	12.8/10 (2-32)	4.70/1.5 (1-19)		-----	
Mechanical ventilation[1]	9.7/8 (0-21)	4.70/1.5 (1-19)		-----	
CD163 score[1,2]	52.9 (14.4-87.8) 49.0±28.7	71.4 (37.1-71.4) 69.2±20.3	0.1931	31.5 (19.5-47.6) 31.7±8.2	0.3149
IL-6 lung tissue expression in percentage per HPF[1]	3.9 (0.3-7.6) 4.0±2.5	1.3 (0.7-3.1) 1.6±0.9	0.0652	0.0 (0.0-5.6) 0.6±1.6	0.0049
TNF-alpha lung tissue expression in percentage per HPF[1]	5.8 (3.2-35.3) 12.3±12.9	2.1 (0.1-4.9) 2.5±1.5	0.0092	2.2 (0.2-4.1) 1.9±1.5	0.0048
ICAM-1 lung tissue expression in percentage per HPF[1]	4.3 (1.4-20.6) 7.4±7.3	0.9 (0.0-3.3) 1.0±1.0	0.0034	0.4 (0.1-2.6) 0.8±0.8	0.0034
Caspase-1 Allred score[1]	8.0 (7.2-8.0) 7.8±0.3	4.5 (3.0-7.0) 4.8±1.2	0.0009	2.0 (2.0-4.0) 2.4±0.7	0.0009
CD163[3]	7[‡]	--		5[§]	
IL-6[3]	8[‡]	--		5[§]	
TNF-alpha[3]	7[‡]	--		6[§]	
ICAM-1[3]	8[‡]	--		3[§]	
Caspase-1[3]	8[‡]	--		3[§]	

Legends: [1]Average/Median (Min-Max); [2]mean number of CD163+ macrophages in 30 high power field (HPF). **p*-values obtained were compared between COVID-19 versus H1N1. [†]*p*-values obtained were compared between COVID-19 and Control group. [3]Allred score in myocardial samples. [‡]Myocardial samples of COVID-19 patients 4 and 6. [§]Control patient myocardial sample: female, 80 years old, hypertension, pulmonary thromboembolism after left knee arthroplasty. *p*-values were performed using the non-parametric Kruskal-Wallis test.

REFERENCES

1. Pan American Health Organization/World Health Organization. OPAS/OMS Brasil - Folha Informativa – COVID-19 (Doença Causada Pelo Novo Coronavírus). https://www.paho.org/bra/index.php?option=com_content&view=article&id=6101:covid19&Itemid=875. Accessed May 10, 2020.
2. Saúde Mda. Coronavírus: Brasil registra 58.509 casos e 4.016 mortes. Ministério da Saúde. https://www.saude.gov.br/noticias/agencia-saude/46789-coronavirus-brasil-registra-58-509-casos-e-4-016-mortes. Published April 25, 2020. Accessed May 10, 2020.
3. Varga Z, Flammer AJ, Steiger P, et al. Endothelial cell infection and endotheliitis in COVID-19. The Lancet. 2020;395(10234):1417-1418.

4. Ackermann M, Verleden SE, Kuehnel M, et al. Pulmonary Vascular Endothelialitis, Thrombosis, and Angiogenesis in Covid-19. New England Journal of Medicine. 2020.
5. Vita JA, Keaney JF. Endothelial Function. Circulation. 2002;106(6):640-642.
6. Hansson GK. Inflammation, Atherosclerosis, and Coronary Artery Disease. New England Journal of Medicine. 2005;352(16):1685-1695.
7. Wu X, Zhang H, Qi W, et al. Nicotine promotes atherosclerosis via ROS-NLRP3-mediated endothelial cell pyroptosis. Cell Death & Disease. 2018;9(2).
8. Tang Y-S, Zhao Y-H, Zhong Y, et al. Neferine inhibits LPS-ATP-induced endothelial cell pyroptosis via regulation of ROS/NLRP3/Caspase-1 signaling pathway. Inflammation Research. 2019;68(9):727-738
9. Claudia CVDS, Rosimeri KSB, Nayanne LCP, et al. Parkin protein expression and its impact on survival of patients with advanced colorectal cancer. Cancer Biology & Medicine. 2018;15(1):61.
10. Harvey JM, Clark GM, Osborne CK, Allred DC. Estrogen Receptor Status by Immunohistochemistry Is Superior to the Ligand-Binding Assay for Predicting Response to Adjuvant Endocrine Therapy in Breast Cancer. Journal of Clinical Oncology. 1999;17(5):1474-1474.
11. Xu J, Zou M-H. Molecular Insights and Therapeutic Targets for Diabetic Endothelial Dysfunction. Circulation. 2009;120(13):1266-1286.
12. Yang M. Cell Pyroptosis, a Potential Pathogenic Mechanism of 2019-nCoV Infection. SSRN Electronic Journal. 2020.
13. Gimbrone MA. Vascular Endothelium in Hemostasis and Thrombosis. Edinburgh, Indiana: Churchill Livingstone; 1986.
14. Pober JS, Cotran RS. The Role Of Endothelial Cells In Inflammation. Transplantation. 1990;50(4):537-544.
15. Pober JS, Cotran RS. Cytokines and endothelial cell biology. Physiological Reviews. 1990;70(2):427-451.
16. Pober JS, Sessa WC. Evolving functions of endothelial cells in inflammation. Nature Reviews Immunology. 2007;7(10):803-815.
17. Henry CBS, Duling BR. TNF-α increases entry of macromolecules into luminal endothelial cell glycocalyx. American Journal of Physiology-Heart and Circulatory Physiology. 2000;279(6).
18. Vanteeffelen JW, Brands J, Stroes ES, Vink H. Endothelial Glycocalyx: Sweet Shield of Blood Vessels. Trends in Cardiovascular Medicine. 2007;17(3):101-105.
19. Mulivor AW, Lipowsky HH. Role of glycocalyx in leukocyte-endothelial cell adhesion. American Journal of Physiology-Heart and Circulatory Physiology. 2002;283(4).
20. Reitsma S, Slaaf DW, Vink H, Van Zandvoort MAMJ, Egbrink MGAO. The endothelial glycocalyx: composition, functions, and visualization. Pflügers Archiv - European Journal of Physiology. 2007;454(3):345-359.
21. Becker BF, Chappell D, Bruegger D, Annecke T, Jacob M. Therapeutic strategies targeting the endothelial glycocalyx: acute deficits, but great potential. Cardiovascular Research. 2010;87(2):300-310.
22. Becker BF, Chappell D, Jacob M. Endothelial glycocalyx and coronary vascular permeability: the fringe benefit. Basic Research in Cardiology. 2010;105(6):687-701.
23. Gando S, Nanzaki S, Morimoto Y, Kobayashi S, Kemmotsu O. Tissue factor and tissue factor pathway inhibitor levels during and after cardiopulmonary resuscitation. Thromb Res. 1999;96(2):107-113.
24. Wong CK, Lam CWK, Wu AKL, et al. Plasma inflammatory cytokines and chemokines in severe acute respiratory syndrome. Clinical & Experimental Immunology. 2004;136(1):95-103.
25. Mehta P, Mcauley DF, Brown M, Sanchez E, Tattersall RS, Manson JJ. COVID-19: consider cytokine storm syndromes and immunosuppression. The Lancet. 2020;395(10229):1033-1034.
26. Theoharides TC. COVID -19, pulmonary mast cells, cytokine storms, and beneficial actions of luteolin. BioFactors. 2020.

27. Ross R, Glomset J. Studies of Primate Arterial Smooth Muscle Cells in Relation to Atherosclerosis. Advances in Experimental Medicine and Biology Arterial Mesenchyme and Arteriosclerosis. 1974:265-279.
28. Durieu-Trautmann O, Chaverot N, Cazaubon S, Strosberg AD, Couraud PO. Intercellular adhesion molecule 1 activation induces tyrosine phosphorylation of the cytoskeleton-associated protein cortactin in brain microvessel endothelial cells. J Biol Chem. 1994;269(17):12536-12540.
29. Woywodt A. Circulating endothelial cells: life, death, detachment and repair of the endothelial cell layer. Nephrology Dialysis Transplantation. 2002;17(10):1728-1730.
30. Gimbrone MA Jr, García-Cardeña G. Endothelial Cell Dysfunction and the Pathobiology of Atherosclerosis. Circ Res. 2016;118(4):620-636.
31. Xu J, Zou M-H. Molecular Insights and Therapeutic Targets for Diabetic Endothelial Dysfunction. Circulation. 2009;120(13):1266-1286.
32. Roberts AC, Porter KE. Cellular and molecular mechanisms of endothelial dysfunction in diabetes. Diabetes and Vascular Disease Research. 2013;10(6):472-482.
33. Kolářová H, Ambrůzová B, Šindlerová LŠ, Klinke A, Kubala L. Modulation of Endothelial Glycocalyx Structure under Inflammatory Conditions. Mediators of Inflammation. 2014;2014:1-17.
34. Suo J, Zhao L, Wang J, Zhu Z, Zhang H, Gao R. Influenza virus aggravates the ox-LDL-induced apoptosis of human endothelial cells via promoting p53 signaling. Journal of Medical Virology. 2015;87(7):1113-1123.
35. Yang M. Cell Pyroptosis, a Potential Pathogenic Mechanism of 2019-nCoV Infection. SSRN Electronic Journal. 2020.
36. Cookson BT, Brennan MA. Pro-inflammatory programmed cell death. Trends in Microbiology. 2001;9(3):113-114.
37. Chen I-Y, Moriyama M, Chang M-F, Ichinohe T. Severe Acute Respiratory Syndrome Coronavirus Viroporin 3a Activates the NLRP3 Inflammasome. Frontiers in Microbiology. 2019;10.
38. Jiang Y, Li J, Teng Y, et al. Complement Receptor C5aR1 Inhibition Reduces Pyroptosis in hDPP4-Transgenic Mice Infected with MERS-CoV. Viruses. 2019;11(1):39.
39. Fernandes-Alnemri T, Wu J, Yu JW, et al. The pyroptosome: a supramolecular assembly of ASC dimers mediating inflammatory cell death via caspase-1 activation. Cell Death Differ. 2007;14(9):1590-1604.
40. Wang S, Yuan Y-H, Chen N-H, Wang H-B. The mechanisms of NLRP3 inflammasome/pyroptosis activation and their role in Parkinson's disease. International Immunopharmacology. 2019;67:458-464.
41. He Y, Hara H, Núñez G. Mechanism and Regulation of NLRP3 Inflammasome Activation. Trends in Biochemical Sciences. 2016;41(12):1012-1021.
42. Fink SL, Cookson BT. Apoptosis, Pyroptosis, and Necrosis: Mechanistic Description of Dead and Dying Eukaryotic Cells. Infection and Immunity. 2005;73(4):1907-1916.
43. Kuang S, Zheng J, Yang H, et al. Structure insight of GSDMD reveals the basis of GSDMD autoinhibition in cell pyroptosis. Proceedings of the National Academy of Sciences. 2017;114(40):10642-10647.
44. Bergsbaken T, Fink SL, Cookson BT. Pyroptosis: host cell death and inflammation. Nature Reviews Microbiology. 2009;7(2):99-109.
45. Liu X, Zhang Z, Ruan J, et al. Inflammasome-activated gasdermin D causes pyroptosis by forming membrane pores. Nature. 2016;535(7610):153-158.
46. Shi J, Gao W, Shao F. Pyroptosis: Gasdermin-Mediated Programmed Necrotic Cell Death. Trends in Biochemical Sciences. 2017;42(4):245-254.
47. Smadja DM, Guerin CL, Chocron R, et al. Angiopoietin-2 as a marker of endothelial activation is a good predictor factor for intensive care unit admission of COVID-19 patients. Angiogenesis. 2020.

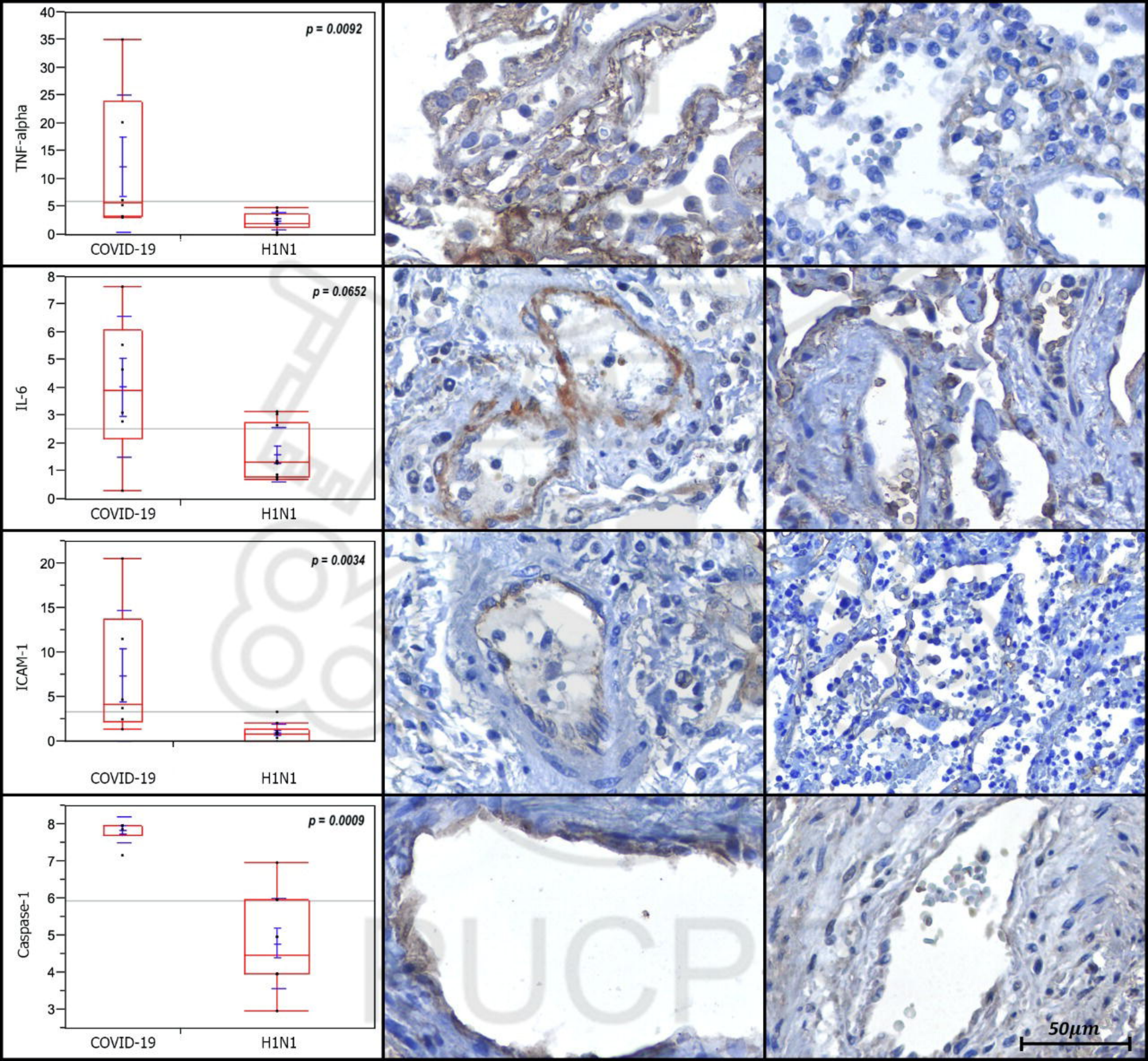
TNF-alpha
p = 0.0092
COVID-19
H1N1
IL-6
p = 0.0652
COVID-19
H1N1
ICAM-1
p = 0.0034
COVID-19
H1N1
Caspase-1
p = 0.0009
COVID-19
H1N1
50µm