

1 **Dupilumab-associated ocular surface disease: incidence, management and long-**
2 **term sequelae.**

3
4

5 Authors:

6 Magdalena Z Popiela^{1,4}, Ramez Barbara¹, Andrew M J Turnbull^{1,5}, Emma Corden¹,
7 Beatrice Suarez Matinez-Falero¹, Daniel O'Driscoll¹, Michael R Ardem-Jones^{1,3},
8 Parwez N Hossain^{1,2}
9 (Orcid ID: <https://orcid.org/0000-0002-3131-2395>)
10

11

12 Affiliations: ¹*Eye Unit, Southampton General Hospital, Southampton UK*

13 ²*Clinical Experimental Sciences, University of Southampton,*
14 *Southampton, UK*

15 ³*Dept of Dermatology, Southampton General Hospital, Southampton,*
16 *UK*

17 ⁴*Eye Unit, St Bernard's hospital, Gibraltar*

18 ⁵*Bournemouth Eye Unit, Royal Bournemouth Hospital, Bournemouth,*
19 *UK*

20

21 Running title: Dupilumab -associated ocular surface disease

22

23 Key words: dupilumab -associated conjunctivitis, cicatrizing conjunctivitis,
24 dupilumab- associated ocular surface disease

25

26

27 Corresponding Author:

28 Professor Parwez Hossain

29 Eye Unit,

30 University of Southampton

31 Southampton General Hospital

32 Tremona Road

33 Southampton

34 SO16 6YD

35 Email: parwez@soton.ac.uk

36 Tel: +44 23 8120 4270

37 **Abstract**

38

39 **Objective**

40 To determine the incidence of ocular surface disease in patients with atopic dermatitis
41 (AD) treated with dupilumab at a tertiary, university hospital. To describe the features
42 of dupilumab-associated ocular surface disease, establish the need for treatment and
43 report any long-term effects on the ocular surface.

44

45 **Methods**

46 A retrospective analysis of consecutive patients treated with dupilumab for AD
47 between January 2017 and August 2019 was undertaken. Data was collected on
48 demographics, incidence and type of ocular disease features, natural history and
49 treatment.

50

51 **Results**

52 50% (14/28) patients developed ocular symptoms with a mean time of onset of 6.75
53 (+/- 6.1) weeks from starting dupilumab. 69% of these (9/13) were diagnosed with
54 conjunctivitis - associated with cicatrisation in two patients and periorbital skin
55 changes in four. Of these nine, four had prior history of atopic keratoconjunctivitis.
56 All were treated with topical steroids; two required additional ciclosporin drops. 67%
57 (6/9) patients developed chronic ocular inflammation requiring maintenance drops at
58 a mean of 16 (+/- 6.9) months of follow up. All patients had improvement in their AD
59 severity; only one patient discontinued dupilumab due to ocular side effects.

60

61

62 **Conclusion**

63 The rate of dupilumab-associated ocular surface disease was 32%. Periorbital skin
64 changes and conjunctival cicatrisation were noted in association with conjunctivitis.
65 Ocular surface disease improved on topical steroids and ciclosporin but 67% of
66 patients needed on-going treatment. Patients should be referred to an ophthalmologist
67 prior to starting dupilumab as a large proportion develops chronic ocular
68 inflammation.

69

70

71 **Introduction**

72

73 Dupilumab is the first biologic approved for use in treatment of moderate to severe
74 atopic dermatitis (AD).¹⁻⁵ Dupilumab targets interleukin (IL)-4 receptor blocking IL-4
75 and IL-13 signalling pathway. It has also shown promise in treatment of asthma,
76 chronic rhinosinusitis with nasal polyposis and eosinophilic oesophagitis.^{1,2}

77

78 Dupilumab has been found to significantly improve signs and symptoms of AD and is
79 considered a safe treatment for long- term use.⁶ Conjunctivitis is a known side effect
80 with rates in initial trials varying between 8.6% (CHRONOS) to 28 % (LIBERTY AD
81 CAFÉ). Conjunctivitis is considered mild and self-limiting in the majority of cases,
82 with fewer than 0.5% of patients suffering with a severe form necessitating drug
83 cessation.²

84

85 Current International Eczema Council recommendations allow for dupilumab to be
86 started in patients with prior ocular surface disease and to continue dupilumab in the

87 event of conjunctivitis occurring.⁷ Prior history of ocular surface disease and more
88 severe AD are considered risk factors for the development of dupilumab-associated
89 conjunctivitis.^{8,9}
90
91 Since the start of clinical use, apart from self-limiting conjunctivitis other ocular
92 features have been described; severe follicular conjunctivitis^{10,11}, limbal nodules^{4,10},
93 blepharo-conjunctivitis¹⁰⁻¹³, cicatricial ectropion^{14,15}, keratitis¹⁰ and dry eyes¹⁶. This
94 has led to the use of the term dupilumab-associated ocular surface disease to
95 encompass various clinical presentations.^{8,9,15} A much higher incidence of ocular
96 surface problems has been reported in clinical practice than in the initial drug trials -
97 as high as 70% in one series.⁴ No data is available on the longer-term effects of
98 dupilumab on the ocular surface. Our study aimed to establish local incidence of
99 dupilumab-associated ocular surface disease, describe its features, establish the need
100 for treatment and identify any long-term sequelae.

101

102 **Methods**

103 The Health Research Authority and Health and Care Research Wales (HCRW)
104 approval was granted in November 2019 (19/HRA/5882) for a retrospective case
105 review of all patients developing dupilumab-associated eye disease at Southampton
106 General Hospital- a large tertiary referral centre in the United Kingdom.

107 Patients prescribed dupilumab between January 2017 and August 2019 were
108 identified from the severe atopic dermatitis clinic in the dermatology department.
109 Their details were checked in the electronic patient records to identify those who
110 attended ophthalmology clinics. Data for patients who developed eye symptoms was

111 collected retrospectively in February 2020 to allow for at least six months of
112 ophthalmic follow up. Presenting ocular symptoms, signs on initial review, treatment,
113 visual acuity at first and last follow up and any side effects of topical therapy were
114 noted. Long-term use of treatment was recorded. Eczema Severity and Index scores
115 (EASI) were recorded at pre-treatment and at 16 weeks post dupilumab initiation, as
116 well as the percentage of patients reaching 50 % and 75 % improvement in EASI at
117 16 weeks (EASI 50 and EASI 75 respectively).

118 **Statistics**

119 Because of only a few studies for reference, the study is classed as an exploratory
120 research study. Data was analysed using descriptive statistics using The SAMPL
121 Guidelines as reference ([https://www.equator-network.org/wp-](https://www.equator-network.org/wp-content/uploads/2013/03/SAMPL-Guidelines-3-13-13.pdf)
122 [content/uploads/2013/03/SAMPL-Guidelines-3-13-13.pdf](https://www.equator-network.org/wp-content/uploads/2013/03/SAMPL-Guidelines-3-13-13.pdf)) with the statistical tools
123 within Microsoft Excel 2014 (Microsoft Corp., Redmond, WA). Logistic regression
124 and Mann- Whitney U test were used to test for differences in demographic data
125 between patients with and without ocular symptoms. Statistical significance was
126 defined with a P value of equal to or less than 0.05. All statistical analyses were
127 performed using SPSS software (version 20.0, IBM Corp, Armonk, NY, USA).

128

129 **Results**

130

131 28 patients were prescribed dupilumab for AD between January 2017 and August
132 2019. 14 patients were referred to the ophthalmology department with symptoms of
133 bilateral eye redness, soreness, itching and epiphora with a mean time of onset of 6.75
134 (+/- 6.1) weeks from starting dupilumab. One patient was lost to follow up with the

135 remaining 13 cases seen in the ocular surface clinic under the care of the
136 ophthalmology department. There were no significant differences in demographic
137 characteristics of patients treated with dupilumab who developed ocular symptoms
138 and those who did not develop ocular symptoms.

139

140 Four patients seen in the ophthalmology department showed reduced tear break up
141 time (TBUT <10 seconds) with meibomian gland disease and were diagnosed as
142 having evaporative dry eyes without signs of conjunctivitis. They were prescribed
143 lubricating eye drops and given advice on lid hygiene. One patient received a course
144 of Maxitrol ointment for eyelid disease. They were excluded from further analysis.

145

146 Nine patients showed features of conjunctivitis on initial presentation with bilateral
147 marked conjunctival redness [Figure 1]. Six patients displayed bilateral conjunctival
148 papillary reaction and three had bilateral conjunctival follicular changes. Two patients
149 showed limbal nodules similar in appearance to Trantas dots at initial visit.

150

151 Two female patients, who were related, had associated conjunctival cicatrization in
152 the lower fornix and one showed scarring in the superior tarsal conjunctiva on initial
153 presentation. One of these patients went on to develop progressive cicatrization and a
154 leukoplakic lesion in the lower fornix, confirmed on biopsy as pre-cancerous actinic
155 keratosis with dysplasia [Figure 2].

156

157 Peri-ocular changes with cicatrizing ectropion, punctal stenosis and periocular
158 dermatitis were noted in four patients in association with conjunctivitis.

159

160 Mean time to development of self reported eye symptoms after the start of dupilumab
161 therapy in the conjunctivitis group was 6 +/- 5.5 weeks. Patients were seen in the
162 ocular surface clinic on average 8 +/- 5.2 weeks later. 44.4 % patients (4/9) had a past
163 history of atopic keratoconjunctivitis prior to receiving dupilumab. Their ocular
164 surface disease was stable at the time of dupilumab initiation with subsequent
165 development of new symptoms of conjunctivitis. None were receiving active
166 ophthalmic treatment at the time of starting dupilumab.

167

168 Initial treatment in the eye clinic for dupilumab-associated conjunctivitis included
169 topical steroids in all cases. Six patients received additional topical lubricant. Out of
170 nine patients presenting with conjunctivitis, seven had a good response to topical
171 steroids alone [Figure 3], two required additional topical ciclosporin 0.1% (Ikervis®,
172 Santen Pharmaceuticals) to control symptoms. One patient was prescribed tacrolimus
173 ointment to the eyelids by the dermatologist.

174

175 67% (6/9) patients were on maintenance topical steroid or steroid and ciclosporin
176 combination at a mean of 16 +/- 6.9 months follow up. Two of these six (33%) had a
177 prior history of atopic keratoconjunctivitis, which was quiescent at the time of starting
178 dupilumab. The remaining three patients used topical steroid for 3-12 months with
179 complete resolution of symptoms and signs of conjunctivitis.

180

181 We have not noted any changes in visual acuity from first to last visit; mean visual
182 acuity was recorded as 0.1 logMAR at both time points. No patients developed side
183 effects due to prescribed drops. All patients had an improvement in their Eczema
184 Area and Severity Index scores, with a 76% mean improvement in EASI score from

185 pre-treatment to 16 weeks follow-up in the conjunctivitis group. 89% of patients
186 achieved EASI 50 (50 % improvement in EASI score) and 55.6% achieved EASI 75
187 (75% improvement in EASI score).
188 One patient required additional therapy with methotrexate and one with topical
189 steroids. Dupilumab was discontinued in one patient due to severe conjunctivitis with
190 loss of eye-lashes (madarosis).

191

192 **Discussion**

193

194 Conjunctivitis is a known side effect of dupilumab, particularly affecting AD
195 patients.^{1,2} The LIBERTY AD CAFÉ study reported the highest incidence of
196 dupilumab -associated conjunctivitis amongst initial trials (28%), attributed to higher
197 awareness of this side effect amongst investigators.¹ The CAFÉ trial reported
198 conjunctivitis in 22.1% of patients, which was thought to be due to the high
199 percentage of participants with severe AD and prior atopic keratoconjunctivitis, both
200 of which are considered risk factors.^{8,9}

201

202 In our series, we found a higher rate of dupilumab-associated conjunctivitis (32%)
203 compared to landmark studies.² This is in keeping with other clinical reports of real-
204 world outcomes. Dupilumab-associated ocular surface disease was reported in 43%
205 and 70% by Nahum et al. and Ivert et al. respectively^{5,9}. These differences could be
206 due to overall smaller numbers of patients included in the clinical reports compared to
207 landmark studies.^{2,4,5,10}

208

209 Maudinet et al ¹⁰ reported features of dupilumab-associated conjunctivitis in keeping
210 with our findings. In their series, 60% of patients presented with mild injection and
211 papillary conjunctivitis and were treated with topical lubricants, whereas the
212 remaining 40% had severe follicular conjunctivitis requiring topical steroid treatment.
213 In our cohort we did not find that differentiating between papillary and follicular
214 presentation was clinically relevant. All patient had severe bulbar conjunctiva
215 injection, associated more commonly with papillary response, and all necessitated
216 steroid therapy.

217

218 Importantly, two patients in our study had cicatrising changes present in the lower
219 fornix and subtarsal conjunctiva at presentation. These two patients were related,
220 perhaps implicating a genetic predisposition for developing a more severe immune
221 response to dupilumab. This could also be a result of their AD alone and / or due to
222 the presence of chronic ocular inflammation. However, neither had a history of atopic
223 keratoconjunctivitis (AKC) nor symptoms of chronic ocular surface problems
224 requiring ophthalmic care prior to starting dupilumab. Another explanation for the
225 severity of ocular surface inflammatory features in these two cases could be related to
226 a delay in ophthalmic review between developing dupilumab related ocular symptoms
227 and being seen in the ocular surface clinic. In one case this time delay was –five
228 months.

229

230 One of the patients affected by cicatrization went on to develop a progressive
231 leukoplakic lesion in the lower conjunctival fornix, which was confirmed
232 histologically to be actinic keratosis with dysplasia - a precancerous lesion. This was

233 thought to be a result of life long immunosuppression and not solely a result of
234 dupilumab use. This patient was continued on dupilumab due to good dermatological
235 response. Further excisional biopsy with postoperative adjuvant treatment with
236 Interferon alpha-2b drops was planned at last follow up.

237

238 One patient (3.5%) in our series had to discontinue dupilumab due to severe
239 conjunctivitis and loss of lashes (madarosis). Madarosis has not been described before
240 and represents an extreme reaction to dupilumab.^{2,5, 10-14} To our knowledge, there are
241 two other case reports of conjunctival cicatrisation associated with dupilumab use.^{12,17}
242 Associated cicatrising ectropion, periocular dermatitis and punctal stenosis have been
243 described more commonly making the term dupilumab- associated ocular surface
244 disease rather than dupilumab-associated conjunctivitis more descriptive.¹⁰⁻¹⁵

245

246 Dupilumab is also known to increase the risk of orofacial herpes simplex infection
247 recurrence.^{2,5} Herpes simplex virus (HSV) uveitis while on dupilumab has been
248 described with no reports of HSV keratitis.⁵ One patient in our series had previous
249 history of HSV keratitis but did not develop any self-reported herpetic eye disease
250 flare-ups whilst on dupilumab. No patients in our series were swabbed for the
251 presence of HSV at the time of their acute presentation, so this cannot be ruled out for
252 certain as a cause of their acute ‘dupilumab- associated’ conjunctivitis presentation.
253 However, no patients demonstrated any of the typical features of herpes simplex
254 keratitis and we consider HSV as the causative agent to be unlikely.

255

256 The aetiology of dupilumab-associated conjunctivitis is not fully understood but
257 shares some common characteristics with atopic blepharoconjunctivitis and allergic
258 eye disease - namely decrease in goblet cells, heightened OX40 ligand activity,
259 eosinophilia and increased Demodex infestation due to changes in the ocular surface
260 environment.^{10,18-23} Allergic blepharokeratoconjunctivitis is common in AD with 32-
261 56% of patients affected.^{18,22-24} Previous history of atopic keratoconjunctivitis and
262 more severe AD prior to dupilumab initiation have been implicated as risk factors for
263 developing dupilumab-associated ocular surface disease.^{8,9} In our series, 44.4% of
264 patients had prior history of allergic eye disease and 50% went on to require long-
265 term ocular treatment.

266

267 All of our patients had improvement in ocular symptoms on topical steroids, which
268 were the mainstay of the initial treatment.²⁵ Topical steroids alone were sufficient at
269 reversing signs and symptoms of acute conjunctivitis in 89% of patients. Two patients
270 required additional ciclosporin drops to control their symptoms. Topical preparations
271 of ciclosporin have been successfully used in treatment of ocular surface disease for
272 many years. Ciclosporin is a calcineurin inhibitor that inhibits T-cell-mediated
273 immune responses and has been shown to increase goblet cell numbers.²⁶ Dupilumab
274 targets IL-13 action and secondary depletion of goblet cells and mucin production in
275 the conjunctiva could be responsible for dupilumab-associated conjunctivitis.²⁻⁵
276 Ciclosporin might be particularly useful in treatment of dupilumab-associated ocular
277 surface disease as it could reverse some of the local immunological actions of
278 dupilumab. Use of Ikervis (ciclosporin 0.1%) drops in dupilumab-associated ocular
279 surface disease remains off label since Ikervis is approved for use in dry eyes.²⁸ In our
280 series, Ikervis drops used twice a day were added to topical steroids with good clinical

281 outcomes. Use of tacrolimus^{4,8} and pimecrolimus²⁸ ointments to the eye lids has also
282 been reported to improve dupilumab- associated ocular surface disease in other case
283 series.

284

285 Mean duration of follow up was 16 (+/- 6.9) months. A large proportion of our
286 patients (67%) required continuation of topical immunosuppressive therapy to prevent
287 flare-ups on discontinuation of drops. Akinlade et al. reported that 80% of patients
288 had resolution of conjunctivitis while on dupilumab in clinical trials, but there was no
289 mention of duration of symptoms, nor what therapy these patients received for
290 treatment.² It also leaves 20% of cases with on-going ocular surface inflammation
291 while on dupilumab. These findings support our theory that dupilumab- associated
292 conjunctivitis might not be just a one off event in all affected eyes. The drug might
293 alter the ocular surface flaring up the susceptibility to chronic blepharoconjunctivitis
294 in AD patients. Alternatively, a large percentage of AD patients considered for
295 dupilumab have previously undiagnosed ocular surface inflammation. Clinically it is
296 difficult to distinguish a blepharoconjunctivitis flare up from dupilumab- associated
297 ocular surface disease as they share many similarities.^{2,9-18} In the series of Maudinet
298 et al., 64% of patients had previously undiagnosed blepharoconjunctivitis when
299 examined prior to starting dupilumab. Interestingly, lower rates of dupilumab-
300 associated conjunctivitis were observed in patients seen and treated by the
301 ophthalmologist prior to starting the drug than in patients not seen by ophthalmologist
302 prior to dupilumab therapy (13% versus 25% respectively).

303

304 Current practice in the UK is that the ophthalmologist reviews patients after they
305 develop ocular symptoms from dupilumab. Given that a large percentage of patients

306 require long-term ocular treatments, dupilumab is considered in a group of patients
307 with high risk for ocular surface problems, and dupilumab-associated conjunctivitis
308 can result in cicatrisation, our recommendation is that AD patients should be
309 examined by the ophthalmologist prior to starting the drug.

310

311 No patient in our cohort developed side effects due to topical therapy during the
312 follow up and vision remained excellent. All had improvement in EASI scores. With
313 the retrospective nature of our study and small sample it is impossible to say if our
314 patients had pre-existing undiagnosed AKC or whether dupilumab sensitized their
315 eyes to become chronically inflamed. Larger long-term prospective studies would be
316 needed to answer this question. We also lack data on the exact duration of the acute
317 dupilumab-associated conjunctivitis due to retrospective data collection. In our series
318 of patients, those not requiring maintenance steroid drops used topical steroids
319 between 3- 12 months.

320

321 In summary, dupilumab is used in patients who have a strong predisposition to
322 chronic ocular surface problems. In our series, 32% were affected by acute
323 dupilumab-associated ocular surface disease, which responded well to topical steroids
324 with or without adjunctive topical ciclosporin. Dupilumab-associated conjunctivitis
325 can lead to conjunctival cicatrisation and be associated with periocular skin changes,
326 punctal stenosis and madarosis, making dupilumab- associated ocular surface disease
327 a more useful, catch-all term. Dupilumab may unmask a predisposition to chronic
328 ocular inflammation and a significant number of patients need long-term topical
329 immunosuppressive therapy. Patients should be examined by the ophthalmologist

330 prior to starting dupilumab to optimise their ocular surface and arrange timely follow
331 up to detect acute dupilumab-associated ocular surface disease more swift

332

333

334 **References**

335 1. de Bruin-Weller M, Thaçi D, Smith CH, Reich K, Cork MJ, Radin A et al.

336 Dupilumab with concomitant topical corticosteroid treatment in adults with atopic
337 dermatitis with an inadequate response or intolerance to ciclosporin A or when this
338 treatment is medically inadvisable: a placebo-controlled, randomized phase

339 III clinical trial (LIBERTY AD CAFÉ). *Br J Dermatol*. 2018;178(5):1083–1101.

340

341 2. Akinlade B, Guttman-Yassky E, de Bruin-Weller M, Simpson EL, Blauvelt A,

342 Cork MJ et al. Conjunctivitis in dupilumab clinical trials. *Br J Dermatol*.

343 2019;181(3):459–473.

344

345 3. Chu CY. Keeping an eye on the ocular problems in dupilumab clinical trials. *Br J*

346 *Dermatol*. 2019;181(3):436–437

347

348 4. Wollenberg A, Ariens L, Thurau S, van Luijk C, Seegräber M, de Bruin-Weller M.

349 Conjunctivitis occurring in atopic dermatitis patients treated with dupilumab-clinical
350 characteristics and treatment. *J Allergy Clin Immunol Pract*. 2018;6(5):1778–1780.

351

352 5. Ivert LU, Wahlgren CF, Ivert L, Lundqvist M, Bradley M. Eye Complications

353 During Dupilumab Treatment for Severe Atopic Dermatitis. *Acta Derm Venereol*.

354 2019;99(4):375–378.

355

356 6. Deleuran M, Thaçi D, Beck LA, de Bruin-Weller M, Blauvelt A, Forman S et al.
357 Dupilumab shows long-term safety and efficacy in patients with moderate to severe
358 atopic dermatitis enrolled in a phase 3 open-label extension study. *J Am Acad*
359 *Dermatol.* 2020;82(2):377-388.

360

361 7. Thyssen JP, de Bruin-Weller MS, Paller AS, Leshem YA, Vestergaard C, Deleuran
362 M et al. Conjunctivitis in atopic dermatitis patients with and without dupilumab
363 therapy - international eczema council survey and opinion. *J Eur Acad Dermatol*
364 *Venereol.* 2019;33(7):1224-1231.

365

366 8. Treister AD, Kraff-Cooper C, Lio PA. Risk Factors for Dupilumab-Associated
367 Conjunctivitis in Patients With Atopic Dermatitis. *JAMA Dermatol.*
368 2018;154(10):1208-1211.

369

370 9. Nahum Y, Mimouni M, Livny E, Bahar I, Hodak E, Leshem YA. Dupilumab-
371 induced ocular surface disease (DIOSD) in patients with atopic dermatitis: clinical
372 presentation, risk factors for development and outcomes of treatment with tacrolimus
373 ointment. *Br J Ophthalmol.* 2020;104(6):776-779.

374

375 10. Maudinet A, Law-Koune S, Duretz C, Lasek A, Modiano P, Tran THC. Ocular
376 Surface Diseases Induced by Dupilumab in Severe Atopic Dermatitis. *Ophthalmol*
377 *Ther.* 2019;8(3):485-490.

378

- 379 11. Shen E, Xie K, Jwo K, Smith J, Mosaed S. Dupilumab-Induced Follicular
380 Conjunctivitis. *Ocul Immunol Inflamm*. 2019;27(8):1339-1341.
381
- 382 12. Levine RM, Tattersall IW, Gaudio PA, King BA. Cicatrizing
383 Blepharoconjunctivitis Occurring During Dupilumab Treatment and a Proposed
384 Algorithm for Its Management. *JAMA Dermatol*. 2018;154(12):1485-1486.
385
- 386 13. Paulose SA, Sherman SW, Dagi Glass LR, Suh LH. Dupilumab-associated
387 blepharoconjunctivitis. *Am J Ophthalmol Case Rep*. 2019;16:100550.
388
- 389 14. Barnes AC, Blandford AD, Perry JD. Cicatricial ectropion in a patient treated
390 with dupilumab. *Am J Ophthalmol Case Rep*. 2017;7:120-122.
391
- 392 15. Yamane MLM, Belsito DV, Glass LR.
393 Two differing presentations of periocular dermatitis as
394 a side effect of dupilumab for atopic dermatitis. *Orbit*. 2019;38(5):390-394.
395
- 396 16. Zirwas MJ, Wulff K, Beckman K. Lifitegrast add-on treatment for dupilumab-
397 induced ocular surface disease (DIOSD): A novel case report. *JAAD Case Rep*.
398 2018;5(1):34-36.
399
- 400 17. Liberman P, Shifera AS, Berkenstock M. Dupilumab-Associated Conjunctivitis in
401 Patients With Atopic Dermatitis. *Cornea*. 2020;39(6):784-786.
402

- 403 18. Guglielmetti S, Dart JK, Calder V. Atopic keratoconjunctivitis and atopic
404 dermatitis. *Curr Opin Allergy Clin Immunol*. 2010;10(5):478-485.
405
- 406 19. de Bruin-Weller M, Graham NMH, Pirozzi G, Shumel B. Could conjunctivitis in
407 patients with atopic dermatitis treated with dupilumab be caused by colonization with
408 Demodex and increased interleukin-17 levels?: reply from the authors. *Br J Dermatol*.
409 2018;178(5):1220-1221.
410
- 411 20. Thyssen JP. Could conjunctivitis in patients with atopic dermatitis treated with
412 dupilumab be caused by colonization with Demodex and increased interleukin-17
413 levels? *Br J Dermatol*. 2018; 178 (5):1220.
414
- 415 21. Mennini M, Dahdah L, Fiocchi A. Two Phase 3 Trials of Dupilumab versus
416 Placebo in Atopic Dermatitis. *N Engl J Med*. 2017;376(11):1090
417
- 418 22. Thyssen JP, Toft PB, Halling-Overgaard AS, Gislason GH, Skov L, Egeberg A.
419 Incidence, prevalence, and risk of selected ocular disease in adults with atopic
420 dermatitis. *J Am Acad Dermatol*. 2017;77(2):280-286
421
- 422 23. Bonini S. Atopic keratoconjunctivitis. *Allergy* 2004; 59 Suppl 78:71-3
423
- 424 24. Tuft SJ, Kemeny DM, Dart JK, Buckley RJ. Clinical features of atopic
425 keratoconjunctivitis. *Ophthalmology*. 1991;98(2):150-158.
426

- 427 25. Aszodi N, Thureau S, Seegräber M, de Bruin-Weller M, Wollenberg A.
428 Management of dupilumab-associated conjunctivitis in atopic dermatitis. *J Dtsch*
429 *Dermatol Ges.* 2019;17(5):488-491.
430
- 431 26. Utine CA, Stern M, Akpek EK. Clinical review: topical ophthalmic use of
432 cyclosporin A. *Ocul Immunol Inflamm* 2010; 18(5): 352–61.
433
- 434 27. Hoy SM. Ciclosporin Ophthalmic Emulsion 0.1%: A Review in Severe Dry Eye
435 Disease. *Drugs.* 2017;77(17):1909–1916.
436
- 437 28. Sernicola A, Gattazzo I, Di Staso F, Giordano D, Capalbo A, Persechino F et al.
438 Treatment of refractory conjunctivitis associated to dupilumab with topical
439 pimecrolimus applied to the eyelid skin. *Dermatol Ther.* 2019;32(6):e13134.

440
441
442
443
444

445 **Figure captions**

446

447 Figure 1. Patient with acute dupilumab - associated conjunctivitis.

448

449 Figure 2. Patient on dupilumab with progressive cicatrisation and leukoplakic
450 lesion in lower fornix.

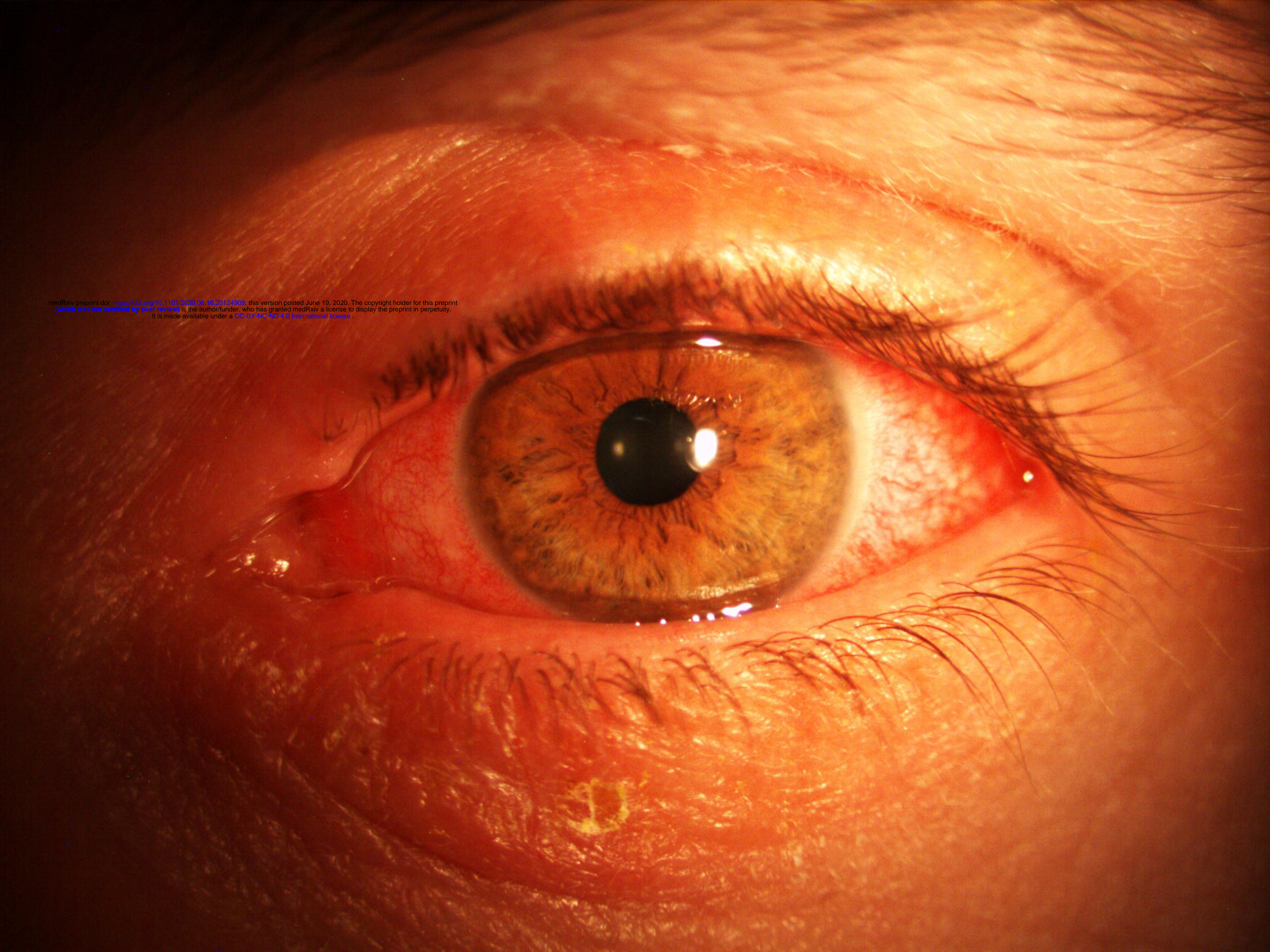
451

452 Figure 3. Patient from figure 1 after treatment with topical steroids.

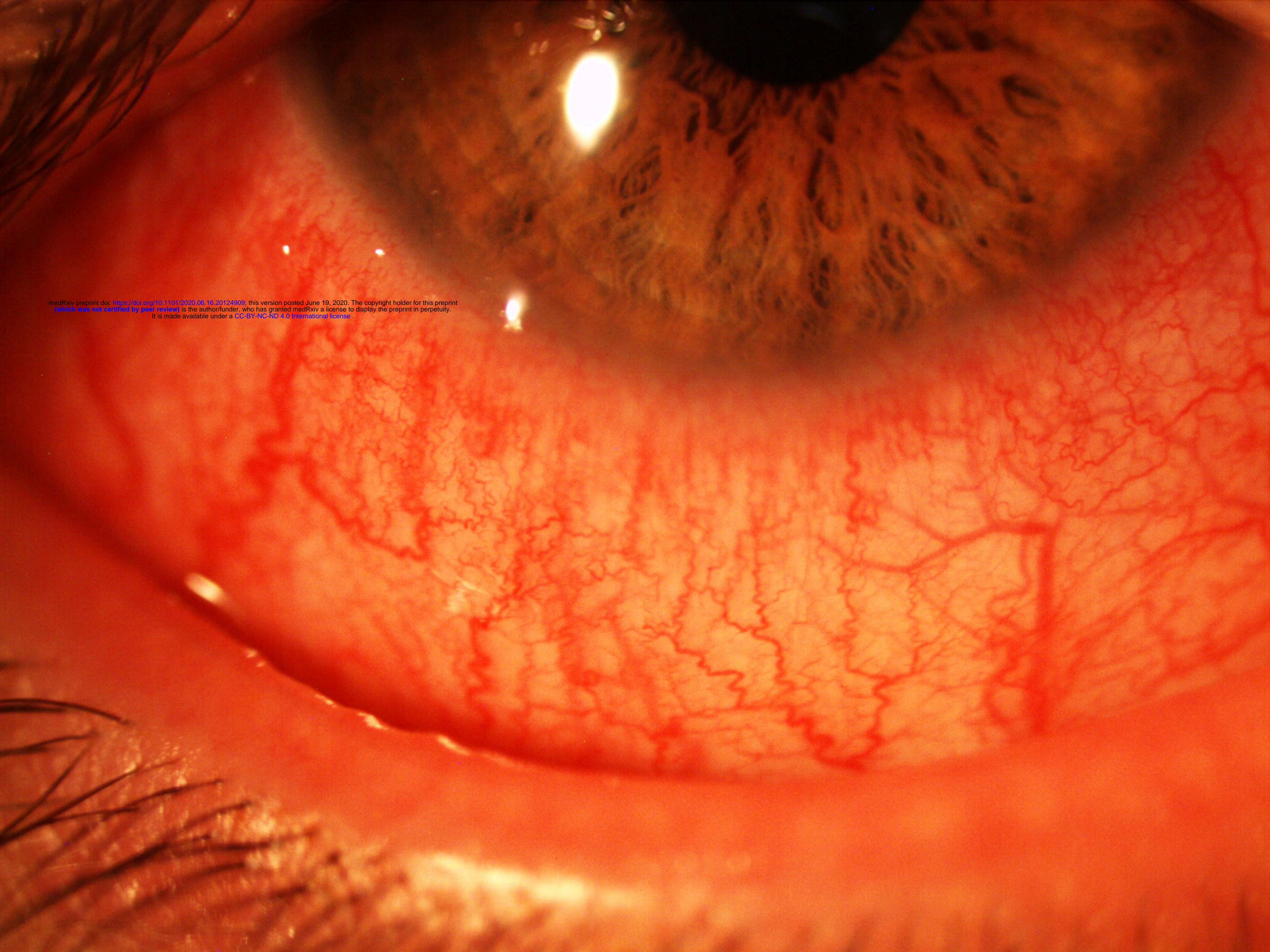
453

454

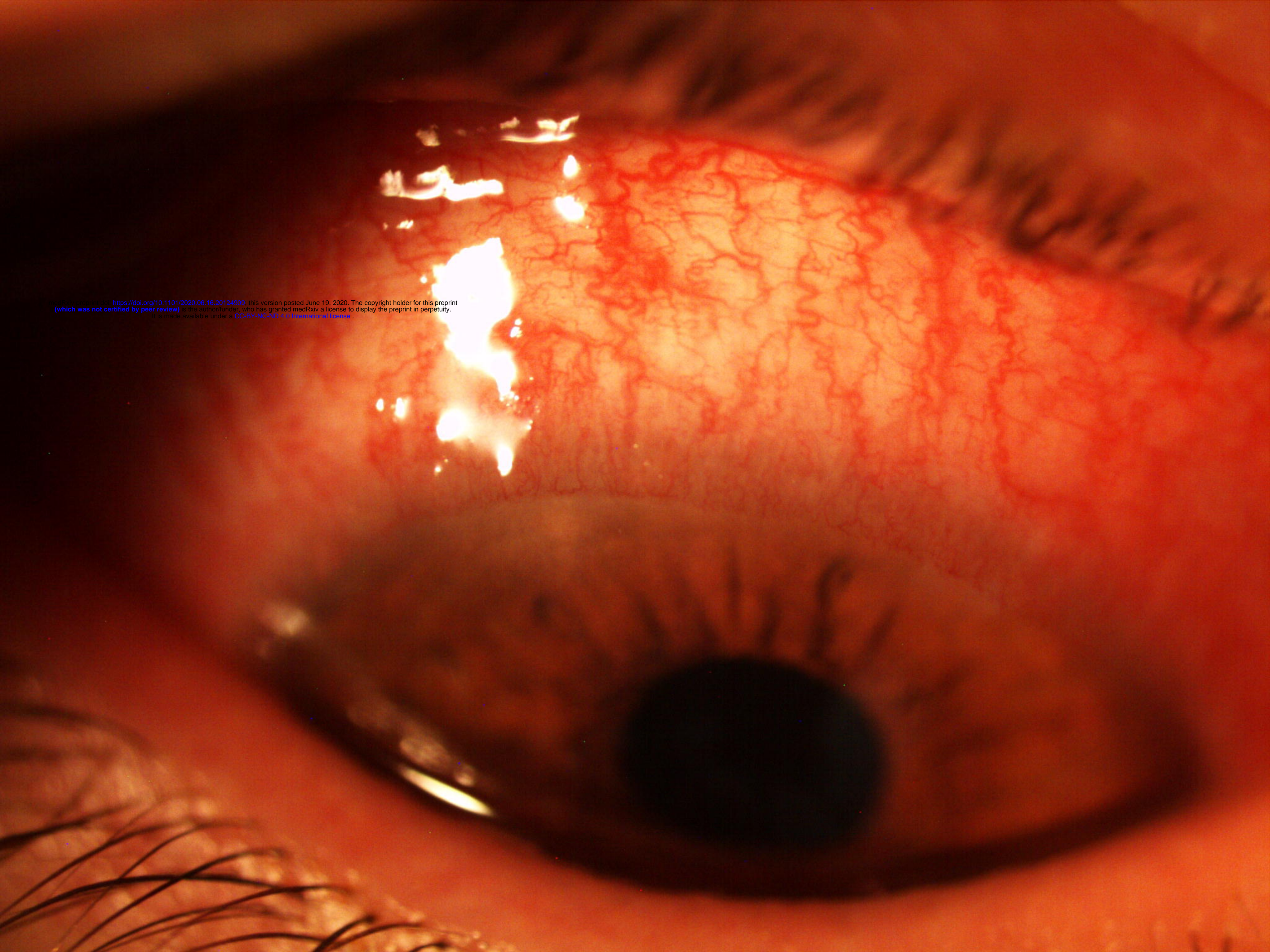
medRxiv preprint doi: <https://doi.org/10.1101/2020.06.16.20114494>; this version posted June 19, 2020. The copyright holder for this preprint (which was not certified by peer review) is the author/funder, who has granted medRxiv a license to display the preprint in perpetuity. It is made available under a CC-BY-NC-ND 4.0 International license.



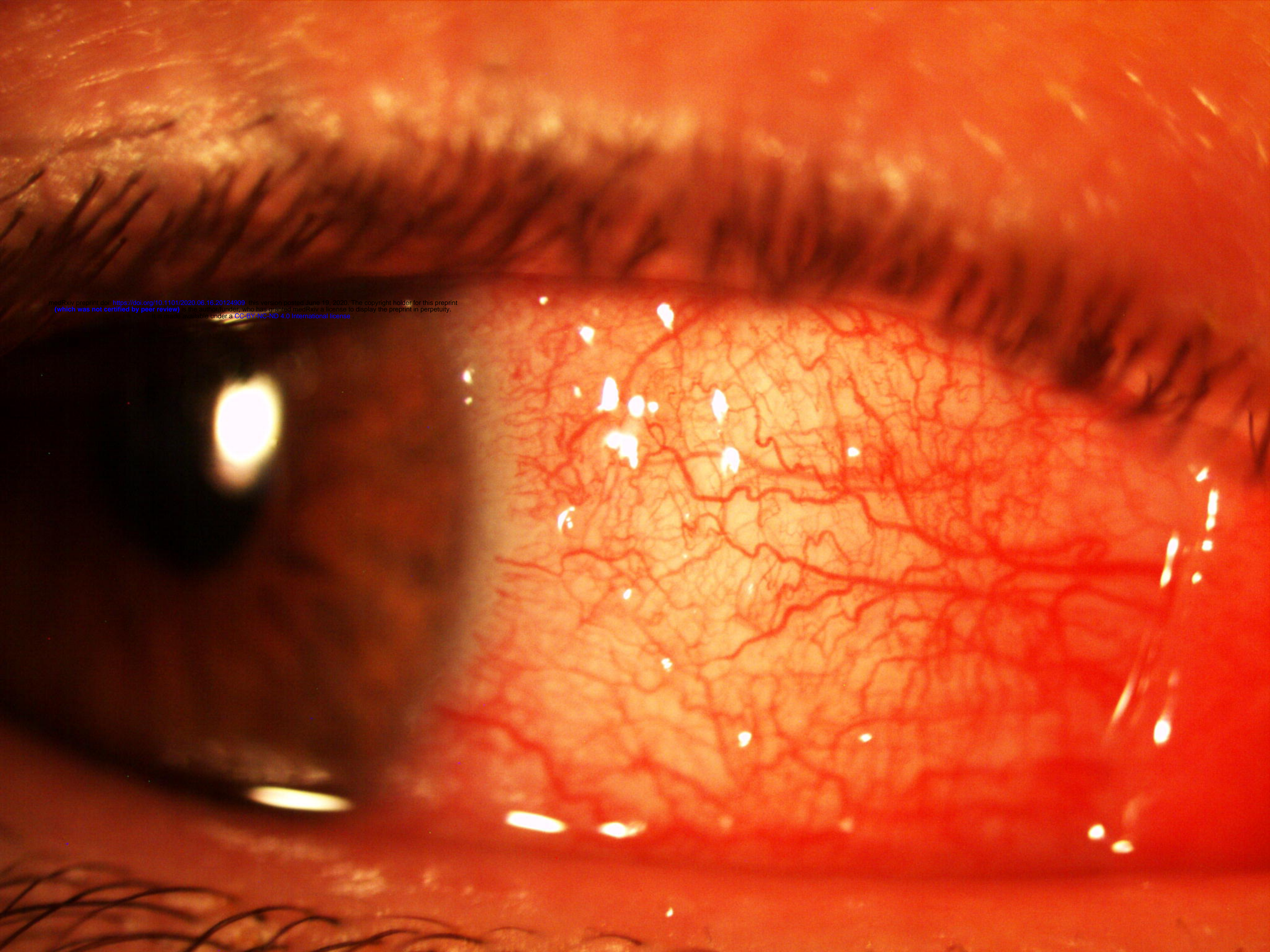
medRxiv preprint doi: <https://doi.org/10.1101/2020.06.16.20124909>; this version posted June 19, 2020. The copyright holder for this preprint (which was not certified by peer review) is the author/funder, who has granted medRxiv a license to display the preprint in perpetuity. It is made available under a [CC-BY-NC-ND 4.0 International license](#).



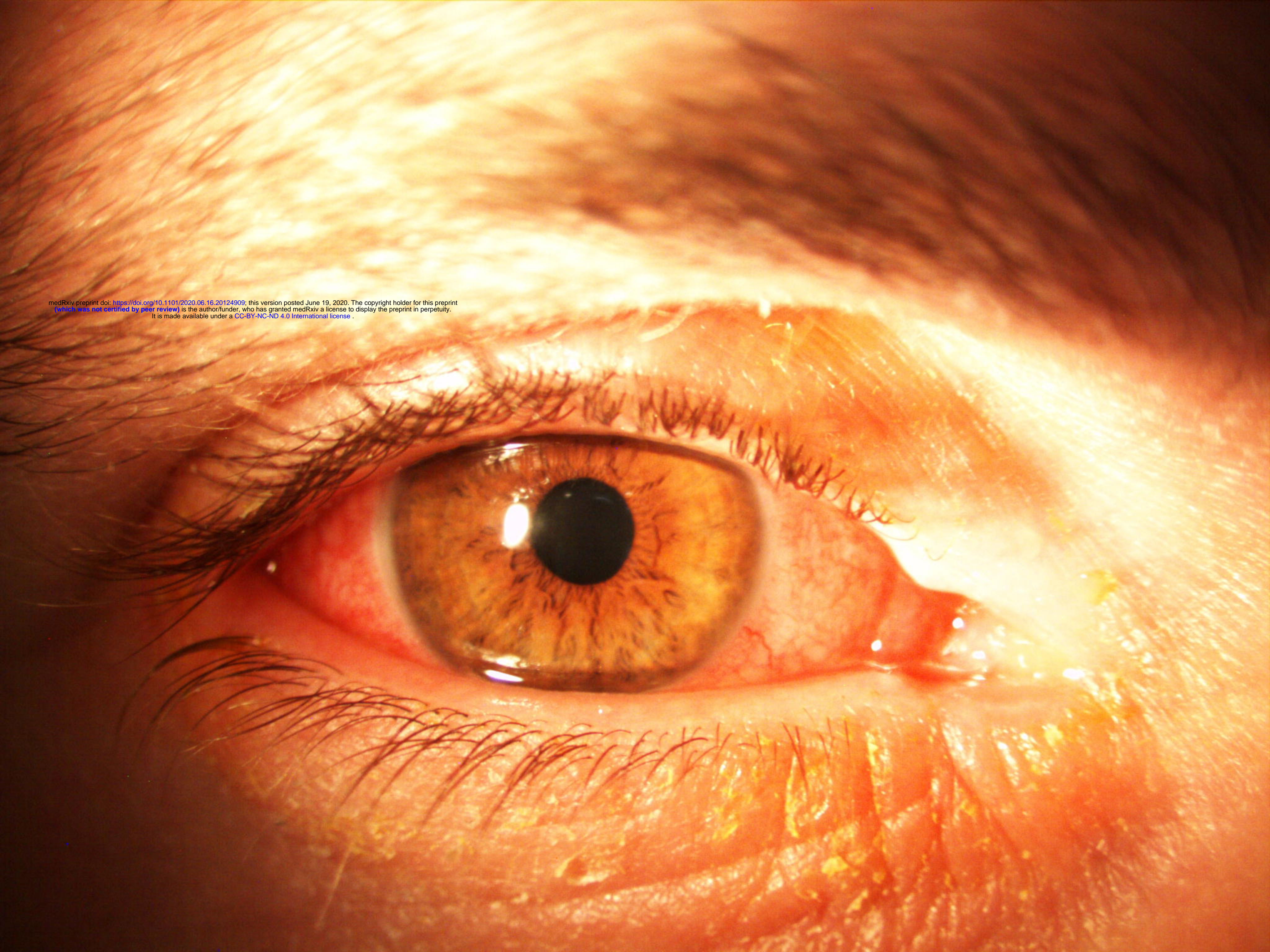
<https://doi.org/10.1101/2020.06.16.20124909>; this version posted June 19, 2020. The copyright holder for this preprint (which was not certified by peer review) is the author/funder, who has granted medRxiv a license to display the preprint in perpetuity. It is made available under a [CC-BY-NC-ND 4.0 International license](https://creativecommons.org/licenses/by-nc-nd/4.0/).

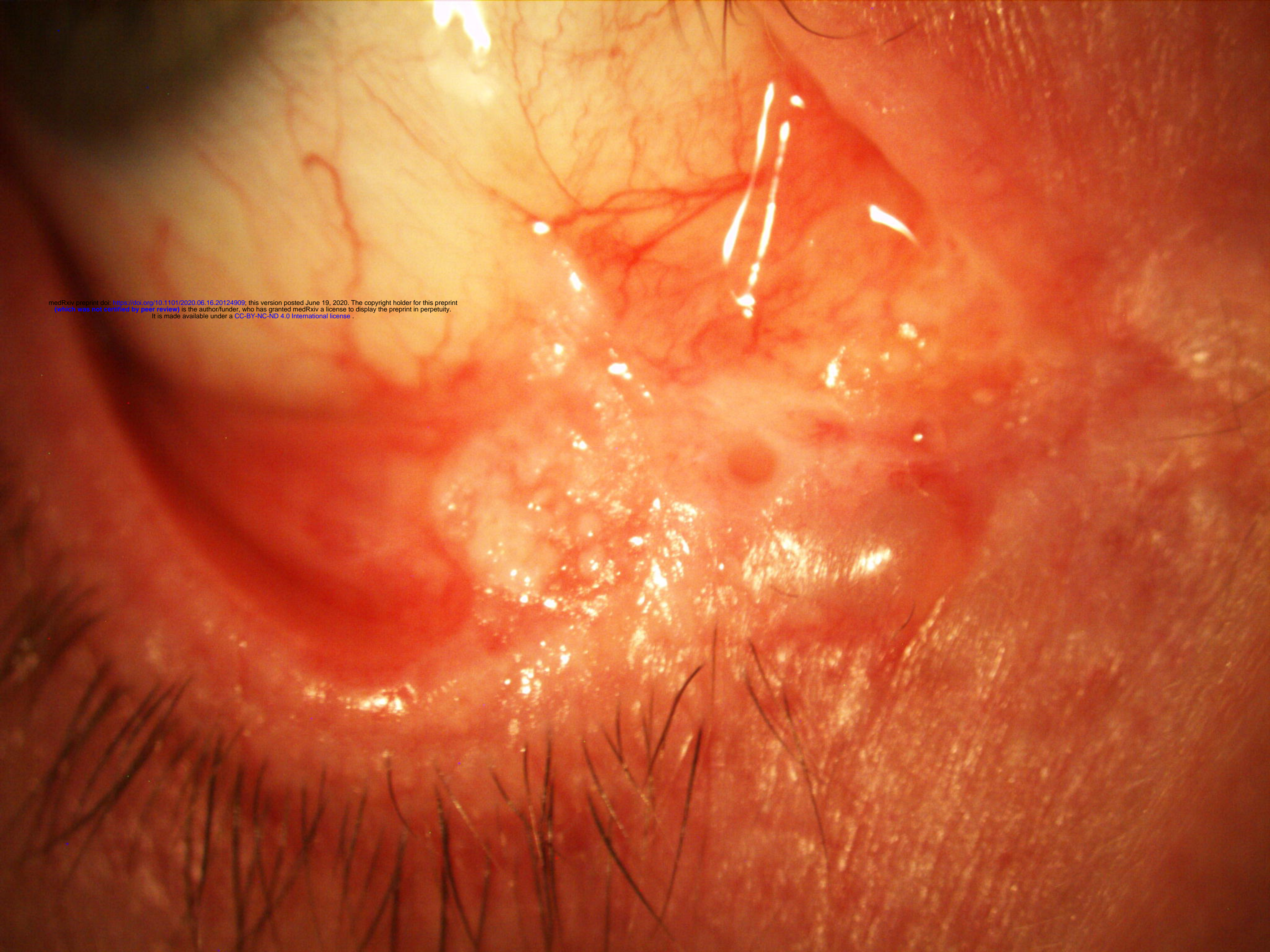


medRxiv preprint doi: <https://doi.org/10.1101/2020.06.16.20124909>; this version posted June 19, 2020. The copyright holder for this preprint (which was not certified by peer review) is the author/funder, who has granted medRxiv a license to display the preprint in perpetuity. It is made available under a [CC-BY-NC-ND 4.0 International license](https://creativecommons.org/licenses/by-nc-nd/4.0/).



medRxiv preprint doi: <https://doi.org/10.1101/2020.06.16.20124909>; this version posted June 19, 2020. The copyright holder for this preprint (which was not certified by peer review) is the author/funder, who has granted medRxiv a license to display the preprint in perpetuity. It is made available under a [CC-BY-NC-ND 4.0 International license](#).





medRxiv preprint doi: <https://doi.org/10.1101/2020.06.16.20124909>; this version posted June 19, 2020. The copyright holder for this preprint (which was not certified by peer review) is the author/funder, who has granted medRxiv a license to display the preprint in perpetuity. It is made available under a [CC-BY-NC-ND 4.0 International license](#).

