COVID-19 receptor ACE2 is expressed in human conjunctival tissue, expecially in diseased conjunctival

Shengjie Li[a, b, c*],Danhui Li[d], Jianchen Fang[d], Qiang Liu[d], Xinghuai Sun [b, c], Gezhi Xu[b*], Wenjun Cao[a, b*]

a. Department of Clinical Laboratory, Eye & ENT Hospital, Shanghai Medical College, Fudan University, Shanghai 200031, China

b. Department of Ophthalmology & Visual Science, Eye & ENT Hospital, Shanghai Medical College, Fudan University, Shanghai 200031, China

c. NHC Key Laboratory of Myopia (Fudan University), Key Laboratory of Myopia, Chinese Academy of Medical Sciences, and Shanghai Key Laboratory of Visual Impairment and Restoration (Fudan University), Shanghai 200031, China

d. Department of Pathology, Renji Hospital, School of Medicine, Shanghai Jiao Tong University, Shanghai 200031, China

Shengjie Li and Danhui Li contributed equally to this work.

***Corresponding author:** Shengjie Li, E-mail: lishengjie6363020@163.com Address: Eye & ENT Hospital, Shanghai Medical College, Fudan University, No.83 Fenyang Road, Shanghai, China, 200031; Wenjun Cao, E-mail: wgkjyk@aliyun.com Address: Eye & ENT Hospital, Shanghai Medical College, Fudan University, No.83 Fenyang Road, Shanghai, China, 200031; Gezhi Xu, E-mail: xugezhi@sohu.com Address: Eye & ENT Hospital, Shanghai Medical College, Fudan University, No.83 Fenyang Road, Shanghai, China, 200031

Running head: ACE2 expression in conjunctival tissue

Keywords: angiotensin-converting enzyme 2, conjunctival tissue, COVID-19, SARS-CoV-2

Abstract

COVID-19 virus has currently caused major outbreaks worldwide. ACE2 is a major cellular-entry receptor for the COVID-19 virus. Although ACE2 is known to be expressed in many organs, whether it is expressed by the conjunctival tissue is largely unknown. Human conjunctival tissues from 68 subjects were obtained, which included 10 subjects with conjunctival nevi, 20 subjects with conjunctivitis, 9 subjects with conjunctival papilloma, 16 subjects with conjunctival cyst, 7 subjects with conjunctival polyps, and 6 ocular traumas as normal subjects. Expression of ACE2 was evaluated by immunohistochemistry, immunofluorescence, reverse transcriptase-quantitative polymerase chain reaction, and western blot assay. We observed the expression of ACE2 by conjunctival tissues, expecially in conjunctival epithelial cells. ACE2 was significantly ($p<0.001$) overexpressed in conjunctival cells obtained from subjects with conjunctivitis, conjunctival nevi, conjunctival papilloma, conjunctival cyst, and conjunctival polyps epithelial cells when compared to that in conjunctival epithelial cells obtained from control subjects. Collectively, clinical features of reported COVID-19 patients combined with our results indicate that COVID-19 is likely to be transmitted through the conjunctiva.

1. Introduction

In December 2019, coronavirus disease 2019 (COVID-19) was first reported in people in Wuhan, Hubei province, China.[1] Since then, the COVID-19 virus has rapidly spread throughout the world.[2,3] As of May 16, 2020, 4425485 laboratory-confirmed cases were reported. Furthermore, the World Health Organization reported 302059 fatalities.[4] The typical signs and symptoms of COVID-19 are fever, dry cough, and fatigue. The virus is mainly transmitted through respiratory droplets and by close contact with infected individuals, as reported by the Health commission, PRC. Furthermore, about 0.8% of COVID-19 patients showed symptoms of conjunctival congestion.[5] Thus, the ocular surface may as a possible site of virus entry and also as a source of contagious infection [6]. However, whether COVID-19 can be transmitted through the conjunctiva is still unclear.

Studies provide powerful evidence that angiotensin-converting enzyme 2 (ACE2) is a major cellular-entry receptor for the COVID-19 virus.[7, 8] Lukassen et al.[9] and Hamming I et al.[10] have shown the expression of ACE2 in lung tissue, which may explain why most COVID-19 patients show increased sputum production and experience shortness of breath.[11] Using single-cell transcriptome analysis, Haoyan Chen et al.[12] and Hao Zhang et al.[13] have shown that ACE2 is expressed in the epithelial cells of the colon and digestive system, which may explain why 3.8% of COVID-19 patients experience nausea or vomiting, and diarrhoea.[1] Moreover, previous studies have shown that oral, nasal, and nasopharyngeal epithelia do not express ACE;[10] these results are consistent with the lack of any obvious upper

respiratory distress symptoms in COVID-19 patients.[1,11] These studies, along with the typical symptoms exhibited by COVID-19 patients, may provide evidence that the expression of ACE2 gene may be a factor involved in the mode of transmission of the virus.

Currently, it is still unknown whether the COVID-19 virus is transmitted through the conjunctiva, and whether the conjunctival tissue can express ACE2.[14] In order to understand the relationship between the expression levels of ACE2 and the likelihood of COVID-19 transmission through the conjunctiva, we studied the mRNA and protein level of ACE2 in conjunctival tissue.

2. Materials and methods

This study was conducted at the Department of Pathology, Renji Hospital, Shanghai Jiao Tong University, Shanghai, China. The ethics committee of the Renji Hospital of Shanghai Jiao Tong University approved this study, and it adhered to the principles of the Declaration of Helsinki. Informed consent was obtained from all participating subjects. All subjects were recruited from Renji Hospital of Shanghai Jiao Tong University.

2.1 Human conjunctival tissue

Human conjunctival tissues were obtained from patients undergoing biopsy for diagnoses or prior to surgery. Diseased conjunctival tissues were obtained from 62 different subjects with the following conditions: ten patients with conjunctival nevi, 20 patients with conjunctivitis, nine patients with conjunctival papilloma, 16 patients

with conjunctival cyst, and seven patients with conjunctival polyps; six normal conjunctival tissues were obtained from patients with ocular trauma, who needed ophthalmectomy.

2.2 RNA isolation and detection

Total RNA was extracted using GenEluteTM FFPE RNA Purification Kit (RNB400, Sigma-Aldrich) as per the manufacturer's instructions. The quality and integrity of the acquired total RNA were evaluated using a NanoDrop™ 2000c (Thermo Fisher Scientific, Inc., Wilmington, DE, USA). For reverse transcription-quantitative polymerase chain reaction (RT-qPCR), 1,000 ng of total RNA was reverse-transcribed with 2 μL of 5X OneStep RT Mix. The RT-qPCR reaction was performed using 1 μL of RT products, 0.2 μL of 10 μM forward primer, 0.2 μL of 10 μM pmol reverse primer, and 5 μL of 2X SYBR Green I qPCR mix and completed to 10 μL with nuclease-free water. The primers used were as follows: ACE2-forward, 5′-AAAGGAACAGTCCACACTTGCCC-3′, and ACE2-reverse, 5′-TGAAGACCCATTTTGCTGAAGAGCC-3′.

2.3 Western blot assay

Total protein was extracted from conjunctival tissue using ice-cold RIPA lysis buffer together with PMSF mixture. For gel electrophoresis, 80 μg total extracted proteins of each sample were separated by 10% sodium dodecyl sulfate-polyacrylamide gel (SDS-PAGE) and subsequently transferred to polyvinylidene difluoride (PVDF) membranes (Millipore, Billerica, MA, USA), followed by blocking with 5% non-fat milk for ~2 h at room temperature. Then the membranes were incubated with primary

antibodies against GAPDH (1:10000; ab181602, Abcam, Cambridge, MA, USA) and ACE2 (1:1000; ab15348, Abcam, Cambridge, MA, USA). After being washed three times with TBST, the membranes were further incubated with specific horseradish peroxidase conjugated secondary antibodies (1:5,000; ab6721; Abcam, Cambridge, MA, USA). Immuno-stained bands were detected by chemiluminescent method. Image software (Imagepro plus 6.0, Media Cybernetics, Inc., USA) were used to quantify band intensities.

2.4 Immunohistochemistry

Paraffin-embedded sections (4 μm) of conjunctival tissue collected from the patients were prepared on slides. The antigen was retrieved by microwaving the samples at a temperature over 90℃ after they were dewaxed and rehydrated. Slides were then blocked with 5% bovine serum albumin (BSA) for 1 h to reduce nonspecific binding. Two specimens were taken from each sample. One specimen was incubated with polyclonal rabbit anti-ACE2 primary antibody (ab15348, Abcam, Cambridge, MA, USA) for 2 h at 1:1500 dilution. Another specimen was incubated with monoclonal mouse anti-ACE2 antibody (66699-1-Ig, Proteintech, Wuhan, China) for 2 h at 1:150 dilution. Specimens were then incubated with a secondary antibody, horseradish peroxidase (HRP)-conjugated goat anti-rabbit lgG polyclonal antibody (Zhongshan, Beijing, China, dilution of 1:100), for 1 h. 3,3’-Diaminobenzidine tetrahydrochloride (DAB; Zhongshan, Beijing, China) was used as a chromogen and haematoxylin was used to counterstain the slides. Sections were scanned using a KFBIO scanner (KF-PRO-005-EX, Zhejiang, China) and viewed with KFBIO.SlideViewer software.

Image processing software (Imagepro Plus, Media Cybernetics, Inc., USA) was used to quantify the degree of immunohistochemical staining. The area (sum) and integrated optical density (IOD) (sum) were counted in four different fields using a computer-automated method (Imagepro plus 6.0, Media Cybernetics, Inc., USA). Area of interest (AOI) = IOD (sum) / area (sum); the results were averaged.

2.5 Immunofluorescence

Briefly, 4μm FFPE sections of human conjunctiva were dewaxed and hydrated. Tissue sections were placed in a repair box filled with citric acid antigen repair buffer (pH 6.0) for antigen repair. Then the tissues sections were covered uniformly with 3% BSA and sealed at room temperature for 30 min. After adding primary anti-ACE2 antibody (ab15348, Abcam, Cambridge, MA, USA; dilution 1:200), incubate overnight at 4 ℃. Wash three times with PBS (pH 7.4) and then add secondary Cy-3 labeled anti-rabbit IgG antibody (dilution 1:1500), incubate darkly at room temperature for 50min. Again wash three times with PBS (pH 7.4) then add DAPI stain, incubate darkly at room temperature for 10min. After being washed and dried, use anti-fluorescence quench sealing tablet to seal the sections. The sections were observed under a Nikon inverted fluorescence microscope and the images were collected (ultraviolet excitation wavelength 330-380 nm, emission wavelength 420 nm; FITC green light excitation wavelength 465-495 nm, emission wavelength 515-555 nm; CY3 red light excitation wavelength 510-560, emission wavelength 590nm). Three images were taken from each sample. Image processing software (Imagepro Plus, Media Cybernetics, Inc., USA) was used to quantify the mean gray

value of immunofluorescence staining. The results were averaged.

2.6 Statistical analysis

All analyses were performed using the Statistical Package for the Social Sciences software, version 13.0 (SPSS Inc., Chicago, IL, USA). The figures were created using GraphPad Prism 6 software (La Jolla, CA, USA). The results were analysed using the two-tailed Mann-Whitney test. A value of $p<0.05$ was considered statistically significant.

3. Results

3.1 Characteristics of the study patients

Sixty-eight subjects with a mean age of 47.42 ±16.19 years [(32 males (47.06%); 36 females (52.94%)] were recruited in the study. A total of 68 conjunctival tissues were collected from subjects with the following conditions: conjunctival nevi (n=10), conjunctivitis (n=20), conjunctival papilloma (n=9), conjunctival cyst (n=16), conjunctival polyps (n=7), and normal conjunctiva tissues (n=6). The demographic data of the study subjects are summarised in Table 1.

3.2 Comparison of ACE2 mRNA levels in conjunctival tissues

RT-qPCR was used to examine the expression level of ACE2. A significant difference in mRNA level of ACE2 between normal conjunctival tissues and other diseased conjunctival tissues was observed ($p<0.001$; Figure 1A). The ACE2 mRNA levels was significantly overexpressed in the conjunctival tissues of inflamed conjunctiva, conjunctival nevi, conjunctival cyst, conjunctival papilloma, and conjunctival polyps

as compared to that in normal conjunctival tissues ($p<0.001$; Figure 1A). A significant difference in ACE2 mRNA level between conjunctivitis tissues and other diseased conjunctival tissues was observed ($p<0.001$; Figure 1A). Conjunctival tissues from conjunctival cyst, conjunctival papilloma, and conjunctival polyps exhibited a higher ACE2 expression than that suffering from conjunctivitis. Moreover, there was no significant difference in ACE2 expression among diseased conjunctival tissues expect conjunctivitis (Figure 1A, $p=0.08$).

3.3 Comparison of ACE2 protein levels in conjunctival tissues

As presented in Figure 1B, the protein level of ACE2 was detected by western blot assay. The protein level of ACE2 was significantly ($p<0.001$ for both) higher in the conjunctival tissues of inflamed conjunctiva, conjunctival nevi, conjunctival cyst, conjunctival papilloma, and conjunctival polyps as compared to that in normal conjunctival tissues (Figure 1C). Furthermore, in diseased conjunctival tissues, the protein level of ACE2 was significantly ($p<0.001$) lower in the conjunctival tissues of inflamed conjunctiva as compared to other diseased conjunctival tissues (Figure 1C).

3.4 The localization of ACE2 in conjunctival tissues by immunohistochemistry

Two different antibodies [polyclonal rabbit anti-ACE2 antibody (Figure 2, 4) and monoclonal mouse anti-ACE2 antibody (Figure 3, 5)] were used. Notably, we observed the presence of ACE2 in conjunctival epithelial cells (Figure 2D–F, Figure 3D–F). Marked ACE2 immunostaining was found in the epithelial cells in the tissue samples of conjunctival polyps (Figure 2G–I, Figure 3G–I), conjunctival papilloma (Figure 2J–L, Figure 3J–L), conjunctival cyst (Figure 2M–O, Figure 3M–O),

conjunctival nevi (Figure 2P–R, Figure 3P–R), and conjunctivitis (Figure 2S–U, Figure 3S–U). A significant visual difference in the level of ACE2 staining was noted between diseased and normal conjunctival epithelial cells.

Additionally, ACE2 was also expressed in the conjunctival lamina propria lymphocytes and vascular endothelial cells (Figure 4A, Figure 5A). Strong staining was seen in the vascular endothelium and lymphocytes in the subepithelial tissues of the conjunctival polyps (Figure 4B, Figure 5B), conjunctival papilloma (Figure 4C, Figure 5C), conjunctival cyst (Figure 4D, Figure 5D), and conjunctivitis (Figure 4F, Figure 5F). In the conjunctival tissue exhibiting conjunctival nevi (Figure 4E, Figure 5E), strong staining was seen in the melanocytes and eccrine sweat-gland cells.

3.5 The localization of ACE2 in conjunctival tissues by immunofluorescence

We also observed the presence of ACE2 in conjunctival epithelial cells by immunofluorescence (Figure 6 A-C). Marked ACE2 immunostaining was found in the epithelial cells in the tissue samples of conjunctival polyps (Figure 6 D-F), conjunctival papilloma (Figure G-I), conjunctival cyst (Figure J-L), conjunctival nevi (Figure M-O), and conjunctivitis (Figure P-R). A significant visual difference in the level of ACE2 staining was noted between diseased and normal conjunctival epithelial cells.

3.6 Comparison of ACE2 protein levels in conjunctival epithelial cells

A summary of the quantitative data is presented in Figure 7A-C. A significant difference in ACE2 expression between normal conjunctival epithelial cells and other diseased conjunctival epithelial cells was observed ($p<0.05$). The ACE2 was

significantly ($p<0.05$ for both) overexpressed in the epithelial cells of inflamed conjunctiva, conjunctival nevi, conjunctival papilloma, conjunctival cyst, and conjunctival polyps as compared to that in normal conjunctival epithelial cells. Furthermore, in diseased conjunctival tissues, the level of ACE2 was significantly ($p<0.001$) lower in the conjunctival epithelial cells of inflamed conjunctiva as compared to other diseased conjunctival tissues.

4. Discussion

COVID-19 is currently a global pandemic; however, the possibility of its transmission through the conjunctiva is still unclear. In this study, we report the level of ACE2, the major cellular-entry receptor of the COVID-19 virus, in human conjunctival tissue. The most significant finding was the surface expression of ACE2 in conjunctival epithelial cells. Furthermore, ACE2 was significantly overexpressed in diseased epithelial cells when compared to that in conjunctival epithelial cells obtained from control subjects. The demonstration of ACE2 expression in human conjunctival tissue can potentially identify the possible routes of infection for COVID-19.

It is evident that several respiratory viruses are capable of using the eye as both a site for replication as well as a port of entry, which could result in a productive respiratory infection.[15] Athanasiu P et al.[16] reported human parainfluenza viruses in conjunctival cells. Warren D et al.[17] reported these viruses in children presenting with conjunctivitis and upper respiratory tract illnesses. Further, Peiris JS et al.[18] reported that SARS-CoV can be transmitted either through direct or indirect contact

with the mucous membranes of the eyes. Collectively, it is evident that the virus, in the form of droplets, can be transmitted through the human conjunctival epithelium.[19]

Lu CW et al.[20] have proposed that the COVID-19 virus transmission through the ocular surface must not be ignored, indicating the possibility of its transmission via the eye. They also reported that Guangfa Wang, a member of the national expert panel on pneumonia, was infected by the COVID-19 virus during inspection in Wuhan. Wang complained of redness of the eyes, which indicates that he was infected through the ocular surface.[20,21] Furthermore, Xia J et al.[22] performed a prospective interventional case study series to assess the presence of novel coronavirus in tears and conjunctival secretions of COVID-19-infected patients. They report that conjunctival swab samples collected from patients with conjunctivitis yielded positive RT-PCR results, whereas negative RT-PCR results were obtained for the tear fluid and conjunctival secretion samples in patients without conjunctivitis. In our study, a marked immunostaining revealed that ACE2 was abundantly expressed in epithelial cells in patients with conjunctivitis as compared to that in the epithelial cells from normal conjunctivae. This could explain why some studies reported positive RT-PCR results only in patients with conjunctivitis.

Moreover, our study also showed that ACE2 was significantly overexpressed in conjunctivitis, conjunctival nevi, conjunctival papilloma, conjunctival cyst, and conjunctival polyps epithelial cells as compared to that in normal conjunctival epithelial cells. Our results were highly consistent with the anatomical features that

viruses enter the host via the conjunctival route. Conjunctiva exposed to the environment is easily overlooked. Thus, subjects with diseased conjunctivae may be more susceptible to COVID-19 infection via conjunctival epithelial cells; therefore, individuals with diseased conjunctivae should use protective eyewear. Since medical staffs are in contact with patients at a close-range during examination, protective goggles are required to be worn, especially by ophthalmologists.

We conclude that ACE2 is present in human conjunctival tissue, especially in conjunctival epithelial cells, which might provide a possible route of entry for the COVID-19 virus. Abundant ACE2 is expressed in diseased conjunctival tissue; therefore, subjects with diseased conjunctivae may be more susceptible to COVID-19. Collectively, clinical features of reported COVID-19 patients combined with our results indicate that COVID-19 is likely to be transmitted through the conjunctiva. Future studies have to elucidate whether COVID-19 was bind to a co-receptor in addition to ACE2.

Acknowledgements

This work was supported by Shanghai Sailing Program (18YF1403500), Shanghai Municipal Commission of Health and Family Planning (20174Y0169), Shanghai Municipal Commission of Health and Family Planning (201840050), Shanghai Science Technology Committee Foundation grant (19411964600). The sponsor or funding organization had no role in the design or conduct of this research.

Conflict of Interest Statement

The authors declare that they have no competing interests.

Author contributions

SJ L, DH L, XH S, GZ X and WJ C conceived and designed the project. GZ X and WJ C supervised the project. SJ L, DH L, JC F, and QL performed experiments. SJ L and DH L analyzed data. DH L, JC F, and QL provided tissue. SJ L and DH L wrote the manuscript, and all authors read, revised, and approved the manuscript.

References

[1] Guan WJ , Ni ZY , Hu Y, et al. Clinical Characteristics of Coronavirus Disease 2019 in China. N Engl J Med. 2020 Feb 28. doi: 10.1056/NEJMoa2002032. [Epub ahead of print]

[2] Young BE, Ong SWX, Kalimuddin S, et al. Epidemiologic Features and Clinical Course of Patients Infected With SARS-CoV-2 in Singapore. JAMA. 2020 Mar 3. doi: 10.1001/jama.2020.3204. [Epub ahead of print]

[3] Kandel N , Chungong S , Omaar A , Xing J. Health security capacities in the context of COVID-19 outbreak: an analysis of International Health Regulations annual report data from 182 countries. Lancet. 2020 Mar 18. pii: S0140-6736(20)30553-5.

[4] WHO. https://www.who.int/emergencies/diseases/novel-coronavirus-2019/situation-reports.

[5] Report of the WHO-China Joint Mission on Coronavirus Disease 2019 (COVID-19). February 16-24, 2020. https://www.who.int/docs/ default-source/coronaviruse/who-china-joint-mission-on-covid-19- final-report.pdf.

[6] Jun ISY, Hui KKO, Songbo PZ. Perspectives on Coronavirus Disease 2019 Control Measures for Ophthalmology Clinics Based on a Singapore Center

Experience. JAMA ophthalmology. 2020.

[7] Zhou P, Yang XL, Wang XG, et al. A pneumonia outbreak associated with a new coronavirus of probable bat origin. Nature. 2020 Mar;579(7798):270-273.

[8] Wan Y, Shang J, Graham R, Baric RS, Li F. Receptor Recognition by the Novel Coronavirus from Wuhan: an Analysis Based on Decade-Long Structural Studies of SARS Coronavirus. J Virol. 2020 Mar 17;94(7).

[9] Lukassen S, Chua RL, Trefzer T, Kahn NC, Schneider MA, Muley T, et al. SARS-CoV-2 receptor ACE2 and TMPRSS2 are primarily expressed in bronchial transient secretory cells. The EMBO journal. 2020:e105114.

[10] Hamming I, Timens W, Bulthuis ML, Lely AT, Navis G, van Goor H. Tissue distribution of ACE2 protein, the functional receptor for SARS coronavirus. A first step in understanding SARS pathogenesis. J Pathol. 2004 Jun;203(2):631-637.

[11] Huang C, Wang Y, Li X. Clinical features of patients infected with 2019 novel coronavirus in Wuhan, China. Lancet. 2020 Feb 15;395(10223):497-506.

[12] Haoyan Chen, Baoqin Xuan, Yuqing Yan, et al. Profiling ACE2 expression in colon tissue of healthy adults and colorectal cancer patients by single-cell transcriptome analysis. medRxiv preprint doi: https://doi.org/10.1101/2020.02.15.20023457

[13] Hao Zhang, Zijian Kang, Haiyi Gong, et al. The digestive system is a potential route of 2019-nCov infection: a bioinformatics analysis based on single-cell transcriptomes. Biorxiv. doi:https://doi.org/10.1101/2020.01.30.927806

[14] Peng Y, Zhou YH. Is novel coronavirus disease (COVID-19) transmitted through conjunctiva? J Med Virol. 2020 Mar 16. doi: 10.1002/jmv.25753. [Epub ahead of

print]

[15] Belser JA, Rota PA, Tumpey TM. Ocular tropism of respiratory viruses. Microbiol Mol Biol Rev. 2013 Mar;77(1):144-156.

[16] Athanasiu P, Anghelescu S, Predescu E. Rapid detection by immunofluorescence of multiple viral infections in patients with keratitis. Virologie. 1984 Apr-Jun;35(2):83-88.

[17] Warren D, Nelson KE, Farrar JA. A large outbreak of epidemic keratoconjunctivitis: problems in controlling nosocomial spread. J Infect Dis. 1989 Dec;160(6):938-943.

[18] Peiris JS, Yuen KY, Osterhaus AD, Stöhr K. The severe acute respiratory syndrome. N Engl J Med. 2003 Dec 18;349(25):2431-2441.

[19] Olofsson S, Kumlin U, Dimock K, Arnberg N. Avian influenza and sialic acid receptors: more than meets the eye? Lancet Infect Dis. 2005 Mar;5(3):184-188.

[20] Lu CW, Liu XF, Jia ZF. 2019-nCoV transmission through the ocular surface must not be ignored. Lancet. 2020 Feb 22;395(10224):e39.

[21] Dai X. Peking University Hospital Wang Guangfa disclosed treatment status on Weibo and suspected infection without wearing goggles. Jan 22, 2020. http://www.bjnews. com.cn/news/2020/01/23/678189.html (accessed Jan 24, 2020)

[22] Xia J, Tong J, Liu M, Shen Y, Guo D. Evaluation of coronavirus in tears and conjunctival secretions of patients with SARS-CoV-2 infection. J Med Virol. 2020 Feb 26. doi: 10.1002/jmv.25725. [Epub ahead of print]

Table 1. Demographic details of the study subjects

	Number of subjects
Gender, Male/Female	32/36
Age, mean, rang, years	47.42 ±16.19 (12-72)
BMI, mean, Kg/m^2	23.18 ±4.58
Smoking habit, Proportion% (yes)	16.18 (11)
Drinking habit, Proportion% (yes)	8.82 (6)
Diabetes mellitus, Proportion% (yes)	5.88 (4)
Hypertension, Proportion% (yes)	16.18 (11)
Best corrected visual acuity, LogMAR	
Right	0.83 ±0.26
Left	0.85 ±0.28
Intraocular pressure, mmHg	
Right	14.56 ±3.26
Left	15.58 ±3.19

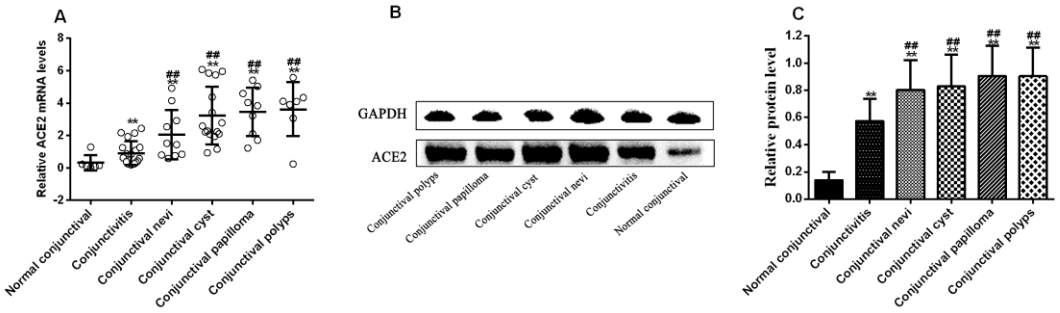

Figure 1. ACE2 mRNA levels (A) and protein levels (B, C) in different type conjunctival tissues were examined by RT-qPCR and western blot assay. Each data point represents one subject. Data are presented as mean ± SD (n=3). Mann–Whitney U test was used. *P<0.05, **P<0.001 vs. the normal conjunctival tissue. #P<0.05, ##P<0.001 vs. conjunctival tissues of inflamed conjunctiva.

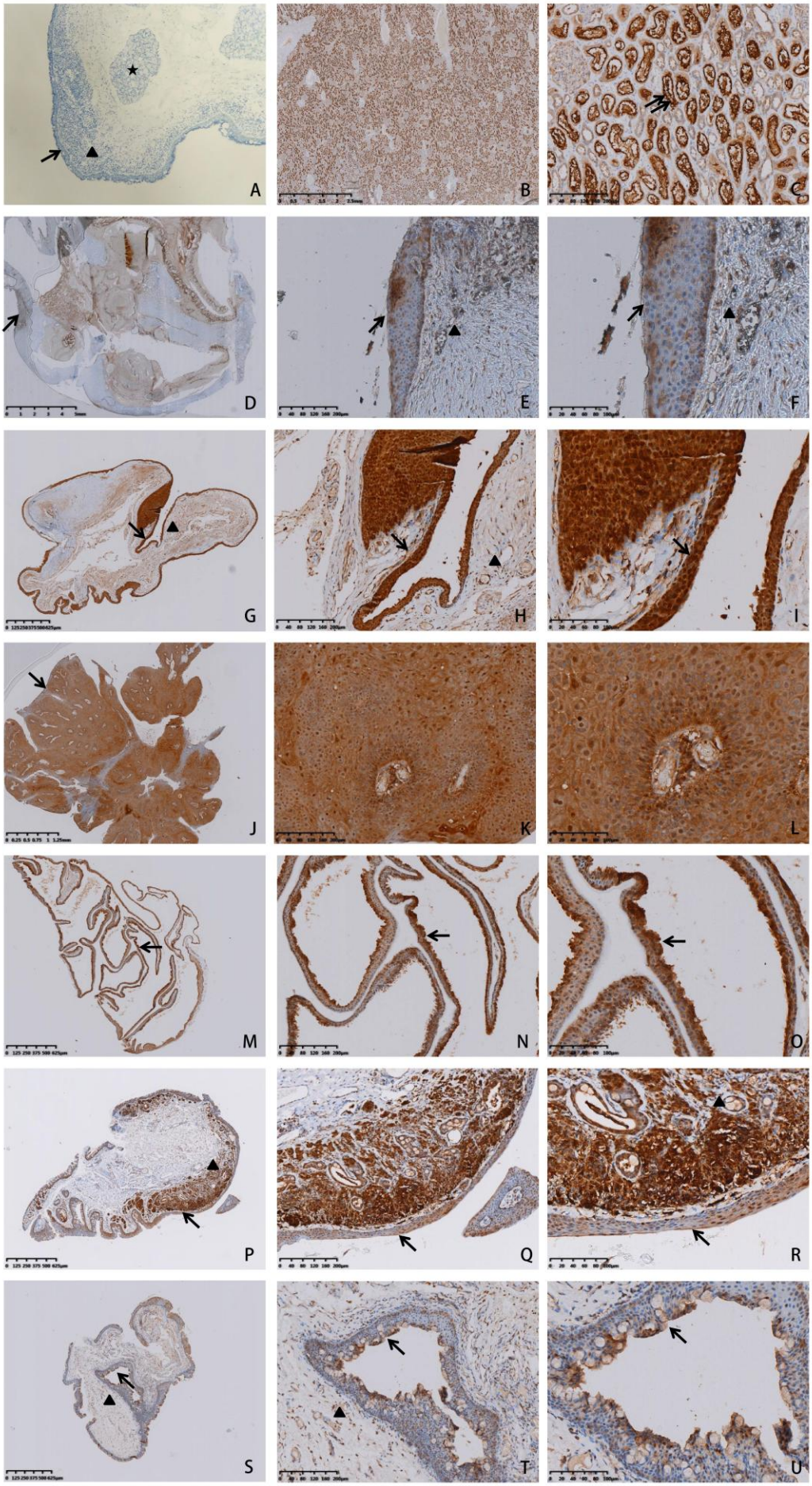
A
B
C
D
E
F
G
H
I
J
K
L
M
N
O
P
Q
R
S
T
U

Figure 2. The normal conjunctiva consists of epithelium (arrow) and stroma (triangle). The stroma is located under the epithelium and is a loose fibrous vascular tissue containing accessory larcimal glands (star), lymphocytes and nerves. Negative control was showed as Figure 2A. The kidney was used as positive control (B, C) and kidney tubules were marked with double arrows. Immunoreactivity is denoted by brown cytoplasmic staining. Normal conjunctival tissue: overview (D) and larger magnification (E, F). Granular ACE2 staining is present in the epithelium. Strong staining is present in conjunctival polypus (G, H and I), conjunctival papilloma (J, K and L), conjunctival cyst (M, N and O), and conjunctival nevi (P, Q and R) . Result expression of ACE2 was weakly positive in conjunctivitis (S, T and U). Images were taken under KFBIO. Results are representative of specimens. The specimens were incubated with polyclonal rabbit anti-ACE2 primary antibody.

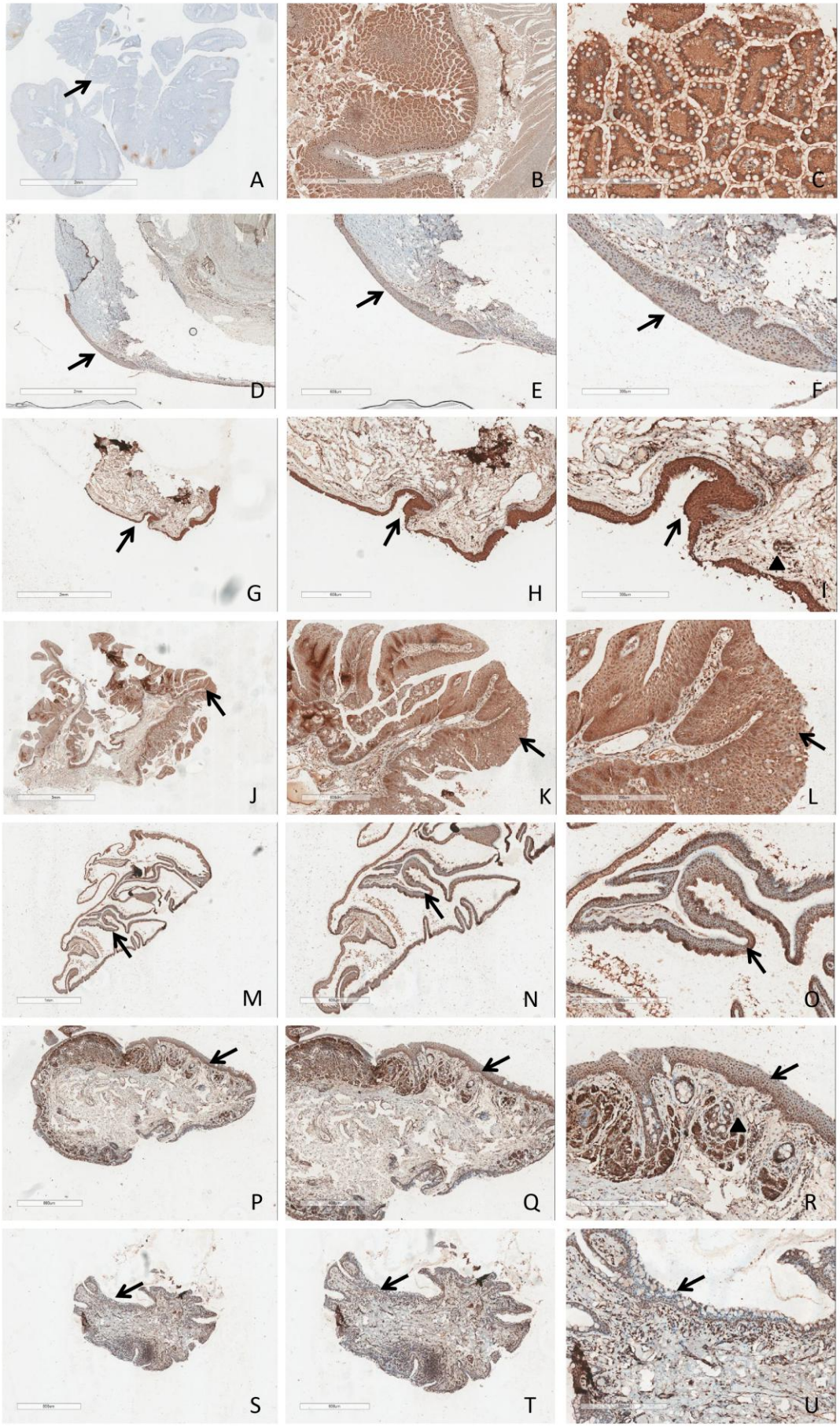
A
B
C
D
E
F
G
H
I
J
K
L
M
N
O
P
Q
R
S
T
U

Figure 3. The normal conjunctiva consists of epithelium (arrow) and stroma (triangle). The stroma is located under the epithelium and is a loose fibrous vascular tissue containing accessory larcimal glands (star), lymphocytes and nerves. Negative control was showed as Figure 3A. The kidney was used as positive control (B, C) and kidney tubules were marked with double arrows. Immunoreactivity is denoted by brown cytoplasmic staining. Normal conjunctival tissue: overview (D) and larger magnification (E, F). Granular ACE2 staining is present in the epithelium. Strong staining is present in conjunctival polypus (G, H and I), conjunctival papilloma (J, K and L), conjunctival cyst (M, N and O), and conjunctival nevi (P, Q and R). Result expression of ACE2 was weakly positive in conjunctivitis (S, T and U). Images were taken under Aperio Scanscope. The specimens were incubated with monoclonal mouse anti-ACE2 antibody.

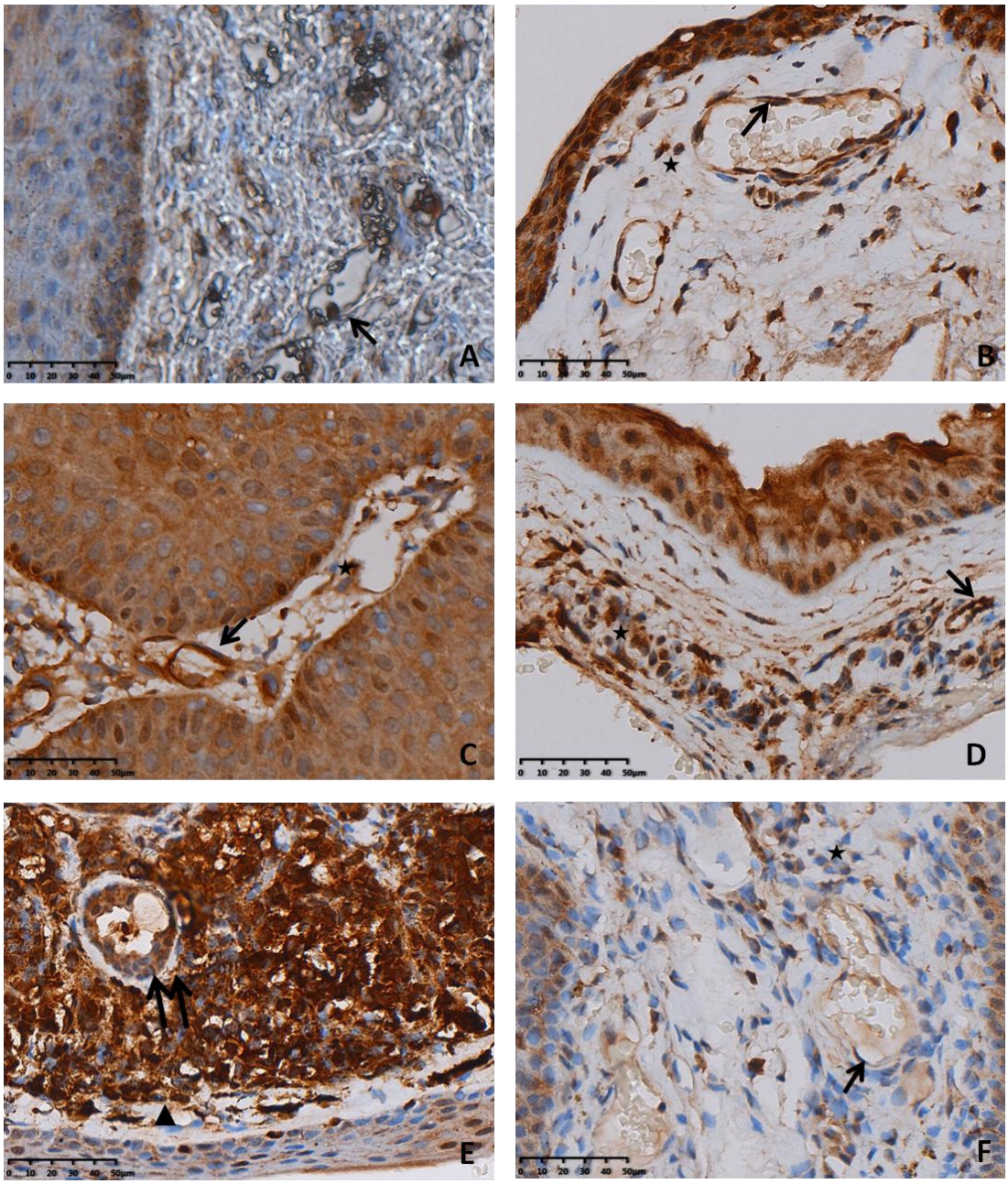

Figure 4. Immunostaining for ACE2 in the vascular endothelium (arrow) and lymphocyte (star), respectively, in the normal conjunctival tissue (A), conjunctival polyps (B), conjunctival papilloma (C), conjunctival cyst (D), and conjunctivitis (F). In the conjunctival nevi (E), strong staining can be seen in the melanocytes (arrow-head) and eccrine sweat gland cells (double arrow). Results are representative of specimens. The specimens were incubated with polyclonal rabbit anti-ACE2 primary antibody.

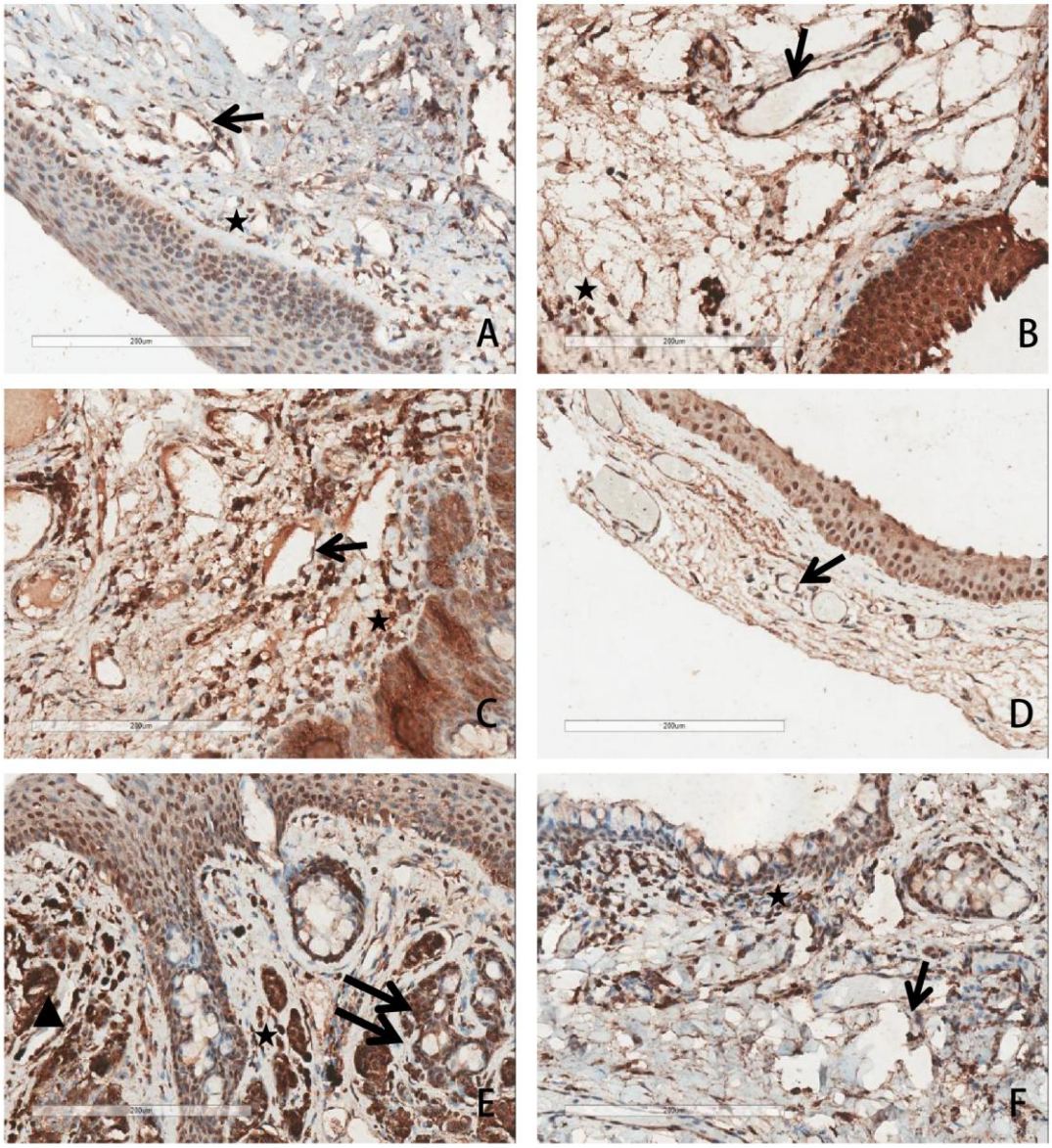

Figure 5. Immunostaining for ACE2 in the vascular endothelium (arrow) and lymphocyte (star), respectively, in the normal conjunctival tissue (A), conjunctival polyps (B), conjunctival papilloma (C), conjunctival cyst (D), and conjunctivitis (F). In the conjunctival nevi (E), strong staining can be seen in the melanocytes (arrow-head) and eccrine sweat gland cells (double arrow). Results are representative of specimens. Results are representative of specimens. The specimens were incubated with monoclonal mouse anti-ACE2 antibody.

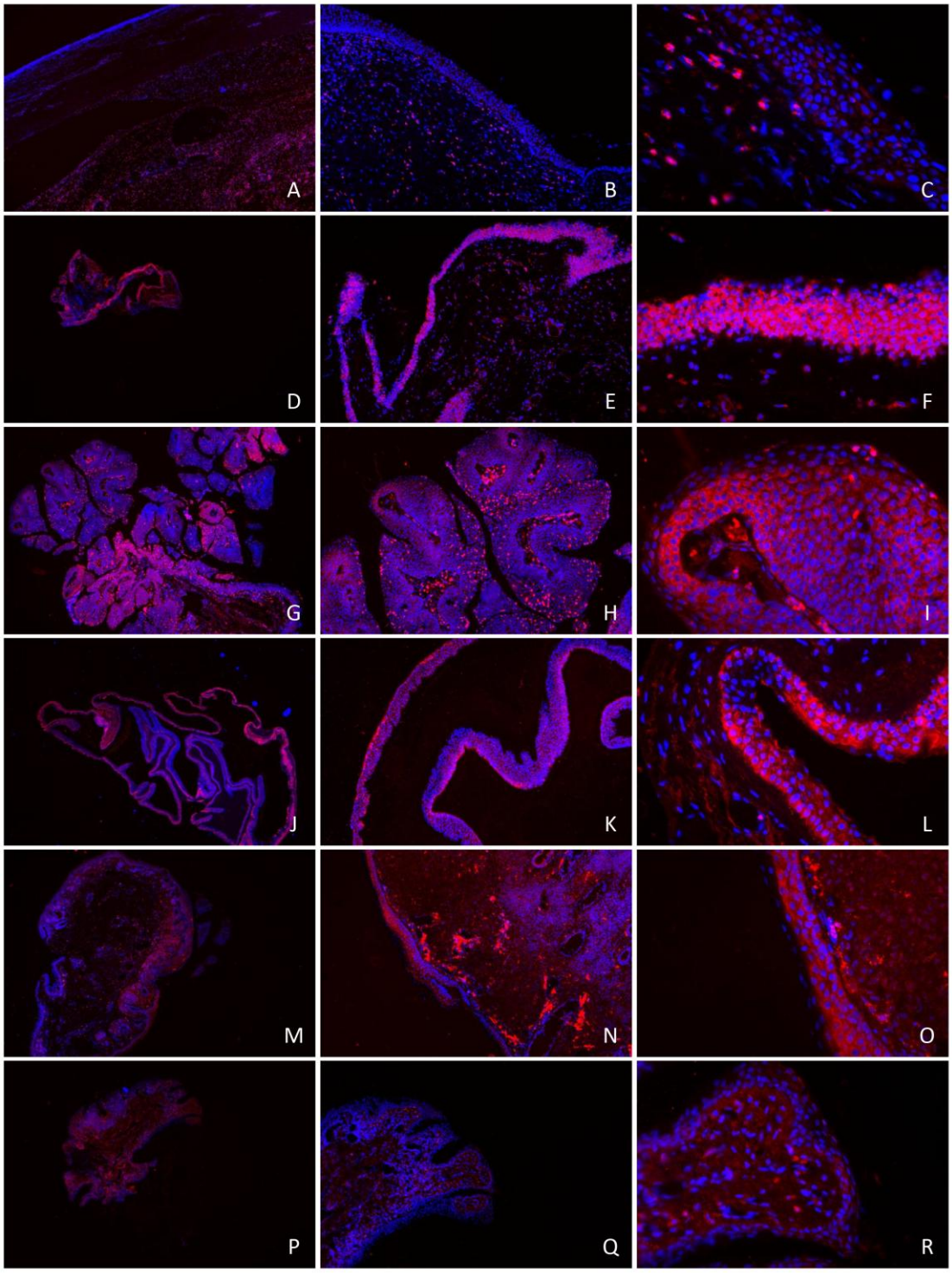

Figure 6. Immunoreactivity is denoted by red staining (DAPI: blue). Normal conjunctival tissue: overview (A) and larger magnification (B, C). Granular ACE2 staining is present in the epithelium. Strong staining is present in conjunctival polypus (D, E and F), conjunctival papilloma (G, H and I), conjunctival cyst (J, K and L), and conjunctival nevi (M, N and 0). Result expression of ACE2 was weakly positive in conjunctivitis (P, Q and R). Results are representative of specimens. The specimens

were incubated with polyclonal rabbit anti-ACE2 primary antibody. Magnification 40x: A, D, G, J, M, P; Magnification 100x: B, E, H, K, N, Q; Magnification 400x: C, F, I, L, O, R.

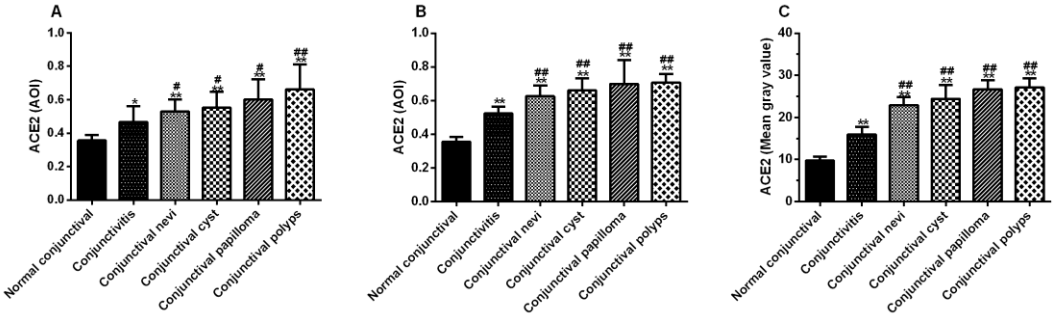

Figure 7. Summary of the quantitative immunohistochemical (A, B) and immunofluorescence (C) staining. Top of the box plot represents the mean; the bar of each box represents the standard deviation. Mann–Whitney U test was used. A: The specimens were incubated with polyclonal rabbit anti-ACE2 antibody; B: The specimens were incubated with monoclonal mouse anti-ACE2 antibody; C: The specimens were incubated with polyclonal rabbit anti-ACE2 primary antibody. *P<0.05, **P<0.001 vs. the normal conjunctival tissue. $^{\#}$P<0.05, $^{\#\#}$P<0.001 vs. conjunctival tissues of inflamed conjunctiva.