medRxiv preprint doi: https://doi.org/10.1101/2020.05.15.20103531; this version posted May 20, 2020. The copyright holder for this preprint (which was not certified by peer review) is the author/funder, who has granted medRxiv a license to display the preprint in perpetuity. All rights reserved. No reuse allowed without permission.

# IL6 inhibition in critically ill COVID-19 patients is associated with increased secondary infections

Lucas M. Kimmig, MD[1,2]*, David Wu, MD, PhD[1,2,*], Matthew Gold, MD[1], Natasha N Pettit, PharmD[1,3], David Pitrak, MD[1,3], Jeffery Mueller, DO[4], Aliya N. Husain, MD[4], Ece A. Mutlu, MD, MS, MBA[5] and Gökhan M. Mutlu, MD[1,2]

[1]Department of Medicine, [2]Section of Pulmonary and Critical Care Medicine and [3]Section of Infectious Diseases and [4]Department of Pathology, University of Chicago, Chicago, Illinois, and [5]Section of Gastroenterology and Hepatology, Rush University, Chicago, Illinois

*Equal contribution

Word count: 974

Corresponding author:

Gökhan M. Mutlu, MD
Section of Pulmonary and Critical Care Medicine
University of Chicago
5841 S Maryland Ave
MC6026
Chicago, IL 60637
Phone: 773-703-1002
Fax: 773-702-6500
Email: gmutlu@uchicago.edu

**NOTE: This preprint reports new research that has not been certified by peer review and should not be used to guide clinical practice.**

medRxiv preprint doi: https://doi.org/10.1101/2020.05.15.20103531; this version posted May 20, 2020. The copyright holder for this preprint (which was not certified by peer review) is the author/funder, who has granted medRxiv a license to display the preprint in perpetuity. All rights reserved. No reuse allowed without permission.

While there has been an increase in the number of clinical trials, currently there are no effective therapies for COVID-19 infection. As a result, the management of COVID-19 patients including those who are critically ill remains supportive. Reports from China suggested that an exaggerated immune response may play a role in the development of respiratory failure, shock, and multiorgan dysfunction in critically ill patients with COVID-19 [1]. Similarities between the exaggerated immune response associated with COVID-19 or sepsis in general and the cytokine release syndrome (CRS) reported in patients with CAR T-cell therapy led to the use of tocilizumab, an anti-IL-6 therapy to attenuate hyperimmune responses associated with COVID [2]. At this time, we do not have any evidence that patients with COVID-19 benefit from tocilizumab or which criteria to apply in selecting patients to receive tocilizumab. Inhibition of IL-6 may also have adverse consequences. Mice lacking a normal IL-6 response have impaired immunity against viral, bacterial and fungal pathogens [3]. Humans treated with tocilizumab had higher risk of serious bacterial, skin and soft tissue infections [4-6].

We observed increased bacterial infections in critically ill COVID-19 patients and thus sought to determine whether there was an association between tocilizumab administration and secondary infections. The study was approved by the University of Chicago Institutional Review Board. Adult patients (>18 years of age) admitted to the adult COVID-19 intensive care unit with COVID-19 between the dates of March 1, 2020 and April 27, 202 were randomly selected for analysis. Out of 60 critically ill COVID-19 patients, 28 received tocilizumab 400 mg once except for three patients who received two doses (800 mg total) and one patient who received a single 800 mg dose. Our protocol recommended 400 mg flat dosing of tocilizumab with the potential for redosing based on clinical response (e.g. oxygenation status, hemodynamic stability, inflammatory marker response). We compared bacterial and fungal infections in those that received the drug to those that did not. There were no differences in patient baseline characteristics (including age, sex, Charlson co-morbidity index (CCI), as well as variables that

medRxiv preprint doi: https://doi.org/10.1101/2020.05.15.20103531; this version posted May 20, 2020. The copyright holder for this preprint (which was not certified by peer review) is the author/funder, who has granted medRxiv a license to display the preprint in perpetuity. All rights reserved. No reuse allowed without permission.

may not be captured by the latter index such as immunosuppression, hypertension, etc.) between the two groups (Table 1). Secondary infections were defined by positive culture data or high clinical suspicion of infection requiring the initiation of antimicrobials and documentation in the progress note.

Receiving tocilizumab was associated with a higher incidence of secondary bacterial infections including hospital acquired pneumonia and ventilator associated pneumonia (64.3% vs. 31.3% p=0.010). In a logistic regression model for bacterial infections as the outcome that also contained age, sex, and the CCI as independent variables, tocilizumab administration was independently associated with presence of secondary bacterial infections (Odds ratio: 3.960 (95% CI 1.351-11.607), p=0.033). While there were two patients with fungal infections, including one patient with Mucor pneumonia and another patient with sinusitis in the tocilizumab group compared with none in the non-tocilizumab group, this did not reach statistical significance. Lastly, we performed post-mortem evaluation of 7 cases; 3 received tocilizumab and 4 did not. All three cases who received tocilizumab had evidence of pneumonia on pathology (Figure 1). Two of four patients who did not receive tocilizumab were nursing home residents with history of stroke and dementia and they died on the same day of admission. Their post-mortem evaluation showed evidence of aspiration pneumonia. The other two patients who did not receive tocilizumab were hospitalized for 4 and 12 days. Their lungs demonstrated only pathological changes consistent with diffuse alveolar damage without any evidence of pneumonia (Figure 1). These findings raise concerns about the use of tocilizumab in the presence of an infection to attenuate CRS. In particular, the occurrence of secondary bacterial infections may prolong ICU stays, and the occurrence of secondary fungal infections stands out as unusual in critical care patients without traditional risk factors (e.g. neutropenia). Since microbiologic identification of the causative organism is frequently not achieved in infections, it is possible that our definition is too broad and may capture some patients who were treated for clinical deterioration. However,

medRxiv preprint doi: https://doi.org/10.1101/2020.05.15.20103531; this version posted May 20, 2020. The copyright holder for this preprint (which was not certified by peer review) is the author/funder, who has granted medRxiv a license to display the preprint in perpetuity. All rights reserved. No reuse allowed without permission.

our definition is similar to other studies where diagnoses are based on coding. Restriction to only microbiologically proven cases would likely miss a majority of infections and may capture contaminants.

Host response to the pathogen during sepsis is a double-edged sword. Cytokines such as IL-6 may contribute to organ injury and death, but they are also central to innate immunity and microbial clearance. While there may be a subset of patients who may potentially benefit from the use of tocilizumab, current evidence does not support the routine use of tocilizumab or other drugs that regulate host immune response (i.e., corticosteroids, anti-IL1, anti-TNFα) in COVID-19 or non-COVID-19 sepsis. Proper discriminatory values that reliably identify patients in whom hyper-inflammation is the key driver of pathogenesis remain poorly defined. While there is evidence of efficacy for IL-6 blockade in rheumatological diseases and to manage complications of T cell engaging therapies, which are driven by a primary immune response, there is no evidence that immune blockade is clinically beneficial when microbial infections drive the host response. Indeed, a previous anti-cytokine strategy targeting TNFα increased mortality in septic patients[7] and was linked to increased risk of infections[8]. While COVID-19 may share clinical features with CAR-T cell-induced CRS, this does not necessarily imply that the syndromic similarities are causally related. Use of experimental therapies outside of properly controlled clinical trials impairs the ability for definitive evaluation of cause and effect and could bring about untoward and possibly lethal side effects. Our findings should raise physician awareness about the potential side effects of tocilizumab on pathogen clearance and development of secondary infections. It also calls for the urgent need to study all drugs including any immunosuppressive agents in randomized controlled trials to better understand their role in any hyperimmune response and on clearance of SARS-CoV-2 and other hospital-acquired pathogens.

medRxiv preprint doi: https://doi.org/10.1101/2020.05.15.20103531; this version posted May 20, 2020. The copyright holder for this preprint (which was not certified by peer review) is the author/funder, who has granted medRxiv a license to display the preprint in perpetuity. All rights reserved. No reuse allowed without permission.

## REFERENCES

1. Zhou F, Yu T, Du R, et al. Clinical course and risk factors for mortality of adult inpatients with COVID-19 in Wuhan, China: a retrospective cohort study. Lancet 2020;395:1054-62.
2. Mehta P, McAuley DF, Brown M, et al. COVID-19: consider cytokine storm syndromes and immunosuppression. Lancet 2020;395:1033-4.
3. Kopf M, Baumann H, Freer G, et al. Impaired immune and acute-phase responses in interleukin-6-deficient mice. Nature 1994;368:339-42.
4. Narazaki M, Kishimoto T. The Two-Faced Cytokine IL-6 in Host Defense and Diseases. Int J Mol Sci 2018;19.
5. Lang VR, Englbrecht M, Rech J, et al. Risk of infections in rheumatoid arthritis patients treated with tocilizumab. Rheumatology (Oxford) 2012;51:852-7.
6. Pawar A, Desai RJ, Solomon DH, et al. Risk of serious infections in tocilizumab versus other biologic drugs in patients with rheumatoid arthritis: a multidatabase cohort study. Ann Rheum Dis 2019;78:456-64.
7. Fisher CJ, Jr., Agosti JM, Opal SM, et al. Treatment of septic shock with the tumor necrosis factor receptor:Fc fusion protein. The Soluble TNF Receptor Sepsis Study Group. N Engl J Med 1996;334:1697-702.
8. Ali T, Kaitha S, Mahmood S, Ftesi A, Stone J, Bronze MS. Clinical use of anti-TNF therapy and increased risk of infections. Drug Healthc Patient Saf 2013;5:79-99.

medRxiv preprint doi: https://doi.org/10.1101/2020.05.15.20103531; this version posted May 20, 2020. The copyright holder for this preprint (which was not certified by peer review) is the author/funder, who has granted medRxiv a license to display the preprint in perpetuity. All rights reserved. No reuse allowed without permission.

**Table 1. Co-morbidities and Outcomes**

| | No tocilizumab (n=32) | Tocilizumab (n=28) | p value* |
|---|---|---|---|
| **Patient characteristics and comorbidities** | | | |
| Age (Mean +/- Standard Deviation) | 64.09 ± 14.24 | 63.86 ± 16.04 | |
| Charlson Co-morbidity Index (CCI) | | | 0.952 |
| Mean | 4.81 | 3.36 | |
| Median | 4.0 | 4.0 | |
| | **n (%)** | **n (%)** | |
| CCI Categories | | | |
| CCI=0 | 3 (9.4) | 1 (3.6) | |
| CCI=1-2 | 6 (18.8) | 10 (35.7) | |
| CCI=3-4 | 8 (25.0) | 6 (21.4) | |
| CCI>=5 | 15 (46.8) | 11 (39.3) | |
| Sex (Male) | 15 (46.8) | 20 (71.4) | 0.054 |
| Diabetes mellitus | 16 (69.6) | 10 (35.7) | 0.265 |
| Hypertension | 24 (75.0) | 15 (53.6) | 0.083 |
| CKD | 8 (25.0) | 2 (7.1) | 0.064 |
| ESRD | 2 (6.3) | 1 (3.6) | 0.635 |
| Obese (BMI>=30) | 20 (63.0) | 14 (50.0) | 0.330 |
| Overweight (BMI=25-30) | 3 (9.4) | 2 (7.1) | 1.000 |
| Myocardial Infarction History | 3 (9.4) | 3 (10.7) | 1.000 |
| Congestive Heart Failure | 10 (31.3) | 3 (10.7) | 0.066 |
| Peripheral Vascular Disease | 3 (9.4) | 3 (10.7) | 1.000 |
| Any Cardiovascular Disease | 7 (21.9) | 3 (10.7) | 0.187 |
| Hyperlipidemia | 5 (15.6) | 6 (21.4) | 0.563 |
| Any Pulmonary Disease | 12 (37.5) | 4 (14.3) | 0.125 |
| Chronic Obstructive Pulmonary Disease | 7 (21.9) | 3 (10.7) | 0.312 |
| Stroke/TIA | 7 (21.9) | 2 (7.1) | 0.111 |
| Hemiplegia | 4 (12.5) | 0 (0) | 0.116 |
| Dementia | 5 (15.6) | 1 (3.6) | 0.201 |
| Any Connective Tissue Disorder | 0 (0) | 1 (3.6) | 0.467 |
| Any Liver Disease | 1 (3.1) | 0 (0) | 1.000 |
| Cancer | 3 (9.4) | 4 (14.3) | 0.695 |
| Localized | 2 (6.3) | 4 (14.3) | 0.404 |
| Metastatic | 1 (3.1) | 0 (0) | 0.494 |
| Substance abuse | 0 (0) | 1 (3.6) | 0.467 |
| Smoking | 16 (50.0) | 6 (21.4) | 0.027 |
| **Outcome** | | | 0.127 |
| Discharged | 16 (50) | 7 (25) | |
| Death | 8 (25) | 12 (42.9) | |
| Still hospitalized | 8 (25) | 9 (32.1) | |
| **Infectious Outcomes** | | | |
| Bacterial infections | 10 (31.3) | 18 (64.3) | 0.010 |
| Hospital/ventilator-acquired pneumonia | 7 (21.9) | 13 (46.4) | |
| Sepsis, other source or undefined | 2 (6.25) | 4 (14.3) | |
| Fungal infections# | 0 | 2 (7.1) | 0.096 |
| Pneumonia | 0 | 1 (3.6) | |
| Sinusitis | 0 | 2 (7.1) | |

*T-tests, Mann-Whitney U, Chi-Square, or Fisher Exact tests were used as appropriate.

# One patient had fungal infection in different sites. One additional patient who received tocilizumab developed oral thrush.

medRxiv preprint doi: https://doi.org/10.1101/2020.05.15.20103531; this version posted May 20, 2020. The copyright holder for this preprint (which was not certified by peer review) is the author/funder, who has granted medRxiv a license to display the preprint in perpetuity. All rights reserved. No reuse allowed without permission.

## FIGURE LEGEND

**Figure 1. Postmortem histopathology of lungs from COVID-19 patients.** Low (100x) and high power (200x) images of lungs from patients who died due to COVID-19. **A.** Organizing hyaline membranes are seen in the lung which has pre-existing emphysema (100x). Higher power shows fibrin, fibroblasts and mononuclear cells incorporated into the alveolar walls (200x). **B.** There is diffuse alveolar damage with hyaline membranes lining alveoli (100x). Higher power shows minimal inflammation with only a few mononuclear cells (200x). **C.** There is extensive intra-alveolar inflammation (neutrophils) in an otherwise normal lung (100x). On higher power, there is minimal alveolar wall thickening by inflammatory cells (also mainly neutrophils on myeloperoxidase staining and only rare lymphocytes) (200x). **D.** Majority of the sections from this case show organizing intra-alveolar fibrin (100x). Several foci of acute inflammation with alveolar filling are present, as seen here on higher power (200x).
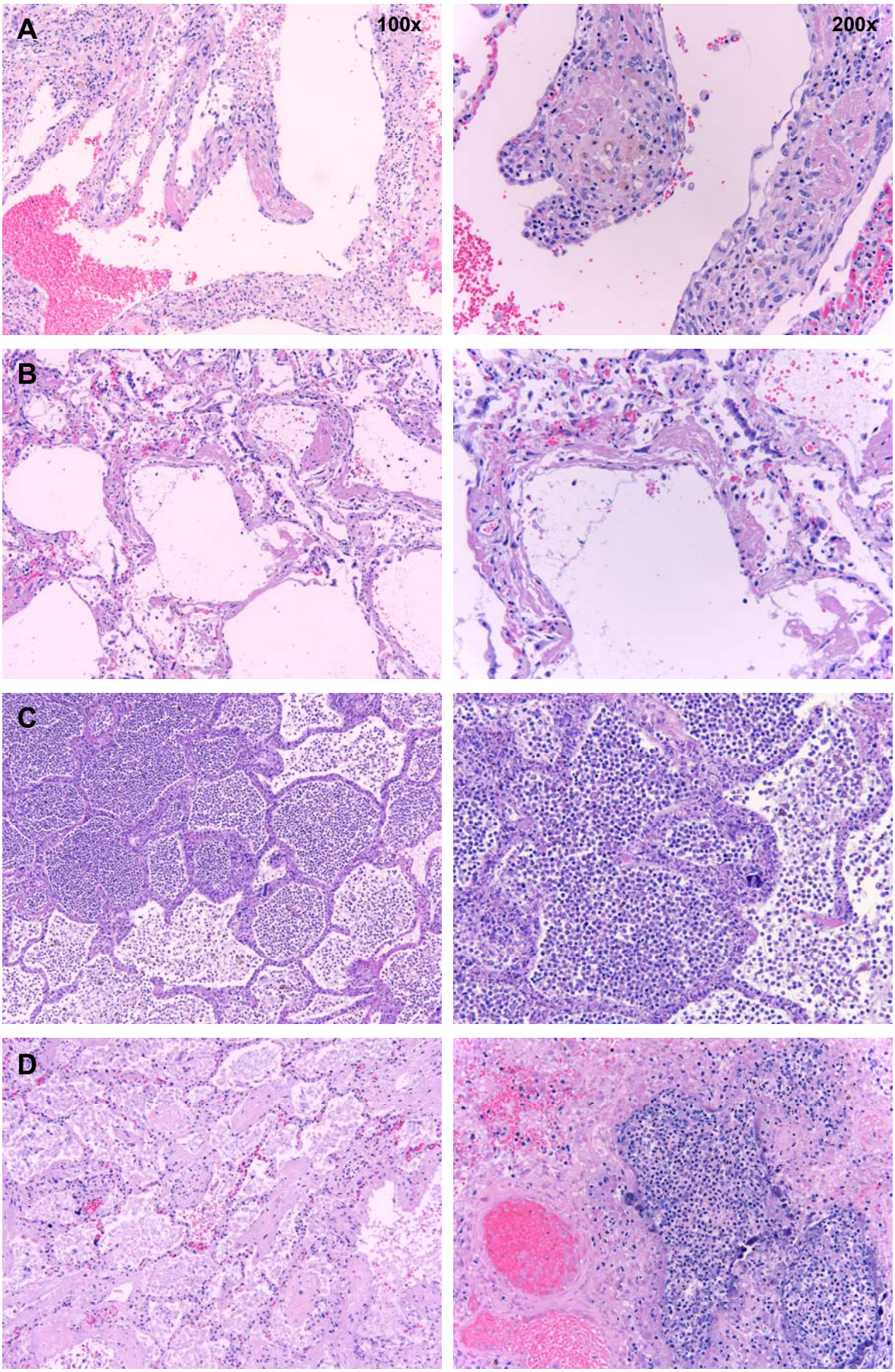
medRxiv preprint doi: https://doi.org/10.1101/2020.05.15.20103531; this version posted May 20, 2020. The copyright holder for this preprint (which was not certified by peer review) is the author/funder, who has granted medRxiv a license to display the preprint in perpetuity. All rights reserved. No reuse allowed without permission.