Clinical characteristics and early outcomes in patients with COVID-19 treated with tocilizumab at a United States academic center

Casey A. Rimland,[1a] Camille E. Morgan,[1,2a] Griffin J. Bell,[2] Min K. Kim,[3] Tanner Hedrick,[4] Ashley Marx,[4] Brian Bramson,[3] Sonia Napravnik,[2,3] John L. Schmitz,[5] Shannon S. Carson,[6] William A. Fischer,[6] Joseph J. Eron,[3] Cynthia L. Gay,[3] Jonathan B. Parr[3*]
([a] Contributed equally, * Corresponding author)

[1] Medical Scientist Training Program, University of North Carolina at Chapel Hill (UNC), Chapel Hill, NC
[2] Department of Epidemiology, UNC Gillings School of Global Public Health, Chapel Hill, NC
[3] Division of Infectious Diseases, Department of Medicine, UNC School of Medicine, Chapel Hill, NC
[4] Department of Pharmacy, UNC Medical Center, Chapel Hill, NC
[5] Department of Pathology and Laboratory Medicine, UNC School of Medicine, Chapel Hill, NC
[6] Division of Pulmonary Diseases and Critical Care Medicine, Department of Medicine, UNC School of Medicine, Chapel Hill, NC

Classification: Biological Sciences, Medical Sciences

Keywords: interleukin 6 (IL-6), SARS-CoV-2, tocilizumab, cytokine release syndrome, COVID-19

Corresponding author: Jonathan B. Parr, MD, MPH; 130 Mason Farm Rd, Chapel Hill, NC 27599; 1-919-843-4132; jonathan_parr@med.unc.edu

Author Contributions: CAR and CEM extracted data, analyzed data, and wrote the first draft. GJB analyzed and visualized data. MKK extracted data. JBP conceptualized and supervised the study. CAR, CEM, GJB, MKK, TH, AM, BB, SN, JLS, SSC, WAF, JJE, CLG, and JBP reviewed and edited the final draft.

This PDF file includes:
Main Text
Figure 1
Table 1

ABSTRACT

Limited evidence is available to guide treatment of coronavirus disease 2019 (COVID-19), caused by the novel severe acute respiratory syndrome coronavirus 2 (SARS-CoV-2). A hyperinflammatory state mediated by interleukin-6 (IL-6) has been proposed as a driver of severe disease. Use of the IL-6 receptor inhibitor tocilizumab for severe COVID-19 was first reported in China, where a case series described marked improvements in inflammatory markers, fever, oxygen requirement, and outcomes following its administration. Here, we provide the first description of a tocilizumab-treated cohort of patients with COVID-19 in the United States. We describe 11 patients from a single academic medical center, nine (82%) of whom were critically ill requiring mechanical ventilation in an intensive care unit at the time of tocilizumab administration. C-reactive protein levels decreased in all patients following treatment (median 211.6 pre- *vs.* 19.7 mg/L 5 days post-tocilizumab [p=0.001]). When IL-6 levels were obtained before and after therapy, wide variation was seen in baseline levels; post-dose IL-6 concentrations were consistently increased. In contrast to prior reports, we did not observe significant clinical improvement in temperature or oxygen requirements in most patients. Two patients were discharged (18%), five remained in critical condition in the intensive care unit (46%), one was weaned off the ventilator to room air (9%), and three died (27%). Our findings suggest that tocilizumab should be used with caution in severe and critically ill patients and highlight the need for data from randomized controlled trials to determine its efficacy in the treatment of COVID-19.

INTRODUCTION

A hyperinflammatory state is posited as a driver of severe COVID-19 (1). Elevations of IL-6, a pro-inflammatory cytokine, have been described in acute respiratory distress syndrome and in cytokine release syndrome (CRS) following chimeric antigen receptor (CAR) T-cell immunotherapy (2, 3). Recently, a role for IL-6-driven inflammation in severe COVID-19 was suggested, as increased levels were associated with increased mortality (4). Tocilizumab, a humanized monoclonal antibody that binds the IL-6 receptor and prevents signaling (5), is used in inflammatory diseases and for treatment of CRS (6, 7) and has been proposed as a treatment for COVID-19 (8).

Reports of tocilizumab use for COVID-19 are limited to two retrospective case series from China (9, 10) and four single-case reports (11–14). Xu *et al*. (9) reported improved inflammatory markers, oxygen requirements, and fever in 21 patients after tocilizumab treatment and concluded that it was an effective treatment in severe COVID-19. However, these patients were also treated with corticosteroids, lopinavir/ritonavir, interferon-α, and ribavirin, making the effect of tocilizumab difficult to interpret. Further, only two patients required mechanical ventilation. Luo *et al.*'s (10) description of 15 patients treated with tocilizumab included a larger cohort of critically ill patients and more measured results, with 20% mortality and all remaining patients hospitalized at the time of the report.

Given the paucity of data on tocilizumab use in COVID-19 and the lack of peer-reviewed case series outside of China, we evaluated 11 patients treated with tocilizumab for COVID-19 at our institution. We detail their clinical and laboratory characteristics before and after treatment with tocilizumab and reconsider its use in patients with severe or critical COVID-19.

METHODS

We performed a retrospective cohort study of patients with COVID-19 who were treated with tocilizumab at the University of North Carolina at Chapel Hill (UNC) Medical Center between March 21st and April 25th, 2020. Demographic, laboratory, and clinical data were extracted from the medical record. COVID-19 was diagnosed using nasopharyngeal swabs and SARS-CoV-2 reverse-transcriptase PCR (RT-PCR). IL-6 testing was conducted at Mayo Clinic Laboratories (Rochester, MN) using an electrochemiluminescence assay. Baseline IL-6 values for two patients were obtained from a multi-cytokine panel (lower limit of detection [LOD] of 5.0 pg/mL); all others were from a standalone IL-6 assay (LOD 1.8 pg/ml). Disease severity was defined according to the World Health Organization (WHO) COVID-19 clinical status scale with minor modification (15). Descriptive statistics were calculated using JMP 15 (SAS Institute, Cary, NC). The Wilcoxon signed rank test was performed in Prism 8 (GraphPad, La Jolla, CA), and data was visualized using the *tidyverse* package in R 3.6.0 (R Core Team, Vienna, Austria). The study was approved by the UNC Institutional Review Board (#20-1095).

RESULTS

Patient population

Eleven patients with confirmed SARS-CoV-2 infection who were treated with tocilizumab for COVID-19 were included. Demographic, clinical, and laboratory data are displayed in **Table 1.** Most patients were male; were black or Latino; worked in a factory or the food industry; and suffered from multiple comorbidities, including obesity and/or hypertension. Patients took a median of seven (IQR 3.25-12) home medications. Five (46%) took an angiotensin converting enzyme inhibitor (ACEI) or angiotensin receptor blocker (ARB) at baseline. Seven were

transferred from outside hospitals; all within one day of initial presentation. One (9%) was previously admitted for COVID-19 and required readmission. Five (46%) were diagnosed with COVID-19 by SARS-CoV-2 RT-PCR as outpatients prior to presentation.

Hospital course

Most patients had severe or critical COVID-19 by modified WHO criteria, elevated inflammatory markers, lymphopenia, and abnormal chest imaging upon admission. All patients required supplemental oxygen on admission, including five (46%) via low-flow nasal cannula (LFNC ≤ 10L/min), two (18%) via high-flow nasal cannula (HFNC), and four (36%) via mechanical ventilation. During the observation period, eight (73%) were critically ill requiring mechanical ventilation and vasopressors, one (9%) was critically ill requiring mechanical ventilation alone, one (9%) with do-not-intubate status received HFNC only, and one (9%) had mild disease requiring LFNC.

Outcomes after tocilizumab

Tocilizumab was administered a median of one day (IQR 1-4) from admission and nine days (IQR 7-14) after symptom onset. Two of six patients with available baseline IL-6 levels had low levels, one below the assay's LOD (≤5 pg/mL) and another of 10.4 pg/mL. Four of five patients with available IL-6 levels after tocilizumab had IL-6 levels above the upper limit of quantification. All four patients with matched baseline and post-tocilizumab testing had increased IL-6 after tocilizumab.

CRP and fibrinogen decreased significantly after tocilizumab in all patients (**Figure 1A,** median CRP 211.6 vs 19.7 mg/L [p=0.001] and fibrinogen 767 mg/dL vs. 420 mg/dL [p=0.002] pre- and 5 days post-tocilizumab, respectively). However, other laboratory markers did not show clear trends (**Figure 1B**). In addition, temperature did not show obvious improvement (**Figure 1C**), and only a limited number showed improvement in oxygen requirements (patients 1, 2 and 11; **Figure 1D**).

At end of follow-up, patients had been observed for a median of 17 days (IQR=11-24, range=7-34) after their initial tocilizumab dose. Three died (27%); five (45%) remained in the intensive care unit (ICU) on mechanical ventilation, receiving vasopressors or hemodialysis; one (9%) had been transferred from the ICU to floor status and weaned to room air; and two (18%) had been discharged home without oxygen. Seven patients (64%) had minimally elevated liver function tests shortly after tocilizumab administration. While two patients were diagnosed with ileus and two were diagnosed with bacterial pneumonia after tocilizumab administration, no serious adverse events were observed**.**

DISCUSSION

While tocilizumab was recently described as a promising therapy for patients with severe COVID-19 (9), our findings raise questions about its use in critically ill patients. We report the first observational data from a cohort of patients with COVID-19 treated with tocilizumab in the United States, almost all of whom required advanced ICU care. CRP and fibrinogen rapidly improved after tocilizumab administration as previously observed by Xu *et al*. (9) and Luo *et al*. (10), but we did not observe clear evidence of improvement in other markers of disease severity or clinical outcomes in our cohort. These findings, in addition to low baseline IL-6 levels observed in a subset of tocilizumab-treated patients, suggest a need for caution in patients presenting with severe or critical COVID-19, especially those without baseline IL-6 data.

Important clinical and demographic differences exist between our cohort and those reported by Xu *et al.* (9) and Luo *et al.* (10). The cohort described by Xu *et al*. (9) had few patients requiring mechanical ventilation (n=2/21), with almost half of their patients requiring LFNC or no oxygen (n=9/21). Luo *et al.* (10) did not report specific oxygen requirements of their cohort but did include more patients reported as critically ill (n=7/15). Our cohort included higher rates of baseline hypertension (n=10/11, 91%) compared to Luo *et al*. (10) (n=9/15, 60%) and Xu *et al.* (9) (n=9/21, 43%), a majority were black/Latino (73%) and were overweight or obese (91%). We also observed substantially lower baseline IL-6 levels in our patients compared to those reported by both Xu *et al.* (9) and Luo *et al.* (10), although IL-6 assays were conducted in different laboratories using different methods. Two patients in our cohort had low baseline IL-6 levels, one below the detection level, despite elevation in other markers of inflammation including CRP, raising questions about IL-6's role in the severe COVID-19 inflammatory state. Our findings demonstrate the challenge of defining CRS in the setting of COVID-19, given the lack of standardization across IL-6 assays and limited data to support IL-6 cut-offs for use of tocilizumab in patients presenting with severe infection.

Our findings contrast with previous reports and do not provide clear evidence of clinical improvement after tocilizumab treatment in patients with severe COVID-19. Several explanations for these differences should be considered. First, our patients were more severely ill than previous cohorts. It is possible that tocilizumab was administered too late in the disease process to offer benefit. Second, our patient cohort was more racially and ethnically diverse and had more comorbidities than those reported in China. Our cohort was largely composed of patients with obesity and hypertension, including many treated with ACEI/ARBs. Third, improvements observed in prior, less severely ill patient cohorts, might have occurred as a part of the normal disease process, with or without tocilizumab administration.

In conclusion, findings from our observational cohort indicate that tocilizumab use in severe and critical COVID-19 patients should be considered cautiously. Tocilizumab dramatically reduces select inflammatory markers (CRP, fibrinogen), but it is unclear whether its activity leads to equally dramatic effects on clinical outcomes, especially in critically ill patients. The role of IL-6 in severe COVID-19 needs to be closely examined, and randomized controlled trials are essential to determine when, or if, tocilizumab should be used in routine COVID-19 care.

ACKNOWLEDGMENTS

The authors would like to thank the UNC nurses; laboratory staff; and allied health providers involved in the care of patients with COVID-19. We also thank Carlton Moore and Hannah Little for assistance with initial exploration of data and numerous colleagues in the Divisions of Hospital Medicine, Pulmonary and Critical Care, and Infectious Diseases who provided direct care to these patients.

The authors report no designated funding for the project. CAR and CEM receive training support from the University of North Carolina at Chapel Hill Medical Scientist Training Program. CAR additionally receives training support from the National Institutes of Health MD/PhD Partnership Program.

CONFLICTS OF INTEREST

JBP reports research support outside the submitted work from Gilead Sciences and the World Health Organization, and non-financial support from Abbott Laboratories. CLG has received research support outside the submitted work from Viiv Healthcare and Gilead Sciences. SSC reports research support outside of the submitted work from Biomarck Pharmaceuticals.

FIGURE LEGENDS

Figure 1. Laboratory and clinical outcomes of patients treated with tocilizumab. (**A-B**) Trends in laboratory values over time following tocilizumab administration. Blue lines indicate medians; IQRs are depicted by blue shading. Laboratory reference ranges are shown by dashed red lines. (**C-D**) Trends in oxygen requirements and temperature over time following tocilizumab administration. Orange lines were produced using locally estimated scatterplot smoothing. Patient outcomes are indicated in parentheses. For the single patient (#6) treated with two doses of Tocilizumab, time 0 refers to the time of initial administration. Abbreviations: IQR, interquartile range; ICU, intensive care unit.

REFERENCES

1. Q. Ye, B. Wang, J. Mao, The pathogenesis and treatment of the `Cytokine Storm' in COVID-19. *J. Infect.* (2020) https:/doi.org/10.1016/j.jinf.2020.03.037.
2. I. P. Aisiku, J.-M. Yamal, P. Doshi, J. S. Benoit, S. Gopinath, J. C. Goodman, C. S. Robertson, Plasma cytokines IL-6, IL-8, and IL-10 are associated with the development of acute respiratory distress syndrome in patients with severe traumatic brain injury. *Crit. Care Lond. Engl.* **20**, 288 (2016).
3. T. Giavridis, S. J. C. van der Stegen, J. Eyquem, M. Hamieh, A. Piersigilli, M. Sadelain, CAR T cell-induced cytokine release syndrome is mediated by macrophages and abated by IL-1 blockade. *Nat. Med.* **24**, 731–738 (2018).
4. F. Zhou, T. Yu, R. Du, G. Fan, Y. Liu, *et al.*, Clinical course and risk factors for mortality of adult inpatients with COVID-19 in Wuhan, China: a retrospective cohort study. *Lancet* **395**, 1054–1062 (2020).
5. K. Sato, M. Tsuchiya, J. Saldanha, Y. Koishihara, Y. Ohsugi, T. Kishimoto, M. M. Bendig, Reshaping a Human Antibody to Inhibit the Interleukin 6-dependent Tumor Cell Growth. *Cancer Res.* **53**, 851–856 (1993).
6. J.-F. Rossi, Z.-Y. Lu, M. Jourdan, B. Klein, Interleukin-6 as a Therapeutic Target. *Clin. Cancer Res.* **21**, 1248–1257 (2015).
7. S. L. Maude, D. Barrett, D. T. Teachey, S. A. Grupp, Managing Cytokine Release Syndrome Associated With Novel T Cell-Engaging Therapies. *Cancer J. Sudbury Mass* **20**, 119–122 (2014).
8. B. Liu, M. Li, Z. Zhou, X. Guan, Y. Xiang, Can we use interleukin-6 (IL-6) blockade for coronavirus disease 2019 (COVID-19)-induced cytokine release syndrome (CRS)? *J. Autoimmun.*, 102452 (2020).
9. X. Xu, M. Han, T. Li, W. Sun, D. Wang, B. Fu, Y. Zhou, X. Zheng, Y. Yang, X. Li, X. Zhang, A. Pan, H. Wei, Effective treatment of severe COVID-19 patients with tocilizumab. *Proc. Natl. Acad. Sci.*, 202005615 (2020).
10. P. Luo, Y. Liu, L. Qiu, X. Liu, D. Liu, J. Li, Tocilizumab treatment in COVID-19: A single center experience. *J. Med. Virol.* **n/a** (2020).
11. A. J. Ferrey, G. Choi, R. M. Hanna, Y. Chang, E. Tantisattamo, K. Ivaturi, E. Park, L. Nyugen, B. Wang, S. Tonthat, C. M. Rhee, U. Reddy, W. L. Lau, S. S. Huang, S. Gohil, A. N. Amin, L. Hsieh, T. T. Cheng, R. A. Lee, K. Kalantar-Zadeh, A Case of Novel Coronavirus Disease 19 in a Chronic Hemodialysis Patient Presenting with Gastroenteritis and Developing Severe Pulmonary Disease. *Am. J. Nephrol.* **51**, 337–342 (2020).
12. J.-M. Michot, L. Albiges, N. Chaput, V. Saada, F. Pommeret, F. Griscelli, C. Balleyguier, B. Besse, A. Marabelle, F. Netzer, M. Merad, C. Robert, F. Barlesi, B. Gachot, A. Stoclin, Tocilizumab, an anti-IL6 receptor antibody, to treat Covid-19-related respiratory failure: a case report. *Ann. Oncol.* (2020) https:/doi.org/10.1016/j.annonc.2020.03.300 (May 5, 2020).
13. C. Mihai, R. Dobrota, M. Schröder, A. Garaiman, S. Jordan, M. O. Becker, B. Maurer, O. Distler, COVID-19 in a patient with systemic sclerosis treated with tocilizumab for SSc-ILD. *Ann. Rheum. Dis.* **79**, 668–669 (2020).
14. X. Zhang, K. Song, F. Tong, M. Fei, H. Guo, Z. Lu, J. Wang, C. Zheng, First case of COVID-19 in a patient with multiple myeloma successfully treated with tocilizumab. *Blood Adv.* **4**, 1307–1310 (2020).
15. World Health Organization, "WHO R&D Blueprint novel Coronavirus: COVID-19 Therapeutic Trial Synopsis" (2020).

Table 1. Patients with COVID19 treated with tocilizumab demographics and clinical characteristics (n=11)

Demographics and Clinical Characteristics	Median (IQR) / Percentage (n)
Age	59 (48-65)
Sex (% male)	82% (9)
Race	
Hispanic/Latino	46% (5)
Caucasian	27% (3)
African American	27% (3)
Employment Type	
Factory worker	36.4% (n=4)
Unemployed/retired	27.3% (n=3)
Food industry	18.2% (n=2)
Working but unspecified	9.1% (n=1)
Unknown employment status	9.1% (n=1)
Current Tobacco Use	
Cigarettes	9% (1)
E-Cigarettes/Vaping	9% (1)
Ethanol Use	9% (1)
Substance Use	9% (1)
BMI	31 (29-36)
Normal (18.5-25)	9% (1)
Overweight (25-30)	36% (4)
Obese (>30)	55% (6)
Comorbidities	
Hypertension	73% (8)
Type 2 Diabetes Mellitus	36% (4)
Lung Disease	27% (3)
Cardiovascular Disease	18% (2)
Liver Disease	9% (1)
Renal Disease	9% (1)
HIV	9% (1)
Active Cancer	9% (1)
Solid organ transplant	9% (1)
Transferred from OSH	64% (7)
COVID-19 Clinical and Treatment Characteristics	
Exposure History	
Unknown exposure	55% (6)
Positive contact	36% (4)
Travel history	9% (1)
Time from symptom onset to admission	8 (5-11)
Abnormal CXR/CT on admission	91% (10)
Prone positioning while intubated	78% (7/9)
Dosage of Tocilizumab	
Dose (mg/kg)	7.9 (5.8-8.1)*
Time (days) to Tocilizumab	
From Admission	1 (1-4)
From Symptom Onset	9 (7-14)
Other Treatments	
Azithromycin	64% (7)
Hydroxychloroquine	36% (4)
Ritonavir/Lopinavir	27% (3)
Steroids	27% (3)

Admission Labs[#]	*Median (IQR)*	*Percentage abnormal (n)*
CRP (mg/L)	197.3 (146.8-324.9)	100% (11/11 elevated)
Fibrinogen (mg/dL)	662.0 (566-928.5)	100% (9/9 elevated)
Ferritin (ng/mL)	589.5 (389.8-1705)	80% (8/10 elevated)
LDH (U/L)	1203 (943-2122)	89% (8/9 elevated)
D-Dimer (ng/mL)	343.5 (199.5-1,203)	70% (7/10 elevated)
WBC ($x10^9$/L)	8.5 (5.1-9.9)	18% (2/11 elevated)
Absolute Lymphocyte Count ($x10^9$/L)	0.8 (0.6-1)	91% (10/11 reduced)
Platelet Count ($x10^9$/L)	230 (162-382)	18% (2/11 reduced)
Troponin I (ng/mL)	<0.034 (<0.034-0.172)[##]	36% (4/11 elevated)
Creatinine (mg/dL)	0.92 (0.7-2.53)	27% (3/11 elevated)
Pro-BNP (pg/mL)	69.7 (34.3-6,870)	46% (5/11 elevated)
AST (U/L)	51 (44-72)	46% (5/11 elevated)
ALT (U/L)	35 (30-60)	27% (3/11 elevated)

Clinical and Laboratory Outcomes			
Disease Severity	*Admission*	*Highest Severity*	*Outcome*
8 (Deceased)	---	---	27% (3)
7 (Critical, Ventilator + Organ Support)	36% (4)	73% (8)	46% (5)
6 (Critical, Ventilator)	0% (0)	9% (1)	0% (0)
5 (Severe, HFNC/NIPPV)	18% (2)[***]	9% (1)[***]	0% (0)
4 (Mild, LFNC)	36% (4)	9% (1)	0% (0)
3 (Mild, room air)	9% (1)	0% (0)	9% (1)
1-2 (Ambulatory – Discharged)	---	---	18% (2)
Other invasive therapies			
Hemodialysis	27% (3)		
ECMO	9% (1)		
Length of Stay (days)[**]	18 (15-25)		
Length (days) on mechanical ventilation[**]	17 (12-29)		
Laboratory Measures[#]	*Pre-Tocilizumab*	*Post-Tocilizumab*	*p-value*
CRP (mg/L)	211.6 (176.9-313.8)	19.7 (13.6-29)	0.001
Fibrinogen (mg/dL)	767 (625-862)	420 (386.3-473.5)	0.002
IL-6 (pg/mL)	30.65 (9.1–88.8)	>400 (249.4 - >400)	0.13[###]

[*] n=12 doses, one patient received tocilizumab twice
[**] As of date of death, date of discharge, or end date of observation period
[***] One patient was do not intubate status on admission, receiving only HFNC/NIPPV. Patient subsequently died.
[#] Not all patients had all laboratory values available, data representative of patients with data available
[##] Lower limit of detection for Troponin I was <0.034.
[###] Only four patients had matched pre- and post-Tocilizumab IL-6 levels.

Abbreviations: OSH, outside hospital; BMI, body mass index; CXR, chest x-ray; CT, computed tomography; HIV, human immunodeficiency virus; CRP, c-reactive protein; LDH, lactate dehydrogenase; WBC, white blood cell count; BNP, b-type natriuretic peptide; AST, aspartate aminotransferase; ALT, alanine aminotransferase; HFNC, high-flow nasal cannula; NIPPV, non-invasive positive pressure ventilation; LFNC, low-flow nasal cannula; ECMO, extracorporeal membrane oxygenation; IL-6, interleukin-6.

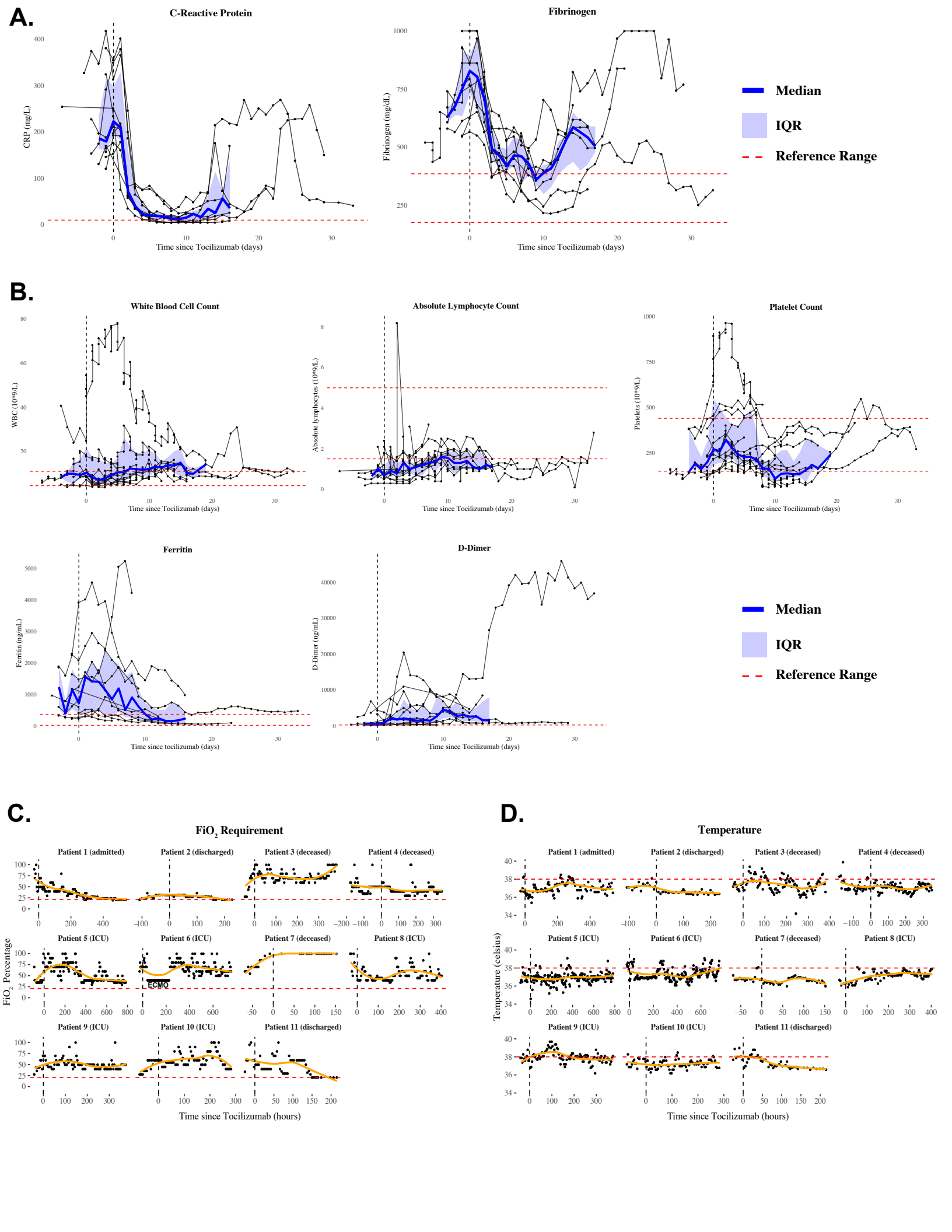
A.
C-Reactive Protein
CRP (mg/L)
Time since Tocilizumab (days)
Fibrinogen
Fibrinogen (mg/dL)
Time since Tocilizumab (days)
Median
IQR
Reference Range
B.
White Blood Cell Count
WBC (10^9/L)
Time since Tocilizumab (days)
Absolute Lymphocyte Count
Absolute lymphocytes (10^9/L)
Time since Tocilizumab (days)
Platelet Count
Platelets (10^9/L)
Time since Tocilizumab (days)
Ferritin
Ferritin (ng/mL)
Time since tocilizumab (days)
D-Dimer
D-Dimer (ng/mL)
Time since Tocilizumab (days)
Median
IQR
Reference Range
C.
FiO2 Requirement
Patient 1 (admitted)
Patient 2 (discharged)
Patient 3 (deceased)
Patient 4 (deceased)
Patient 5 (ICU)
Patient 6 (ICU)
Patient 7 (deceased)
Patient 8 (ICU)
Patient 9 (ICU)
Patient 10 (ICU)
Patient 11 (discharged)
ECMO
FiO2 Percentage
Time since Tocilizumab (hours)
D.
Temperature
Temperature (celsius)
Time since Tocilizumab (hours)