medRxiv preprint doi: https://doi.org/10.1101/2020.04.01.20049833; this version posted April 14, 2020. The copyright holder for this preprint (which was not certified by peer review) is the author/funder, who has granted medRxiv a license to display the preprint in perpetuity. It is made available under a CC-BY-NC-ND 4.0 International license .

Clinical Manifestations of Children with COVID-19: a Systematic Review

Tiago H. de Souza[a], MD, PhD; José A. Nadal[a], MD, MSc;
Roberto J. N. Nogueira[a, b], MD, PhD; Ricardo M. Pereira[a], MD, PhD;
Marcelo B. Brandão[a], MD, PhD

Affiliations:
a Pediatric Intensive Care Unit, Department of Pediatrics, State University of Campinas (UNICAMP), Campinas, SP, Brazil;
b Department of Pediatrics, School of Medicine São Leopoldo Mandic, Campinas, SP, Brazil

Address correspondence to: Tiago Henrique de Souza, Pediatric Intensive Care Unit, Department of Pediatrics, State University of Campinas (UNICAMP)
126, Tessália Vieira de Camargo Street. ZIPCODE 13083-887 Campinas, SP, Brazil.
E-mail: tiago.souza@hc.unicamp.br

Short title: Children with COVID-19

Funding Source: No external funding for this manuscript.

Financial Disclosure: The authors have no financial relationships relevant to this study to disclose.

Conflict of Interest: The authors have disclosed that they do not have any potential conflicts of interest.

Abbreviations:
WHO – World Health Organization
SARS-CoV-2 – Severe acute respiratory syndrome coronavirus 2
COVID-19 – Coronavirus disease 2019
CT – Computed tomography
CDC – Centers for Disease Control and Prevention

Keywords: COVID-19; SARS-CoV-2; coronavirus; children

NOTE: This preprint reports new research that has not been certified by peer review and should not be used to guide clinical practice.

medRxiv preprint doi: https://doi.org/10.1101/2020.04.01.20049833; this version posted April 14, 2020. The copyright holder for this preprint (which was not certified by peer review) is the author/funder, who has granted medRxiv a license to display the preprint in perpetuity. It is made available under a CC-BY-NC-ND 4.0 International license .

Contributors' Statement Page

Tiago Henrique de Souza conceptualized and designed the study, drafted the initial manuscript, and reviewed and revised the manuscript.
Tiago Henrique de Souza and **José Antonio Hersan Nadal** designed the data collection instruments, collected data, carried out the initial analyses, and reviewed and revised the manuscript.
Roberto José Negrão Nogueira, Ricardo Mendes Pereira and Marcelo Barciela Brandão coordinated and supervised data collection, and critically reviewed the manuscript for important intellectual content.
All authors approved the final manuscript as submitted and agree to be accountable for all aspects of the work.

medRxiv preprint doi: https://doi.org/10.1101/2020.04.01.20049833; this version posted April 14, 2020. The copyright holder for this preprint (which was not certified by peer review) is the author/funder, who has granted medRxiv a license to display the preprint in perpetuity. It is made available under a CC-BY-NC-ND 4.0 International license .

ABSTRACT

Background: The coronavirus disease 2019 (COVID-19) outbreak is an unprecedented global public health challenge, leading to thousands of deaths every day worldwide. Despite the epidemiological importance, clinical patterns of children with COVID-19 remain unclear.The aim of this study was todescribe the clinical, laboratorial and radiological characteristics of children with COVID-19.

Methods: The Medline database was searched between December 1st 2019 and April 6th 2020. No language restrictions were applied. Inclusion criteria were: (1) studied patients younger than 18 years old; (2) presented original data from cases of COVID-19 confirmed by reverse-transcription polymerase chain reaction; and (3) contained descriptions of clinical manifestations, laboratory tests or radiological examinations.

Results: A total of 38 studies (1,124 cases) were included. From all the cases, 1,117 had their severity classified: 14.2% were asymptomatic, 36.3% were mild, 46.0% were moderate, 2.1% were severe and 1.2% were critical. The most prevalent symptom was fever (47.5%), followed by cough (41.5%), nasal symptoms (11.2%), diarrhea (8.1%) and nausea/vomiting (7.1%). One hundred forty-five (36.9%) children were diagnosed with pneumonia and 43 (10.9%) upper airway infections were reported. Reduced lymphocyte count were reported in 12.9% of cases. Abnormalities on computed tomography was reported in 63.0% of cases. The most prevalent abnormalities reported were ground glass opacities, patchy shadows and consolidations. Only one death was reported.

Conclusions: Clinical manifestations of children with COVID-19 differ widely from adults cases. Fever and respiratory symptoms should not be considered a hallmark of COVID-19 in children.

medRxiv preprint doi: https://doi.org/10.1101/2020.04.01.20049833; this version posted April 14, 2020. The copyright holder for this preprint (which was not certified by peer review) is the author/funder, who has granted medRxiv a license to display the preprint in perpetuity. It is made available under a CC-BY-NC-ND 4.0 International license .

INTRODUCTION

In late December 2019, Chinese authorities informed the World Health Organization (WHO) that, due to unknown cause, an outbreak of pneumonia emerged in Wuhan, Hubei province. On January 7, 2020, a new type of coronavirus (severe acute respiratory syndrome coronavirus 2, SARS-CoV-2) was isolated and few days after the disease has been named "coronavirus disease 2019" (abbreviated "COVID-19"). The first death caused by COVID-19 was on January 9, 2020, in Wuhan and since then more than 370,000 cases and 16,000 deaths occurred worldwide.[1] Nowadays, the death toll in Italy has exceeded four timese the number registered in China and the United States became the new COVID-19 epicenter.

In spite of stepped-up efforts to contain the pandemic, the number of affected patients and the death toll continue to rise. Elderly patients infected with SARS-CoV-2 are at high risk to have severe acute respiratory syndrome, complications and death.[2] Due to unknown reasons, children with COVID-19 appear to have a milder clinical course compared to adults, and reports of death are scarce.[3,4] However, pediatric population may play a major role in community spread of SARS-CoV-2. In addition to viral shedding in nasal secretions, there is evidence of fecal shedding for several weeks after diagnosis, which poses a challenge for infection control.[5]

Despite the epidemiological importance, clinical patterns of children with COVID-19 remain unclear. The WHO recommends testing all suspected cases, however, children infected with SARS-CoV-2 may not meet all the criteria required in

medRxiv preprint doi: https://doi.org/10.1101/2020.04.01.20049833; this version posted April 14, 2020. The copyright holder for this preprint (which was not certified by peer review) is the author/funder, who has granted medRxiv a license to display the preprint in perpetuity. It is made available under a CC-BY-NC-ND 4.0 International license .

the suspected case definition.[6] The objective of this study is to describe the clinical, laboratorial and radiological characteristics of children with COVID-19 reported in the literature.

METHODS

This review was performed in accordance with the Preferred Reporting Items for Systematic and Meta-Analysis (PRISMA) statement.[7,8] The Medline database was searched using the following search strategy: ((((covid-19) OR coronavirus) OR SARS-CoV-2)) AND (((((((pediatrics) OR children) OR neonates) OR child) OR neonate) OR infant) OR infants). No language restrictions were applied. Articles published between December 1st 2019 and April 7th 2020 were evaluated for inclusion. No attempts were made to contact the study authors for identifying missing and confusing data. A manual search of the references found in the selected articles and reviews was also performed.

Study Selection

Two authors (THS and JAN) screened the titles and abstracts independently and in duplicate for potential eligibility. They subsequently read the full texts to determine final eligibility. Discrepancies were resolved through discussion and consensus, and if necessary, the assistance of a third author (MBB) was sought.

Eligible studies fulfilled the following criteria: (1) studied patients younger than 18 years old; (2) presented original data from cases of COVID-19 confirmed by reverse-transcription polymerase chain reaction; (3) contained descriptions of clinical manifestations, laboratory tests or radiological examinations.

Data Extraction

medRxiv preprint doi: https://doi.org/10.1101/2020.04.01.20049833; this version posted April 14, 2020. The copyright holder for this preprint (which was not certified by peer review) is the author/funder, who has granted medRxiv a license to display the preprint in perpetuity. It is made available under a CC-BY-NC-ND 4.0 International license .

A structured data extraction form was piloted and then used to extract data from the reports of all included studies in duplicate and independently by two authors (THS and JAN). Discrepancies in extracted data were resolved through discussion. The following data were extracted, when available, from each elected article: first author, publication year, study design, number of cases, gender, age, clinical manifestations, laboratory tests, radiological examinations and outcomes (discharged, still hospitalized or death).

When sufficient data was reported, the cases were classified into the following clinical types:[9]

1. Asymptomatic infection: without any clinical symptoms and signs and the chest imaging is normal, while the SARS-CoV-2 nucleic acid test was positive or the serum-specific antibody was retrospectively diagnosed as infection.
2. Mild: symptoms of acute upper respiratory tract infection, including fever, fatigue, myalgia, cough, sore throat, runny nose, and sneezing. Physical examination shows congestion of the pharynx and no auscultatory abnormalities. Some cases may have no fever, or have only digestive symptoms such as nausea, vomiting, abdominal pain and diarrhea.
3. Moderate: presented as pneumonia. Frequent fever and cough, mostly dry cough, followed by productive cough , some may have wheezing, but no obvious hypoxemia such as shortness of breath, and lungs can hear sputum or dry snoring and / or wet snoring. Some cases may have no clinical signs and symptoms, but chest computed tomography (CT) shows lung lesions, which are subclinical.

medRxiv preprint doi: https://doi.org/10.1101/2020.04.01.20049833; this version posted April 14, 2020. The copyright holder for this preprint (which was not certified by peer review) is the author/funder, who has granted medRxiv a license to display the preprint in perpetuity. It is made available under a CC-BY-NC-ND 4.0 International license .

4. Severe: Early respiratory symptoms such as fever and cough, may be accompanied by gastrointestinal symptoms such as diarrhea. The disease usually progresses around 1 week, and dyspnea occurs, with central cyanosis. Oxygen saturation is less than 92%, with other hypoxia manifestations.
5. Critical: Children can quickly progress to acute respiratory distress syndrome (ARDS) or respiratory failure, and may also have shock, encephalopathy, myocardial injury or heart failure, coagulation dysfunction, and acute kidney injury, including multiple organ dysfunction. Can be life threatening.

RESULTS

Study Selection and Characteristics

Of 293 potentially relevant articles identified by the search strategy, 38 met the inclusion criteria. A total of 1117 descriptions of pediatric cases[3,5,18–27,10,28–37,11,38–40,12–17] and 7 neonate cases[41–45] of COVID-19 were obtained, being that 643 were males 478 were females, and 3 were not disclosed. The flow diagram (**Figure 1**) summarizes the steps followed to identify the studies meeting the inclusion criteria.

Twenty studies were case reports,[20,21,32,35,37–43,45,22–28,31] 11 were case series[5,15,44,16–19,29,30,33,34] and 6 were retrospective studies.[3,10–14,36] With the exception of 5 multicenter studies,[5,10–12,36] all others were unicentric studies. Thirty-three studies were conducted in China,[3,5,18–22,24–27,29,10,30,32–37,39–41,11,42–44,12–17], 1 in Italy,[38] 1 in Iran,[45] 1 in Singapore,[28] 1 in Korea,[23] and 1 in Vietnam.[31]

Severity of illness

medRxiv preprint doi: https://doi.org/10.1101/2020.04.01.20049833; this version posted April 14, 2020. The copyright holder for this preprint (which was not certified by peer review) is the author/funder, who has granted medRxiv a license to display the preprint in perpetuity. It is made available under a CC-BY-NC-ND 4.0 International license .

A total of 1117 cases had their severity classified based on the reported clinical data. One hundred fifty-nine (14.2%) cases were asymptomatic, 406 (36.3%) were mild, 514 (46.0%) were moderate, 25 (2.1%) were severe and 13 (1.2%) were critical cases. **Table 1** summarizes the severity of illness reported in each included study.

Clinical manifestations

The most prevalent symptom was fever, reported in 47.5% of the cases, followed by cough (41.5%), nasal symptoms (11.2%), diarrhea (8.1%), nausea/vomiting (7.1%), fatigue (5.0%) and respiratory distress (3.5%). One hundred forty-five (36.9%) children were diagnosed with pneumonia and 43 (10.9%) upper airway infections were reported. Amongst the most common clinical signs described were pharyngeal erythema (20.6%), tachycardia (18.6%) and tachypnea (13.4%) on admission. All the clinical manifestations reported in the selected studies and their relative frequencies are described in **Table 2**. All clinical manifestations described in each study are presented in **E-Table 1** in the Supplement.

Laboratorial characteristics

Twenty-nine studies detailed the white blood cell count of 174 cases.[11,13,24–33,14,34–43,16,45,17–19,21–23] Of these, 13 (7.5%) were elevated, 29 (16.6%) were decreased, and 132 (75.8%) were within normal ranges. Normal or elevated lymphocytes count were detailed in 28 studies, involving 154 cases.[11,13,26–35,16,36–43,45,17,19,21–25] Normal lymphocyte count were reported in 69.5% and elevated in 11.7% of cases. Reduced lymphocyte count were reported in 45 of 350 (12.9%) cases.[3,11,24–33,12,34–43,13,45,16,17,19,21–23]. Zheng et al reported a median white blood cell count of 6.2×10^9/L [interquartile

medRxiv preprint doi: https://doi.org/10.1101/2020.04.01.20049833; this version posted April 14, 2020. The copyright holder for this preprint (which was not certified by peer review) is the author/funder, who has granted medRxiv a license to display the preprint in perpetuity. It is made available under a CC-BY-NC-ND 4.0 International license .

range (IQR) 4.30–9.85] and median lymphocyte count of 2.19 × 10^9/L (IQR 1.15–3.31) of 25 pediatric patients.

Normal or decreased platelet count were detailed in 15 studies, involving 32 cases.[16,23,37,39–41,45,24,25,27,29,31–33,35] Normal platelet count were reported in 78.1% (22/32) and descreased in 3.2% (1/32) of cases. Increased platelet count were reported in 6 of 63 (9.5%) cases.[11,16,35,37,39–41,45,23–25,27,29,31–33]

Elevated C-reactive protein (CRP) levels were described in 59 of 305 cases (19.3%), reported in 25 studies.[3,11,26,27,29,31–37,13,39–42,45,16,19–24]. Zheng et al reported a median CRP level of 15.5 mg/dL (IQR 0.93-25.04) in 25 cases, and Cai et al. a median of 7.5 mg/dL in 10 cases.

Procalcitonin levels were elevated in 139 of 279 cases (49.8%), reported in 16 studies.[3,11,37,39–43,13,16,24,26,27,31,33,36] Cai et al reported a median procalcitonin level of 0.07 ng/dL in 10 cases.

Increased liver enzymes were described in 56 of 292 cases (19.2%), reported in 16 studies.[3,11,34–37,39–41,43,13,16,21,24,27,29,31,33] Zheng et al reported a median of 12 U/L in 25 cases, and Cai et al. a median alanine aminotransferase and aspartate aminotransferase level of 18.5 U/L and 27.7 U/L, respectively, in 10 cases.

Co-infections with other pathogens were reported in 5 studies.[12,13,16,19,34] Two patients were reported with influenza A, 5 with influenza B, 3 with respiratory syncytial virus (RSV), 1 with cytomegalovirus, 7 with *Mycoplasma pneumoniae* and 1 with *Enterobacter aerogenes*.

Radiological features

Twenty-seven studies reported 184 cases which underwent chest CT.[3,11,21–27,29,30,32,12,34–36,39–42,13,14,16–20] One hundred sixteen (63.0%) CT scans presented

medRxiv preprint doi: https://doi.org/10.1101/2020.04.01.20049833; this version posted April 14, 2020. The copyright holder for this preprint (which was not certified by peer review) is the author/funder, who has granted medRxiv a license to display the preprint in perpetuity. It is made available under a CC-BY-NC-ND 4.0 International license .

abnormalities. The most prevalent abnormalities reported were ground glass opacities, patchy shadows and consolidations. In the study of Lu et al. involving 171 cases, ground glass opacities and patchy shadowings were observed in 32.7% and 31% of cases, respectively.[3] Pleural effusion was observed in a 2-month-old child with simultaneus RSV and SARS-CoV-2 infections.[19]

Outcomes

Clinical outcomes of death, discharged or still hospitalized were described for 371 cases in 32 studies.[3,5,21–29,31,11,33–42,12,44,45,13,14,16–18,20] Of these, 62 cases were still hospitalized when studies were submitted, 308 were discharged and 1 died.

DISCUSSION

In our study, we described the main clinical, laboratorial and radiological characteristics of children infected with SARS-CoV-2 reported in the literature. It was observed that only a small proportion of infected children became severely or critically ill. About half of the children with COVID-19 were asymptomatic or mild cases, and several were classified as moderate due to radiological abnormalities in spite of their mild clinical manifestations. The prognosis seems to be very good, with recovery described in the vast majority of reported cases. Only one death was reported in the included studies, a 10-month-old child with intussusception.[3]

Since COVID-19 has a favorable clinical course in children, the importance of pediatric cases is mainly due to epidemiological issues. Despite being mild or asymptomatic cases, prolonged viral shedding in stool and nasal secretions made children facilitators of viral transmission.[5,46] In the study of Xu et al., eight of ten children with SARS-CoV02 had persistently positive rectal swabs even after their

medRxiv preprint doi: https://doi.org/10.1101/2020.04.01.20049833; this version posted April 14, 2020. The copyright holder for this preprint (which was not certified by peer review) is the author/funder, who has granted medRxiv a license to display the preprint in perpetuity. It is made available under a CC-BY-NC-ND 4.0 International license .

nasopharyngeal tests were negative.[46] This raises concerns about the possibility of a fecal–oral route of transmission. The role of children in the transmission chain needs to be urgently clarified to establish social and public health policies for the protection of vulnerable populations, such as the elderly and people with comorbidities.

Testing people who meet the COVID-19 suspected case definition is essential for clinical management and outbreak control. The Centers for Disease Control and Prevention (CDC) recommends that clinicians should decide to test patients based on the presence of signs and symptoms compatible with COVID-19. The WHO, CDC and several other government health agencies emphasize fever and respiratory symptoms in the criteria for suspected cases, however, we observed in our study that only 47.5% of pediatric cases had fever.[47,48] Since many are asymptomatic or mild cases, children certainly are not tested as often as adults, leading to an underestimate of the true numbers of infected people and increased transmission of the virus.

Guan et al. demonstrated pronounced lymphopenia in adults with COVID-19, especially in severe cases, where the observed prevalence was 96.1%.[4] Some authors even suggest that lymphopenia is a predictor of prognosis in adult patients with COVID-19.[49]t In our study, decreased lymphocyte count was described in only 12.9% of infected children, in contrast with adults, in which 80% of the non-severe cases have lymphopenia. With this, lymphopenia may not be a reliable indicator of COVID-19 in children.

Similarly to adults, the most prevalent abnormalities on chest CT of children with COVID-19 were ground glass opacities and patchy shadowings. However, while 86.2% of adults cases presented any abnormalities on chest CT, the same occurred in only 63.0% of children in the selected studies. Descriptions of chest x-rays of pediatric cases are scarce and would be usefull for resource-limited settings.

medRxiv preprint doi: https://doi.org/10.1101/2020.04.01.20049833; this version posted April 14, 2020. The copyright holder for this preprint (which was not certified by peer review) is the author/funder, who has granted medRxiv a license to display the preprint in perpetuity. It is made available under a CC-BY-NC-ND 4.0 International license .

Our study has some limitations. Firstly, data from the same patient may have been presented in more than one included study. Secondly, the majority of data are from China, and may not be generalized for other populations.

CONCLUSION

Most children with COVID-19 have a favorable clinical course and their clinical manifestations differ widely from adults cases. Fever and respiratory symptoms should not be considered a hallmark of COVID-19 in children. With this, pediatricians should have a high level of clinical suspicion to diagnose children infected with SARS-Cov-2, as the majority of pediatric cases are asymptomatic or mild. Regardless of the favorable prognosis, it is important that the child's role in the contamination chain is precisely established and considered.

REFERENCES

1. World Health Organization. Coronavirus disease 2019 (COVID-19): Situation report - 64. 2020.

2. Arentz M, Yim E, Klaff L, Lokhandwala S, Riedo FX, Chong M, Lee M. Characteristics and outcomes of 21 critically Ill patients with COVID-19 in washington state. JAMA 2020 Mar 19.

3. Lu X, Zhang L, Du H, Zhang J, Li YY, Qu J, Zhang W, Wang Y, Bao S, Li Y, et al. SARS-CoV-2 Infection in Children. N Engl J Med 2020 Mar 18.

4. Guan W, Ni Z, Hu Y, Liang W, Ou C, He J, Liu L, Shan H, Lei C, Hui DSC, et al. Clinical characteristics of coronavirus disease 2019 in china. N Engl J Med 2020 Feb 28.

5. Cai J, Xu J, Lin D, Yang Z, Xu L, Qu Z, Zhang Y, Zhang H, Jia R, Liu P, et al. A case series of children with 2019 novel coronavirus infection: clinical and epidemiological features. Clin Infect Dis 2020 Feb 28.

6. Wang Y, Liu Y, Liu L, Wang X, Luo N, Ling L. Clinical outcome of 55 asymptomatic cases at the time of hospital admission infected with SARS-Coronavirus-2 in Shenzhen, China. J Infect Dis 2020 Mar 17.

7. Liberati A, Altman DG, Tetzlaff J, Mulrow C, Gøtzsche PC, Ioannidis JPA, Clarke M, Devereaux PJ, Kleijnen J, Moher D. The PRISMA statement for reporting systematic reviews and meta-analyses of studies that evaluate health care interventions: Explanation and elaboration. PLoS Med 2009;6(7):1–28.

medRxiv preprint doi: https://doi.org/10.1101/2020.04.01.20049833; this version posted April 14, 2020. The copyright holder for this preprint (which was not certified by peer review) is the author/funder, who has granted medRxiv a license to display the preprint in perpetuity. It is made available under a CC-BY-NC-ND 4.0 International license .

8. Moher D, Liberati A, Tetzlaff J, Altman DG, Altman D, Antes G, Atkins D, Barbour V, Barrowman N, Berlin JA, et al. Preferred reporting items for systematic reviews and meta-analyses: The PRISMA statement. PLoS Med 2009;6(7):1–6.

9. The Society of Pediatrics CMA, the Editorial Board CJ of P. Recommendations for the diagnosis, prevention and control of the 2019 novel coronavirus infection in children (first interim edition). Chinese J Pediatr 2020;58(0):E004.

10. Dong Y, Xi Mo YH, Qi X, Jiang F, Jiang Z, Tong S. COVID-19 in children: initial characterization of the pediatric disease. Pediatrics 2020 Mar 1:e20200834.

11. Wang D, Ju XL, Xie F, Lu Y, Li FY, Huang HH, Fang XL, Li YJ, Wang JY, Yi B, et al. Clinical analysis of 31 cases of 2019 novel coronavirus infection in children from six provinces (autonomous region) of northern China. Zhonghua Er Ke Za Zhi 2020;58(4):E011.

12. Zheng F, Liao C, Fan Q, Chen H, Zhao X, Xie Z, Li X, Chen C, Lu X, Liu Z, et al. Clinical characteristics of children with coronavirus disease 2019 in Hubei, China. Curr Med Sci 2020.

13. Xia W, Shao J, Guo Y, Peng X, Li Z, Hu D. Clinical and CT features in pediatric patients with COVID-19 infection: Different points from adults. Pediatr Pulmonol 2020;n/a(n/a).

14. Feng K, Yun YX, Wang XF, Yang GD, Zheng YJ, Lin CM, Wang LF. Analysis of CT features of 15 children with 2019 novel coronavirus infection. Zhonghua Er Ke Za Zhi 2020;58(0):E007.

15. Wei M, Yuan J, Liu Y, Fu T, Yu X, Zhang Z-J. Novel coronavirus infection in hospitalized infants under 1 year of age in China. JAMA 2020 Feb 14.

16. Sun D, Li H, Lu X-X, Xiao H, Ren J, Zhang F-R, Liu Z-S. Clinical features of severe pediatric patients with coronavirus disease 2019 in Wuhan: a single center's observational study. World J Pediatr 2020.

17. Liu W, Zhang Q, Chen J, Xiang R, Song H, Shu S, Chen L, Liang L, Zhou J, You L, et al. Detection of Covid-19 in children in early january 2020 in Wuhan, China. N Engl J Med 2020 Mar 12.

18. Hu Z, Song C, Xu C, Jin G, Chen Y, Xu X, Ma H, Chen W, Lin Y, Zheng Y, et al. Clinical characteristics of 24 asymptomatic infections with COVID-19 screened among close contacts in Nanjing, China. Sci China Life Sci 2020.

19. Liu H, Liu F, Li J, Zhang T, Wang D, Lan W. Clinical and CT imaging features of the COVID-19 pneumonia: Focus on pregnant women and children. J Infect 2020 Mar 23.

20. Lou XX, Shi CX, Zhou CC, Tian YS. Three children who recovered from novel coronavirus 2019 pneumonia. J Paediatr Child Health 2020 Mar 22.

21. Li Y, Guo F, Cao Y, Li L, Guo Y. Insight into COVID-2019 for pediatricians. Pediatr Pulmonol 2020 Mar 18.

22. Ji L-N, Chao S, Wang Y-J, Li X-J, Mu X-D, Lin M-G, Jiang R-M. Clinical features of pediatric patients with COVID-19: a report of two family cluster cases. World J Pediatr 2020.

23. Park JY, Han MS, Park KU, Kim JY, Choi EH. First pediatric case of coronavirus disease 2019 in Korea. J Korean Med Sci 2020;35(11).

medRxiv preprint doi: https://doi.org/10.1101/2020.04.01.20049833; this version posted April 14, 2020. The copyright holder for this preprint (which was not certified by peer review) is the author/funder, who has granted medRxiv a license to display the preprint in perpetuity. It is made available under a CC-BY-NC-ND 4.0 International license .

24. Cui Y, Tian M, Huang D, Wang X, Huang Y, Fan L, Wang L, Chen Y, Liu W, Zhang K, et al. A 55-day-old female infant infected with COVID 19: presenting with pneumonia, liver injury, and heart damage. J Infect Dis 2020 Mar 17.

25. Tang A, Tong Z, Wang H, Dai Y, Li K, Liu J, Wu W, Yuan C, Yu M, Li P, et al. Detection of novel coronavirus by RT-PCR in stool specimen from asymptomatic child, China. Emerg Infect Dis J 2020;26(6).

26. Zhang YH, Lin DJ, Xiao MF, Wang JC, Wei Y, Lei ZX, Zeng ZQ, Li L, Li HA, Xiang W. 2019-novel coronavirus infection in a three-month-old baby. Zhonghua Er Ke Za Zhi 2020;58(0):E006.

27. Chen F, Liu ZS, Zhang FR, Xiong RH, Chen Y, Cheng XF, Wang WY, Ren J. First case of severe childhood novel coronavirus pneumonia in China. Zhonghua Er Ke Za Zhi 2020;58(0):E005.

28. Kam K, Yung CF, Cui L, Lin Tzer Pin R, Mak TM, Maiwald M, Li J, Chong CY, Nadua K, Tan NWH, et al. A well infant with coronavirus disease 2019 (COVID-19) with high viral load. Clin Infect Dis 2020 Feb 28.

29. Chan JF-W, Yuan S, Kok K-H, To KK-W, Chu H, Yang J, Xing F, Liu J, Yip CC-Y, Poon RW-S, et al. A familial cluster of pneumonia associated with the 2019 novel coronavirus indicating person-to-person transmission: a study of a family cluster. Lancet 2020;395(10223):514–523.

30. Liu M, Song Z, Xiao K. High-resolution computed tomography manifestations of 5 pediatric patients with 2019 novel coronavirus. J Comput Assist Tomogr 2020.

31. Le HT, Nguyen L V, Tran DM, Do HT, Tran HT, Le YT, Phan PH. The first infant case of COVID-19 acquired from a secondary transmission in Vietnam. Lancet Child Adolesc Heal 2020.

32. Pan X, Chen D, Xia Y, Wu X, Li T, Ou X, Zhou L, Liu J. Asymptomatic cases in a family cluster with SARS-CoV-2 infection. Lancet Infect Dis 2020;20(4):410–411.

33. Su L, Ma X, Yu H, Zhang Z, Bian P, Han Y, Sun J, Liu Y, Yang C, Geng J, et al. The different clinical characteristics of corona virus disease cases between children and their families in China – the character of children with COVID-19. Emerg Microbes Infect 2020;9(1):707–713.

34. Zhou Y, Yang G-D, Feng K, Huang H, Yun Y-X, Mou X-Y, Wang L-F. Clinical features and chest CT findings of coronavirus disease 2019 in infants and young children. Zhonghua Er Ke Za Zhi 2020;22(3):215–220.

35. Zhang G-X, Zhang A-M, Huang L, Cheng L-Y, Liu Z-X, Peng X-L, Wang H-W. Twin girls infected with SARS-CoV-2. Zhonghua Er Ke Za Zhi 2020;22(3):221–225.

36. Qiu H, Wu J, Hong L, Luo Y, Song Q, Chen D. Clinical and epidemiological features of 36 children with coronavirus disease 2019 (COVID-19) in Zhejiang, China: an observational cohort study. Lancet Infect Dis 2020 Mar 30.

37. Cai JH, Wang XS, Ge YL, Xia AM, Chang HL, Tian H, Zhu YX, Wang QR, Zeng JS. First case of 2019 novel coronavirus infection in children in Shanghai. Zhonghua Er Ke Za Zhi 2020;58(0):E002.

38. Canarutto D, Priolo A, Russo G, Pitea M, Vigone MC, Barera G. COVID-19 infection in a paucisymptomatic infant: Raising the index of suspicion in epidemic settings. Pediatr Pulmonol 2020;n/a(n/a).

medRxiv preprint doi: https://doi.org/10.1101/2020.04.01.20049833; this version posted April 14, 2020. The copyright holder for this preprint (which was not certified by peer review) is the author/funder, who has granted medRxiv a license to display the preprint in perpetuity. It is made available under a CC-BY-NC-ND 4.0 International license .

39. Zhang T, Cui X, Zhao X, Wang J, Zheng J, Zheng G, Guo W, Cai C, He S, Xu Y. Detectable SARS-CoV-2 viral RNA in feces of three children during recovery period of COVID-19 pneumonia. J Med Virol 2020 Mar 29.

40. Lin J, Duan J, Tan T, Fu Z, Dai J. The isolation period should be longer: Lesson from a child infected with SARS-CoV-2 in Chongqing, China. Pediatr Pulmonol 2020;n/a(n/a).

41. Zeng LK, Tao XW, Yuan WH, Wang J, Liu X, Liu ZS. First case of neonate infected with novel coronavirus pneumonia in China. Zhonghua Er Ke Za Zhi 2020;58(0):E009.

42. Wang J, Wang D, Chen G-C, Tao X-W, Zeng L-K. SARS-CoV-2 infection with gastrointestinal symptoms as the first manifestation in a neonate. Zhonghua Er Ke Za Zhi 2020;22(3):211–214.

43. Zeng L, Xia S, Yuan W, Yan K, Xiao F, Shao J, Zhou W. Neonatal early-onset infection with SARS-CoV-2 in 33 neonates born to mothers with COVID-19 in Wuhan, China. JAMA Pediatr 2020 Mar 26.

44. Yu N, Li W, Kang Q, Xiong Z, Wang S, Lin X, Liu Y, Xiao J, Liu H, Deng D, et al. Clinical features and obstetric and neonatal outcomes of pregnant patients with COVID-19 in Wuhan, China: a retrospective, single-centre, descriptive study. Lancet Infect Dis 2020 Mar 30.

45. Kamali Aghdam M, Jafari N, Eftekhari K. Novel coronavirus in a 15-day-old neonate with clinical signs of sepsis, a case report. Infect Dis (Auckl) 2020 Apr 1:1–3.

46. Xu Y, Li X, Zhu B, Liang H, Fang C, Gong Y, Guo Q, Sun X, Zhao D, Shen J, et al. Characteristics of pediatric SARS-CoV-2 infection and potential evidence for persistent fecal viral shedding. Nat Med 2020.

47. CDC Health Alert Network. Updated guidance on evaluating and testing persons for coronavirus disease 2019 (COVID-19). 2020 [accessed 2020 Mar 7]. https://emergency.cdc.gov/han/2020/HAN00429.asp

48. World Health Organization. Global Surveillance for human infection with coronavirus disease (COVID-19). 2020 [accessed 2020 Mar 27]. https://www.who.int/publications-detail/global-surveillance-for-human-infection-with-novel-coronavirus-(2019-ncov)

49. Tan L, Wang Q, Zhang D, Ding J, Huang Q, Tang Y-Q, Wang Q, Miao H. Lymphopenia predicts disease severity of COVID-19: a descriptive and predictive study. Signal Transduct Target Ther 2020;5(1):33.

Acknowledgements

Thank you to Carolina Grotta Ramos Telio for her review of the manuscript.

medRxiv preprint doi: https://doi.org/10.1101/2020.04.01.20049833; this version posted April 14, 2020. The copyright holder for this preprint (which was not certified by peer review) is the author/funder, who has granted medRxiv a license to display the preprint in perpetuity. It is made available under a CC-BY-NC-ND 4.0 International license .

Table 1. Severity of illness and characteristics of cases reported.

Table 2. Distributions of clinical manifestations of children with COVID-19 described in the selected studies.

E-Table 1. Clinical manifestations reported in the selected studies.

Figure 1. Preferred Reporting Items for Systematic Reviews and Meta-Analyses flow diagram of selection process.

(which was not certified by peer review) is the author/funder, who has granted medRxiv a license to display the preprint in perpetuit
It is made available under a CC-BY-NC-ND 4.0 International license .

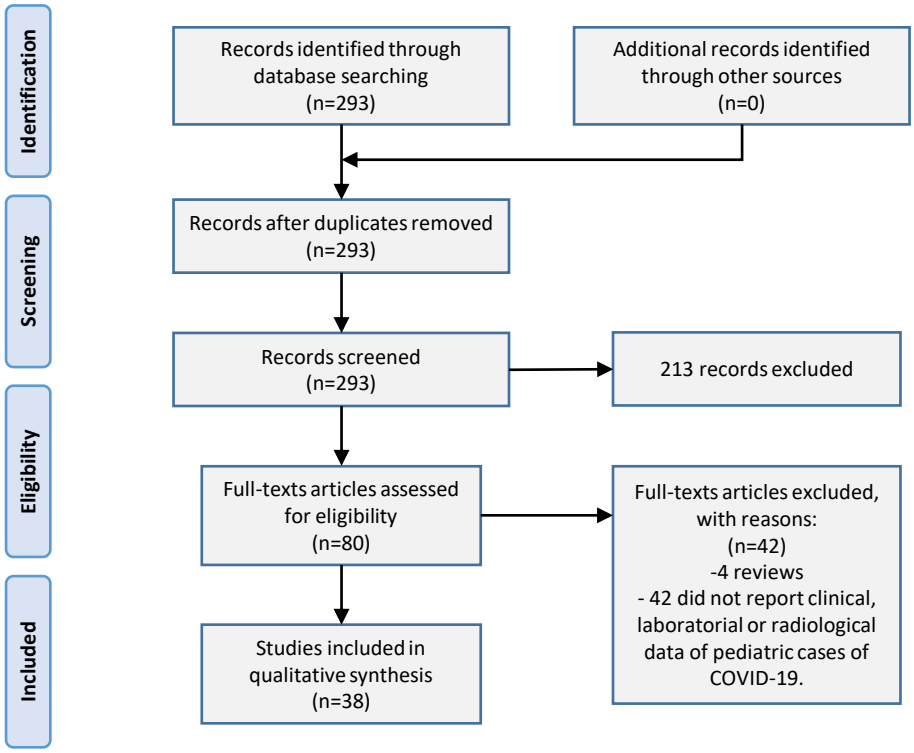

Table 1. Severity of illness and characteristics of cases reported.

			Gender		Severity of illness					
Studies	N	Age	Males	Females	Asymptomatic	Mild	Moderate	Severe	Critical	NA
Dong et al.	731	10 y*	420	311	94 (12.9%)	315 (43.1%)	300 (41.0%)	15 (2.5%)	3 (0.4%)	1 (0.1%)
Lu et al.	171	6 y (1 d to 15 y)*	104	67	27 (15.7%)	33 (19.3%)	107 (62.6%)	1 (0.6%)	3 (1.7%)	
Qiu et al.	36	8 y (1 y to 16 y)**	23	13	10 (27.7%)	7 (19.4%)	19 (52.8%)			
Wang et al.	31	7 (6 mo to 17)**	15	16	4 (12.9%)	13 (41.9%)	14 (45.1%)			
Zheng et al.	25	3 y (3 mo to 14 y)**	14	11		8 (32.0%)	15 (60.0%)		2 (8.0%)	
Xia et al.	20	2 y (1 day to 14 y)*	13	7			19 (95.0%)	1 (5.0%)		
Feng et al.	15	7 (4 y to 14 y)**	5	10		3 (20.0%)	12 (80.0%)			
Cai et al.	10	74 mo (3 mo to 131 mo)*	4	6		6	4			
Wei et al.	9	6 mo (1 mo to 11 mo)*	2	7	1	6				2
Su et al.	9	4.5 y (11 mo to 9y)*	3	6	6	3				
Zhou et al.	9	1 y (7 mo to 3 y)**	4	5	5		4			
Sun et al.	8	6.8 y (2 mo to 15 y)*	6	2				5	3	
Liu et al.	6	3 y (1y to 7y)**	2	4			4	1		1
Hu et al.	5	8 y (5 y to 15 y)*	3	2	4	1				
Liu et al.	5	5.9 y (7 mo to 13 y)*	4	1	3	2				
Liu et al.	4	3 y (2 mo to 9 y)*	2	2		1	3			
Lou et al.	3	6 mo/6 y/8 y	1	2			3			
Zeng et al.	3	neonates	3				2		1	
Zhang et al.	3	6 y/8 y/9 y	3				3			
Li et al.	2	4 y/4 y	1	1	1		1			
Ji et al.	2	15 y/9 y	2			2				
Aghdam et al.	1	15 d	NR	NR				1		
Canarruto et al.	1	32 d	1			1				
Le et al.	1	3 mo		1		1				

medRxiv preprint doi: https://doi.org/10.1101/2020.04.01.20049833; this version posted April 14, 2020. The copyright holder for this preprint (which was not certified by peer review) is the author/funder, who has granted medRxiv a license to display the preprint in perpetuity. It is made available under a CC-BY-NC-ND 4.0 International license .

Lin et al.	1	7 y		1		1				
Pan et al.	1	3 y	1		1					
Wang et al.	1	19 days	1			1				
Zhang et al.	1	1 y 2 m		1		1				
Yu et al.	1	neonate	NR	NR	1					
Park et al.	1	10 y		1			1			
Cui et al.	1	55 d		1				1		
Tang et al.	1	10 y	1		1					
Zhang et al.	1	3 mo					1			
Cai et al.	1	7 y	1				1			
Zeng et al.	1	17 d	1				1			
Chen et al.	1	1 y	1						1	
Kam et al.	1	6 mo	1			1				
Chan et al.	1	10 y	1		1					
Total	1117		643	478	159 (14.2%)	406 (36.3|%)	514 (46.0%)	25 (2.1%)	13 (1.2%)	4 (0.4%)

* value expressed as mean (range)

** value expressed as median (range)

NR = not reported

medRxiv preprint doi: https://doi.org/10.1101/2020.04.01.20049833; this version posted April 14, 2020. The copyright holder for this preprint (which was not certified by peer review) is the author/funder, who has granted medRxiv a license to display the preprint in perpetuity. It is made available under a CC-BY-NC-ND 4.0 International license .

medRxiv preprint doi: https://doi.org/10.1101/2020.04.01.20049833; this version posted April 14, 2020. The copyright holder for this preprint (which was not certified by peer review) is the author/funder, who has granted medRxiv a license to display the preprint in perpetuity. It is made available under a CC-BY-NC-ND 4.0 International license .

Table 2. Distributions of clinical manifestations of children with COVID-19 described in the selected studies.

Clinical manifestations	Frequency of occurrence*
Fever	187 (47.5%)
Cough	163 (41.5%)
Pneumonia	145 (36.9%)
Pharyngeal erythema	81 (20.6%)
Tachycardia on admission	73 (18.6%)
Tachypnea on admission	53 (13.4%)
Nasal symptoms	44 (11.2%)
Upper airway infections	43 (10.9%)
Diarrhea	32 (8.1%)
Nausea/Vomiting	28 (7.1%)
Fatigue	20 (5.0%)
Respiratory distress	14 (3.5%)
Sore throat	10 (2.5%)
Respiratory failure	7 (1.8%)
Creptations	6 (1.5%)
Sputum	6 (1.5%)
Hypoxemia	5 (1.3%)
Abdominal pain	2 (0.5%)
Sneezing	2 (0.5%)
Cyanosis	2 (0.5%)
Lymphadenopathy	1(0.2%)

* expressed in absolute number and percentage in relation to the total of cases in which clinical manifestations were described (n = 393).

eTable 1. Clinical manifestations reported in the selected studies.

Studies	Lu et al.	Qiu et al.	Wang et al.	Zheng et al.	Xia et al.	Feng et al.	Cai et al.	Wei et al.	Su et al.	Zhou et al.	Sun et al.	Liu et al.	Hu et al.	Liu et al.	Liu et al.	Lou et al.	Zeng et al.	Zhang et al.	Li et al.	Ji et al.	Le et al.	Wang et al.	Zhang et al.	Park et al.	Cui et al.	Zhang et al.	Cai et al.	Zeng et al.	Chen et al.	Kam et al.	Canarruto et al.	Aghdam et al.	Lin et al.	Total*
N	171	36	31	25	20	15	10	9	9	9	8	6	5	5	4	3	3	3	2	2	1	1	1	1	1	1	1	1	1	1	1	1	1	393**
Fever	71 (41.5%)	13 (36%)	20 (65%)	13 (52%)	12 (60%)	5 (33%)	8 (80%)	4	2	4	6	6	1	2	3	3	2	2		1	1		1			1	1	1	1	1	1	1		187 (47.5%)
Cough	83 (48.5%)	7 (19%)	14 (45%)	11 (44%)	13 (65%)	1 (6%)	6 (60%)	2	1	2	6	6		2	3	1		1	1						1			1			1			163 (41.5%)
Pneumonia	111 (64.9%)	11 (30%)		15 (60%)								4					3												1					145 (36.9%)
Pharyngeal erythema	79 (46.2%)																	1							1									81 (20.6%)
Tachycardia on admission	72 (42.1%)																															1		73 (18.6%)
Tachypnea on admission	49 (28.7%)	1 (3%)			2 (10%)																											1		53 (13.4%)
Nasal symptoms	22 (12.9%)	1 (3%)		2 (8%)	3 (15%)	1 (6%)	3 (30%)			1						2		2	1	1	1				1			1			1		1	44 (11.2%)
Upper airway infections	33 (19.2%)			8 (32%)				2																										43 (10.9%)
Diarrhea	15 (8.8%)	2 (6%)	3 (9%)	3 (12%)	3 (15%)											2		2		1									1					32 (8.1%)
Nausea/ Vomiting	11 (6.4%)		2 (6%)	2 (8%)	2 (10%)						4	4										1						1	1					28 (7.1%)
Fatigue	13 (7.6%)		3 (10%)		1 (5%)										1	2																		20 (5.0%)
Respiratory distress					3 (15%)						8						1												1			1		14 (3.5%)
Sore throat		2 (6%)	2 (3%)		1 (5%)		4 (40%)											1																10 (2.5%)
Respiratory failure	3 (1,7%)			2 (8%)													1												1					7 (1.8%)

medRxiv preprint doi: https://doi.org/10.1101/2020.04.01.20049833; this version posted April 14, 2020. The copyright holder for this preprint (which was not certified by peer review) is the author/funder, who has granted medRxiv a license to display the preprint in perpetuity. It is made available under a CC-BY-NC-ND 4.0 International license .

Studies	Lu et al.	Qiu et al.	Wang et al.	Zheng et al.	Xia et al.	Feng et al.	Cai et al.	Wei et al.	Su et al.	Zhou et al.	Sun et al.	Liu et al.	Hu et al.	Liu et al.	Liu et al.	Lou et al.	Zeng et al.		Li et al.	Ji et al.	Le et al.	Wang et al.	Zhang et al.	Park et al.	Cui et al.	Zhang et al.	Cai et al.	Zeng et al.	Chen et al.	Kam et al.				Total
Creptations					1 (5%)						5																							6 (1.5%)
Sputum								1			4													1										6 (1.5%)
Hypoxemia	4 (2.3%)																								1									5 (1.3%)
Abdominal Pain				2 (8%)																														2 (0.5%)
Sneezing							2 (20%)																											2 (0.5%)
Cyanosis					1 (5%)												1																	2 (0.5%)
Lymphadenopathy															1																			1 (0.2%)

* Values are expressed as N and relative frequencies. Studies that described asymptomatic cases were not included in this table.

** The cases presented by Dong et al. were excluded from the total because data on patients' clinical manifestations were not provided.

medRxiv preprint doi: https://doi.org/10.1101/2020.04.01.20049833; this version posted April 14, 2020. The copyright holder for this preprint (which was not certified by peer review) is the author/funder, who has granted medRxiv a license to display the preprint in perpetuity. It is made available under a CC-BY-NC-ND 4.0 International license .