medRxiv preprint doi: https://doi.org/10.1101/2020.03.18.20038125; this version posted March 20, 2020. The copyright holder for this preprint (which was not certified by peer review) is the author/funder, who has granted medRxiv a license to display the preprint in perpetuity. It is made available under a CC-BY 4.0 International license .

Non-severe vs severe symptomatic COVID-19: 104 cases from the outbreak on the cruise ship "Diamond Princess" in Japan

Sakiko Tabata, M.D.[1†], Kazuo Imai, M.D.[1,2*†], Shuichi Kawano, M.D.[1,4], Mayu Ikeda, M.D.[1], Tatsuya Kodama, M.D.[1], Kazuyasu Miyoshi, M.D.[1], Hirofumi Obinata, M.D.[1,3], Satoshi Mimura, M.D.[1], Tsutomu Kodera, M.D.[1], Manabu Kitagaki, M.D.[1], Michiya Sato, M.D.[1], Satoshi Suzuki, M.D.[1], Toshimitsu Ito, M.D.[1], Yasuhide Uwabe, M.D.[1], Kaku Tamura, M.D.[1]

1. Self-Defense Forces Central Hospital, 24-2-1, Ikejiri, Setagaya-ku, Tokyo, Japan
2. Department of Infectious Disease and Infection Control, Saitama medical university, 38 Moro, Hongo, Iruma-gun, Saitama, Japan
3. Department of Emergency and Critical Care Medicine, Nippon Medical School, 1-1-5, Sendagi, Bunkyo-ku, Tokyo, Japan
4. Japan Ground Self-Defense Force Medical Service School, 24-2-1, Ikejiri, Setagaya-ku, Tokyo, Japan

* Corresponding author
†Both authors contributed equally

Corresponding author
Kazuo Imai, M.D.

Self-Defense Forces Central Hospital, 24-2-1, Ikejiri, Setagaya-ku, Tokyo, Japan
Department of Infectious Disease and Infection Control, Saitama medical university, 38 Moro, Hongo, Iruma-gun, Saitama, Japan
Mail; k_imai@saitama-med.ac.jp
Tel; 03-3411-0151 or 049-276-111

NOTE: This preprint reports new research that has not been certified by peer review and should not be used to guide clinical practice.

medRxiv preprint doi: https://doi.org/10.1101/2020.03.18.20038125; this version posted March 20, 2020. The copyright holder for this preprint (which was not certified by peer review) is the author/funder, who has granted medRxiv a license to display the preprint in perpetuity. It is made available under a CC-BY 4.0 International license .

Abstract

Background

The ongoing outbreak of 2019 novel coronavirus disease (COVID-19) is a global threat. Clarifying its clinical features such as risk factors for disease progression is a pressing issue. We analyzed the difference between non-severe and severe cases with COVID-19 as a result of the mass infection on a cruise ship "Diamond Princess" in Japan.

Methods

In this retrospective, single-center study, total 104 cases of laboratory-confirmed COVID-19 were enrolled from the mass infection on the cruise ship from 11th to 25th Feb, 2020, at Self-Defense Forces Central Hospital in Japan. Clinical records, laboratory data, and radiological findings were collected and analyzed. Clinical outcomes were followed up until 26th Feb, 2020.

Findings

Of the 104 patients, 47 were male. The median age was 68 years. During the observation period, eight patients deteriorated into the severe cases. Finally, 76 and 28 patients were classified as non-severe (asymptomatic, mild), and severe cases, respectively. Chest CT abnormalities were found in 43 in non-severe cases and 23 in severe cases. The prevalence of consolidation on chest CT scan and lymphopenia on the admission day was significantly higher in severe cases and in the eight cases which worsened into severe disease during the observation period.

Interpretation

The high proportion of non-severe cases corrects the assessment of the trend of the outbreak. Consolidation on chest CT scan and lymphopenia were possible risk factors for deterioration of COVID-19 and contribute to the clinical management.

Funding

Not applicable.

Research in context

Evidence before this study

We looked into PubMed database for articles published in English up to 1st, Mar, 2020, using the keywords "novel coronavirus", "2019 novel coronavirus", "2019-nCoV", "Severe acute respiratory syndrome coronavirus 2", "SARS-CoV2", "COVID-19", "mass infection", "herd infection", "cruise ship", "Diamond Princess", "asymptomatic" and "subclinical". There were no published clinical studies of featuring COVID-19 as a result of mass infection of cruise ship. We found a published researches entitled "Characteristics of COVID-19 infection in Beijing.", and "Radiological findings from 81 patients with COVID-19 pneumonia in Wuhan, China: a descriptive study" comparing patients with COVID-19 between asymptomatic, mild, and severe cases. However, above researches

medRxiv preprint doi: https://doi.org/10.1101/2020.03.18.20038125; this version posted March 20, 2020. The copyright holder for this preprint (which was not certified by peer review) is the author/funder, who has granted medRxiv a license to display the preprint in perpetuity. It is made available under a CC-BY 4.0 International license .

did not describe the marker of deterioration, or the risk factors for disease progression.

Added value of this study

We presented a high proportion of asymptomatic and mild cases in patients infected with severe acute respiratory syndrome coronavirus 2 (SARS-CoV2). On the admission day, the prevalence of consolidation detected by CT scan and lymphopenia were significant higher in severe cases and in cases which deteriorated into sever cases during the observation period. Consolidation on CT scan and lymphopenia reflect the disease progression. This report contributes to the improvement of the epidemiological and clinical management of COVID-19.

Implications of all the available evidence

There is a high prevalence of non-severe cases in patients infected with COVID-19 as a result of the mass infection on a cruise ship. The prevalence of asymptomatic and mild cases of COVID-19 contributes to the further assessment on the trend of outbreak. Consolidation detected by CT scan and lymphopenia are useful for the markers of disease progression.

Introduction

The 2019 novel coronavirus disease (COVID-19) is caused by a novel coronavirus – severe acute respiratory syndrome coronavirus 2 (SARS-CoV2). The first case was reported in Wuhan, China, in December 2019, [1] and the ongoing outbreak has been declared by the World Health Organization as a Public Health Emergency of International Concern. Since the specific treatment for COVID-19 is unknown, detection of the patients who are at high risk of severe illness is necessary in order to prepare sufficient supportive therapy. Also, explosive increase in patients caused a collapse of health care system. Therefore triage of the patients and transportation to the proper facilities are required. The knowledge of the clinical characteristics of the disease and pathogenicity of the virus is increasingly accumulated. However, detail of the clinical characteristics is still unknown and most of the articles previously printed are mainly focused on the severe cases of COVID-19. [2-5] In Japan, a large number of infection among passengers and crew members of the cruise ship “Diamond Princess” occurred in Feb, 2020. By 1st March, 2020, over 700 people were laboratory-confirmed with SARS-CoV2 infection. All symptomatic and asymptomatic cases were referred to the medical institutions designated for infectious diseases in accordance with Infectious Diseases Control Law of Japan. Approximately 15% of the laboratory-confirmed cases were admitted to Self-Defense Forces Central Hospital in Japan.

The prevalence of asymptomatic and mild cases of COVID-19 contributes to the assessment of epidemic trend [6]. In the clinical settings, identifying the patients who are at risk of deterioration is essential. For these reasons, understanding of the differences between non-severe (asymptomatic and mild) cases and severe cases is required.

Therefore, we retrospectively collected and analyzed detailed clinical findings in hospitalized cases

medRxiv preprint doi: https://doi.org/10.1101/2020.03.18.20038125; this version posted March 20, 2020. The copyright holder for this preprint (which was not certified by peer review) is the author/funder, who has granted medRxiv a license to display the preprint in perpetuity. It is made available under a CC-BY 4.0 International license .

with COVID-19 of the cruise ship outbreak, including asymptomatic/mild and severe symptomatic cases, at the Self-Defense Forces Central Hospital in Japan.

Methods

Study design and patients

We conducted a retrospective review on the medical records of 104 laboratory-confirmed patients with COVID-19 who were referred to the Self-Defense Forces Central Hospital in Japan, since 11th to 25nd Feb 2020. In the cruise ship, all patients were examined under quantitative reverse transcription polymerase chain reaction (qRT-PCR) or nested polymerase chain reaction (PCR) for SARS-CoV2 in the pharyngeal swab or sputum according to the recommendation by the National Institute of Infectious Disease at the public health institute.[7] This study was reviewed and approved by the Japan Self-Defense Forces Central Hospital (approval number 01-011). Both written and oral informed consent was obtained from each enrolled patient.

Data collection

We retrospectively collected patient information from the electronic medical records of our hospital, including clinical records, laboratory findings, and chest CT scans. All information were collected and reviewed by two study investigators (ST and KI),

Definitions

The geographical regions were classified according to the standard country or area codes for statistical use (M49) by the United Nations Statistics Division. Asymptomatic cases were defined as patients with no history of clinical signs and symptoms. Severe symptomatic cases were defined as patients showing clinical symptoms of pneumonia (dyspnea, tachypnea, saturation of percutaneous oxygen (SpO2) <93%, and patients' need for oxygen therapy). [8] Other symptomatic cases were classified as mild cases.

Statistical analysis

Continuous variables were expressed as mean standard deviation (SD) or median interquartile range [IQR], and compared with under the T-test or Wilcoxon rank-sum test for parametric or non-parametric data, respectively; categorical variables were expressed as number (%) and compared by $\chi 2$ test or Fisher''s exact test. Multivariable logistic regression analysis was used for multivariate analysis. The final multivariable logistic regression models were adjusted for age, sex, smoking, and any underlying disease. A two-sided *p*-value of less than 0.05 was considered statistically significant. All statistical analyses were calculated using Stata13.

Role of the funding source

There was no funding source for this study.

Result

medRxiv preprint doi: https://doi.org/10.1101/2020.03.18.20038125; this version posted March 20, 2020. The copyright holder for this preprint (which was not certified by peer review) is the author/funder, who has granted medRxiv a license to display the preprint in perpetuity. It is made available under a CC-BY 4.0 International license .

During the observation period, total 107 laboratory-confirmed patients with COVID-19 from the cruise ship were hospitalized at the Self-Defense Forces Central Hospital in Japan. Three patients were excluded from this study because of their withdrawal to join this study. Therefore, the remaining 104 patients were analyzed. Clinical history, physical examination and chest CT scan were evaluated on the admission day, and blood tests were conducted within two days. The characteristics of the 104 patients are presented in Table 1. The age range was 25–93 years (median, 68 years; IQR, 46.75–75), and 47 patients (45.2%) were male. The most common nationality of patients was Eastern Asia, which included Japan and China. The observation period is from three to fifteen days (median, 10; IQR, 7–10 day). Fifty two patients (50.0 %) had comorbidities.

The clinical findings and severity of the patients before and after admission are shown on Table 2. Of the 104 patients, the most common clinical signs and symptoms presented before the admission were fever (28.8%) and cough (27.9%). On the admission day, 43 patients (41.3%) didn't show any symptoms; therefore, these patients were classified as asymptomatic. Forty-one patients (39.4%) were classified as mild cases, and 20 patients (19.2%) were severe cases. During the observation period, 80 new clinical signs and symptoms arose. Seven asymptomatic cases were reclassified as mild cases. Three asymptomatic cases and five mild cases required oxygen therapy because of the pneumonia of COVID-19; thus, they were reclassified as severe cases. The confirmed classification of severity at the end of the observation is; 33 patients (31.7%) as asymptomatic, 43 patients (41.3%) as mild, and 28 patients (26.9 %) as severe. Describing about the eight patients who deteriorated and reclassified as severe cases, the age range was 42–87 years (median, 70 years; IQR, 70–77), and five patients (62.5%) were male. The period of deterioration from onset was 1- 5 days (median, 4 days; IQR, 2.5-5). Also, of all the patients, 14 patients (13.5%) needed oxygen therapy, and a patient required mechanical ventilation. None of the patients died during the observation period.

The differences in clinical, laboratory, and radiographic abnormality on the admission day between non-severe cases and severe cases were analyzed. There were no significant differences observed in the distribution of age, sex, and comorbid condition between two groups (Table 3). Of the 76 non-severe patients, 43 patients (56.6%) manifested the abnormal findings on CT scan with various patterns. (Figure 1). In univariate analyses, the prevalence of CT abnormality detected on the admission day was significantly higher in the severe cases than in non-severe cases (85.2% vs 56.6%; $p = 0.03$; OR, 3.53; 95% CI; 1.21-10.27). Significant differences in the prevalence of the CT pattern were found between severe and non-severe cases as follows: bilateral lung findings (57.1% vs 28.9%; OR, 3.27; 95% CI; 1.33–8.06; $p = 0.01$), multifocal ground-glass opacity (GGO) (63.0% vs 34.2%; OR, 2.97; 95% CI; 1.21–7.26; $p = 0.02$), and consolidation (48.1% vs 19.7%; OR, 3.52; 95% CI; 1.38–8.96; $p = 0.01$). With regard to blood tests, the elevation of aspartate transaminase (AST) ≥ 38 IU/dL (32.1% vs 11.8%; OR, 3.52; 95% CI; 1.22-10.12; $p = 0.01$) and depletion of lymphocyte count <1,200 (/μL) (lymphopenia) (57.1% vs 25.0%; OR, 4.00; 95% CI; 1.61-9.95; $p <$ 0.01) in severe cases was significantly higher than in non-severe cases. Subsequently, the patients

medRxiv preprint doi: https://doi.org/10.1101/2020.03.18.20038125; this version posted March 20, 2020. The copyright holder for this preprint (which was not certified by peer review) is the author/funder, who has granted medRxiv a license to display the preprint in perpetuity. It is made available under a CC-BY 4.0 International license .

who worsened to severe cases during the observation period (n=8) were compared with the patients in non-severe cases (n=76). In the patients who deteriorated, eight patients (100.0%) presented the radiographical abnormality on CT in prior to the typical pneumonia symptoms (Figure 2). Consolidation on chest CT scan and lymphopenia were found in six (75.0%) and five patients (62.5 %), respectively. In univariate analyses, the prevalence of consolidation (75.0% vs 19.7%; OR, 12.20; 95% CI; 2.23–66.59; $p = 0.04$) and lymphopenia (62.5% vs 25.0%;OR, 5.00; 95% CI; 1.10–22.92; $p = 0.04$) were found to be significant higher in the patients who worsened to severe cases.

In multivariate analysis, the prevalence of consolidation detected by chest CT scan (adjusted OR: 3.24; 95% CI; 1.04-10.40; $p = 0.04$), and lymphopenia (adjusted OR, 4.30; 95% CI; 1.50-13.75; $p < 0.01$) were found to be significant higher in severe cases.

Discussion

In the outbreak of COVID-19 on the cruise ship "Diamond Princess," members of the cruise ship were tested by PCR for SARS-CoV2 and all laboratory-confirmed cases were referred to the hospitals. This situation is worthy to note because we observed the clinical course of even asymptomatic or mild symptomatic patients, which have not been investigated in the reports previously published. [2-5]

The possible risk factors for deterioration of COVID-19 have been unclear, because patients do not visit hospitals if they are asymptomatic or only mild symptomatic. Based on the previous findings of COVID-19 in China, old age, male sex, and presence of comorbidities may be risk factors for disease progression and poor prognosis.[1] In this study, the prevalence of consolidation detected by chest CT scan and lymphopenia were significantly higher in severe cases and in the cases that worsened to severe condition during the observation period than in non-severe cases ($p < 0.05$). Therefore, consolidation and lymphopenia are considered as possible risk factors for disease progression of COVID-19. Pan F, et al. and Shi H, et al. reported that the pattern of abnormal lung findings was varied from GGO into consolidation during the time course of COVID-19 [9], and the appearance of consolidation became more frequent in patients within 1-3 weeks after symptom onset. [10] Previous reports showed 55% of patients with COVID-19 developed dyspnea a median of 8 days (IQR, 5.0–13.0) after symptom onset, [1] thus, the timing of appearance of consolidation on CT scan is associated with the timing of deterioration of the disease. Generally, consolidation is easily detectable in chest X-ray. It may be useful for evaluation for risk of the disease progression in the patients with COVID-19 in the setting with limited resources,

With regard to blood tests, lymphopenia is a common feature in symptomatic COVID-19 [11,12], and this can be caused by either direct effect of the SARS-CoV2 or cytokines. Lymphopenia was also frequently found in SARS [13], and was considered as a marker of disease activity. [14] Our findings

medRxiv preprint doi: https://doi.org/10.1101/2020.03.18.20038125; this version posted March 20, 2020. The copyright holder for this preprint (which was not certified by peer review) is the author/funder, who has granted medRxiv a license to display the preprint in perpetuity. It is made available under a CC-BY 4.0 International license .

suggest that lymphopenia may also reflect the disease progression and lead a new insight into the phenotype and pathogenicity of SARS-CoV2.

CT scan showed a high prevalence of abnormality in lungs in non-severe cases (56.6 %) and severe cases (85.1 %), and that findings are also seen even in asymptomatic cases. Shi H, et al. also mentioned these asymptomatic abnormal lung findings in their report focusing on the radiological findings on CT scan of COVID-19 cases. [10] This interesting clinical feature of the SARS-CoV2 infection has not been reported in the SARS-CoV or Middle East respiratory syndrome coronavirus (MERS-CoV). All of the eight patients, who reclassified as severe cases from non-severe case during the observation period, presented CT abnormality in advance of the appearance of typical pneumonia symptoms. Moreover, less than half of the patients had no obvious symptoms such as fever and cough. These facts warn us that COVID-19 pneumonia progresses “silently” without any remarkable symptoms. Assessment with the blood test and chest CT scan might lead to a successful devotion of medical resources to the patients who have the risk of disease progression in the setting and mass infection as well as in the normal clinical settings. On the other hand, majority of asymptomatic cases with radiological abnormality on CT scan did not develop the severe pneumonia. The difference of clinical outcomes may associate with their background, and genetic and pathogenic diversity of SARS-CoV2. Understanding of its relevance to the duration of virus shedding or to the incidence rate of secondary bacterial pneumonia is important for improvement of clinical management. Further study is required to clarify this clinical impact in the asymptomatic and mild patients with COVID-19.

It is important to determine the proportion of asymptomatic and mild cases to assess not only the risk of subsequent outbreaks but also the future trends. [6] Generally, asymptomatic and mild infections contribute to herd immunity and its dampening effect on epidemic spread. [6,15] However, the prevalence of asymptomatic and mild cases of COVID-19 has not been elucidated because detection of the asymptomatic case by RT-PCR is not realistic, except for the limited situation like a mass infection. In this study, we showed that 73.0 % of the patients in the mass infection on a cruise ship were asymptomatic and mild cases, and the proportion was higher than previously reported [6,11,16]. However, the sensitivity of RT-PCR is considered insufficient [17], and the accurate prevalence is still underestimated. The serological screening by using specific antibody of COVID-19 is expected to confirm our result. Many countries and institutions are using contact tracing in the surveillance of COVID-19. However, it is suggested that the large number of asymptomatic and mild patients may have been overlooked in the past.

Viral RNA was frequently detected through throat swabs or sputum even in asymptomatic and mild symptomatic patients. In Germany and China, the transmission from an asymptomatic patient to another person has been reported. [18-20] Zou L, et al. showed that viral RNA was detected in the upper respiratory specimen in asymptomatic patients over 11 days, and the viral load of an asymptomatic patient was equivalent to that of symptomatic cases. [21] Also, the fact that we found CT abnormality even in the asymptomatic patients also suggest that they may have a certain amount of viral load.

medRxiv preprint doi: https://doi.org/10.1101/2020.03.18.20038125; this version posted March 20, 2020. The copyright holder for this preprint (which was not certified by peer review) is the author/funder, who has granted medRxiv a license to display the preprint in perpetuity. It is made available under a CC-BY 4.0 International license .

Previous findings along with our results may support the evidence that asymptomatic patients also shed the SARS-CoV2 from the upper respiratory tract. Also, during the mass infection on the cruise ship, there was a possibility that both asymptomatic and symptomatic patients spread the SARS-CoV2. Further study is desired to clarify the transmission from an asymptomatic patient to another person.

The limitations of this study were the selection bias and small number of patients. We enrolled the ideal homogeneous clusters of relatively healthy person who can get aboard a cruise ship for a long term. However, our patient population and was not completely representative of patients in the normal clinical settings. In addition, there were only a few patients who deteriorated into severe cases from non-severe case during the observation period in this study. Therefore, further multicenter, multi-national cohort study is desired to determine the prediction marker of diseases progression.

Conclusion

Our study highlighted the high prevalence of asymptomatic and mild cases of COVID-19 as a result of mass infection on a cruise ship. Consolidation on CT scan and lymphopenia may reflect the risk of disease progression. Our findings contribute to estimate the future trend of outbreaks, better understanding of clinical course and improvement of the management of COVID-19. Further cohort study is needed to determine the prediction marker of diseases activity.

Competing interest

The authors declare that they have no conflicts of interests.

Funding

This research did not receive any specific grant from funding agencies in the public, commercial, or nonprofit sectors.

Authors' contributions

TI and KT, study conception and design; ST and KI, collecting data and performed the data analysis; ST, KI, MI, and KM manuscript drafting, and editing; TaK, HO, SK, TsK, MK and SM, manuscript revision; MS, SS and UY, study supervision. All authors read and approved the final manuscript.

Acknowledgments

medRxiv preprint doi: https://doi.org/10.1101/2020.03.18.20038125; this version posted March 20, 2020. The copyright holder for this preprint (which was not certified by peer review) is the author/funder, who has granted medRxiv a license to display the preprint in perpetuity. It is made available under a CC-BY 4.0 International license .

We thank everyone involved in the COVID-19 management and treatment team from the Self-Defense Forces Central Hospital in Japan and members who were assembled from other institutes of Japan Self-Defense Forces. Particularly, we thank Dr. Koji Kameda, Dr. Takayuki Yamamoto, Dr. Daishi Higashiyama, Dr. Yoshitaka Imoto, Dr. Masataka Miyama, Dr. Tsukasa Mizuno, Dr. Kento Kato, Dr. Masaru Honda, Dr. Shoji Takeda, and Dr. Masumi Ogawa, Dr. Shingo Tanaka, Dr. Hisashi Sasaki, Dr. Mitsuki Yamaga, Dr. Shinichiro Ota and Dr. Hiroaki Taniguchi for supporting the data collection, and Dr. Akira Fujikawa and Dr. Shohei Inui for the interpretation of chest CT scan. We also thank Mr. Shingo Tamaki (School of Tropical Medicine and Global Health, Nagasaki University, Japan) for the supporting statistical analysis, and Colonel. Kazuhiro Nakaya (Medical Department, Ground Staff Office, Ministry of Defense) for the scientific advice.

References

1. Huang C, Wang Y, Li X, et al. Clinical features of patients infected with 2019 novel coronavirus in Wuhan, China. *The Lancet* 2020; **395**: 497-506.
2. Zhang JJ, Dong X, Cao YY, et al. Clinical characteristics of 140 patients infected by SARS-CoV-2 in Wuhan, China. *Allergy* 2020.
3. Chen N, Zhou M, Dong X, et al. Epidemiological and clinical characteristics of 99 cases of 2019 novel coronavirus pneumonia in Wuhan, China: a descriptive study. *The Lancet* 2020; **395**: 507-13.
4. Wang D, Hu B, Hu C, et al. Clinical Characteristics of 138 Hospitalized Patients With 2019 Novel Coronavirus-Infected Pneumonia in Wuhan, China. *JAMA* 2020.
5. Li K, Wu J, Wu F, et al. The Clinical and Chest CT Features Associated with Severe and Critical COVID-19 Pneumonia. *Investigative Radiology* 2020.
6. Munster VJ, Koopmans M, van Doremalen N, van Riel D, de Wit E. A Novel Coronavirus Emerging in China - Key Questions for Impact Assessment. *The New England Journal of Medicine* 2020; **382**: 692-4.
7. Nao N, Shirato K, Katano H, et al. Detection of second case of 2019-nCoV infection in Japan. National Institute of Infectious Diseases. .https://www.niid.go.jp/niid/images/vir3/nCoV/method-niid-20200123-2_erratum.pdf [Latest accessed 1/Mar/2020]
8. Zhang J, Zhou L, Yang Y, Peng W, Wang W, Chen X. Therapeutic and triage strategies for 2019 novel coronavirus disease in fever clinics. *The Lancet Respiratory Medicine*.
9. Pan F, Ye T, Sun P, et al. Time Course of Lung Changes On Chest CT During Recovery From 2019 Novel Coronavirus (COVID-19) Pneumonia. *Radiology* 2020: 200370.
10. Shi H, Han X, Jiang N, et al. Radiological findings from 81 patients with COVID-19 pneumonia in Wuhan, China: a descriptive study. *The Lancet Infectious Diseases*.

medRxiv preprint doi: https://doi.org/10.1101/2020.03.18.20038125; this version posted March 20, 2020. The copyright holder for this preprint (which was not certified by peer review) is the author/funder, who has granted medRxiv a license to display the preprint in perpetuity. It is made available under a CC-BY 4.0 International license .

11. Guan W-j, Ni Z-y, Hu Y, et al. Clinical Characteristics of Coronavirus Disease 2019 in China. *New England Journal of Medicine* 2020.

12. Chen H, Guo J, Wang C, et al. Clinical characteristics and intrauterine vertical transmission potential of COVID-19 infection in nine pregnant women: a retrospective review of medical records. *The Lancet*.

13. Wong RS, Wu A, To KF, et al. Haematological manifestations in patients with severe acute respiratory syndrome: retrospective analysis. *BMJ* 2003; **326**: 1358-62.

14. Booth CM, Matukas LM, Tomlinson GA, et al. Clinical features and short-term outcomes of 144 patients with SARS in the greater Toronto area. *JAMA* 2003; **289**: 2801-9.

15. Bellan SE, Pulliam JRC, Dushoff J, Meyers LA. Ebola control: effect of asymptomatic infection and acquired immunity. *The Lancet* 2014; **384**: 1499-500.

16. Wang W, Tang J, Wei F. Updated understanding of the outbreak of 2019 novel coronavirus (2019-nCoV) in Wuhan, China. *Journal of Medical Virology* 2020; **92**: 441-7.

17. Huang P, Liu T, Huang L, et al. Use of Chest CT in Combination with Negative RT-PCR Assay for the 2019 Novel Coronavirus but High Clinical Suspicion. *Radiology* 2020: 200330.

18. Rothe C, Schunk M, Sothmann P, et al. Transmission of 2019-nCoV Infection from an Asymptomatic Contact in Germany. *The New England Journal of Medicine* 2020.

19. Bai Y, Yao L, Wei T, et al. Presumed Asymptomatic Carrier Transmission of COVID-19. *JAMA* 2020.

20. Yu P, Zhu J, Zhang Z, Han Y, Huang L. A familial cluster of infection associated with the 2019 novel coronavirus indicating potential person-to-person transmission during the incubation period. *The Journal of Infectious Diseases* 2020.

21. Zou L, Ruan F, Huang M, et al. SARS-CoV-2 Viral Load in Upper Respiratory Specimens of Infected Patients. *The New England Journal of Medicine* 2020.

Figure Legends

Figure 1. The CT pattern of abnormal lung findings among asymptomatic patients with COVID-19. A patient 73 years old, female. The patchy non-segmental ground grass opacity (GGO) adjacent to the parietal pleura in the right upper lobe (A and B), and in both lower lobes (C and D). A patient 70 years old, female. The GGO with interlobular septal thickening (crazy-paving appearance) adjacent to the parietal pleura in the both lower lobes (E). A patient 76 years old, male. CT scan showed the GGO with consolidation, bronchial wall thickening, and bronchiectasis in the left lower lobe (F).

Figure 2. The progress of CT findings in a patient with COVID-19. A male patient 75 years old was asymptomatic on the admission day. On the fourth day of admission, he showed tachypnea and hypoxemia, and treated oxygen therapy. On the admission day, Chest CT scan showed multifocal

medRxiv preprint doi: https://doi.org/10.1101/2020.03.18.20038125; this version posted March 20, 2020. The copyright holder for this preprint (which was not certified by peer review) is the author/funder, who has granted medRxiv a license to display the preprint in perpetuity. It is made available under a CC-BY 4.0 International license .

GGO adjacent to the parietal pleura in multiple lobes with emphysematous changes (A, B and C). On the tenth day of admission, a follow-up chest CT scan showed an increase of extent of GGO with crazy-paving appearance (D, E and F).

medRxiv preprint doi: https://doi.org/10.1101/2020.03.18.20038125; this version posted March 20, 2020. The copyright holder for this preprint (which was not certified by peer review) is the author/funder, who has granted medRxiv a license to display the preprint in perpetuity. It is made available under a CC-BY 4.0 International license .

Table1: The baseline characteristics of patients with COVID-19 from the cruise ship

	Total number of patients (n = 104)
Characteristics	
Age	68 [46.75–75]
Sex (male)	47 (45.2 %)
Observation period (days)	10 [7-10]
The period onset to admission (days)	5 [2 - 7]
Nationality	
Eastern Asia	55 (52.9%)
Southeast Asia	21 (20.2%)
Europe	4 (3.8%)
Northern America	14 (13.5%)
Oceania	4 (3.8%)
Others	6 (5.8%)
Smoking	
Yes	18 (17.3%)
Comorbid condition	
Total	52 (50.0%)
Cardiovascular	31 (29.8%)
Endocrine	9 (8.7%)
Diabetes mellitus	7 (6.7%)
Respiratory	7 (6.7%)
Carcinoma	4 (3.8%)

Data are n (%) or median (IQR), unless otherwise specified.

medRxiv preprint doi: https://doi.org/10.1101/2020.03.18.20038125; this version posted March 20, 2020. The copyright holder for this preprint (which was not certified by peer review) is the author/funder, who has granted medRxiv a license to display the preprint in perpetuity. It is made available under a CC-BY 4.0 International license .

Table 2. Clinical findings and severity of patients with COVID-19

	Number (%) n = 104	
	Started before the admission	**End of the observation period**
Signs and symptoms		
Fever	30 (28.8%)	36 (34.6%)
Cough	29 (27.9%)	43 (41.3%)
Malaise	12 (11.5%)	22 (21.2%)
Headache	10 (9.6%)	18 (17.3%)
Sore throat	11 (10.6%)	11 (10.6%)
Runny nose	16 (15.4%)	25 (24.0%)
Diarrhea	8 (7.7%)	10 (9.6%)
Dyspnea	7 (6.7%)	19 (18.3%)
Tachypnea	16 (15.4%)	24 (23.1%)
SpO2 < 93 %	3 (2.9%)	14 (13.5%)
Treatment		
Oxygen therapy	3 (2.9%)	14 (13.5%)
Mechanical ventilation	-	1 (1.0%)
Severity		
Asymptomatic	43 (41.3%)	33 (31.7%)
Mild	41 (39.4%)	43 (41.3%)
Severe	20 (19.2 %)	28 (26.9%)

Data are n (%)

medRxiv preprint doi: https://doi.org/10.1101/2020.03.18.20038125; this version posted March 20, 2020. The copyright holder for this preprint (which was not certified by peer review) is the author/funder, who has granted medRxiv a license to display the preprint in perpetuity. It is made available under a CC-BY 4.0 International license .

Table 3. The differences in clinical characteristics between non-severe cases and severe cases on the admission day

			Univariate		Multivariate	
	Non-severe n = 76	**Severe n = 28**	**p-value**	**OR**	**p-value**	**Adjusted OR**
Characteristics						
Age	66.5 [44.75-74]	72.5 [55.25-76.5]	0.08		0.62	
Sex (male)	32 (42.1%)	15 (53.6%)	0.37		0.28	
Smoking						
Yes	11 (14.5%)	7 (25.0%)	0.24		0.08	
Underlying disease						
Total	34 (44.7%)	18 (64.3%)	0.12		0.18	
Radiographically findings on the day of admission						
Abnormal lung finding	43 (56.6%)	23 (82.1%)	0.02*	3.53 (1.21-10.27)		
Bilateral lung findings	22 (28.9%)	16 (57.1%)	0.01*	3.27 (1.33-8.03)		
Multifocal GGO	26 (34.2%)	17 (60.7 %)	0.02*	2.97 (1.21-7.26)		
Consolidation	15 (19.7%)	13 (46.4 %)	0.01*	3.52 (1.38-8.96)	0.04*	3.24 (1.04 - 10.40)
Laboratory findings on the day of admission						
AST > 38 (IU/L)	9 (11.8%)	9 (32.1%)	0.02*	3.52 (1.22-10.12)	0.07	
ALT > 45 (IU/L)	10 (13.2%)	7 (25.0%)	0.22			
LDH > 230 (IU/L)	17 (22.4%)	10 (35.7%)	0.21			
CRP > 1.0 (mg/dL)	34 (44.7 %)	19 (67.9%)	0.07			
White blood cell count < 4000 (/μL)	13 (17.1%)	6 (21.4%)	0.58			
Platelet count < 20 ($\times 10^4$/μL)	6 (7.9%)	2 (7.1%)	1.00			
Lymphocyte count <1200 (/μL)	19 (25.0%)	16 (57.1%)	< 0.01*	4.00 (1.61-9.95)	< 0.01*	4.30 (1.50-13.75)

Data are n (%), or median [IQR], unless otherwise specified.

OR, odds ratio; 95% CI, 95% confidence interval; GGO, ground-glass opacity; AST, aspartate aminotransferase; ALT, alanine aminotransferase; LDH, lactate dehydrogenase; CRP, C reactive protein.

medRxiv preprint doi: https://doi.org/10.1101/2020.03.18.20038125; this version posted March 20, 2020. The copyright holder for this preprint (which was not certified by peer review) is the author/funder, who has granted medRxiv a license to display the preprint in perpetuity. It is made available under a CC-BY 4.0 International license .

Asterisk indicated the statistical significance.

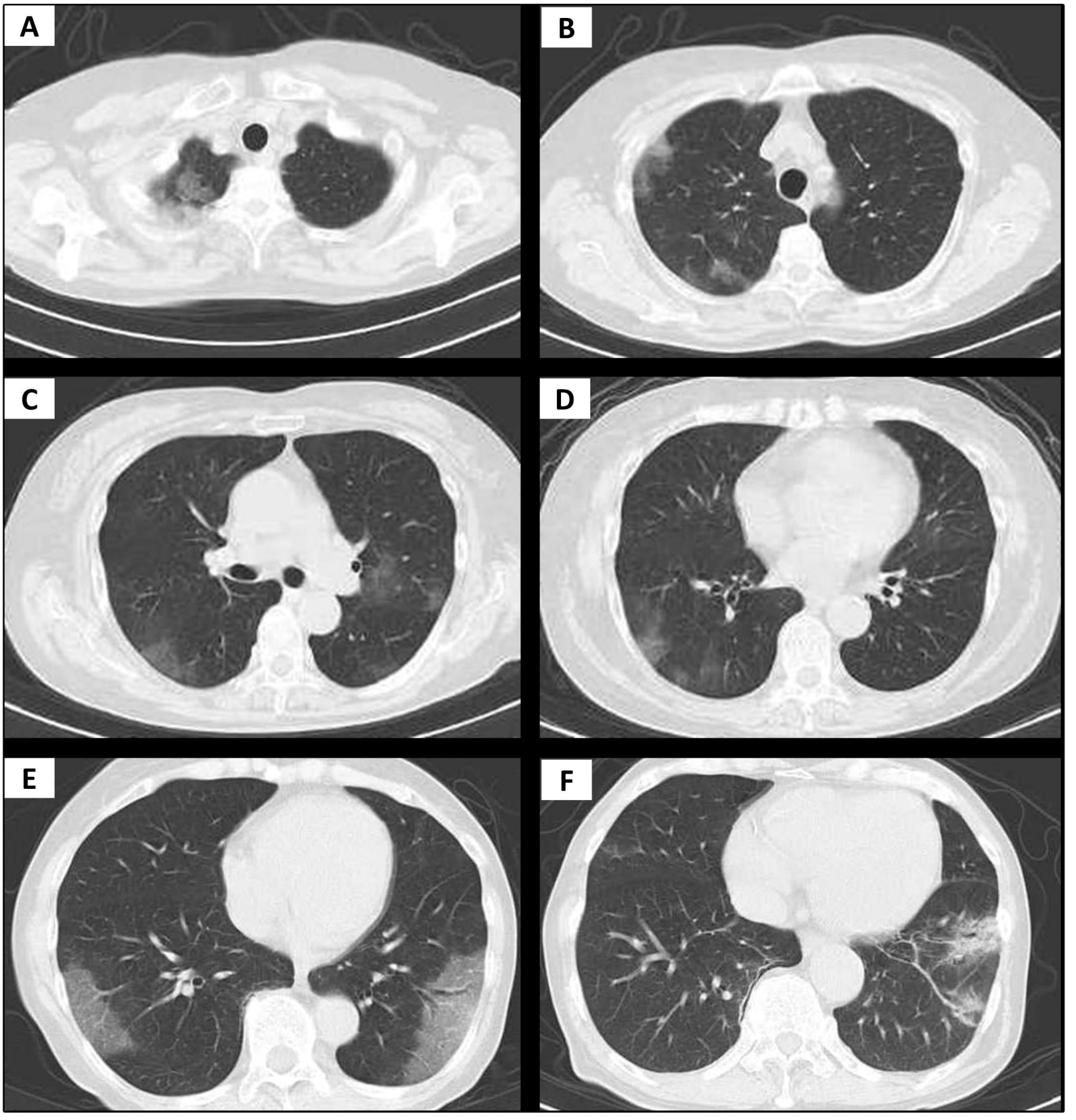
A
B
C
D
E
F

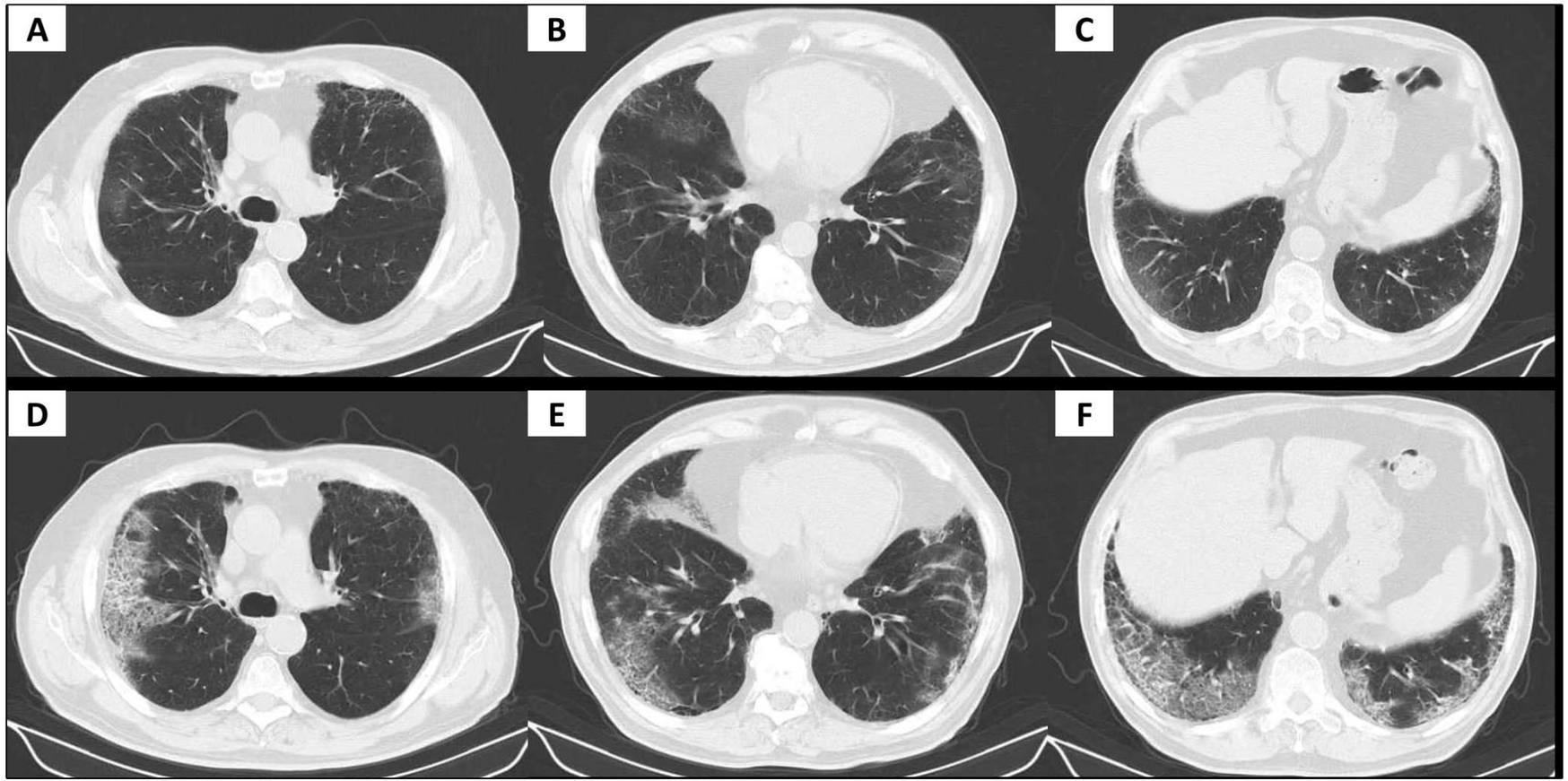
A
B
C
D
E
F